

# Research letter

## Novel autosomal dominant mutation in lorcrin presenting as prominent ichthyosis

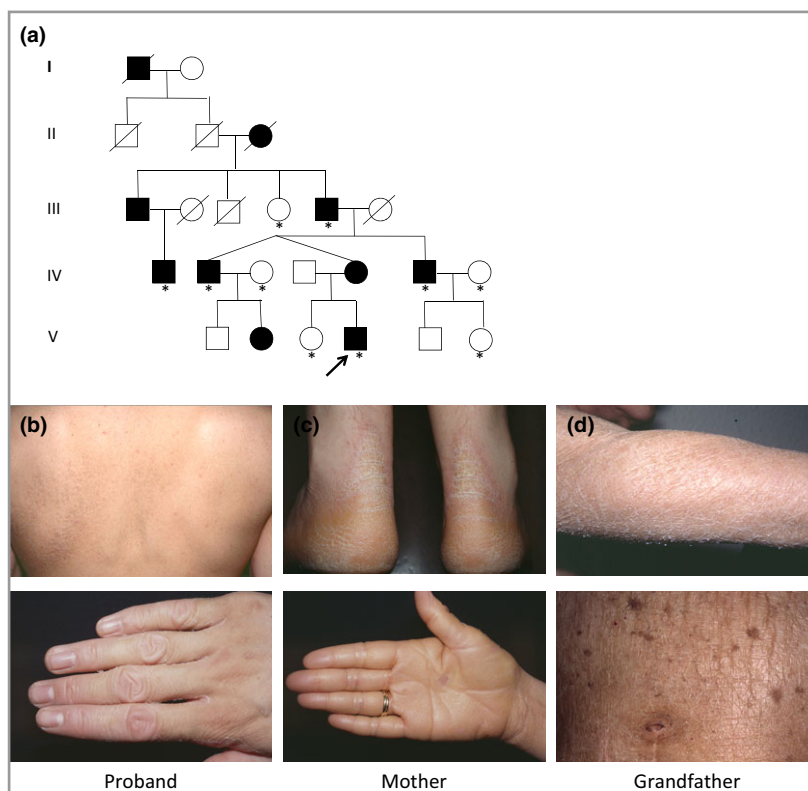
DOI: 10.1111/bjd.13895

DEAR EDITOR, Lorcrin keratoderma (syn. Camisa syndrome, OMIM 604117) is a rare autosomal dominant genodermatosis characterized by palmoplantar keratoderma and ichthyosis.<sup>1,2</sup> It is caused by mutations in lorcrin, a small basic protein synthesized in the upper granular layer, which becomes a major constituent of the cornified cell envelope.<sup>3</sup> Seven distinct mutations in lorcrin have been reported in 15 unrelated pedigrees to date.<sup>4–6</sup> We report a multi-generation family with prominent ichthyosis and palmoplantar involvement due to a novel mutation in lorcrin.

The proband was a 14-year-old boy who presented with generalized dryness and scaling affecting his trunk and all four

limbs, previously thought to be ichthyosis vulgaris, which was reported from early childhood (Fig. 1a). Clinical examination revealed widespread, prominent ichthyosis and mild diffuse transgredient hyperkeratosis of palms and soles. There was no evidence of atopic dermatitis or keratosis pilaris. His mother and eight other family members were similarly affected (Fig. 1b). Subsequently, a further child was born with a colloidion membrane followed by generalized ichthyosis.

Biopsies of affected skin were processed for light and electron microscopy by standard methods (upper back of the proband's mother) or for electron microscopy only (affected acral skin from the proband's grandfather).<sup>7</sup> Following informed consent, genomic DNA was extracted from blood or saliva samples from 10 affected and unaffected family members (Fig. 1a). A whole exome sequencing approach was taken to analyse the proband's DNA (Methods S1; see Supporting Information).

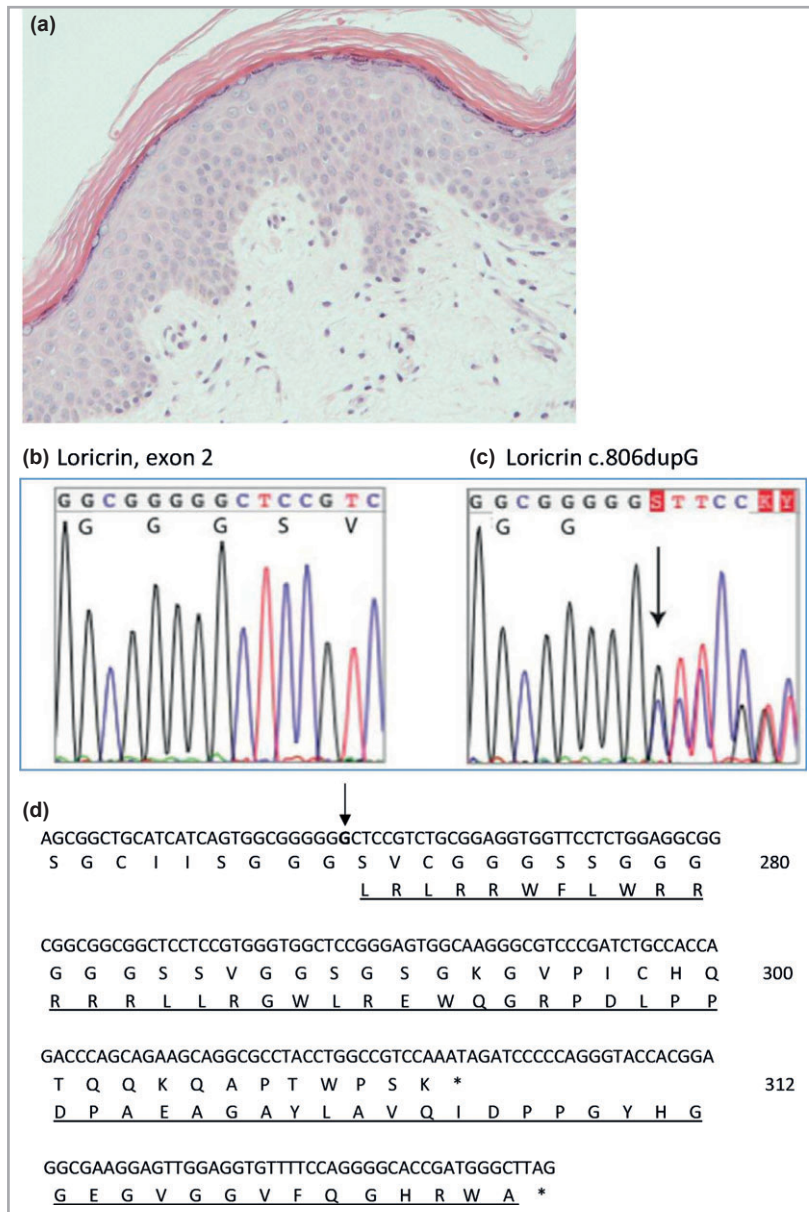


**Fig 1.** (a) Pedigree of family with lorcrin keratoderma. Filled symbols represent affected individuals. Whole exome sequencing was performed on one affected family member. \*marks individuals who were screened for lorcrin mutation by Sanger sequencing. (b–d) Clinical pictures of (b) the proband: ichthyosis of upper back with brawny appearance and knuckle pads; (c) proband's mother: transgredient hyperkeratosis of palms and soles; (d) proband's grandfather: widespread ichthyosis of forearm and trunk.

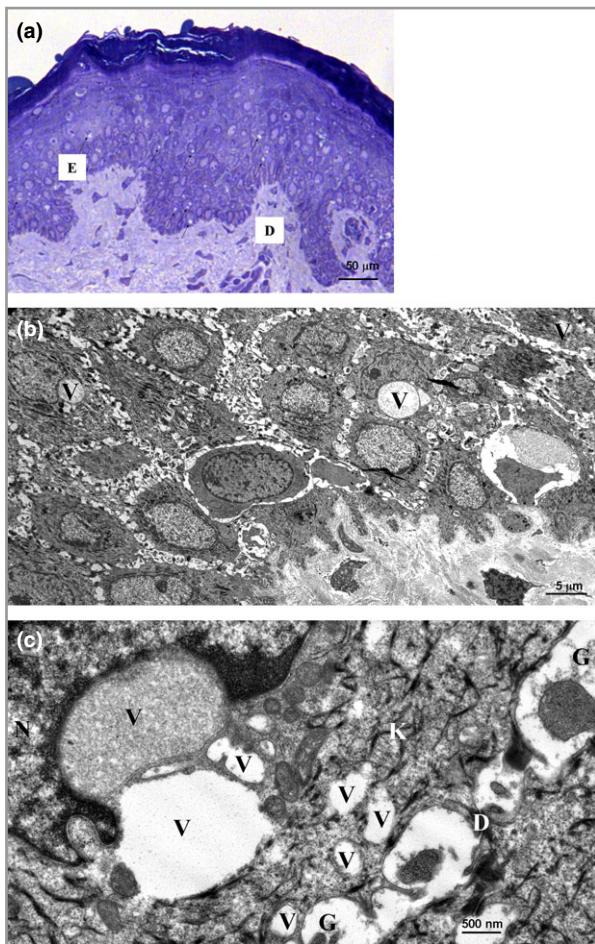
Light microscopy of skin from the proband's mother showed mild hyperkeratosis, a normal granular layer and no significant parakeratosis (Fig. 2a). Electron microscopy of (i) affected acral skin demonstrated mild intracellular oedema, abundant keratohyaline granules in upper layers, with desmosomes and keratin filaments appearing intact and of (ii) affected upper back skin, vacuolar changes and disruption of suprabasal keratinocytes (Fig. 3). Whole exome sequencing directed at relevant epidermal genes revealed a novel heterozygous duplication mutation in the loricrin gene in exon 2 (designated c.806dupG), with an insertion of a

single base pair resulting in a frameshift leading to a delayed termination codon and elongation of the protein by 22 amino acids (Fig. 2d). The mutation was confirmed by Sanger sequencing (Methods S2; see Supporting Information) and was present in affected individuals but was not in unaffected family members (Figs 1a, 2b,c). This mutation is not on the dbSNP database or NHLBI Exome Variant Server (<http://evs.gs.washington.edu/EVS/>).

Six different heterozygous insertion mutations in loricrin in 14 unrelated pedigrees have previously been reported and one heterozygous deletion in a further pedi-



**Fig 2.** (a) A biopsy from the proband's mother's skin showing mild hyperkeratosis, a normal granular layer and no significant parakeratosis (original magnification  $\times 20$ ). (b–d) Mutation analysis. (b) Normal loricrin sequence in exon 2, showing nucleotides 799–813 (codons 267–271). (c) The equivalent region as in (b) from the proband showing the heterozygous mutation c.806dupG, leading to a delayed termination codon and a mutant protein 22 amino acids longer than wild-type. (d) Nucleotide sequence at the 5' end of loricrin. The inserted G nucleotide is in bold and indicated with an arrow. The predicted amino acid sequences of the wild-type and mutant (underlined) alleles are shown.



**Fig 3.** Semithin sections and ultrastructural images. In semithin sections (a) there was epidermal acanthosis and compact hyperkeratosis with a pattern of diffuse vacuolar change. These vacuoles (small arrows) were predominantly observed in the suprabasal keratinocyte layers. Suprabasal layer keratinocytes also showed focal cytolytic changes and some cells appeared necrotic. (b) Ultrastructurally there was disruption to the normal keratin filament network within suprabasal keratinocytes concurrent with the presence of peri-nuclear, membrane-bound vacuoles (V), some containing granular material. At higher magnification (c), keratin filament networks (K) were disturbed or showed some clumping particularly around the nucleus (N). Desmosome connections between keratinocytes mostly appeared normal, although there were small detached desmosomes (D) with disrupted keratin filament (K) association in some areas together with a slight widening of intercellular spaces between adjacent keratinocytes and some granular debris (G) present within the intercellular spaces. Scale bars 50 µm (a), 5 µm (b) and 500 nm (c).

gree<sup>2,4-6,8,9,11-13</sup> (see Supporting Information; Table S1). All six insertion mutations are single base-pair insertions leading to delayed termination codons with the most frequent mutation 730insG being present in eight of the 14 published families.<sup>2,4,8-13</sup> This region of the loricrin gene is thought to be a mutation hotspot because of the presence of six consecutive guanine nucleotides.<sup>12</sup> All

single-base-pair insertion and deletion mutations lead to a frameshift and delayed termination, thus elongating the protein by 22 amino acids and changing the Gly-Lys-rich domain into an Arg-Leu-rich terminal domain,<sup>2</sup> except for two pedigrees of Brazilian origin, where the new protein is 25 amino acids longer than wild-type protein.<sup>5</sup> The mechanism of action of these mutations is thought to relate to preferential localization of mutant loricrin in the nucleus due to the formation of nuclear localization sequences within the arginine-rich mutant loricrin.<sup>14</sup> It has been suggested that the abnormal nuclear protein may disrupt the apoptotic process in terminal differentiation of keratinocytes in mouse models, thus supporting the hypothesis that the phenotype of loricrin keratoderma is caused by the synthesis of mutant loricrin rather than by the lack of wild-type loricrin.<sup>14,15</sup> No clear genotype-phenotype associations for pedigrees with specific mutations have currently been identified.<sup>4,5,13</sup>

The phenotype of loricrin keratoderma is heterogeneous. The common clinical features in both the 15 previously reported pedigrees and our new pedigree are palmoplantar keratoderma, usually of a honeycomb pattern, and generalized ichthyosis. Other features, including knuckle pads, pseudoainhum/hyperconstricting bands with autoamputation of digits and collodion babies, are variably reported. Previously, Gedicke *et al.*<sup>13</sup> have suggested that the term 'mutilating keratoderma with ichthyosis' is not entirely suitable, due to the variation in phenotypes previously reported. Similarly, given the prominence of generalized ichthyosis with lesser palmoplantar involvement in this pedigree, and the presence of generalized ichthyosis in all previously reported pedigrees, we suggest that the condition could be described as loricrin ichthyosis rather than loricrin keratoderma.

## Acknowledgments

We would like to thank the patients, their family members and control subjects for their cooperation in this study.

<sup>1</sup>Centre for Dermatology and Genetic Medicine, Colleges of Life Sciences and Medicine, Dentistry and Nursing and  
<sup>3</sup>Division of Computational Biology, College of Life Sciences, University of Dundee, U.K.  
<sup>2</sup>Department of Dermatology, University Hospital Crosshouse, Kilmarnock Road, Kilmarnock KA2 0BE, U.K.  
<sup>4</sup>Department of Pathology and <sup>7</sup>Alan Lyell Centre for Dermatology, Southern General Hospital, Glasgow, U.K.  
<sup>5</sup>EB Laboratory, Viapath LLP, St Thomas' Hospital, London Group, King's College London (Guy's Campus), U.K.  
<sup>6</sup>Department of Cell Pathology, St John's

E. POHLER<sup>1</sup>  
 F. CUNNINGHAM<sup>2</sup>  
 A. SANDILANDS<sup>1</sup>  
 C. COLE<sup>3</sup>  
 S. DIGBY<sup>4</sup>  
 J.R. McMILLAN<sup>5</sup>  
 S. ARISTODEMOU<sup>5</sup>  
 J.A. McGRATH<sup>6</sup>  
 F.J.D. SMITH<sup>1</sup>  
 W.H.I. McLEAN<sup>1</sup>  
 C.S. MUNRO<sup>7</sup>  
 M. ZAMIRI<sup>2,7</sup>

Institute of Dermatology, St. Thomas' Hospital, London, U.K.

Correspondence: Fiona Cunningham.

E-mail: fionajcunningham@gmail.com

## References

- 1 Camisa C, Rosanna C. Variant of keratoderma hereditaria mutilans (Vohwinkel's syndrome). Treatment with orally administered isotretinoin. *Arch Dermatol* 1984; **120**:1323–8.
- 2 Maestrini E, Monaco AP, McGrath JA et al. A molecular defect in lorcrin, the major component of the cornified cell envelope, underlies Vohwinkel's syndrome. *Nat Genet* 1996; **13**:70–7.
- 3 Ishida-Yamamoto A, Kato H, Kiyama H et al. Mutant lorcrin is not crosslinked into the cornified cell envelope but is translocated into the nucleus in lorcrin keratoderma. *J Invest Dermatol*. 2000; **115**:1088–94.
- 4 Yeh JM, Yang MH, Chao SC. Collodion baby and lorcrin keratoderma: a case report and mutation analysis. *Clin Exp Dermatol* 2013; **38**:147–50.
- 5 Hotz A, Bourrat E, Hausser I et al. Two novel mutations in the LOR gene in three families with lorcrin keratoderma. *Br J Dermatol* 2014; **172**:1158–62.
- 6 Kinsler VA, Drury S, Khan A et al. Novel microdeletion in LOR causing autosomal dominant lorcrin keratoderma. *Br J Dermatol* 2015; **172**:262–4.
- 7 Hayat MA. Rinsing, dehydrating and embedding. In: *Principles and Techniques of Electron Microscopy: Biological Applications*, 3rd edn. Basingstoke: Macmillan Press, 1989; 79–137.
- 8 Korge BP, Ishida-Yamamoto A, Punter C et al. Lorcrin mutation in Vohwinkel's keratoderma is unique to the variant with ichthyosis. *J Invest Dermatol* 1997; **109**:604–10.
- 9 O'Driscoll J, Muston GC, McGrath JA et al. A recurrent mutation in the lorcrin gene underlies the ichthyotic variant of Vohwinkel syndrome. *Clin Exp Dermatol* 2002; **27**:243–6.
- 10 Matsumoto K, Muto M, Sekin S et al. Lorcrin keratoderma: a cause of congenital ichthyosiform erythroderma and collodion baby. *Br J Dermatol* 2001; **145**:657–60.
- 11 Takahashi H, Ishida-Yamamoto A, Kishi A et al. Lorcrin gene mutation in a Japanese patient of Vohwinkel syndrome. *J Dermatol Sci* 1999; **19**:44–7.
- 12 Drera B, Tadini F, Balbo G et al. De novo occurrence of the 730insG recurrent mutation in an Italian family with the ichthyotic variant of Vohwinkel syndrome, lorcrin keratoderma. *Clin Genet* 2008; **73**:85–8.
- 13 Gedicke MM, Traupe H, Fischer B et al. Towards characterization of palmoplantar keratoderma caused by gain-of-function mutation in lorcrin: analysis of a family and review of the literature. *Br J Dermatol* 2006; **154**:167–71.
- 14 Ishida-Yamamoto A. Lorcrin keratoderma: a novel disease entity characterized by nuclear accumulation of mutant lorcrin. *J Dermatol Sci* 2003; **31**:3–8.
- 15 Suga Y, Jarnik M, Attar PS et al. Transgenic mice expressing a mutant form of lorcrin reveal the molecular basis of the skin diseases, Vohwinkel syndrome and progressive symmetric erythrokeratoderma. *J Cell Biol* 2000; **151**:401–12.

Funding sources: The Centre for Dermatology and Genetic Medicine at the University of Dundee is supported by a Wellcome Trust Strategic Award (098439/Z/12/Z to W.H.I.M. and J.A.M). This work was also supported by a Wellcome Trust Programme Grant (092530/Z/10/Z to W.H.I.M.) and by a grant from the Pachyonychia Congenita Project (to FJDS, www.pachyonychia.org).

Conflicts of interest: None.

## Supporting Information

Additional Supporting Information may be found in the online version of this article at the publisher's website:

**Methods S1.** Whole exome sequencing.

**Methods S2.** Confirmation of mutation in exon 2 by Sanger sequencing

**Table S1.** Clinical features of families with lorcrin keratoderma.