

Left juxtaposition of the auricles with l-position of the aorta

Report of 6 cases

S. P. ALLWORK, A. E. URBAN,¹ AND R. H. ANDERSON²

From the Department of Surgery, Royal Postgraduate Medical School; Thoracic Unit, Hospital for Sick Children, Great Ormond Street; and Department of Paediatrics, Cardiothoracic Institute, Brompton Hospital, London

Six hearts are described in which juxtaposition of the auricles to the left of the great arteries (left juxtaposition) was associated with l-position of the aorta. Atrial anatomy was abnormal but constant; the os of the right auricle occupied the expected site of the atrial septum, producing posterior and inferior displacement of this structure. This is of importance since the os could be mistaken for a defect of the atrial septum, while the displacement of actual defects is of significance to any intended catheterisation procedure including atrial septostomy. Five of the hearts showed atrioventricular concordance while the other specimen was an example of primitive ventricle with a right-sided outlet chamber. The ventriculoarterial connection in this latter case was normal, with l-malposition (anatomically corrected malposition). Ventriculoarterial connections in the other hearts were transposition in 3, single aortic trunk with pulmonary atresia in 1, and an intermediate between double outlet right ventricle and transposition in the other. These cases confirm the observation that juxtaposition of the auricles is associated with severe cyanotic congenital heart disease.

In the normal heart the auricular appendages (auricles) extend forwards from the atria to encircle the origin of the aorta and pulmonary artery. The uncommon condition in which the auricles lie side by side, either to the left or the right of the great arteries, has been well recognised since the description of a single case by Birmingham (1893). This anatomical arrangement was called juxtaposition of the atrial appendages by Dixon (1954) and is well known to be associated with major intracardiac anomalies with cyanosis, particularly when the right auricle is juxtaposed to the left (Melhuish and Van Praagh, 1968).

Six hearts with left juxtaposition of the auricles are described, in each of which the aortic valve is situated to the left of the pulmonary valve in situs solitus individuals with atrioventricular concordance. The hearts show a range of malformations at ventricular and conal levels. The atrial anatomy, however, was in all cases relatively constant. As it has been shown that juxtaposition of the auricles

is readily identified radiologically (Ellis and Jameson, 1963), a thorough understanding of the likely accompanying defects may facilitate treatment.

The cases

The 6 hearts were from the collections of necropsied material of the Royal Postgraduate Medical School, the Hospital for Sick Children, and the Cardiothoracic Institute, all in London (Table). All had been hospital patients. Cases 3 and 6 had undergone aorto-pulmonary arterial (Waterston) anastomosis, and case 5 had had an atrial baffle (Mustard) operation. The remaining 3 had had no operation. All 6 patients had died of causes related to their malformations. Their ages ranged from 5 days to 30 years.

Anatomical findings

All 6 specimens had situs solitus viscerio-atrial relations, and all had concordant atrioventricular connections. In each case the right auricle was to the left of the great arteries, so that it lay superior and slightly anterior to the left auricle (Fig. 1). The aorta

¹Present address: Johanniter-Kinderklinik für den Rhein-Sieg-Kreis, Arnold-Janssen-Strasse 29, 5205 Sankt Augustin 1, W. Germany.

²British Heart Foundation Senior Research Fellow.

Received for publication 28 September 1976

Table Anatomical findings in 6 patients with {S-D-L} segmental anatomy and left juxtaposition of auricles

No.	Age	Sex	Situs	Cardiac segments*	PFO	ASD I	ASD II	VSD	Origin of PA	RV	Origin of aorta	Conus	Pulmonary outflow tract obstruction
1	3/12	M	Solitus	S-D-L	+	0	0	Ant	RV-LV	N	RV	Aortic	0
2	16	F	Solitus	S-D-L	0	0	+	Post	LV	H	RV	Bilat	0
3	5d	F	Solitus	S-D-L	+	0	0	Ant	0	N	RV	Aortic	Atresia
4	30	F	Solitus	S-D-L	+	0	+	VBF	Outlet chamber	O-C	Ventricle	Bilat	0
5	4/12	M	Solitus	S-D-L	0	+	0	Ant	LV	H	RV	Aortic	AMS
6	3/12	M	Solitus	S-D-L	+	0	+	Post	LV	H	RV	Aortic	Fibrous

Abbreviations: A, aortic; Ant, anterior; AMS, aneurysm of membranous septum; ASD I, primum atrial septal defect; ASD II, secundum atrial septal defect; AV-SLV, atrioventricular valve—semilunar valve continuity; Bilat, bilateral; DORV, double outlet right ventricle; H, hypoplastic; LV, left ventricle; M, mitral; N, normal; O-C, outlet chamber; P, pulmonary; PA, pulmonary artery; PDA, persistent ductus arteriosus; PFO, patent foramen ovale; Post, posterior; PS, pulmonary stenosis; RV, right ventricle; SVC, superior vena cava; T, tricuspid; TGA, transposition of great arteries; VBF, ventriculobulbar foramen.

*According to the classification of Melhuish and Van Praagh (1968).

in each case was anterior and to the left of the main pulmonary artery, so that the segmental anatomy for the whole group was {S-D-L} (Fig. 2). In specimens 1 and 6 the apex of the heart was directed to the right, and in the remaining 4, the apex was to the left.

ANATOMY OF ATRIA

Although the atria received their appropriate veins, the chambers were not normally related to one another. The left atrium was posterior to the right atrium, as is usual, but the right atrium, instead of forming the right border of the heart, was immediately anterior to the left. The position and relations of the left atrium and its auricle were not deranged by juxtaposition of the right auricle. The right auricle in all cases was displaced behind the great arteries, the atrium itself remaining as a right-sided chamber. The os of the right auricle was anterior to the crista terminalis, so that at first sight it resembled a defect of the atrial septum. Defects of the atrial septum were situated posteriorly in the chamber (Fig. 3).

In heart 1, the superior vena cava entered the right atrium more inferiorly than is usual, and the foramen ovale was patent. The atrium in heart 2 received the superior and inferior venae cavae in the normal manner, and there was a large persistent left superior vena cava (Fig. 2) in addition to a channel resembling the normal coronary sinus, which received the great cardiac vein. There was a secundum defect of the atrial septum, 29 mm in diameter. Indeed, in this heart, the septum primum was represented only by a rim of tissue, 2 mm high, on the inferior aspect of the defect. Heart 3 had a

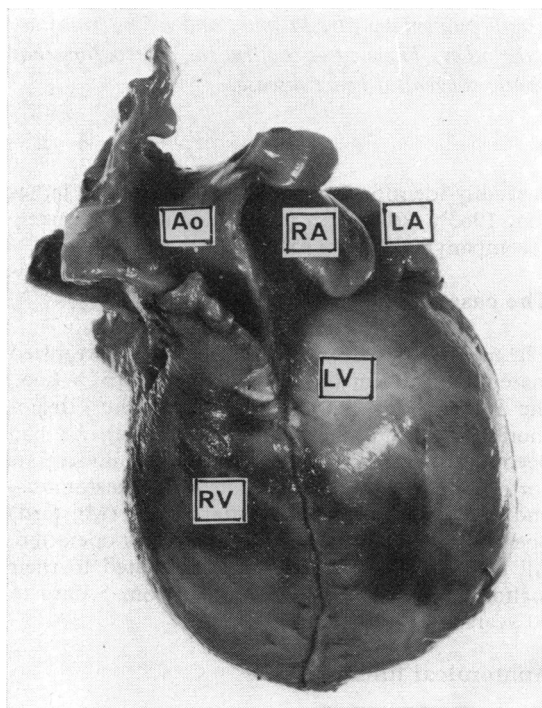


Fig. 1 Case 3. The right auricle (RA) is to the left of the great arteries, and lies anterior and slightly superior to the left auricle (LA). The aorta (Ao) is anterior and to the left of the atretic pulmonary artery. (RV=right ventricle; LV=left ventricle.)

in this heart, constituted a communication between the right auricle and the left atrium.

ANATOMY OF VENTRICLES

All the specimens except heart 4 had two identifiable ventricular chambers. Two atrioventricular valves were recognised in each case, and all the hearts had ventricular septal defects which permitted intra-cardiac shunting.

In heart 1, the ventricular septal defect (14 × 10 mm) was high in the anterior ventricular septum; the trabecula septomarginalis formed its floor and the defect extended posteriorly to the atrioventricular valves which made contact through its posterior margin. Both aortic and pulmonary valves were related to the defect, the pulmonary valve exactly overriding the septum (Fig. 4).

Heart 2 had a dysplastic tricuspid valve, right ventricle, and aorta. The ventricular septal defect occupied the posterior septum and was subpulmonary (Fig. 5). Its topography resembled an endocardial cushion defect, so that the tricuspid valve marked the superior boundary. The tricuspid and mitral valves were in continuity through the defect.

In heart 3 the ventricles were of equal size. The defect, 10 × 10 mm, lay immediately beneath the aortic valve, anterior to the septomarginal trabecula (Fig. 6). There was no pulmonary valve.

In heart 4 (Fig. 7A), both atrioventricular valves opened into a primitive ventricle. The aorta arose from the ventricle, and the pulmonary artery originated from a bulbar (outflow) chamber which communicated with the primitive ventricle through a ventriculobulbar foramen (Fig. 7B).

AV-SLV continuity	Coronary arteries	Additional data	Anatomical diagnosis
P-M-T	TGA	Apex of heart to right	Transitional DORV-TGA without PS
None	Single	Left SVC	TGA; hypoplastic RV
None	TGA	PDA	Solitary aortic trunk
None	Single	0	Primitive ventricle; anatomically corrected malposition
P-M-T	TGA	PDA	TGA; subpulmonary stenosis resulting from AMS; hypoplastic RV
P-A-T-M	TGA	PDA; apex of heart to right	TGA; valvar and subvalvar pulmonary stenosis; hypoplastic RV

stretched superior foramen ovale. Heart 4, which weighed 870 g, had 2 secundum defects; the larger, in the inferoanterior portion of the septum primum measured 40 × 25 mm, and the smaller defect, in the superior posterior septum, measured 6 mm in diameter. Heart 5 had an endocardial cushion defect, the atrial component of which was large; accurate assessment of its size was not possible because of the surgically placed baffle. Heart 6 had a superior foramen ovale. In this heart the atrial septum lay in a more oblique plane, so that it more closely resembled the normal atrial septum than in the other 5 cases. The foramen ovale was patent superiorly, and because of the orientation of the atrial septum

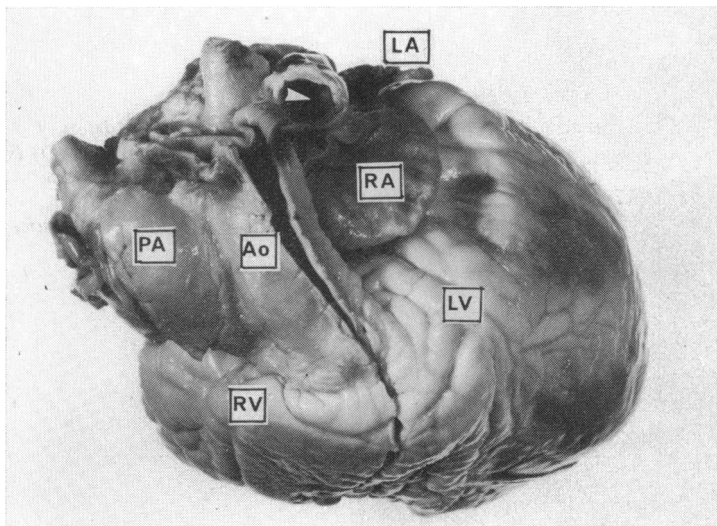


Fig. 2 Case 2. The aorta (Ao) arises from the right ventricle (RV) and is placed anteriorly and to the left of the pulmonary artery (PA). LA=left auricle; LV=left ventricle. The persistent left superior vena cava is arrowed in white.

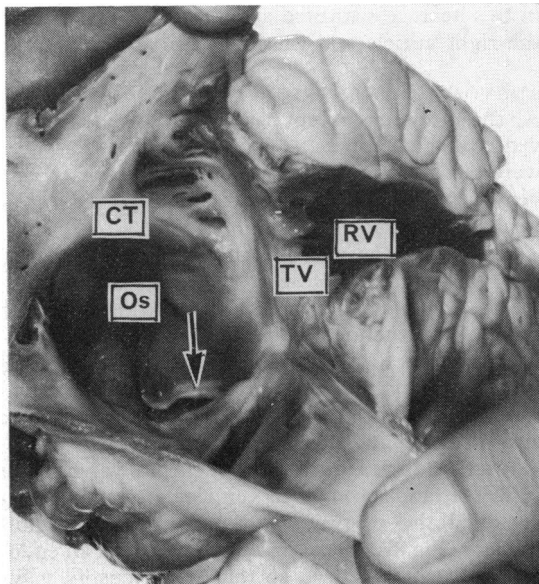


Fig. 3 Case 2. The right atrium and right ventricle (RV) are hypoplastic. The septum primum (arrowed) is seen as a rim of tissue 2 mm in depth. The os of the right auricle (Os) appears at first sight to be a defect of the atrial septum. CT=crista terminalis; TV=tricuspid valve.

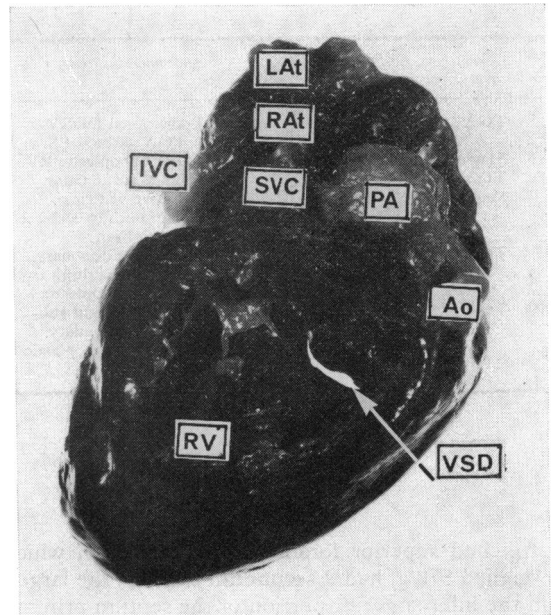


Fig. 4 Case 1. This specimen is a waxed preparation, thus the photograph appears rather dark. The defect of the ventricular septum (VSD) is seen as a slit in this view, and the pulmonary artery (PA) overrides it. The aorta (Ao) arises wholly from the right ventricle (RV). The great arteries are equal in size. IVC=inferior vena cava; LAAt=left atrium; RAAt=right atrium; SVC=superior vena cava.

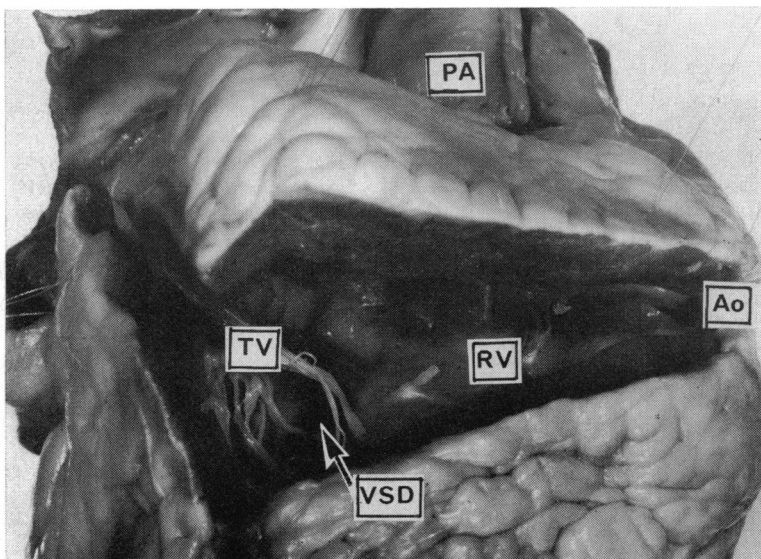


Fig. 5 Case 2. The defect of the ventricular septum (VSD) is posterior. The tricuspid valve (TV), right ventricle (RV), and aorta (Ao) are hypoplastic.

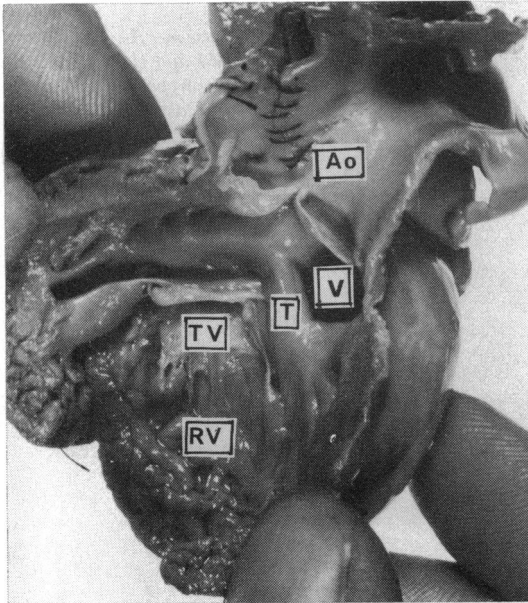


Fig. 6 Case 3. The defect of the ventricular septum (V) is anterior to the trabecula septomarginalis (T), and is subaortic. Other abbreviations as in previous figures.

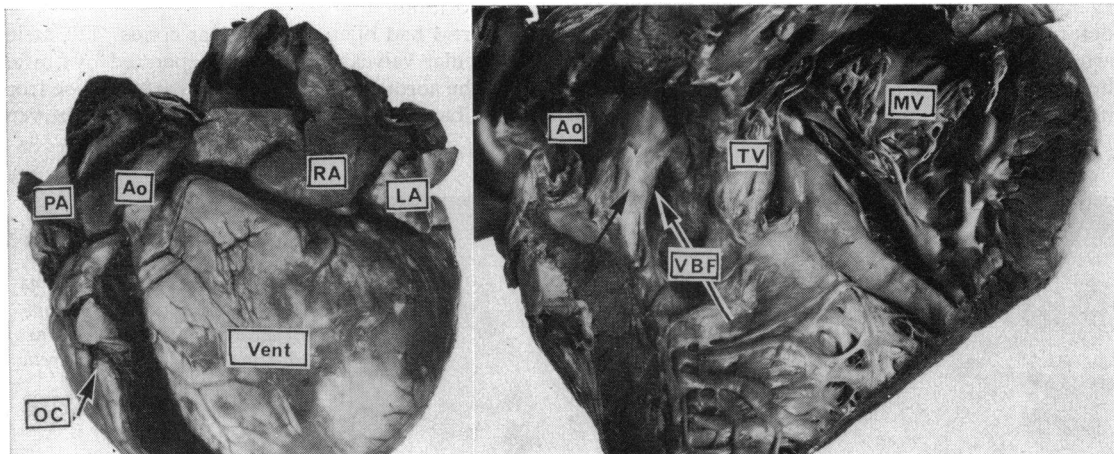
Heart 5 had hypoplasia of the tricuspid valve and the right ventricle. The ventricular septal defect was anterior to the trabecula septomarginalis and in the subaortic position (Fig. 8A and B).

Heart 6 also had a hypoplastic tricuspid valve and right ventricle, which was divided into discrete inflow and outflow portions by anomalous muscle bands. The defect in this specimen was midseptal, lying beneath the pulmonary outflow tract, but extended to the posterior ventricular septum (Fig. 9A and B).

ANATOMY OF CONUS

Ventriculoarterial connections were abnormal in all 6 specimens, and the conal anatomy differed widely. In heart 1, the aorta arose from a muscular conus in the right ventricle. The pulmonary artery, separated from the aorta by the conus septum, overrode the ventricular septal defect so that the pulmonary valve was in fibrous continuity through the defect with both the atrioventricular valves. The ventriculoarterial connection was transitional between that of double outlet right ventricle and transposition.

In heart 2, the aorta arose from a muscular right ventricular conus. The pulmonary artery arose ex-



(A)

(B)

Fig. 7 Case 4. (A) Showing the juxtaposed auricles (RA, LA). The great arteries (PA, Ao) are equal in size. The wall of the right atrium is hypertrophied. OC=outlet chamber; Vent=ventricle. (B) The ventricular morphology of this heart is that of primitive (single) ventricle with an outlet chamber. The illustration shows the primitive ventricle from which the aorta (Ao) arises, the ventriculobulbar foramen (VBF), and the two atrioventricular valves (TV, MV). The pulmonary artery is not seen, but arises from the outlet chamber. There are numerous patches of fibrosis ('jet lesions') especially on the bulbar septum (arrowed in black). In this heart, therefore, the great arteries are normally connected, but show l-malposition (anatomically corrected malposition). Note that both the tricuspid and mitral valves open to the primitive ventricular chamber, and are separated by a prominent posterior ridge. Note also that the aortic valve is supported by a complete muscular conus.

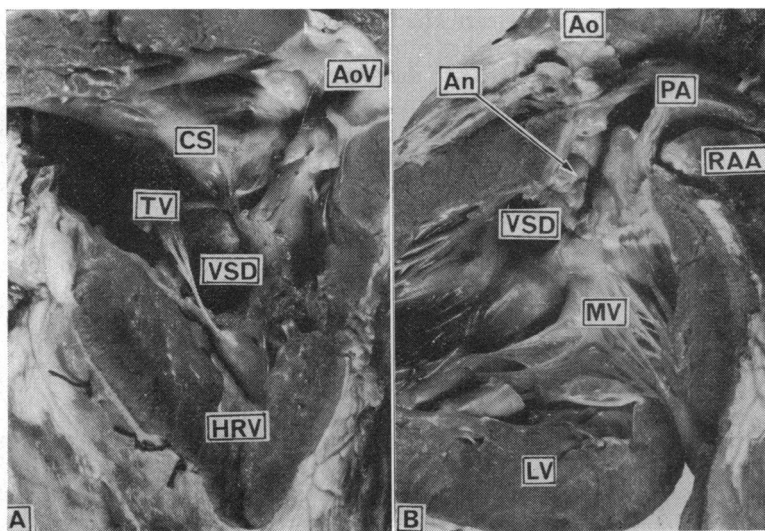


Fig. 8 Case 5. (A) The tricuspid valve (TV) and right ventricle (HRV) are hypoplastic. This child had an atrioventricular canal, the ventricular component of which (VSD) is anterior to the trabecula septomarginalis, and subaortic. AoV=aortic valve; CS=conus septum. (B) The left side of the heart of case 5. The right auricle (RAA) is seen to the left of the pulmonary artery (PA). The mitral (MV) and pulmonary valves are in fibrous continuity. The membranous septum is aneurysmal (An) and causes a degree of obstruction to the pulmonary outflow tract. LV=left ventricle.

clusively from the left ventricle, but was dissociated from the mitral valve by a slender muscle slip, not more than 2 mm in width; this muscle slip extended from the left ventricle into the posterior conus septum, so that neither the aortic nor the pulmonary valve was in fibrous continuity with either atrioventricular valve. The atrioventricular valves, however, were continuous with one another through the defect in the ventricular septum. The ventriculoarterial connection was that of transposition. In heart 3, the aorta arose from a muscular conus, immediately above the septal defect. The atric

pulmonary artery was represented by a thread of tissue and did not make contact with either ventricle. There was thus no fibrous continuity with either atrioventricular valve. Since we were unable to identify the origin of the pulmonary artery, the ventriculoarterial connection was described as single aortic trunk arising from the right ventricle with l-malposition.

Heart 4 had bilateral muscular conus. The atrioventricular valves were widely separated by muscle from the aorta, and the pulmonary artery arose from the bulbar (outflow) chamber. In this heart the ven-

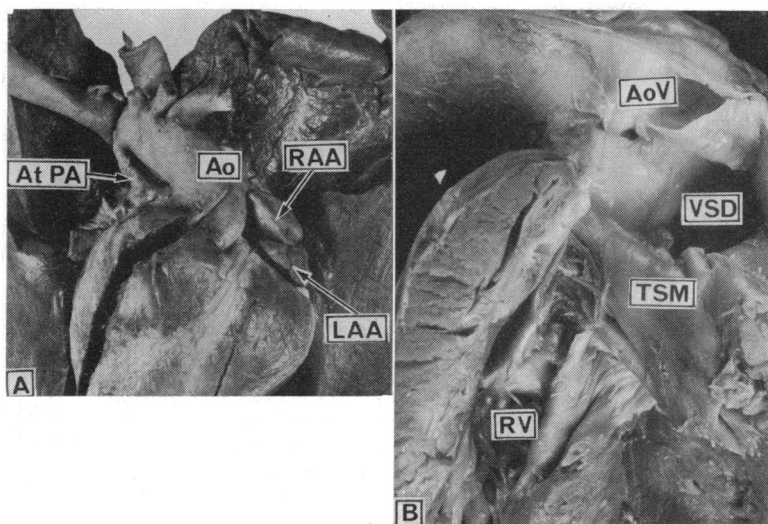


Fig. 9 Case 6. (A) The apex of the heart is directed to the right. The right auricle (RAA) lies superior and anterior to the left auricle (LAA). The aorta (Ao) is to the left of the atretic pulmonary artery (At PA). (B) The right ventricle (RV) in heart 6. The chamber is divided by anomalous muscle bands into discrete inflow and outflow portions. The ventricular septal defect (VSD) is midseptal, superior to the trabecula septomarginalis (TSM), and extends to the posterior part of the ventricular septum. AoV=aortic valve.

triculoarterial connections were normal but l-malposition was present; this is usually termed 'anatomically corrected malposition'.

Heart 5 had a subaortic conus only, and the pulmonary valve arising from the left ventricle was in fibrous continuity with both atrioventricular valves. The ventriculoarterial connection was that of transposition. In heart 6 there was continuity between the aortic and pulmonary valves, resulting from the defect in the conus septum, and fibrous subpulmonary obstruction permitted continuity with the mitral and tricuspid valves. The muscular conus, however, was subaortic. The ventriculoarterial connection was that of transposition.

OBSTRUCTION TO PULMONARY OUTFLOW TRACT

One of the 6 patients (case 3) had atresia of the pulmonary artery. The main pulmonary artery was represented by a thread-like structure which made no connection with either ventricle, nor was a pulmonary valve present in either ventricle.

Pulmonary outflow tract obstruction was present in hearts 5 and 6. In heart 5, the left ventricular outflow tract was obstructed by an aneurysmal partly formed membranous septum (Fig. 9B), but the pulmonary valve was not stenotic. Heart 6 had an imperforate, small pulmonary valve deeply wedged between the two atrioventricular valves. Additional obstruction was caused by fibrosis and fibrous excrescences of the inferior portion of the conus septum which was displaced posteriorly; these excrescences resembled valve tissue.

DISTRIBUTION OF CORONARY ARTERIES

Hearts 1, 3, 5, and 6 all had a coronary artery distribution consistent with concordant transposition in situs solitus. The non-coronary sinus of the aortic valve was anteromedial, and the anterior descending and circumflex arteries arose from a common artery from the posterolateral aortic sinus. The anterior descending artery followed the interventricular sulcus, giving off septal and muscular branches, and the circumflex coronary artery arose from the main stem to pass posteriorly in the left atrioventricular groove. The right coronary artery originated from an ostium in the posteromedial aortic sinus, and followed the right atrioventricular groove; numerous conal branches arose from the right coronary artery which terminated as the posterior descending coronary artery.

Hearts 2 and 4 both had a single coronary artery arising from an ostium in the anteromedial aortic sinus. The distribution of the artery was identical in the two hearts, except for some small marginal branches. The coronary artery bifurcated about

1 cm from its origin to give rise to a large artery which lay in the right atrioventricular groove; a number of marginal and diagonal arteries arose from it and the artery terminated as a posterior descending artery on the diaphragmatic surface of the heart. The smaller, left hand branch of the single coronary artery had the appearance of a large conal coronary artery and gave origin to a slender branch in the left atrioventricular groove; the conal portion of the artery divided into numerous small branches which fanned widely over the left ventricle.

Discussion

The anatomical features of 6 hearts with left juxtaposition of the auricles and l-position of the aorta have been described. In addition to these common features, situs solitus and atrioventricular concordance were present in each case. The atrial anatomy was relatively constant, but the hearts showed considerable variation in ventricular and conal anatomy.

ATRIAL ANATOMY IN LEFT JUXTAPOSITION OF AURICLES

Both systemic and pulmonary venous drainage was normal in all 6 hearts; in case 2, the persistent left superior vena cava opened into the right atrium. The unusual feature of this case with left superior vena cava was that a great cardiac vein resembling a 'coronary sinus' also drained into the right atrium. The coronary sinus is the original left sinus horn, and the left superior vena cava normally regresses, persisting as the oblique vein of Marshall. The posterior great cardiac vein normally drains into the left sinus horn. In heart 2 both the left sinus horn and the great cardiac vein were present as separate channels. This finding was noted in 4 of 28 cases of left juxtaposition reviewed by Puech *et al.* (1966) who added one in their series of 3 cases. Melhuish and Van Praagh (1968) noted the same feature in 2 of 21 cases of juxtaposition of the auricles, and Rosenquist *et al.* (1974) described it in one of 6 hearts with left auricular juxtaposition.

An interatrial communication was present in all 6 hearts, and, where this communication was the result of patency of the foramen ovale, this patency occurred in the superior aspect of the fossa ovalis. Rashkind septostomy had been attempted in case 6, but was unsuccessful. The plane of the atrial septum and the anatomy of the fossa ovalis in this condition makes septostomy difficult. This procedure has failed even when the juxtaposition was recognised (Tyrrell and Moes, 1971). We suggest, on anatomical premises, that balloon septostomy may be practicable in this condition if the tip of the catheter

is directed superiorly as well as posteriorly, as the valve of the foramen ovale is a superior structure in left juxtaposition of the auricles.

L-POSITION OF AORTA

The majority of hearts with left juxtaposition of the auricles exhibit d-position of the aorta {S-D-D} (Melhuish and Van Praagh, 1968) but a significant proportion have l-position of the aorta. {S-D-L} segmental anatomy has been reported in association with left juxtaposition by Melhuish and Van Praagh (1968), Wagner *et al.* (1970), Charuzi *et al.* (1973), and Lincoln *et al.* (1975). From the published reports, together with our series, {S-D-L} segmental anatomy appears to be present in about 30 per cent of cases with left juxtaposition.

Three of the 6 hearts (2, 5, and 6) showed complete l-transposition (solitus-concordance-l-transposition). An anterior, subaortic ventricular septal defect was present in heart 5, and all 3 had hypoplasia of the tricuspid valve, the right ventricle, and the aorta.

Heart 1 represented a transitional stage between double outlet right ventricle and complete transposition. If double outlet ventricle is defined as that condition in which $1\frac{1}{2}$ great arteries or more arise from the same ventricle (Lev *et al.*, 1972), this heart arbitrarily could be placed into either category. Transitional hearts have been described by Lev *et al.* (1972) and Anderson *et al.* (1974), but we are unaware of another report of association with left juxtaposition. If this heart, without pulmonary stenosis, is classified as double outlet right ventricle with {S-D-L} segmental anatomy, this is the ninth such case described, others having been reported by Hallermann *et al.* (1970), de la Cruz *et al.* (1974), and Van Praagh *et al.* (1975a, b).

Heart 3 had pulmonary atresia, but the ventricular origin of the pulmonary artery could not be identified so that it was not appropriate to classify this as a case of transposition. We strongly support the view of Van Praagh *et al.* (1971) that for transposition to exist, both great arteries must be placed across the ventricular septum to originate from morphologically inappropriate ventricles. Where only one great artery is present, it is unrewarding to speculate on the ventricular origin of the other.

Heart 4 showed anatomically corrected malposition associated with a primitive ventricle. Anatomically corrected malposition is rare, and has not, as far as we are aware, been reported previously in association with a primitive ventricle. Freedom and Harrington (1974) reviewed 13 cases of anatomically corrected malposition of which 7 had left juxtaposition of the atrial appendages, and Anderson *et al.* (1974b) described 4 cases, of which 2 had

juxtaposition. Of these 4, 3 had a single coronary artery with identical distribution to that of the present case.

SURGICAL IMPLICATIONS

The coexistence of {S-D-L} cardiac segmental anatomy with cyanotic congenital heart disease does not preclude surgical treatment (Van Praagh *et al.*, 1975a, b), but the variations in anatomy at both ventricular and conal levels necessitate careful assessment of the intracardiac arrangements.

The 3 hearts in the present series with transposition all had hypoplastic right ventricles. A Mustard operation had been performed in case 5, but the patch had narrowed the already small tricuspid valve; the defect of the posterior ventricular septum was patent, and there was considerable obstruction to the outflow tract of the left ventricle. The implications of juxtaposition in relation to Mustard's operation have recently been discussed in detail by Rosenquist *et al.* (1974) and Urban *et al.* (1976). Heart 6 also had subpulmonary obstruction, while case 2, with a subpulmonary ventricular septal defect, had severe pulmonary vascular disease.

Hearts 2 and 4 each had a single coronary artery, the distribution of which could prejudice surgical incision in such hearts. We support the view that opacification of the coronary arteries in patients with l-position of the aorta is a valuable aid to the determination of ventricular morphology, as the coronary arteries have the distribution appropriate to their ventricles (Van Praagh *et al.*, 1975b; Allwork *et al.*, 1976).

EMBRYOLOGICAL CONSIDERATIONS

The genesis of the ventricular and conal abnormalities described here has been discussed extensively in recent years (Van Mierop *et al.*, 1963; Van Mierop and Wigglesworth, 1963; Van Mierop, 1971; Van Praagh, 1971; Anderson *et al.*, 1974; Allwork, 1975, 1976), but the reports concerning the atrial anomalies are less numerous. In particular, the morphogenesis of juxtaposition of the auricles is obscure.

Wenner (1909) considered that juxtaposition of the auricles resulted from 'insufficient torsion' of the primitive heart tube. Dixon (1954) accepted this 'explanation' as did Los (1968). Melhuish and Van Praagh (1968) proposed that the condition was mainly the result of an arrest of normal development, and that juxtaposition was an effect, rather than a cause. While our findings are in accord with those of the last-named authors with respect to the range of ventricular and conal anomalies associated with juxtaposition, we are unable to accept that the *auricles* are ever juxtaposed in normal development.

The auricles of the atria are trabeculated muscular structures, macroscopically quite distinct from the smooth walled segments. The auricles are derivatives of the primitive atrium, which at 20 days of gestational age is a single chamber, and part of the primitive heart tube. The smooth walled segments of the definitive atria are derived from the primitive sinus venosus and the pulmonary veins (Boyd, 1965). The primitive sinus venosus receives bilaterally both the vitelline and umbilical veins, together with the common cardinal vein. It is incorporated into the primitive atrium to form a single chamber at about 25 days of gestational age (Boyd, 1965; Hamilton and Mossman, 1972). This common chamber then expands ventrally (anteriorly) and transversely, so that in normal development, the atrium is well seen on either side of the bulbus cordis, by which it is indented. The ventro- (antero-) lateral extremities of the primitive atrium differentiate into the characteristic left and right auricles.

At about 26 days of gestation, the primitive atrium, still a single chamber, opens into the primitive ventricle. The only route for the circulation is from the atrium to the ventricle, through the ventriculobulbar foramen to the bulbar chamber thence to the septating outflow tract. From this account, it is clear that the route from atrium to ventricle is left sided, but we are unaware of any description of normal development which suggests that the extremities of the atria are both left sided.

In normal development the atrioventricular canal gains direct access to the bulbus cordis by a lateral expansion, and the primitive atrioventricular canal is divided into the left and right atrioventricular canals (the future atrioventricular valve orifices) by the endocardial cushions (Boyd, 1965; Los, 1968; Hamilton and Mossman, 1972; Anderson and Ashley, 1974). The immediate cause of the lateral expansion of the atrioventricular canal is a controversial topic but there is general agreement that the process is bound up with the expansion of the elements which will contribute to the definitive right ventricle.

The obvious feature of the 6 hearts presently described is that, in general, the right side of the ventricular segment of the heart is underdeveloped (hearts 2, 4, 5, and 6). Specimen 4 represents an adult example of the route taken by the circulation in the fourth week of gestation. None of the explanations for the morphogenic processes which result in the anomalies described here is very satisfactory. If juxtaposition resulted merely from failure of the atrioventricular canal to expand to the right, the fairly frequent observation of {S-D-L} segmental anatomy (about 30% of cases) would be hard to explain, as would the relative frequency of

anterior defects of the ventricular septum. That rightwards expansion of the primitive atrioventricular canal *has* failed is self evident in view of the high incidence of underdevelopment of the right side of the heart. Hypoplasia of the right heart cannot by itself explain the fact that in 5 of our 6 cases the aorta originated in the right ventricle, nor can it explain the l-position of the aortic valve relative to the pulmonary valve in every case. It is possible that the abnormal atrial interrelation is the result of abnormal development *ab initio* of the venous end of the heart coupled with inadequate morphogenic movements. We suggest, therefore, that the developmental events leading to the formation of hearts such as the 6 described are a great deal more complex than has previously been considered.

We are grateful to Professor J. F. Goodwin, Dr. K. A. Hallidie-Smith, Dr. G. Katz, Mr. J. Stark, Dr. E. A. Shinebourne, and Dr. M. C. Joseph for permission to publish details of the patients previously under their care.

References

- Allwork, S. P. (1975). The embryological basis of congenital malformations of the outflow tracts of the human heart. M. Phil. Dissertation, University of London.
- Allwork, S. P. (1976). The morphogenesis of transposition of the great arteries 1875-1975. *European Journal of Cardiology*, **4**, 3-11.
- Allwork, S. P., Bentall, H. H., Becker, A. E., Cameron, A. H., Gerlis, L. M., Wilkinson, J. L., and Anderson, R. H. (1976). Congenitally corrected transposition; a morphological study of 32 cases. *American Journal of Cardiology*, **38**, 910-926.
- Anderson, R. H., and Ashley, G. T. (1974). Growth and development of the cardiovascular system. In *Scientific Foundations of Paediatrics*, p. 165. Ed. by J. A. Davis and J. Dobbins. Heinemann, London.
- Anderson, R. H., Wilkinson, J. L., Arnold, R., Becker, A. E., and Lubkiewicz, K. (1974). Morphogenesis of bulboventricular malformations. II. Observations on malformed hearts. *British Heart Journal*, **36**, 948-970.
- Birmingham, A. (1893). Extreme anomaly of the heart and great vessels. *Journal of Anatomy and Physiology*, **27**, 139-150.
- Boyd, J. D. (1965). The development of the heart. In *Handbook of Physiology—Circulation III*, p. 2511. American Physiology Society, Washington, D.C.
- Charuzi, Y., Spanos, P. K., Amplatz, K., and Edwards, J. E. (1973). Juxtaposition of the atrial appendages. *Circulation*, **47**, 620-627.
- De La Cruz, M. V., Amoedo, M., Rivera, F., and Attie, F. (1974). Arterioventricular relations and their classification. Two specimens of arterioventricular discordance and review of published reports. *British Heart Journal*, **36**, 539-553.
- Dixon, A. St. J. (1954). Juxtaposition of the atrial appendages. Two cases of an unusual congenital cardiac deformity. *British Heart Journal*, **16**, 153-164.
- Ellis, K., and Jameson, A. G. (1963). Congenital levoposition

- of the right atrial appendage. *American Journal of Roentgenology*, **89**, 984-988.
- Freedom, R. M., and Harrington, D. P. (1974). Anatomically corrected malposition of the great arteries. Report of 2 cases, one with congenital asplenia; frequent association with juxtaposition of atrial appendages. *British Heart Journal*, **36**, 207-215.
- Hallermann, F. J., Kincaid, O. W., Ritter, D. G., Ongley, P. A., and Titus, J. L. (1970). Angiocardiographic and anatomic findings in origin of both great arteries from the right ventricle. *American Journal of Roentgenology*, **109**, 51-66.
- Hamilton, W. J., and Mossman, H. W. (1972). *Human Embryology*, 4th ed., p. 228. Heffer, Cambridge.
- Lev, M., Bharati, S., Meng, C. C. L., Liberthson, R. R., Paul, M. H., and Idriss, F. (1972). A concept of double outlet right ventricle. *Journal of Thoracic and Cardiovascular Surgery*, **64**, 271-281.
- Lincoln, C., Anderson, R. H., Shinebourne, E. A., English, T. A., and Wilkinson, J. L. (1975). Double outlet right ventricle with l-malposition of the aorta. *British Heart Journal*, **37**, 453-463.
- Los, J. A. (1968). Embryology. In *Pediatric Cardiology*, p. 1. Ed. by Hamish Watson. Lloyd-Luke, London.
- Melhuish, B. P. P., and Van Praagh, R. (1968). Juxtaposition of the atrial appendages. A sign of severe cyanotic congenital heart disease. *British Heart Journal*, **30**, 269-284.
- Puech, P., Latour, H., Hertault, J., Grolleau, R., and Robert, M. (1966). La juxtaposition des auricules. A propos de 3 observations. *Archives des Maladies du Coeur et des Vaisseaux*, **59**, 239-262.
- Rosenquist, G. C., Stark, J., and Taylor, J. F. N. (1974). Anatomical relationships in transposition of the great arteries: juxtaposition of the atrial appendages. *Annals of Thoracic Surgery*, **18**, 456-461.
- Tyrell, M. J., and Moes, C. A. F. (1971). Congenital levo-position of the right atrial appendage: its relevance to balloon septostomy. *American Journal of Diseases of Children*, **121**, 508-510.
- Urban, A. E., Stark, J., and Waterston, D. J. (1976). Mustard's operation for transposition of the great arteries complicated by juxtaposition of atrial appendages. *Annals of Thoracic Surgery*, **21**, 304-310.
- Van Mierop, L. H. S. (1971). Transposition of the great arteries. I. Clarification or further confusion? *American Journal of Cardiology*, **28**, 735-738.
- Van Mierop, L. H. S., Alley, R. D., Kausel, H. W., and Stranahan, A. (1963). Pathogenesis of transposition complexes. II. Anomalies due to faulty transfer of the posterior great artery. *American Journal of Cardiology*, **12**, 226-232.
- Van Mierop, L. H. S., and Wigglesworth, F. W. (1963). Pathogenesis of transposition complexes. III. True transposition of the great vessels. *American Journal of Cardiology*, **12**, 233-239.
- Van Praagh, R. (1971). Transposition of the great arteries. II. Transposition clarified. *American Journal of Cardiology*, **28**, 739-741.
- Van Praagh, R., Durnin, R. E., Jockin, H., Wagner, H. R., Kornis, M., Garabedian, H., Ando, M., and Calder, A. L. (1975a). Anatomically corrected malposition of the great arteries {S-D-L}. *Circulation*, **51**, 20-31.
- Van Praagh, R., Pérez-Trevino, C., López-Cuellar, M., Baker, F. W., Zuberbuhler, J. R., Quero, M., Pérez, V. M., Moreno, F., and Van Praagh, S. (1971). Transposition of the great arteries with posterior aorta, anterior pulmonary artery, subpulmonary conus and fibrous continuity between aortic and atrioventricular valves. *American Journal of Cardiology*, **28**, 621-631.
- Van Praagh, R., Pérez-Trevino, C., Reynolds, J., Moes, C. A. F., Keith, J. D., Roy, D. L., Belcourt, C., Weinberg, P. M., and Parisi, L. F. (1975b). Double outlet right ventricle {S-D-L}, with subaortic ventricular septal defect and pulmonary stenosis. *American Journal of Cardiology*, **35**, 42-53.
- Wagner, H. R., Alday, L. E., and Vlad, P. (1970). Juxtaposition of the atrial appendages: a report of 6 necropsied cases. *Circulation*, **42**, 157-163.
- Wenner, O. (1909). Beiträge zur lehre der Herzmissbildungen. *Virchows Archiv für pathologische Anatomie und Physiologie*, **196**, 127-168.

Addendum

Since completing this report, S.P.A. has seen an example of right juxtaposition of the auricles. The patient was a girl of 15. The anatomical findings were situs solitus, common atrium, primitive ventricle with two atrioventricular valves (the left rather small). The aorta arose anteriorly from the main chamber, and a left sided outlet chamber, obstructed by muscle, gave rise to a small pulmonary artery. There were two coronary arteries. Operation to septate the ventricle and atrium and to enlarge the pulmonary outflow tract by a gusset was performed by Professor H. H. Bentall at Hammsmith Hospital in November. The girl has made an excellent recovery. With the exception of pulmonary outflow tract obstruction in this patient, the anatomy is essentially similar to that of heart 4 described above. The ventriculoarterial connection is that of normal connections with d-malposition. This finding of complex congenital malformations with abnormal position of the great arteries confirms the previous findings of Anderson *et al.* (1976) in right juxtaposition of the auricles.

Reference

- Anderson, R. H., Smith A., and Wilkinson, J. L. (1976). Right juxtaposition of the auricular appendages. *European Journal of Cardiology*, **4**, 495-503.

Requests for reprints to Miss S. P. Allwork, Department of Surgery, Royal Postgraduate Medical School, Du Cane Road, London W12 0HS.