

# Primary restrictive cardiomyopathy *Non-tropical endomyocardial fibrosis and hypereosinophilic heart disease*

C. Y. C. CHEW, G. M. ZIADY, M. J. RAPHAEL, M. NELLEN,  
AND C. M. OAKLEY

*From Departments of Medicine (Clinical Cardiology) and Diagnostic Radiology, The Royal Postgraduate Medical School, Hammersmith Hospital, Du Cane Road, London*

*Eleven patients with a restrictive cardiomyopathy are described. Seven of these had biventricular disease and in them the haemodynamic abnormality resembled that in constrictive pericarditis but the condition was distinguishable because of unequal involvement of the two ventricles, murmurs of atrioventricular valve regurgitation, or characteristic ventricular deformity on angiography. Two of these patients had eosinophilia with the clinical features of Löffler's endocarditis. In 4 patients the disease was apparently confined to the left ventricle; they were investigated on account of atypical chest pain, third heart sound, or abnormal electrocardiogram.*

*Simultaneous measurements of left ventricular pressure and volume throughout diastole were made in 3 patients and showed rapid but abruptly curtailed left ventricular filling. Transvenous endomyocardial biopsy in 2 patients showed fibrous tissue with collagen and irregular elastic fibrils. Surgical biopsy in 3 patients excluded pericardial constriction but was diagnostically unhelpful because of failure to obtain endocardium. Necropsy in one patient showed that the heart had features indistinguishable from tropical endomyocardial fibrosis.*

*It is suggested that the spectrum of ventricular abnormalities in these patients results from endomyocardial fibrosis of varying severity and probably of differing cause. This study has shown that 'tropical' endomyocardial fibrosis may occur outside the tropics and suggests that eosinophilia may play a leading role or associated part in the genesis of some cases.*

The early descriptions of heart muscle disease were based on clinical likeness. As it has become possible to investigate and define ventricular function with greater precision, the name given to the heart muscle disorder has described the disturbance of ventricular function and finds its counterpart in the pathological anatomy and histopathology (Goodwin and Oakley, 1972; Oakley, 1975).

In this study, we describe a clinically recognisable group of patients who share a diastolic abnormality of a type which is not seen in patients with other primary cardiomyopathies nor in rare specific disorders such as amyloid heart disease. We wish to reintroduce the term restrictive cardiomyopathy to describe this group which includes patients with the clinical syndrome of Löffler's eosinophilic endocarditis as well as patients with angiocardiographic and necropsy findings typical of tropical endomyocardial fibrosis.

Received for publication 8 December 1976

## Patients

Eleven patients were studied over a 3-year period between July 1972 and July 1975. We have not included a larger number of clinically similar patients, seen by us before or after this but not personally studied.

These were 7 men and 4 women whose ages ranged between 20 and 58 years (Table 1). Seven were white and had not lived in the tropics. The 4 exceptions were an Iranian woman (case 4), a Sudanese man (case 8), a Saudi Arabian man (case 7), and a West Indian man (case 5) who had lived in this country for most of his life.

## CLINICAL FEATURES (TABLE 1)

Five of the patients (cases 1, 2, 3, 4, and 5) presented with features of predominant right heart failure with little or no cardiomegaly, resembling constrictive pericarditis. Case 1 with atypical chest

Table 1 *Clinical, radiographic, and electrocardiographic data*

Case No.	Sex and age (y)	Duration of symptoms (y)	Presenting symptoms	Clinical signs							
				JVP	Rhythm	S3	S4	Murmurs	Oedema	Ascites	Hepatomegal.
1	F 46	8	Atypical chest pain; recent effort dyspnoea	++	SR with intermittent atrial arrhythmias	+	0	0	+	0	+
2	F 35	1	Abdominal swelling	+++	SR	+	0	Soft apical systolic murmur	0	+++	++
3	F 45	1	Dyspnoea and oedema; vague chest pain	+++	SR	+	+	0	+	+	++
4	F 37	2	Dyspnoea; oedema	++	SR	+	0	0	+	+	++
5	M 32	1	Intermittent claudication	++	SR	+	0	Soft systolic murmur over apex and left sternal edge	0	0	+
6	M 35	2	Fever, weight loss, malaise, dry cough, rash, dyspnoea	++	SR	+	0	Murmur of mild mitral regurgitation	0	0	+
7	M 20	1	Effort dyspnoea: tiredness; weakness in legs	++	SR	+	0	Murmur of tricuspid regurgitation	0	0	++
8	M 36	—	Asymptomatic	N	SR	+	0	0	0	0	0
9	M 32	9/12	Atypical chest pain	N	SR	+	+	Soft apical systolic murmur	0	0	0
10	M 43	1/12	History suggestive of preinfarction angina	N	SR	+	+	0	0	0	0
11	M 58	3/12	Atypical chest pain	N	SR	+	0	0	0	0	0

JVP, jugular venous pressure; S3, third sound; S4, fourth sound; SR, sinus rhythm; LA, left atrium; RA, right atrium; N, normal.  
 \*Normal eosinophil count: less than  $0.55 \times 10^9/l$ .

pain was found on examination to have signs of right heart failure. Case 5 presented with bilateral intermittent claudication and was subsequently found to have a cardiac abnormality with a raised venous pressure and an abnormal electrocardiogram. Cases 6 and 7 presented with a constitutional illness, with fever, weight loss, cough, and biventricular heart failure, and had eosinophilia. Four of the patients (cases 1, 9, 10, and 11) were referred because of chest pain which had been thought by their doctors to be angina; if it had not been for this pain, they would probably not have been referred. Case 8 was asymptomatic, but evidence of cardiac abnormality had been found when he was seen at another hospital for an unrelated complaint.

The most prominent physical sign was a third

heart sound and this was present in every case. The third heart sounds were loud and early, between 0.08 and 0.12 s after aortic valve closure. Two patients (cases 2 and 3) showed asynchronous right and left ventricular third heart sounds on phonocardiography (Fig. 1) but these were not recognisable clinically. In all the patients except cases 2 and 5, the third heart sound was best heard at the cardiac apex, rather than at the left sternal edge as in constrictive pericarditis. Sinus rhythm was present in all except one patient (case 1) who had changing atrial arrhythmias including atrial tachycardia, flutter, and fibrillation. The jugular venous pressure was raised in 7 out of the 11 patients who also had non-pulsatile liver enlargement. The exceptions were the 3 patients who presented with chest pain

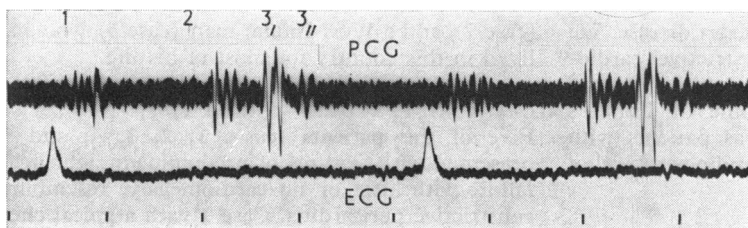


Fig. 1 Case 2. Phonocardiogram (PLG) showing asynchronous third heart sounds.

Chest x-ray film	Electrocardiogram	Eosinophil count*
light cardiomegaly; LA + ; pulmonary venous congestion	Normal apart from rhythm	N
light cardiomegaly	Biatrial hypertrophy; lateral repolarisation changes	N
light cardiomegaly; pulmonary venous congestion	Left anterior hemiblock; biatrial hypertrophy	N
light cardiomegaly	LA + ; lateral repolarisation changes	N
light cardiomegaly	RA + ; right axis deviation; inverted TV4 to V6	N
Normal	LA + ; inferolateral repolarisation changes	$5.2 \times 10^9/l$
light cardiomegaly; pulmonary venous congestion	Right axis deviation; LA + ; lateral T wave inversion	$7.4 \times 10^9/l$
Normal	Inferolateral T wave inversion	N
Normal	Non-specific LV + ; lateral repolarisation changes	N
Normal	Occasional ventricular extrasystoles; repolarisation changes V3 to V6	N
Normal	Normal	N

(cases 9, 10, and 11) and the asymptomatic patient (case 8). The venous pulse showed equal *a* and *v* waves with a wide excursion and prominent *x* and *y* descents. The most prominent *y* descent was seen in case 6 who had evidence of severe right ventricular restriction from eosinophilic endocarditis (see Fig. 12). The heart was clinically enlarged in only one patient (case 7). One patient (case 2) had a wholly diastolic impulse as is sometimes felt in constrictive pericarditis. Four patients (cases 2, 5, 6, and 9) had soft late systolic murmurs of mild mitral regurgitation while case 7 had a murmur of tricuspid regurgitation.

#### ELECTROCARDIOGRAM

The electrocardiogram showed non-specific, non-focal abnormalities, with a normal axis and QRS complex, in all except 3 patients. One showed left axis deviation (case 3) and 2 had right axis deviation (cases 5 and 7); the other patients all showed high normal voltages and left ventricular dominance. Repolarisation abnormalities of the ST segments and T waves were seen in 7 patients. Evidence of left atrial enlargement was present in 3, right atrial enlargement in 1, and biatrial hypertrophy in 2.

#### CHEST RADIOGRAPH

In 5 patients the chest radiographs were normal. The others showed slight cardiac enlargement or an abnormality in cardiac silhouette caused by left atrial or biatrial dilatation. This atrial dilatation was most pronounced in case 1, the patient with changing atrial rhythms. Evidence of pulmonary venous congestion was seen in only 3 patients. No intracardiac calcification was visible. In case 2, chest radiographs 5 years before admission to hospital in heart failure showed a normal sized heart; subsequent serial films showed progressive cardiomegaly and pulmonary venous congestion (Fig. 2).

#### Methods

##### NON-INVASIVE STUDIES

The phonocardiogram, an electrocardiographic lead, apex cardiogram, and mitral echocardiogram were recorded simultaneously, using a 6-channel Cambridge Scientific Instruments recorder (Type 72112) at a paper speed of 100 mm/s. Phonocardiograms were obtained using a suction microphone (Type 72352), and apex cardiogram tracings were obtained with a hand-held polythene funnel connected to a piezoelectric transducer with a pulse amplifier of time constant 1.6 s and a frequency response of  $\pm 3$  dB, 0.1 Hz to 100 Hz. Mitral echograms were obtained using the Smith Kline Ekoline 20 ultrasonoscope connected to a Cambridge recorder using both polaroid photography and strip chart recording.

##### HAEMODYNAMIC AND ANGIOCARDIOGRAPHIC STUDIES

The patients were premedicated with diazepam 10 mg intramuscularly. Under local anaesthetic, routine right and left heart catheterisation was carried out from the right antecubital vein, and from the femoral artery by the Seldinger method. Pressures were recorded using a Statham pressure transducer (P23Gb) and an Electronics for Medicine multiple channel recorder. Zero pressure was taken at the point midway between the plane of the catheterisation table and the sternum. Left ventricular cineangiography in the right anterior oblique position was carried out in all patients except cases 4 and 7. In 3 patients (cases 9, 10, and 11), simultaneous high fidelity measurements of left ventricular pressure and volume during diastole were carried out by a method previously described (Chew *et al.*, 1975). Left ventricular volumes were calculated by the area length method of Kasser and Kennedy (1969). Simultaneous pressures and volumes throughout diastole were plotted for each

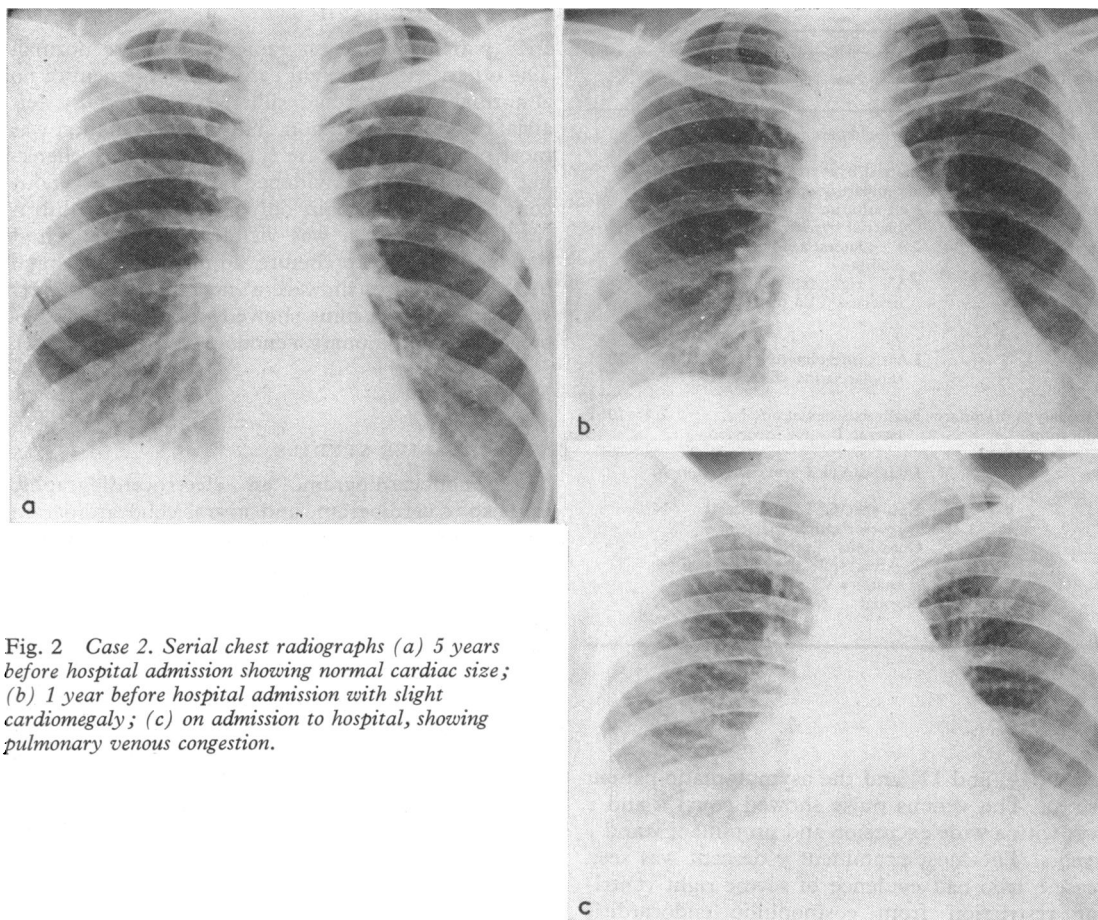


Fig. 2 Case 2. Serial chest radiographs (a) 5 years before hospital admission showing normal cardiac size; (b) 1 year before hospital admission with slight cardiomegaly; (c) on admission to hospital, showing pulmonary venous congestion.

patient using an Olivetti computer aided system for volume measurement. Coronary arteriography was carried out in 5 patients and transvenous right ventricular endomyocardial biopsy in 2 (cases 6 and 11).

## Results

### NON-INVASIVE STUDIES

The third heart sound was seen on the phonocardiogram in all the patients between 80 to 120ms after aortic valve closure, and corresponded well to the peak of the rapid filling wave on the apex cardiogram (Fig. 3).

Echocardiography showed that the diastolic closure rate of the anterior leaflet of the mitral valve was rapid (greater than 200 mm/s) in 7 of the patients while in the others the closure rates were within the normal range. Left ventricular dimen-

sions were within normal limits and filling was rapid as reflected by the rapid early outward movements of the posterior wall echoes, best seen in case 6 (Fig. 4).

### HAEMODYNAMIC AND ANGIOCARDIOGRAPHIC STUDIES (TABLE 2)

#### (a) Biventricular disease (cases 1 to 7)

The filling pressures in both ventricles were raised and except in cases 5 and 6, the left ventricular end-diastolic pressures exceeded the right ventricular end-diastolic pressures by more than 12 mmHg (Fig. 5). The left ventricular end-diastolic pressures ranged between 14 and 36 mmHg and the early diastolic pressures between 2 and 7 mmHg. The pressure record showed an early dip to normal followed by a steep early diastolic rise to a plateau which preceded and obliterated the *a* wave in 5 of the patients. In cases 1, 3, 4, and 7, the pulmonary

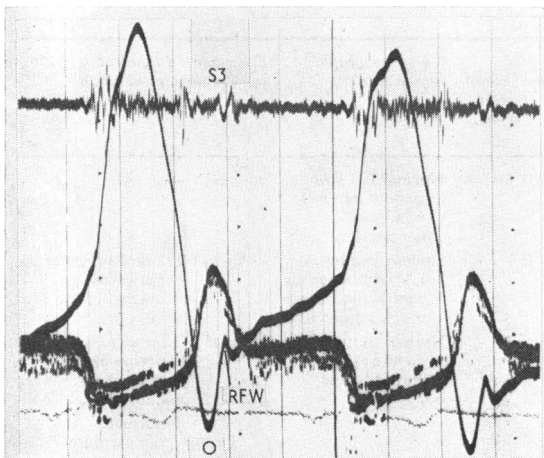


Fig. 3 Case 3. Simultaneous phonocardiogram, echocardiogram, and apex cardiogram showing third heart sound (S3) corresponding to peak of rapid filling wave.

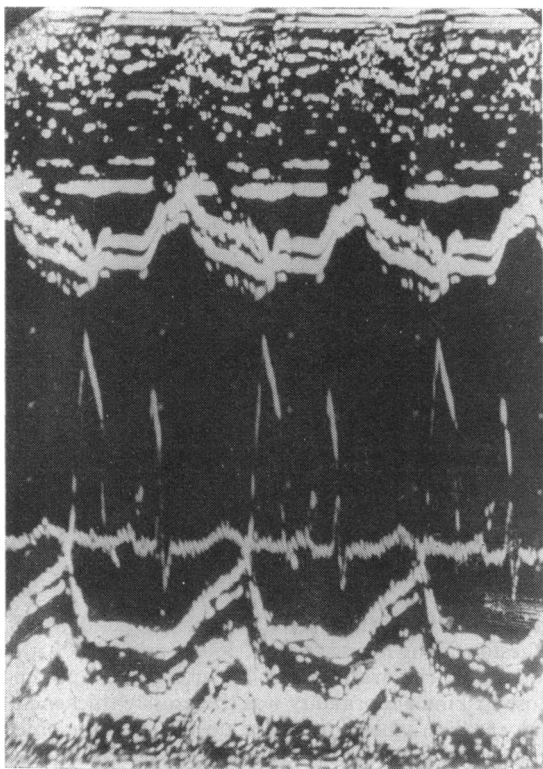


Fig. 4 Case 6. Echocardiogram showing rapid diastolic closure rate of anterior leaflet of mitral valve, normal ventricular dimensions, and rapid outward movement of posterior ventricular wall.

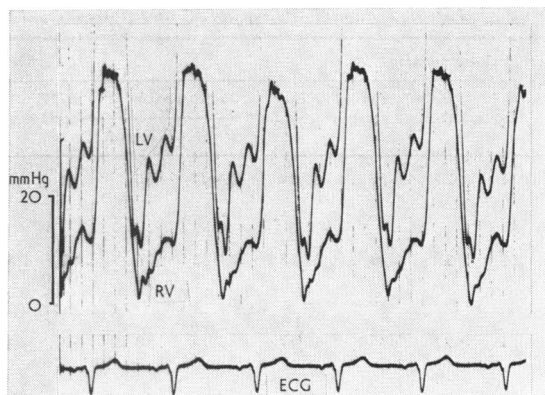


Fig. 5 Case 3. Biventricular endocardial disease showing unequal left and right ventricular diastolic pressures.

artery pressure was raised. The mean pulmonary artery pressure for the group ranged from 18 to 38 mmHg.

Left ventriculography showed a vigorously contracting ventricle with a smooth featureless appearance most obvious in case 2 (Fig. 6), in whom there was slight mitral regurgitation. In case 5, an unusual apical filling defect suggestive of an intraventricular tumour was seen (Fig. 7b and c). In case 6, the left ventricle appeared deformed with a small apical filling defect, but systolic contraction was normal (Fig. 8c and d). Ejection fractions were normal in 3 cases. Case 4 was studied in Iran by Dr. Rashid Massumi and systolic function as judged ventriculographically was reported as normal. Volumes were not calculated in case 6 because of persistent coupled ventricular ectopic beats during ventriculography.

Right ventriculography in cases 5, 6, and 7 showed obliteration of the apex of the right ventricle, exaggerated contraction of the infundibulum, and tricuspid regurgitation (Fig. 7a, 8a and b).

(b) *Left ventricular dysfunction only (cases 8 to 11)* The right heart pressures were normal. The left ventricular end-diastolic pressures were invariably raised (ranging from 18 to 32 mmHg) while the early diastolic pressures were normal; the left ventricular pressure records showed a 'dip and plateau' appearance (Fig. 9).

Left ventriculography in these cases showed normal ventricular configuration and contraction. In 2 cases, there was diminished trabeculation and papillary muscle indentation giving a smooth outline to the left ventricular cavity. Ejection fractions were normal.

Coronary angiograms in cases 9, 10, and 11 were normal.

Table 2 Haemodynamic, angiographic, and pathological data

Case No.	Pressure (mmHg)				LV volume		CI (Fick) (l/min per m <sup>2</sup> )	Ventriculographic appearance	Coronary angiogram	Pathological examination		
	RA (mean)	PAW (mean)	PA (mean)	RV (s/end-d)	Left ventricle (s/early-d End-d)	EDV (ml)					EF (%)	
1	14	24	30	45/14	130/7	30	46	74	1.6	Normal LV size; smooth ventricle with good contraction	Normal	—
2	16	25	28	35/13	135/2	27	63	82	2.5	Smooth featureless LV with vigorous contraction; some mitral regurgitation	—	Thoracotomy: normal pericardium necropsy: see Fig. 10
3	13	30	35	46/17	125/4	30	78	87	2.3	Normal contraction; no mitral regurgitation	Normal	Thoracotomy: no pericardial thickening
4	15	25	34	53/21	104/4	36	*	*	1.9	(Normal)*	—	Thoracotomy: normal pericardium
5	12	10	18	20/16	110/2	14	—	—	2.3	RV angio: small RV with apical filling defect LV angio: apical filling defect	—	Exploratory cardiomy: small LV with fibrous mass in lower part of septum
6	23	20	23	35/19	110/3	24	†	†	2.0	RV angio: large apical filling defect LV angio: apical filling defect	—	RV endocardial biopsy: endocardial thickening with collagen and irregular elastic fibrils; no eosinophils
7	16	32	38	53/16	100/6	35	—	—	2.1	Dilated RV with apical filling defect	—	—
8	8	15	18	32/13	140/2	18	86	80	2.2	Undilated LV with good contraction; no mitral regurgitation	—	—
9	6	10	15	22/7	145/5	18	73	82	2.6	Slight LV hypertrophy with good contraction; reduced trabeculation	Normal	—
10	5	14	18	20/8	120/8	20	42	72	2.7	Normal LV shape and contraction	Normal	—
11	6	20	24	28/10	170/4	32	66	77	1.9	Normal LV appearance	Normal	RV endomyocardial biopsy: excess fibrous tissue; no amyloid

RA, right atrium; PA, pulmonary artery; PAW, pulmonary artery wedge; RV, LV, right and left ventricle; s, d, systolic and diastolic; EDV end-diastolic volume; EF, ejection fraction; CI, cardiac index.

\*Left ventricular angiogram done in Iran and reported as normal.

†Not calculated because of persistent coupling.

#### HISTOPATHOLOGY

In cases 2, 3, and 4, exploratory thoracotomy and surgical biopsy were carried out. The pericardium was normal and the left ventricle small and thick-walled in each patient. Histological examination of the myocardium showed no special features apart from an increase in interstitial fibrous tissue and some hypertrophy of myocardial fibres.

Case 2 died two years after her initial illness, following operation for resection of gangrenous

small bowel resulting from volvulus around band adhesions. The heart weighed 460 g (normal 300 g). Both ventricles were mildly hypertrophied but the most striking abnormality was the grossly thickened endocardium which measured up to 6 mm in some areas (Fig. 10). This endocardial thickening involved the apex and body of the right ventricular cavity and the inflow portion and apex of the left ventricle; the endocardial thickening stopped abruptly with a rolled edge at the junction of the

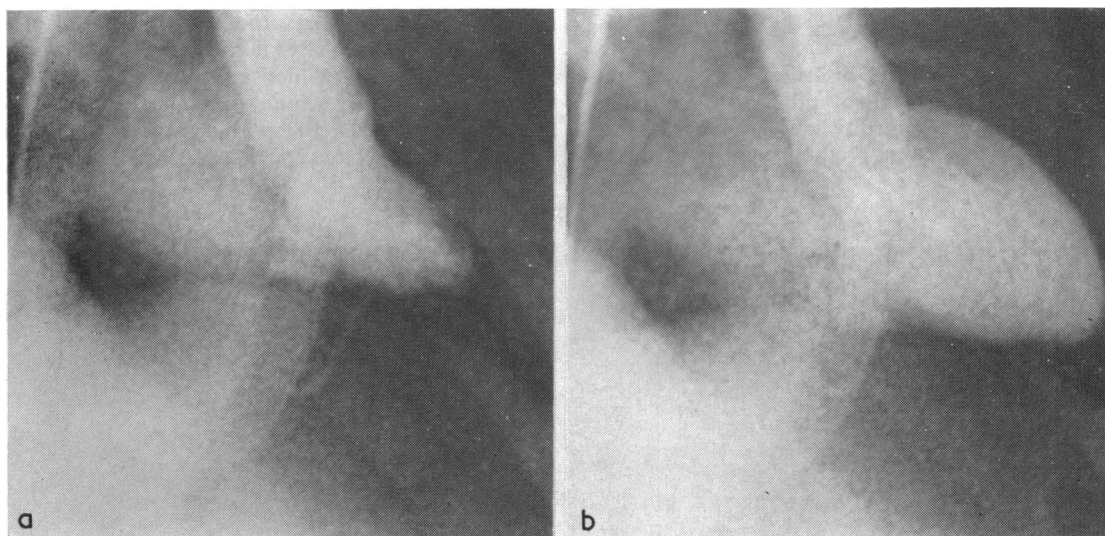


Fig. 6 Case 2. Left ventriculogram (a) end-systole; (b) end-diastole. Smooth, featureless, well-contracting ventricle, with mild mitral regurgitation.

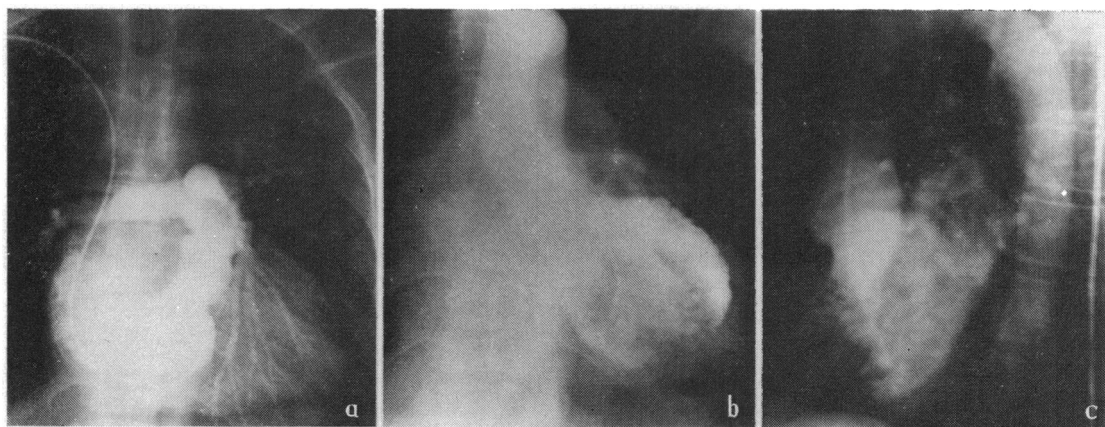


Fig. 7 Case 5. (a) Right ventriculogram showing apical filling defect; (b) and (c) left ventriculogram showing apical filling defect suggestive of intraventricular tumour (AP and lateral views).

inflow and outflow portions of the left ventricle. No thrombus was found in either ventricle. Histological examination showed zonal differentiation with a superficial layer and a granulation tissue layer containing dilated vascular channels and sparse chronic inflammatory infiltrate with no significant eosinophilic infiltration.

Endomyocardial biopsy of the right ventricle in cases 6 and 11 showed endocardial thickening with collagen and irregular elastic fibrils with no tissue eosinophilic infiltration.

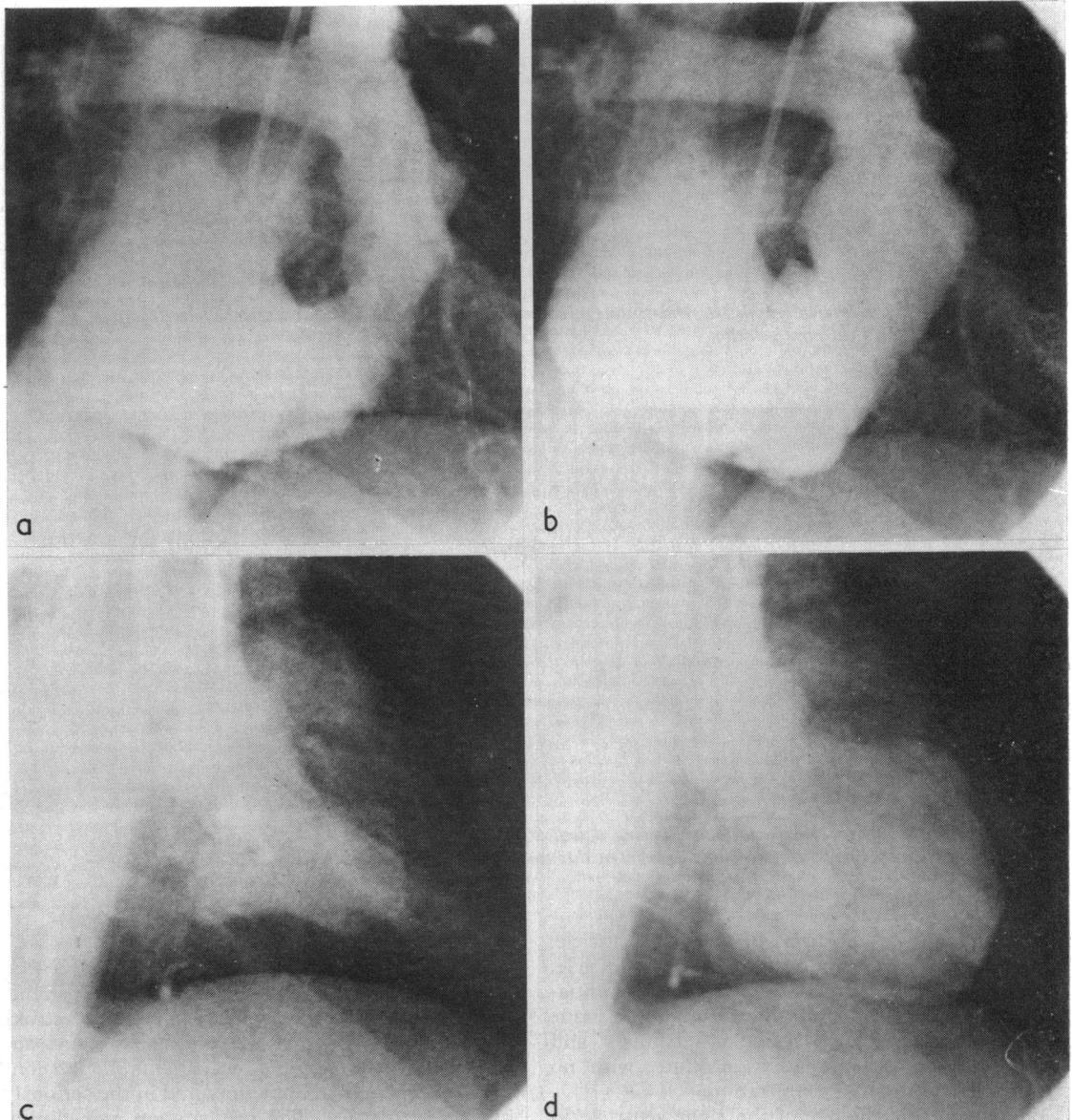
## Discussion

The main haemodynamic defect in these patients was restriction of ventricular filling and stroke output. Systolic contractile ability was not apparently affected in any of our patients though conceivably this could become impaired in the seriously involved ventricles. The presentation and clinical features varied considerably depending on the chambers involved and the severity of the haemodynamic disturbance.

**SEVERE FORM WITH BIVENTRICULAR DYSFUNCTION**

A severe form of the disorder with evidence of biventricular involvement and clinical resemblance to constrictive pericarditis was seen in 5 patients (cases 1 to 5). Three of these patients were sub-

jected to exploratory thoracotomy because of residual doubt even after investigation, and in order to carry out a surgical biopsy. With our accumulated experience of the haemodynamic and angiocardio-graphic features together with a growing reliance on endomyocardial biopsy, which is very useful in this



**Fig. 8** Case 6. (a) and (b) Right ventriculograms at end-systole and end-diastole, showing obliteration of the apex and preservation of infundibular contraction; (c) and (d) Left ventriculogram at end-systole and end-diastole. The ventricle is deformed with good contraction.



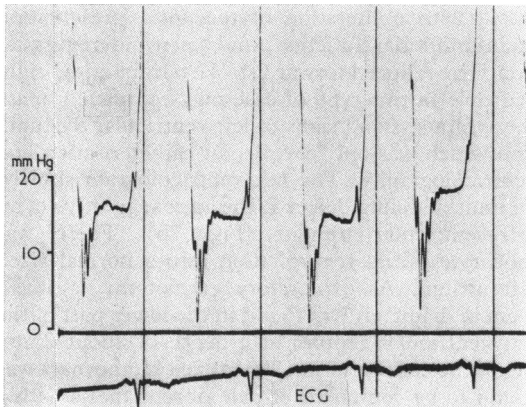


Fig. 9 Case 8. Left ventricular diastolic pressure record with a 'dip and plateau' pattern.

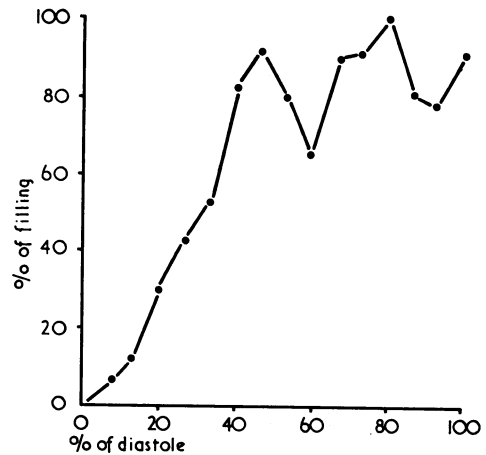


Fig. 11 Case 2. Left ventricular filling plotted frame by frame from cineangiogram. There is rapid filling with 90 per cent of filling completed halfway through diastole. Fluctuations during the second half of diastole may be the result of lapping of blood through the mitral valve.

disorder, the correct clinical diagnosis should now be made in all patients.

The characteristic loud and early third heart sounds reflected the characteristic pattern of ventricular filling which is illustrated in Fig. 11. Ventricular filling was completed early with little or no further filling in late diastole. This mirrored the apex cardiographic and echocardiographic feature of rapid outward movement of the posterior left ventricular wall with abrupt cessation. The timing of the third heart sounds was well within the range recorded in constrictive pericarditis (Wood, 1961). In cases 2 and 3, asynchronous left and right-sided

third heart sounds were recorded and indicated unequal involvement of the two ventricles, a feature which should generally exclude constrictive pericarditis with the exception of those rare cases of constriction in the left atrioventricular groove. While the hearing of an apical mid-diastolic murmur might be the result of a localised pericardial constriction, the presence of systolic murmurs indicating atrioventricular valve regurgitation points to

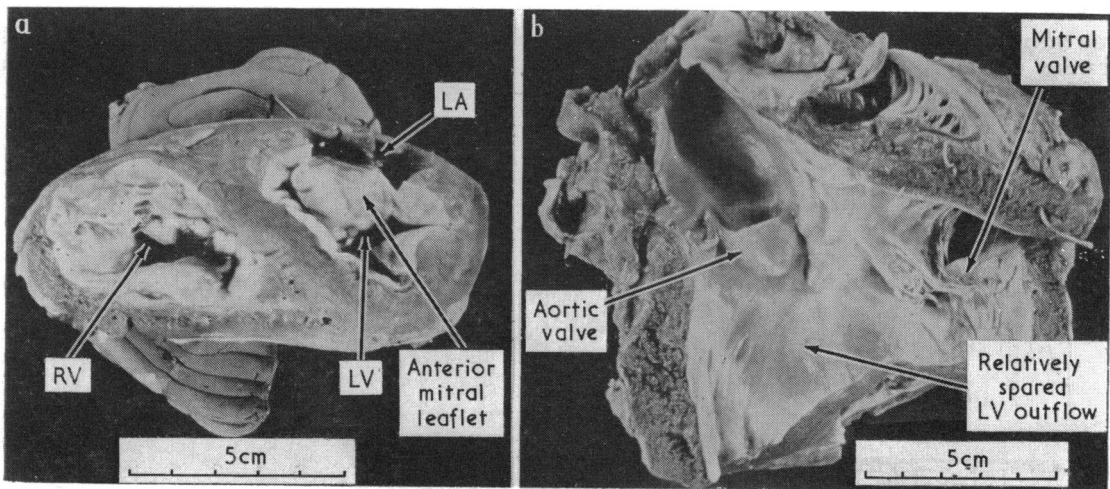


Fig. 10. Case 2. (a) and (b) Heart in case 2. There is gross endocardial thickening of both ventricles.

endocardial disease. In cases 1, 3, and 4, the left ventricular filling pressure was raised sufficiently to lead to pulmonary arterial hypertension. A raised pressure in the pulmonary artery is uncommon in constrictive pericarditis because sufficient rise in the left atrial pressure rarely occurs even in cases of extreme severity. In constrictive pericarditis, external restriction of filling affects both ventricles to an equal degree in most instances so that the end-diastolic pressures in the two ventricles are similar (Shabetai *et al.*, 1970). Both in pericardial constriction and in restrictive cardiomyopathy the dip and plateau form of the diastolic portion of the ventricular pressure record is seen, and in both conditions the early diastolic pressures are normal, in contrast to the raised early diastolic pressures which are seen in both hypertrophic cardiomyopathy (HOCM) and in amyloid heart disease.

The patients differed from those with amyloid heart disease, a condition which is often cited as an example of restrictive heart muscle disorder. In cardiac amyloidosis, as in restrictive cardiomyopathy, the left ventricular volume is normal at end-diastole but there is usually also distinct impairment of systolic emptying, a combination that results in the extremely low stroke volume, low pulse pressure, and low blood pressure, characteristic of amyloid heart disease. In amyloid heart disease the diastolic pressure in the left ventricle is high at the beginning of filling so that a true dip and plateau pressure pulse is rarely seen. We have previously shown that the left ventricle fills slowly throughout most of diastole in amyloid heart disease, and that this slow filling is reflected clinically by the absence of a third heart sound (Chew *et al.*, 1975).

The clinical and haemodynamic features of case 5 were those of predominant right ventricular involvement, and a right ventriculogram showed features of right-sided endomyocardial fibrosis (Cockshott *et al.*, 1967). The right ventricle was

small, with obliteration of the apex, preservation of infundibular function, and tricuspid regurgitation. The reduced forward stroke output of the right ventricle in this type of case may completely mask the symptoms and signs of left ventricular dysfunction which was only revealed at catheterisation and ventriculography. The left ventriculogram showed an unusual filling defect at the apex suggestive of an intraventricular tumour (Fig. 7b). There was moderate mitral regurgitation into a normal sized left atrium. At exploratory cardiotomy, a mass, 3 cm in diameter, was found in the lower part of the left ventricular septum at a depth of about 2 mm below the endocardium. When excised, the mass was found to be composed of pale fibrous tissue with a necrotic centre, but there was no plane of cleavage to suggest a tumour. This case superficially resembled that described by Van der Hauwaert *et al.* (1965). These authors described a 16-month-old boy with eosinophilia and ventriculographic features akin to right-sided endomyocardial fibrosis; he was found at necropsy to have a large fibrotic mass in the right ventricle producing tricuspid stenosis.

Cases 6 and 7 had a striking eosinophilia and the clinical features of Löffler's eosinophilic endocarditis (Löffler, 1936; Brink and Weber, 1963; Scott and Bruce, 1975), though there were no embolic manifestations or electrocardiographic evidence of conduction defects. Our observations and those of Bell *et al.* (1976) show that the haemodynamic and ventriculographic findings in Löffler's endocarditis can be similar to those in severe endomyocardial fibrosis. As is characteristic of severe right-sided endomyocardial fibrosis, identical pressures were recorded in the right atrium and right ventricle in case 6 (Fig. 12). Ventriculographically both cases (6 and 7) had apical filling defects in the right ventricle, and a left ventriculogram in case 6 showed an undilated, well-contracting ventricle with an apical filling defect (Fig. 8).

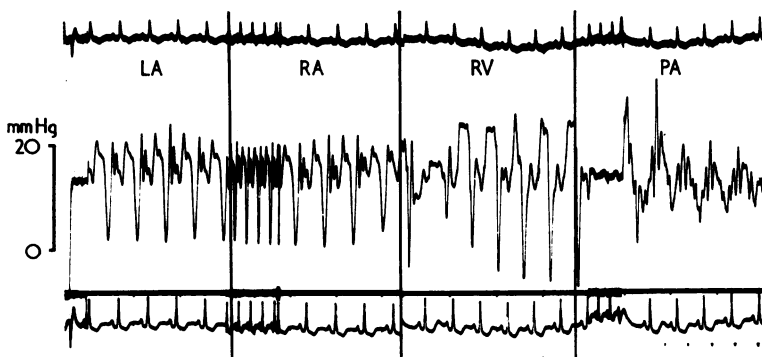


Fig. 12 Case 6. Löffler's eosinophilic endocarditis. Identical pressure tracings from right ventricle, and from right and left atria, with prominent y descent in all.

Exploratory thoracotomy and surgical biopsy was carried out in cases 2, 3, and 4. In each of these patients, the pericardium was found to be normal and the left ventricle small and thick walled. Histological examination of the myocardium showed a non-specific increase in interstitial fibrous tissue and some myocardial fibre hypertrophy. This well illustrates the difficulty in diagnosing a predominantly endocardial disease from a surgical biopsy as endocardium may not even be obtained.

The macroscopical and histological appearances in case 2 were typical of tropical biventricular endomyocardial fibrosis. The endocardium was grossly thickened and classically involved the apex and body of the right ventricular cavity and the inflow portion and the apex of the left ventricle. The endocardial thickening ceased abruptly at the junction of the inflow and outflow portions of the left ventricle with a rolled edge, as is commonly seen in endomyocardial fibrosis (Davies, 1968).

Transvenous right ventricular endomyocardial biopsy in case 6 with Löffler's eosinophilic endocarditis showed endocardial thickening with collagen and irregular elastic fibrils but no tissue eosinophilic infiltration.

**LEFT VENTRICULAR DYSFUNCTION ONLY**

Four of our cases (cases 8, 9, 10, and 11) had evidence of left ventricular disorder only. Three had atypical chest pain and were specifically referred for coronary arteriography. One was asymptomatic but had an abnormal electrocardiogram. These patients should be recognisable clinically by the unexpected third heart sound and the non-specific repolarisation changes on the electrocardiograms. The consistently raised filling pressure in the left ventricle and the shape of the left ventricular pressure pulse were characteristic.

The nature of the diastolic abnormality was studied in detail in cases 9, 10, and 11, in whom instantaneous left ventricular pressures and volumes were measured at 50 ms intervals throughout diastole (Fig. 13). At the moment of mitral valve opening the ventricular pressure and volume were both normal and filling was rapid, but in mid-diastole the pressure climbed steeply to an abnormally high level and after this time there was little further increase in ventricular volume. When examined against time, left ventricular filling was rapid and abruptly curtailed, as in case 2. Because contractile function was normal and the atrioventricular valves not involved in the endocardial process, this rapid ventricular filling enables these patients to compensate by tachycardia for reduced stroke output. The characteristic early and

loud third heart sound is the clinical counterpart of this haemodynamic abnormality.

A contrast may be made with hypertrophic cardiomyopathy (HOCM) in which chest pain is also a common presenting symptom. In HOCM, the early diastolic pressures are abnormally high (Fig. 14) and rise further during diastole, culminating in an augmented *a* wave. Left ventriculography further differentiated between the two conditions. Unlike that in patients with HOCM, the left ventricle was normally shaped but showed normal or

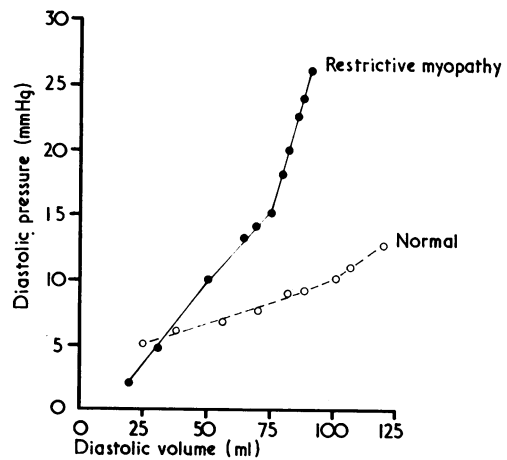


Fig. 13 Case 11. Pressure-volume relation during one diastolic cycle.

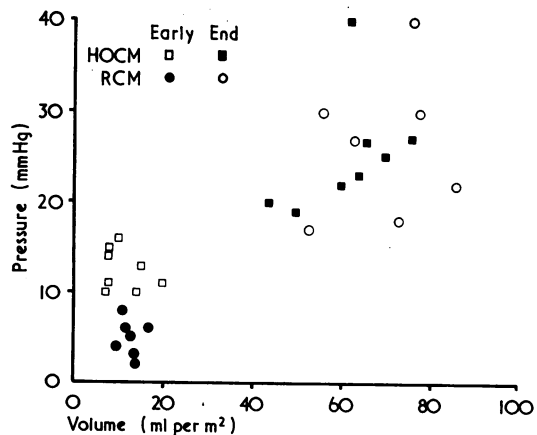


Fig. 14 Left ventricular pressures and volumes at early and end-diastole in hypertrophic cardiomyopathy (HOCM) and restrictive cardiomyopathy (RCM).

diminished trabeculation and reduced papillary muscle indentation. This gave the ventricle a smooth featureless appearance which was most obvious in severely affected cases though recognisable also in the milder ones.

#### USE OF ENDOMYOCARDIAL BIOPSY

A right ventricular biopsy in case 11 showed an excess of fibrous tissue which suggested that the disease process involved both ventricles even though the haemodynamic abnormality was confined to the left ventricle. In the absence of ventricular dilatation the finding of excessive fibrous tissue is highly suggestive of endomyocardial fibrosis. Left ventricular biopsy may be hazardous in patients with eosinophilia in whom mural thrombus may be present, and in any patient with features of restrictive cardiomyopathy, left ventriculography should probably always be carried out before attempting a biopsy from the left ventricle in order that intracavitary thrombus can be recognised. It is possible that right ventricular biopsy may be diagnostic even in patients without clinical right ventricular involvement, and that (as in case 11) left ventricular biopsy can be avoided.

#### POSSIBLE AETIOLOGY

A wealth of published material now exists on the occurrence of endomyocardial scarring and varying degrees of myocardial fibrosis outside tropical Africa. Cases have been reported from the USA (McKusick and Cochran, 1952; Thomas *et al.*, 1954; Clark *et al.*, 1956; McNamara *et al.*, 1959; Bishop *et al.*, 1968). Brazil (Andrade and Guimaraes, 1964), Ceylon (Nagaratnam and Dissanayake, 1959), South India (Samuel and Anklesaria, 1960), Japan (Nakajima *et al.*, 1961; Yoshida *et al.*, 1964), Jamaica (Stuart and Hayes, 1963), Malaya (La Brooy, 1957), Mexico (Contreras *et al.*, 1971), and Portugal (Coelho and Pimentel, 1963). In Britain, a number of cases have been reported (Lynch and Watt, 1957; Faruque, 1963; Davies *et al.*, 1965). Black and Fowler (1965) encountered 5 cases of endomyocardial fibrosis with normal coronary arteries in a district general hospital and suggested that the condition might be more common than previously suspected.

The relation between these non-African cases of endomyocardial fibrosis and those of Ugandan type endomyocardial fibrosis as seen in tropical Africa and South America is difficult to ascertain. Connor *et al.* (1967, 1968) reviewed the findings in cases reported from Britain and the United States who were thought to have endomyocardial fibrosis but who had lived outside the tropics and found 4 that had extensive enough endocardial scarring and

fibrosis to resemble Ugandan type endomyocardial fibrosis; these 4 cases were identical pathologically to our case 2 who came to necropsy.

Haemodynamically, our cases with biventricular disease are similar to those described as endomyocardial fibrosis from Africa and South America (Shillingford and Somers, 1961; Somers *et al.*, 1968; Guimarães *et al.*, 1974; Bertrand *et al.*, 1975). We have, however, shown that a mild form of the disorder exists in our society to which little attention has previously been paid. These cases in our series would have escaped recognition if they had not complained of chest pain. In medically less sophisticated societies, these mild and asymptomatic cases would probably not seek medical attention; this may explain the absence of descriptions of early or mild cases from those centres in tropical Africa from which the classical and clinically florid forms were originally described by Davies and his associates (Davies, 1948; Ball *et al.*, 1954).

None of the predisposing factors postulated in the pathogenesis of tropical endomyocardial fibrosis, such as filariasis (Ive *et al.*, 1967) or a diet rich in serotonin (Arnott, 1959) was relevant in our cases. None received drugs such as methysergide, busulphan, or daunorubicin which have recently been implicated in the development of endocardial fibrosis (Bana *et al.*, 1974; Weinberger *et al.*, 1975; Wilcox *et al.*, 1976).

Roberts *et al.* (1969, 1970) suggested that there might be a spectrum of eosinophilic heart disease ranging in severity from Löffler's eosinophilic endocarditis, the most acute and fatal form, to Ugandan type endomyocardial fibrosis. The evidence so far linking Löffler's eosinophilic endocarditis or the cardiac disorder occurring in other hypereosinophilic states with endomyocardial fibrosis without eosinophilia is reviewed by Oakley and Olsen (1977). Pathologically the two conditions are often indistinguishable (Brockington and Olsen, 1973; Olsen, 1975) and there have been reports of patients who present with an initial hypereosinophilic illness, survive, and who are found at necropsy to have endomyocardial fibrosis, in some with features identical to Ugandan type endomyocardial fibrosis (Blair *et al.*, 1974; Frenkel *et al.*, 1975; Libanoff and McMahon, 1976). Chusid *et al.* (1975) studied 14 patients presenting with the hypereosinophilic syndrome and in reviewing the published reports found clinical and pathological involvement of the heart in 95 per cent of the cases. Of those that came to necropsy, 41 per cent had thrombi closely adherent to endocardium, which was fibrotic in 31 per cent. The left ventricles appeared to be more severely affected than the right and both thrombus formation and endocardial

fibrosis were more frequent at the apices than in the outflow tracts. Abnormal echocardiographic features consisting of left ventricular free wall and septal thickening were found in the majority of both asymptomatic and symptomatic cases.

Eosinophils are often abundant in areas of chronic inflammation though sparse at sites of acute inflammation. Several substances have chemotactic activity for eosinophils, including histamine and some antigen-antibody complexes (Archer, 1965) and some components of human complement (Lachmann *et al.*, 1970). Eosinophils can phagocytose immune complexes (Sabesin, 1963; Litt, 1964); morphological changes in the eosinophils are recognised and Connell (1968) pointed out that phagocytosis of immune complexes may produce vacuolation and degranulation. Some of Chusid's patients with a hypereosinophilic syndrome and a restrictive cardiac disorder showed such changes, and recently Spry and Tai (1976) showed that a proportion of the circulating eosinophils in such patients possessed receptors for rabbit IgG coated erythrocytes and actively phagocytosed lymphocytes coated with rabbit IgG or human C<sub>3</sub>B. These abnormal eosinophils, therefore, had characteristics of mature or stimulated eosinophils with the capacity of responding to soluble substances in the blood by forming endocytic vacuoles leading to degranulation. This eosinophilic material which would normally not enter the blood stream where eosinophils are in tissue sites may itself be responsible for cardiac injury. Alternatively, it is possible that eosinophils migrating to the scene of immunological activity act in an entirely beneficial fashion through their phagocytic activity.

The absence of eosinophilia in some of our cases and in those from tropical Africa in no way invalidates this hypothesis. Eosinophilia may not be sustained even though the damage caused by or associated with it proceeds to healing with fibrosis, a stage of final scarring which we recognise as endomyocardial fibrosis when it occurs in the tropics and which we suggest occurs also in temperate climes and in milder form. Van der Geld and his associates in Uganda (1966) found a high incidence of circulating autoantibodies to heart muscle in endomyocardial fibrosis using immunological staining methods, and the incidence and severity of endocardial lesions in a population may reflect variable individual autoimmune responsiveness and account for the predilection of endomyocardial fibrosis in Uganda for immigrant groups from Rwanda and Burundi and relative immunity of the local indigenous Ganda tribe (Connor *et al.*, 1967, 1968). A less severe or less sustained endocardial process easily explains the existence of mild cases which are

likely to have a good prognosis and would be unlikely to be recognised except for the chance recognition of a cardiac abnormality in an environment where diagnosis is aggressively pursued.

The group of patients described showed a restrictive cardiac disorder which varied in site and severity, thus accounting for the wide clinical spectrum. Our mildest cases, whose disease predominantly affected the left ventricle, presented because of chest pain which may be only a rare symptom in this disorder but which led in them to further investigation. Such patients should have a good prognosis, but in the more severe forms, with biventricular and valvular involvement, the prognosis may be much less good (D'Arbela *et al.*, 1972), though even these patients may live a number of years (Chusid *et al.*, 1975). It is in the most severely affected patients that endocardial resection and valve replacement may occasionally be carried out successfully and with benefit, as has recently been reported by a number of American and European workers (Lepley *et al.*, 1974; Dubost, 1975; Cachera *et al.*, 1976).

We thank Professor J. F. Goodwin for allowing us to include cases 3, 6, and 11; Drs. E. Besterman and R. Vecht for case 5; and Dr. E. G. J. Olsen for interpreting the biopsies, and for Fig. 10.

#### References

- Andrade, Z. A., and Guimarães, A. C. (1964). Endomyocardial fibrosis in Bahia, Brazil. *British Heart Journal*, **26**, 813-820.
- Archer, R. K. (1965). On the functions of eosinophils in the antigen-antibody reaction. *British Journal of Haematology*, **11**, 123-129.
- Arnott, W. M. (1959). A problem in tropical cardiology. *British Medical Journal*, **2**, 1273-1277.
- Ball, J. D., Williams, A. W., and Davies, J. N. P. (1954). Endomyocardial fibrosis. *Lancet*, **1**, 1049-1054.
- Bana, D. S., Macneal, P. S., Le Compte, P. M., Shah, Y., and Graham, J. R. (1974). Cardiac murmurs and endocardial fibrosis associated with methysergide therapy. *American Heart Journal*, **88**, 640-655.
- Bell, J. A., Jenkins, B. S., and Webb-Peploe, M. M. (1976). Clinical, haemodynamic and angiographic findings in Löffler's eosinophilic endocarditis. *British Heart Journal*, **38**, 541-548.
- Bertrand, E., Renambot, J., Chauvet, J., Le Bras, M., Lamouche, P., Ekra, A., Roux, F., Erte, M., and Loubière, R. (1975). Sur 14 cas de fibrose endocardique constrictive (ou fibrose endo-myocardique). *Archives des Maladies du Cœur et des Vaisseaux*, **68**, 625-635.
- Bishop, M. B., Bousvaros, G., Cunningham, T. J., Jain, A. C., and Davies, J. N. P. (1968). Endomyocardial fibrosis in a North American negro. *Lancet*, **2**, 750-751.
- Black, M., and Fowler, J. M. (1965). Endomyocardial fibrosis in Britain. *British Medical Journal*, **1**, 682-686.
- Blair, H. T., Chahine, R. A., Raizner, A. E., Gyorkey, F., and Luchi, R. J. (1974). Unusual hemodynamics in Löffler's

- endomyocarditis. *American Journal of Cardiology*, **34**, 606-609.
- Brink, A. J., and Weber, H. W. (1963). Fibroplastic parietal endocarditis with eosinophilia. Löffler's endocarditis. *American Journal of Medicine*, **34**, 52-70.
- Brockington, I. F., and Olsen, E. G. J. (1973). Löffler's endocarditis and Davies' endomyocardial fibrosis. *American Heart Journal*, **85**, 308-322.
- Cachera, J. P., Poulain, H., Menasche, Ph., Laurent, F., Loisanche, D., and Chiche, P. (1976). Endocardite fibreuse d'origine filarienne traitement chirurgical par endocardectomie du ventricule gauche et remplacement prosthétique de la valve mitrale. *Tropical Cardiology*, **2**, 79-89.
- Chew, C., Ziady, G. M., Raphael, M. J., and Oakley, C. M. (1975). The functional defect in amyloid heart disease. The 'stiff heart' syndrome. *American Journal of Cardiology*, **36**, 438-444.
- Chusid, M. J., Dale, D. C., West, B. C., and Wolff, S. M. (1975). The hypereosinophilic syndrome: analysis of fourteen cases with review of the literature. *Medicine*, **54**, 1-27.
- Clark, G. M., Valentine, E., and Blount, S. G. (1956). Endocardial fibrosis simulating constrictive pericarditis. *New England Journal of Medicine*, **254**, 349-355.
- Cockshott, W. P., Saric, S., and Ikeme, A. C. (1967). Radiological findings in endomyocardial fibrosis. *Circulation*, **35**, 913-922.
- Coelho, E., and Pimentel, J. C. (1963). Diffuse endomyocardial fibrosis. *American Journal of Medicine*, **35**, 569-576.
- Connell, J. T. (1968). Morphological changes in eosinophils in allergic disease. *Journal of Allergy*, **41**, 1-9.
- Connor, D. H., Somers, K., Hutt, M. S. R., Manion, W. C., and D'Arbela, P. G. (1967). Endomyocardial fibrosis in Uganda (Davies' disease) (Part I). *American Heart Journal*, **74**, 687-709.
- Connor, D. H., Somers, K., Hutt, M. S. R., Manion, W. C., and D'Arbela, P. G. (1968). Endomyocardial fibrosis in Uganda (Davies' disease) (Part II). *American Heart Journal*, **75**, 107-124.
- Contreras, R., Bialostozky, D., Medrano, G., Fishleder, B., and Guadalajara, J. F. (1971). Fibrosis endomiocardiaca Africana o tropical. Comunicacion del primer caso observado en México. *Archivos del Instituto de Cardiología de México*, **41**, 476-489.
- D'Arbela, P. G., Mutazindwa, T., Patel, A. K., and Somers, K. (1972). Survival after first presentation with endomyocardial fibrosis. *British Heart Journal*, **34**, 403-407.
- Davies, H., Deuchar, D. C., and Missen, G. A. K. (1965). Endomyocardial fibrosis: two cases with severe pulmonary hypertension presenting in England. *Guys Hospital Reports*, **114**, 337-362.
- Davies, J. N. P. (1948). Endocardial fibrosis in Africans. *East African Medical Journal*, **25**, 10-14.
- Davies, J. N. P. (1968). The ridge in endomyocardial fibrosis. *Lancet*, **1**, 631-632.
- Dubost, C. (1975). L'endocardectomie: traitement chirurgical de la fibrose endocardique constrictive. *Comptes Rendus Hebdomadaires des Seances de l'Academie des Sciences Series D (Paris)*, **281**, 855-877.
- Faruque, A. A. (1963). Adult endomyocardial fibrosis in Britain. *Lancet*, **2**, 331-333.
- Frenkel, R., Grieco, M. H., and Garrett, R. (1975). Löffler's endomyocarditis associated with bronchial asthma and eosinophilia. *Annals of Allergy*, **34**, 213-218.
- Goodwin, J. F., and Oakley, C. M. (1972). The cardiomyopathies. *British Heart Journal*, **34**, 545-552.
- Guimarães, A. C., Filho, A. S., Esteves, J. P., Vinhaes, L. S. A., and Abreu, W. N. (1974). Hemodynamics in endomyocardial fibrosis. *American Heart Journal*, **88**, 294-303.
- Ive, F. A., Willis, A. J. P., Ikeme, A. C., and Brockington, I. F. (1967). Endomyocardial fibrosis and filariasis. *Quarterly Journal of Medicine*, **36**, 495-516.
- Kasser, I. S., and Kennedy, J. W. (1969). Measurement of left ventricular volumes in man by single-plane cineangiography. *Investigative Radiology*, **4**, 83-90.
- La Brooy, E. B. (1957). Endomyocardial fibrosis. *Proceedings of the Alumni Association, Malaya*, **10**, 303-312.
- Lachmann, P. J., Kay, A. B., and Thompson, R. A. (1970). The chemotactic activity for neutrophil and eosinophil leucocytes of the trimolecular complex of the fifth, sixth and seventh components of human complement (C567) prepared in free solution by the 'reactive lysis' procedure. *Immunology*, **19**, 895-899.
- Lepley, D., Aris, A., Kornis, M. E., Walker, J. A., and D' Cunha, R. M. (1974). Endomyocardial fibrosis. A surgical approach. *Annals of Thoracic Surgery*, **18**, 626-633.
- Libanoff, A. J., and McMahan, N. J. (1976). Eosinophilia and endomyocardial fibrosis. *American Journal of Cardiology*, **37**, 438-441.
- Litt, M. (1964). Studies in experimental eosinophilia VI Uptake of immune complexes by eosinophils. *Journal of Cell Biology*, **23**, 355-361.
- Löffler, W. (1936). Endocarditis Parietalis Fibroplastica mit Bluteosinophilie. *Schweizerische medizinische Wochenschrift*, **66**, 817-820.
- Lynch, J. B., and Watt, J. (1957). Diffuse endomyocardial sclerosis. *British Heart Journal*, **19**, 173-185.
- McKusick, A., and Cochran, T. H. (1952). Constrictive endocarditis. Report of a case. *Bulletin of the Johns Hopkins Hospital*, **90**, 90-97.
- McNamara, P. J., Jacobs, W. H., and Jaffe, R. J. (1959). Idiopathic cardiac hypertrophy with endomyocardial fibrosis: report of a case developing after recovery from a purulent lung abscess. *Annals of Internal Medicine*, **50**, 1035-1045.
- Nagaratnam, N., and Dissanayake, R. V. P. (1959). Endomyocardial fibrosis in the Ceylonese. *British Heart Journal*, **21**, 167-173.
- Nakajima, K., Okada, R., and Ueda, H. (1961). A case report of endomyocardial fibrosis. *Japanese Heart Journal*, **2**, 265-275.
- Oakley, C. M. (1975). The relation between function and causation in cardiomyopathy. *Postgraduate Medical Journal*, **51**, 271-276.
- Oakley, C. M., and Olsen, E. G. J. (1977). Editorial: Eosinophilia and heart disease. *British Heart Journal*, **39**, 233-237.
- Olsen, E. G. J. (1975). Pathological recognition of cardiomyopathy. *Postgraduate Medical Journal*, **51**, 277-281.
- Roberts, W. C., Buja, L. M., and Ferrans, V. J. (1970). Löffler's fibroplastic parietal endocarditis, eosinophilic leukaemia and Davies' endomyocardial fibrosis: the same disease at different stages? *Pathologia et Microbiologia*, **35**, 90-95.
- Roberts, W. C., Liegler, D. G., and Carbone, P. P. (1969). Endomyocardial disease and eosinophilia. A clinical and pathologic spectrum. *American Journal of Medicine*, **46**, 28-42.
- Sabesin, S. M. (1963). A function of the eosinophil: phagocytosis of antigen-antibody complexes. *Proceedings of the Society for Experimental Biology and Medicine*, **112**, 667-670.
- Samuel, I., and Anklesaria, X. J. (1960). Endomyocardial fibrosis in South India. *Indian Journal of Pathology and Bacteriology*, **3**, 157.
- Scott, M. E., and Bruce, J. H. (1975). Löffler's endocarditis. *British Heart Journal*, **37**, 534-538.
- Shabetai, R., Fowler, N. O., and Guntheroth, W. G. (1970). The hemodynamics of cardiac tamponade and constrictive pericarditis. *American Journal of Cardiology*, **26**, 480-489.

- Shillingford, J. P., and Somers, K. (1961). Clinical and haemodynamic patterns in endomyocardial fibrosis. *British Heart Journal*, **23**, 433-446.
- Somers, K., Brenton, D. P., D'Arbela, P. G., Fowler, J. M., Kanyerezi, B. R., and Sood, N. K. (1968). Haemodynamic features of severe endomyocardial fibrosis of right ventricle including comparison with constrictive pericarditis. *British Heart Journal*, **30**, 322-332.
- Spry, C. J. F., and Tai, P. C. (1976). Studies on blood eosinophils II: patients with Löffler's cardiomyopathy. *Clinical and Experimental Immunology*, **24**, 423-434.
- Stuart, K. L., and Hayes, J. A. (1963). A cardiac disorder of unknown aetiology in Jamaica. *Quarterly Journal of Medicine*, **32**, 99-114.
- Thomas, W. A., Randall, R. V., Bland, E. F., and Castleman, B. (1954). Endocardial fibroelastosis: a factor in heart disease of obscure etiology. *New England Journal of Medicine*, **251**, 327-338.
- Van der Geld, H., Peetoom, F., Somers, K., and Kanyerezi, B. R. (1966). Immunohistological and serological studies in endomyocardial fibrosis. *Lancet*, **2**, 1210-1214.
- Van der Hauwaert, L. G., Corbeel, L., and Maldague, P. (1965). Fibroma of the right ventricle producing severe tricuspid stenosis. *Circulation*, **32**, 451-456.
- Weinberger, A., Pinkhas, J., Sandbank, U., Shaklai, M., and de Vries, A. (1975). Endocardial fibrosis following busulfan treatment. *Journal of the American Medical Association*, **231**, 495.
- Wilcox, R. G., James, P. D., and Togill, P. J. (1976). Endomyocardial fibrosis associated with daunorubicin therapy. *British Heart Journal*, **38**, 860-863.
- Wood, P. (1961). Chronic constrictive pericarditis. *American Journal of Cardiology*, **7**, 48-61.
- Yoshida, T., Nimura, Y., Sakakibara, H., Matsutani, K., Nishizaki, K., and Nakata, T. (1964). A diffuse endocardial fibroelastosis with markedly dilated right atrium observed in an adult. *Japanese Heart Journal*, **5**, 85-92.

Requests for reprints to Dr. C. M. Oakley, Hammersmith Hospital, Du Cane Road, London W12 OHS.