

'Continuously regurgitating mitral valve': systolic and diastolic mitral regurgitation in a case of severe aortic regurgitation and complete heart block

A 67-year-old man presented with progressive effort dyspnoea and intermittent episodes of presyncope. His pulse was regular

at 48/min with collapsing character. His mean jugular venous pressure was normal with intermittent cannon waves. Precordial examination revealed cardiomegaly with forceful apical impulse. On auscultation, a long early diastolic murmur of aortic regurgitation (AR) and a soft systolic murmur of mitral regurgitation (MR) were audible. ECG showed complete heart block (CHB) with wide QRS complexes at a rate of 48/min. Echocardiographic evaluation revealed severe AR, dilated left ventricle (LV), and LV systolic dysfunction (ejection fraction 50%). The mitral valve showed annulus dilatation, normal leaflets and chordae tendinae, and systolic and diastolic MR (figure 1A and see online supplementary video). Colour M mode (figure 1B) and pulse wave Doppler (figure 1C) imaging clearly showed MR during both systole and diastole. The patient underwent permanent pacemaker implantation and aortic valve replacement. Diastolic MR in this case resulted

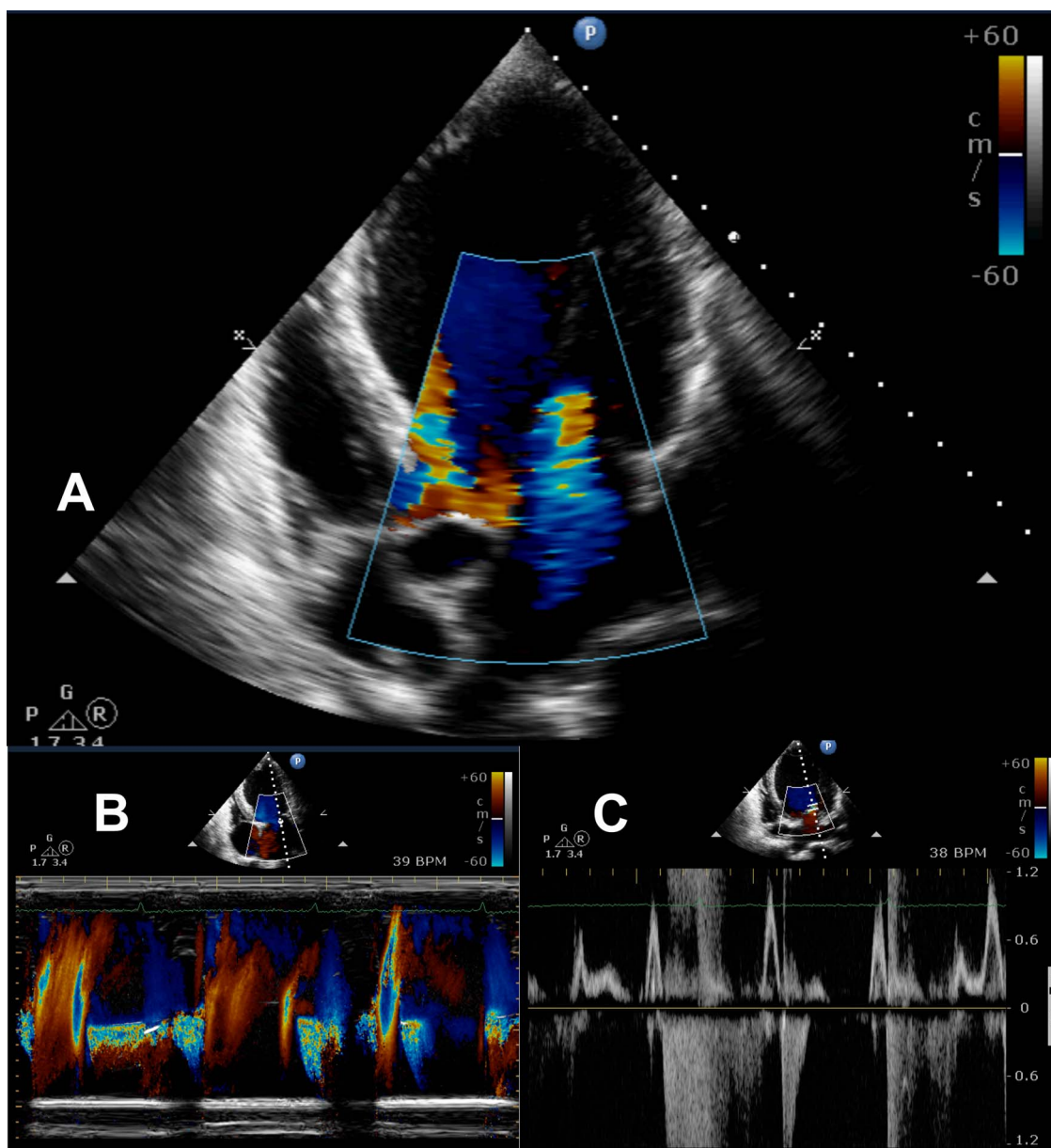


Figure 1 (A) Transthoracic echocardiogram. Colour flow imaging shows aortic and mitral regurgitation in the same frame. (B) Colour M mode across the mitral valve showing systolic and diastolic mitral regurgitation. (C) Pulsed wave Doppler at the mitral valve showing both systolic and diastolic mitral regurgitation.

from a combination of CHB and elevated LV diastolic pressure due to severe AR and LV dysfunction. The causes of diastolic MR include: atrioventricular blocks of any degree; after ventricular premature beats, pacemaker and a prolonged PR interval; during atrial tachyarrhythmias with long filling periods; restrictive cardiomyopathy; and in patients with severe AR.¹

G Rajesh, Deepak Raju, M N Krishnan

Department of Cardiology, Government Medical College, Kozhikode, Kerala, India

Correspondence to Dr Deepak Raju, Department of Cardiology, Government Medical College, Kozhikode, Kerala, India; drj980@gmail.com

Contributors All the authors made a substantial contribution to the concept, design and drafting of the article.

Competing interests None.

Patient consent Obtained.

Provenance and peer review Not commissioned; internally peer reviewed.

► Additional material is published online only. To view please visit the journal online (<http://dx.doi.org/10.1136/heartasia-2013-010388>).

To cite Rajesh G, Raju D, Krishnan MN. *Heart Asia* Published Online First: [please include Day Month Year] doi:10.1136/heartasia-2013-010388

Heart Asia 2013;**0**:172–173. doi:10.1136/heartasia-2013-010388

REFERENCE

- 1 Breitenstein A, Herzog B, Biaggi P. Diastolic mitral regurgitation in complete atrioventricular block. *Cardiovasc Med* 2011;**14**:163–4.