

## Malignant hypertension associated with use of oral contraceptives

F. G. Dunn, J. V. Jones, and R. Fife

From the University Department of Medical Cardiology, Royal Infirmary, Glasgow; and the Glasgow Blood Pressure Clinic

*A 26-year-old woman who had been taking an oral contraceptive preparation for two years developed malignant hypertension. Investigation failed to elicit any renal or other cause for her hypertension, but control of blood pressure was obtained by withdrawal of the oral contraceptive agent and antihypertensive therapy. Subsequently, after withdrawal of therapy, the blood pressure remained near normal. The patient had a previous history of hypertension during pregnancy; she was also overweight.*

Recently there has been an increasing awareness of an association between the use of oral contraceptives and hypertension. Woods (1967) described 6 cases in which pre-existing hypertension was accentuated by oral contraceptives. Other retrospective studies (Laragh *et al.*, 1967) have also suggested a relation between oral contraceptives and hypertension.

Weir *et al.* (1971, 1974) in a prospective study on a group of normotensive women over a 4-year period showed a significant rise in systolic blood pressure after 1 year on oral contraceptives and a significant rise in diastolic pressure at the end of 2 years. Discontinuation of oral contraceptives resulted in return of blood pressure to pretreatment levels within 3 months. No cases of severe or malignant hypertension were noted among these patients. A rise in systolic blood pressure has been confirmed by Fisch, Freedman, and Myatt (1972) and by Clezy *et al.* (1972) who further showed that greater increases in blood pressure occurred among those with a parental history of hypertension and those with a history of hypertension during pregnancy.

Zacherle and Richardson (1972) described a case in which severe hypertension developed while the patient was on oral contraceptives. Antihypertensive agents controlled the blood pressure satisfactorily and the blood pressure remained normal after withdrawal of all therapy. Reintroduction of a sequential oral contraceptive agent 3 years later again resulted in severe hypertension associated on this occasion with early hypertensive retinopathy and irreversible renal failure.

Harris (1969) described a case of malignant hypertension associated with oral contraceptive therapy. The patient had never been pregnant nor was there a family history of hypertension. After one year on antihypertensive therapy, the patient developed symptoms of postural hypotension. Therapy was discontinued and the patient's blood pressure subsequently remained normal. So far as we are aware, there have been no other reports showing an association between malignant hypertension and oral contraceptive agents.

### Case report

A 26-year-old woman presented in June 1966 with an 8-month history of increasing dyspnoea, a 3-month history of headaches, and two episodes of vomiting in the preceding week. During her second pregnancy in 1960 she had developed hypertension, but her blood pressure had settled to normal levels *post partum*, and investigation had failed to reveal a cause for her hypertension. In 1964, the patient had been started on the oral contraceptive agent 'Anovlar 21' (norethisterone acetate 4 mg and ethinyl oestradiol 0.05 mg) by her general practitioner. She remained on this therapy until the time of admission when her blood pressure was 230/150 mmHg (31/20 kPa). Fundi showed papilloedema, haemorrhages, exudates, and hypertensive vessel changes. She was moderately obese.

Blood urea was 33 mg/100 ml (5 mmol/l). Plasma sodium was 136 mmol/l. and chloride was 103 mmol/l. Plasma potassium on admission was low, being 2.7 mmol/l, but repeat estimations were normal at 3.9 mmol/l and 4.2 mmol/l. Creatinine clearance was 70 ml/min. There was proteinuria, but mid-stream specimens of urine contained no cells or casts and there

was no growth on culture. Chest x-ray was normal, but the electrocardiogram showed left ventricular hypertrophy with corresponding T wave inversion. Urinary catecholamines, intravenous pyelogram, and isotope renogram were all normal.

The oral contraceptive agent was discontinued and antihypertensive therapy was started with guanoxan and polythiazide. Blood pressure was rapidly controlled and the patient was discharged home on guanoxan 20 mg/day in divided doses and polythiazide 1 mg thrice weekly. At the time of discharge from hospital, blood pressure was 120/80 mmHg (16/11 kPa).

Over the next two years the patient remained on guanoxan and polythiazide, but, unfortunately, she continued intermittently to take norethisterone and ethinyl oestradiol. During this period her blood pressure was difficult to control (Fig.). Towards the end of 1968 the oral contraceptive was finally discontinued because of ankle swelling. Thereafter satisfactory blood pressure control was achieved with a smaller dose of guanoxan.

In July 1970 the patient became pregnant and, in view of her history of malignant hypertension, termination and sterilization were carried out. Before operation antihypertensive therapy was stopped and she subsequently remained off all such treatment. In July 1973 her blood pressure was 160/90 mmHg (21/12 kPa) though when seen more recently (November 1973) it was recorded as 140/110 mmHg (19/14 kPa). Fundal examination on both occasions showed only grade 1 hypertensive changes.

### Discussion

Certain differences exist between this patient and that described by Harris (1969). This patient was on an agent containing a low dose of oestrogen and

had been known to be hypertensive during a previous pregnancy. Blood pressure control with antihypertensive therapy became satisfactory only after withdrawal of oral contraceptive therapy (Fig.). After three years without treatment the blood pressure did not return fully to normal, but there was no evidence of recurrence of malignant phase hypertension.

In this case and in the cases reported by Harris (1969) and Zacherle and Richardson (1972), there was a significant time interval of 18 to 24 months between starting oral contraceptives and presentation with severe or malignant hypertension. This suggests that the rise in blood pressure while on oral contraceptives is gradual and that earlier detection of a rising blood pressure would have prevented development of malignant phase hypertension.

The mechanism of production of hypertension by oral contraceptives remains uncertain, but they apparently cause a rise in renin substrate with, in some cases, a lowering of renin levels (Laragh *et al.*, 1967). A variable rise in plasma angiotensin II has also been described (Catt *et al.*, 1971). Weir, Tree, and Fraser (1970) did not find a significant rise in plasma aldosterone among patients on oral contraceptives, though a rise in plasma aldosterone had previously been noted (Layne *et al.*, 1962).

It has also been suggested that the oestrogen component of the contraceptive agent may contribute to the development of hypertension. Oestrogen infusions have been shown to raise the systolic blood pressure (Lim *et al.*, 1970). As noted previously, 'anovlar 21' is a low dosage oestrogen preparation. Weir *et al.* (1971) found the increase in systolic blood pressure to be the same in women taking either low dose or high dose oestrogen oral contraceptive preparations.

We have recently seen two other cases of malignant hypertension occurring in young women taking oral contraceptive agents. One of these patients was normotensive immediately before starting oral contraceptives and six months later presented with malignant hypertension. In both cases full investigation failed to reveal a cause for the hypertension. Both these patients were obese, one had a history of hypertension during a previous pregnancy and the other had a parental history of hypertension.

The development of severe or malignant phase hypertension is thought to be a rare occurrence in patients taking oral contraceptive agents. However, it may well be that patients with some predisposing factor (e.g. a history of hypertension during pregnancy, a parental history of hypertension, or obesity) are at greater risk. All of our cases had at least two of these possibly adverse features. Such individuals,

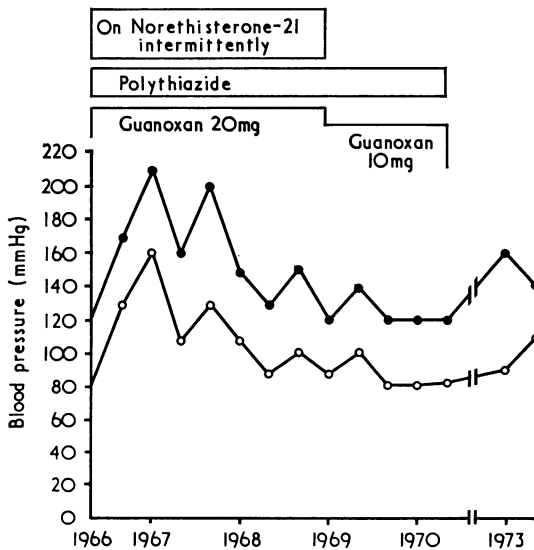


FIG. Blood pressure reading from 1966 to 1973.

even if normotensive at the time, merit a full assessment before introducing an oral contraceptive agent, and require blood pressure checks three-monthly in the first year and regularly thereafter.

We wish to thank Professor T. D. V. Lawrie and Dr. A. R. Lorimer for permission to report this case and for helpful criticism and advice.

### References

- Catt, K. J., Cran, E., Zimmet, P. Z., Best, J. B., Cain, M. D., and Coghlan, J. P. (1971). Angiotensin II blood-levels in human hypertension. *Lancet*, **1**, 459.
- Clezy, T. M., Foy, B. N., Hodge, R. L., and Lumbers, E. R. (1972). Oral contraceptives and hypertension. An epidemiological survey. *British Heart Journal*, **34**, 1238.
- Fisch, I. R., Freedman, S. H., and Myatt, A. V. (1972). Oral contraceptives, pregnancy, and blood pressure. *Journal of the American Medical Association*, **222**, 1507.
- Harris, P. W. R. (1969). Malignant hypertension associated with oral contraceptives. *Lancet*, **2**, 466.
- Laragh, J. H., Sealey, J. E., Ledingham, J. G. G., and Newton, M. A. (1967). Oral contraceptives. Renin, aldosterone, and high blood pressure. *Journal of the American Medical Association*, **201**, 918.
- Layne, D. S., Meyer, C. J., Vaishwanar, P. S., and Pincus, G. (1962). The secretion and metabolism of cortisol and aldosterone in normal and steroid-treated women. *Journal of Clinical Endocrinology and Metabolism*, **22**, 107.
- Lim, Y. L., Lumbers, E. R., Walters, W. A.W., and Whelan, R. F. (1970). Effects of oestrogens on the human circulation. *Journal of Obstetrics and Gynaecology of the British Commonwealth*, **77**, 349.
- Weir, R. J., Briggs, E., Browning, J., Mack, A., Naismith, L., Taylor, L., and Wilson, E. (1971). Blood-pressure in women after one year of oral contraception. *Lancet*, **1**, 467.
- Weir, R. J., Briggs, E., Mack, A., Naismith, L., Taylor, L., and Wilson, E. (1974). Blood pressure in women taking oral contraceptives. *British Medical Journal*, **1**, 533.
- Weir, R. J., Tree, M., and Fraser, R. (1970). Effects of oral contraceptives on blood pressure and on plasma renin, renin substrate, and corticosteroids. *Journal of Clinical Pathology*, **23**, Suppl. 3, 49.
- Woods, J. W. (1967). Oral contraceptives and hypertension. *Lancet*, **2**, 653.
- Zacherle, B. J., and Richardson, J. A. (1972). Irreversible renal failure secondary to hypertension induced by oral contraceptives. *Annals of Internal Medicine*, **77**, 83.

Requests for reprints to Dr. F. G. Dunn, University Department of Medical Cardiology, Royal Infirmary, Glasgow G4 0SF.