



Review

# Improved perioperative analgesia with ultrasound-guided ilioinguinal/iliohypogastric nerve or transversus abdominis plane block for open inguinal surgery: a systematic review and meta-analysis of randomized controlled trials

YUEXIANG WANG, MD<sup>1, 2</sup>), TAO WU, MD<sup>3, 4</sup>), MARISA J. TERRY, MD<sup>3</sup>), JASON S. ELDRIGE, MD<sup>1</sup>), QIANG TONG, MD<sup>1, 3</sup>), PATRICIA J. ERWIN, MLS<sup>5</sup>), ZHEN WANG, PhD<sup>6</sup>), WENCHUN QU, MD, PhD<sup>1, 3</sup>)\*

<sup>1</sup>) Department of Anesthesiology Pain Division, Mayo Clinic: 200 First Street SW, Rochester, MN, 55905, USA

<sup>2</sup>) Department of Ultrasound Medicine, Chinese PLA General Hospital, China

<sup>3</sup>) Department of Physical Medicine and Rehabilitation, Mayo Clinic, USA

<sup>4</sup>) Department of Physical Medicine and Rehabilitation, Sir Run Run Shaw Hospital, College of Medicine of Zhejiang University, China

<sup>5</sup>) Department of Library-Public Services, Mayo Clinic, USA

<sup>6</sup>) Center for the Science of Healthcare Delivery, Mayo Clinic, USA

**Abstract.** [Purpose] Ultrasound-guided ilioinguinal/iliohypogastric (II/IH) nerve and transversus abdominis plane (TAP) blocks have been increasingly utilized in patients for perioperative analgesia. We conducted this meta-analysis to evaluate the clinical efficacy of ultrasound-guided II/IH nerve or TAP blocks for perioperative analgesia in patients undergoing open inguinal surgery. [Subjects and Methods] A systematic search was conducted of 7 databases from the inception to March 5, 2015. Randomized controlled trials (RCTs) comparing the clinical efficacy of ultrasound-guided vs. landmark-based techniques to perform II/IH nerve and TAP blocks in patients with open inguinal surgery were included. We constructed random effects models to pool the standardized mean difference (SMD) for continuous outcomes and the odds ratio (OR) for dichotomized outcomes. [Results] Ultrasound-guided II/IH nerve or TAP blocks were associated with a reduced use of intraoperative additional analgesia and a significant reduction of pain scores during day-stay. The use of rescue drugs was also significantly lower in the ultrasound-guided group. [Conclusion] The use of ultrasound-guidance to perform an II/IH nerve or a TAP block was associated with improved perioperative analgesia in patients following open inguinal surgery compared to landmark-based methods.

**Key words:** Ultrasound, Ilioinguinal/iliohypogastric nerve, Inguinal surgery

*(This article was submitted Oct. 28, 2015, and was accepted Dec. 15, 2015)*

## INTRODUCTION

Open inguinal surgery can lead to high levels of intra- and post-operative pain. Currently available perioperative pain management options include oral or intravenous analgesics, surgical wound infiltration, and single-shot caudal blocks. However, these treatments may yield suboptimal pain control or may be limited by the significant risk of side effects. Of the commonly used oral analgesics, acetaminophen has only mild analgesic properties and has a prolonged time to onset<sup>1, 2</sup>.

\*Corresponding author. Wenchun Qu (E-mail: qu.wenchun@mayo.edu)

©2016 The Society of Physical Therapy Science. Published by IPEC Inc.

This is an open-access article distributed under the terms of the Creative Commons Attribution Non-Commercial No Derivatives (by-nc-nd) License <<http://creativecommons.org/licenses/by-nc-nd/4.0/>>.

Opioid medications are associated with somnolence, nausea, vomiting, and respiratory depression. The potential risks of caudal blocks include subcutaneous infiltration, blood vessel puncture, and dural penetration<sup>3, 4</sup>. Recently, ilioinguinal/iliohypogastric (II/IH) nerve or transversus abdominis plane (TAP) blocks have attracted interest as viable alternatives<sup>3</sup> to provide effective perioperative analgesia for open inguinal surgery. Importantly, it may provide a similar duration of analgesia as a caudal block. It uses a lower dose of local anesthetic agent (0.3 ml/kg of 0.25% bupivacaine) than that used in a caudal block (1 ml/kg)<sup>4</sup>.

There are two main techniques for II/IH or TAP blocks: the landmark-based method or the use of ultrasound guidance. Traditional landmark-based II/IH block using a fascial “click” technique has a low accuracy rate and is associated with increased procedural risks. It is difficult to identify the correct fascial plane, which may lead to the need for multiple attempts<sup>1</sup>. A failure rate of 28–45% has been reported, even in experienced hands<sup>5, 6</sup>. Weintraud et al.<sup>6</sup> reported a mere 14% accuracy rate when local anesthetic was deposited using a landmark-based approach and subsequently imaged under ultrasound to document the location of the fluid collection. No optimal injection site along the course of the II/IH nerve has been identified to improve the accuracy rate largely because of the fact that none of the sites studied have anatomical features that would make the ‘clicking’ prominent enough to be reproducible<sup>7</sup>. In addition, landmark-based techniques are associated with a substantial risk of colonic or small bowel punctures, pelvic hematoma<sup>8</sup>, and femoral nerve palsy<sup>9</sup>.

Ultrasound guidance in regional anesthesia has gained popularity in recent years<sup>10, 11</sup> and has become popular in soft tissue evaluation<sup>12–14</sup> and guided injection<sup>15</sup>. It has emerged as an excellent modality to visualize the TAP, II/IH nerves, vessels, and needle, which may be beneficial in reducing the risk of intraneural, intravascular, or intraperitoneal injections. In addition, a lower dose of local anesthetic is possible because the needle placement can be confirmed. This negates the use of additional volume to offset for inaccurate needle placement<sup>6, 16</sup>. The disadvantages of an ultrasound-guided procedure include the required special equipment, training, and increased cost. The cost-benefit justification requires assessment of efficacy with ultrasound guidance in comparison with the landmark-based approach. Multiple randomized controlled trials have been conducted, but often with a small sample size, heterogeneous designs, and conflicting outcomes. Therefore, we conducted this systematic review and meta-analysis to summarize the current evidence, as well as to evaluate the clinical efficacy of ultrasound-guided II/IH or TAP block for perioperative analgesia in pediatric and adult patients undergoing inguinal surgery.

## SUBJECTS AND METHODS

The study protocol was finalized in advance of any data collection. It defined objectives, search strategy, inclusion/exclusion criteria, data extraction, outcomes of interest, and analytical approaches. The reporting of this systematic review complies with the Preferred Reporting Items for Systematic Reviews and Meta-Analyses (PRISMA) statement<sup>17, 18</sup>.

Comprehensive searches were performed on PubMed, Ovid MEDLINE, Ovid EMBASE, Ovid Cochrane CENTRAL, Web of Science, and Scopus from the inception of the database through March 8, 2015. Each concept used a combination of controlled vocabulary (MeSH and Emtree) combined with text words for each database that uses subject heading (PubMed, MEDLINE, EMBASE, CENTRAL). Web of Science and Scopus depend primarily on text words only. The subject headings included inguinal canal, hernia, inguinal, inguinal hernia and the text words inguinal, ilioinguinal, or iliohypogastric. Similarly, the concept of pain and ultrasound guidance included nerve block, pain, and postoperative and the text words for ultrasound included echogram, ultrasound, and ultrasono. Each search was imported into EndNote (Thomson Reuters Research Soft), which is a bibliographic database manager. Duplicates were removed.

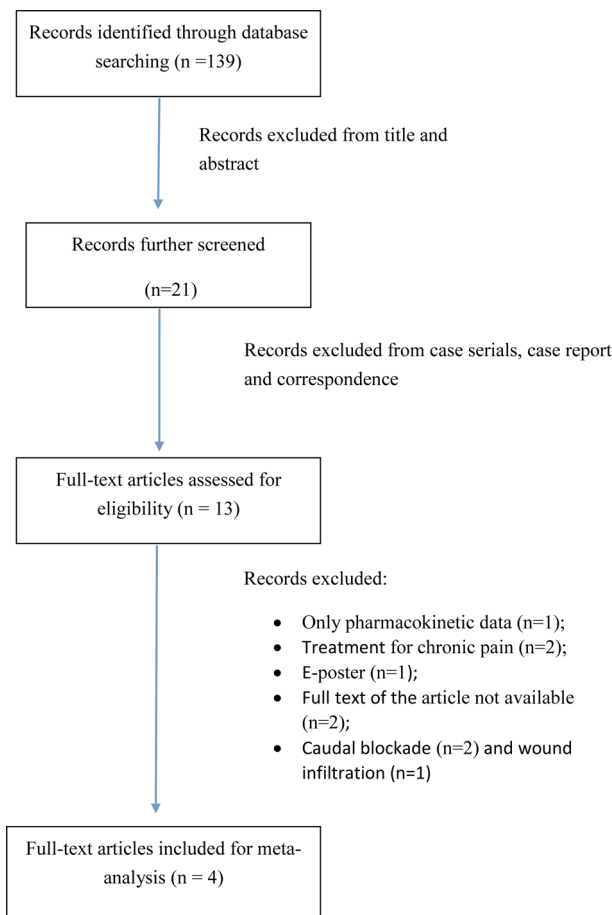
We included randomized controlled trials (RCTs), which compared the clinical efficacy of II/IH nerve or TAP block using ultrasound guidance vs. landmark-based technique for perioperative analgesia in patients following open inguinal surgery. Case series and case reports were excluded. Articles focusing on the therapeutic effect of ultrasound-guided II/IH nerve block for chronic inguinal pain were excluded. Articles focusing on the comparison of ultrasound-guided II/IH nerve or TAP block and wound infiltration were also excluded.

Two reviewers (Y.W. and M.T.), working independently and in duplicate, reviewed titles and abstracts, followed by full texts in order to exclude irrelevant studies. All conflicts were discussed and resolved with a third author (W.Q.). The same two reviewers extracted study details from the full text studies using a standardized pilot-tested form. The following data were extracted: the author, year of publication, study location, sample size, patient characteristics (gender, age), general anesthesia, regional anesthesia, timing of regional anesthesia, the surgery performed, and outcome measures, including the number of patients receiving additional analgesia during surgery and the pain scores of patients during day-stay. The reference sections of all articles were used to identify additional relevant articles.

We used the Cochrane risk of bias tool to assess the methodological quality of the included RCTs in terms of sequence generation, allocation concealment, blinding, incomplete outcome data, selective outcome reporting, and other sources of bias<sup>19</sup>.

For the continuous outcomes (pain scores), we combined the standardized mean difference (SMD) from the included studies using the Der Simonian and Laird random-effect models<sup>20</sup>. We also calculated the odds ratio (OR) for dichotomized outcomes and the pooled OR using the Der Simonian and Laird random-effect models.

We used the  $I^2$  statistic to measure the heterogeneity across the included studies. An  $I^2 > 50\%$  suggests high heterogene-



**Fig. 1.** Flowchart of enrolled studies on ultrasound-guided II/IH nerve or TAP block for peri-operative analgesia in pediatric patients undergoing inguinal surgery

ity<sup>21</sup>). Although we planned to assess publication bias by visually inspecting funnel plots and by conducting the Egger regression asymmetry test, we were unable to conduct these tests because of the limited number of included studies<sup>22</sup>). All statistical analyses were conducted using STATA version 12.1 (Stata Corp LP, College Station, TX, USA).

## RESULTS

We identified 139 articles, which included four RCTs<sup>7, 23, 24, 25</sup>) conducted between 2005 and 2014 that were eligible for this review (Fig. 1). The characteristics of the enrolled studies are described in Table 1. Patients of all ages were included. All patients underwent open surgeries, including inguinal hernia repair, orchidopexy, hydrocelectomy, and hydrocele repair. All patients received general anesthesia that was maintained by Halothane or Sevoflurane in nitrous oxide and oxygen. All patients were randomized into one of two technique groups: ultrasound-guided group and landmark-based group. All ultrasound-guided procedures were performed with a high frequency linear probe. The procedures of the control group were performed using a landmark-based technique. All II/IH nerve or TAP blocks in both groups were performed before surgery.

All of the studies reported a low risk of bias in terms of incomplete outcome data and selective outcome reporting. However, patients and care providers were not blinded to half of the included studies and the remaining studies did not report the blinding at all. We were also unable to evaluate publication bias because of the small number of studies included in the analyses. In summary, the risk of bias within the studies was medium as a result of potential publication bias and unknown quality.

Four studies were included in the meta-analysis<sup>3, 7, 23, 24</sup>) of which blocked the II/IH nerve and 1<sup>25</sup>) blocked the TAP using either an ultrasound-guided or landmark-based technique. A total of 513 patients were randomized into either one of the two technique groups for II/IH nerve or TAP block: ultrasound-guided group (n = 245) or landmark-based group (n = 259). Two hundred patients were children who were evenly randomized into either group. Of the 313 adult patients, 154 were in the ultrasound-guided group and 159 were in the landmark-based group.

Patients who received an ultrasound-guided ilioinguinal/iliohypogastric nerve block were significantly less likely to have

**Table 1.** The characteristics of the enrolled studies

First author	Publish year	Country	Sample size	Patients age	Regional anesthesia		Timing of anesthesia	Surgery	Study design	Study conclusion
					Conventional nerve block group	Ultrasound-guided II/IH nerve or TAP block				
Willschke et al. <sup>7)</sup>	2005	Austria	100	1 month–8 years	Landmark II/IH nerve block: 0.25% levobupivacaine 0.3 ml/kg	US-guided II/IH nerve block: 0.25% levobupivacaine 0.19ml/kg	Before surgery	Inguinal hernia repair, orchidopexy or hydrocele repair	RCT	Ultrasound-guided II/IH nerve blocks can be achieved with significantly smaller volumes of local anaesthetics
Aveline et al. <sup>25)</sup>	2011	France	273	31–83 years	II/IH block by the loss-of-resistance technique: 0.5% levobupivacaine (1.5 mg/kg)	Ultrasound-guided TAP block: 0.5% levobupivacaine (1.5 mg/kg)	Before surgery	unilateral open inguinal hernia repair	RCT	Ultrasound-guided TAP block provided better pain control than ‘blind’ II/IH block after inguinal hernia
Nan et al. <sup>24)</sup>	2012	China	100	4–8 years	Landmark II/IH nerve block: 0.8% lidocaine and 0.25% levobupivacaine 0.3 ml/kg	US-guided II/IH nerve block: 0.8% lidocaine and 0.25% levobupivacaine 0.2 ml/kg	Before surgery	Unilateral inguinal hernia repair, hydrocelectomy, or orchidopexy	RCT	US-guided II/IH nerve block can lower the quantity of local anesthetic and alleviate the medicinal toxicity
Demirci et al. <sup>23)</sup>	2014	Portugal	40	18–80 years	Landmark- II/IH nerve block: 20 ml of 0.5% levobupivacaine	IH/II nerve block with the US guided: 20 ml of 0.5% levobupivacaine	Before surgery	Inguinal hernia repair	RCT	US guided II/IH nerve block in adult are more effective than landmark technique

**Table 2.** Comparison between ultrasound-guided and landmark-based II/IH or TAP blocks

Outcomes	Measure	ES	95% CI	I <sup>2</sup>
*Need intraoperative additional analgesia	OR	0.21	0.09, 0.49	0.0%
*Painscores duringday-stay	SMD	-0.96	-1.68, -0.24	88.3%
*Need rescue drug	OR	0.16	0.06, 0.40	10.2%
PatientSatisfaction	OR	1.08	0.49, 2.38	n/a

\* p&lt;0.05

intraoperative additional analgesia with an OR = 0.21 (95% CI: 0.09 to 0.49;  $p < 0.001$ ;  $I^2 = 0.0\%$ ). In day-stay units, the pain score of the ultrasound-guided II/IH or TAP block group was significantly lower than that of the control group with SMD = -0.96 (95% CI: -1.68 to -0.24;  $p < 0.001$ ;  $I^2 = 88.3\%$ ). The use of rescue drugs was also significantly lower in the ultrasound-guided group (OR = 0.16; 95% CI: 0.06, 0.40;  $p < 0.001$ ,  $I^2 = 10.2\%$ ). We found no significant difference in the number of satisfied patients ( $p = 0.84$ ) (Table 2).

## DISCUSSION

This meta-analysis shows that ultrasound-guided II/IH nerve or TAP block is associated with reduced use of intraoperative additional analgesia, reduced pain in day-stay units, and reduced use of rescue drugs. This improved efficacy is most likely associated with improved proximity of needle placement and local anesthetic agent deposit to II/IH nerves. Landmark-based II/IH nerve block has a low success rate largely because of the highly variable course of the II/IH nerves as shown by cadaver studies<sup>26)</sup>. In addition, only two muscle layers could be identified in some patients in the common injection sites where the external oblique abdominal muscle is only an aponeurosis. Thus, the “click” feeling may not be a reliable way to target the fascial plane between the internal oblique abdominal muscle and the transversus abdominis muscle. In contrast, ultrasound-guided II/IH nerve block could target the II/IH nerve with more accuracy because of the high-resolution imaging of the soft tissue. The abdominal wall layers in addition to the II/IH nerves themselves can often be detected on real-time ultrasound. The real-time visualization of the injectant flow assists with the final adjustment of the needle position for optimal distribu-

tion of the local anesthetic solution to the nerves lying under the fascia of the transversus abdominis muscle. This includes the II/IH nerves.

The significant decrease in intra-operative analgesia is of great value for patients undergoing open inguinal surgery. Fentanyl and morphine are commonly used for additional intraoperative and post-anesthesia care unit (PACU) pain control. They are associated with common side effects including nausea, vomiting, and respiratory depression<sup>23</sup>. The lowest effective amount of local anesthetics for a peripheral block is particularly important in pediatric patients because of an increased risk of toxicity secondary to a higher level of the unbound fraction of the local anesthetic in a younger age. With ultrasound guidance, successful peripheral nerve blocks have been reported with a lower dose of local anesthetics, compared with non-guided techniques<sup>27</sup>. During the last two decades, ultrasonography has also been widely used to evaluate the soft tissues of the musculoskeletal system<sup>28–30</sup>.

Ultrasound guidance in regional anesthesia has been recognized as a cost-effective modality and is recommended as the preferred nerve block technique in larger anesthetic departments. Access to equipment and training has dramatically improved over the past few decades as a result of regional anesthesia fellowship programs, as well as workshops offered by various academic societies and groups. While the application of ultrasound guidance in perioperative pain control is expanding, this study provides evidence in support of using ultrasound-guided II/IH nerve or TAP blocks in managing perioperative open inguinal surgery pain.

Our study has several limitations. Although we conducted a comprehensive search of five databases, only four studies were included in this review. This small number of studies limited the statistical power of detecting significant finding. In addition, we were unable to test potential publication bias as a result of the small number of studies. Overall, using the Grades of Recommendation Assessment Development and Evaluation (GRADE) framework, the overall quality of the evidence is moderate because of the likelihood of publication bias.

In summary, the findings of this meta-analysis suggest that ultrasound-guided II/IH nerve or TAP blocks are associated with improved perioperative analgesia in patients following inguinal surgery compared with landmark-based techniques. While large medical centers may have already adopted the use of ultrasound for guidance in nerve blocks, it should be noted that more anesthesia practices may benefit from ultrasound-guided II/IH nerve or TAP block techniques in the management of perioperative pain associated with open inguinal surgeries.

## REFERENCES

- 1) Ho D, Keneally JP: Analgesia following paediatric day-surgical orchidopexy and herniotomy. *Paediatr Anaesth*, 2000, 10: 627–631. [[Medline](#)] [[CrossRef](#)]
- 2) Arana A, Morton NS, Hansen TG: Treatment with paracetamol in infants. *Acta Anaesthesiol Scand*, 2001, 45: 20–29. [[Medline](#)] [[CrossRef](#)]
- 3) Smith T, Moratin P, Wulf H: Smaller children have greater bupivacaine plasma concentrations after ilioinguinal block. *Br J Anaesth*, 1996, 76: 452–455. [[Medline](#)] [[CrossRef](#)]
- 4) Bhattarai BK, Rahman TR, Sah BP, et al.: Analgesia after inguinal herniotomy in children: combination of simplified (Single Puncture) ilioinguinal and iliohypogastric nerve blocks and wound infiltration vs. caudal block with 0.25% bupivacaine. *Kathmandu Univ Med J KUMJ*, 2005, 3: 208–211 (KUMJ). [[Medline](#)]
- 5) Lim SL, Ng Sb A, Tan GM: Ilioinguinal and iliohypogastric nerve block revisited: single shot versus double shot technique for hernia repair in children. *Paediatr Anaesth*, 2002, 12: 255–260. [[Medline](#)] [[CrossRef](#)]
- 6) Weintraud M, Marhofer P, Bösenberg A, et al.: Ilioinguinal/iliohypogastric blocks in children: where do we administer the local anesthetic without direct visualization? *Anesth Analg*, 2008, 106: 89–93. [[Medline](#)] [[CrossRef](#)]
- 7) Willschke H, Marhofer P, Bösenberg A, et al.: Ultrasonography for ilioinguinal/iliohypogastric nerve blocks in children. *Br J Anaesth*, 2005, 95: 226–230. [[Medline](#)] [[CrossRef](#)]
- 8) Jöhr M, Sossai R: Colonic puncture during ilioinguinal nerve block in a child. *Anesth Analg*, 1999, 88: 1051–1052. [[Medline](#)]
- 9) Notaras MJ: Transient femoral nerve palsy complicating preoperative ilioinguinal nerve blockade inguinal for herniorrhaphy. *Br J Surg*, 1995, 82: 854–855. [[Medline](#)]
- 10) Dillow JM, Rosett RL, Petersen TR, et al.: Ultrasound-guided parasacral approach to the sciatic nerve block in children. *Paediatr Anaesth*, 2013, 23: 1042–1047. [[Medline](#)] [[CrossRef](#)]
- 11) Wang LZ, Hu XX, Zhang YF, et al.: A randomized comparison of caudal block by sacral hiatus injection under ultrasound guidance with traditional sacral canal injection in children. *Paediatr Anaesth*, 2013, 23: 395–400. [[Medline](#)] [[CrossRef](#)]
- 12) Chung SH, You YY: Reliability of ultrasound imaging of the transversus abdominis muscle in asymptomatic subjects.

J Phys Ther Sci, 2015, 27: 1373–1375. [[Medline](#)] [[CrossRef](#)]

- 13) Bilgici A, Cokluk C, Aydın K: Ultrasound neurography in the evaluation of sciatic nerve injuries. J Phys Ther Sci, 2013, 25: 1209–1211. [[Medline](#)] [[CrossRef](#)]
- 14) Murakami T, Sakuraba K, Nagai K: Comparison of changes in the transversus abdominis and neighboring fascia in subjects with and without a history of low back pain using ultrasound imaging. J Phys Ther Sci, 2011, 23: 317–322. [[CrossRef](#)]
- 15) Wu T, Song HX, Dong Y, et al.: Ultrasound-guided versus blind subacromial-subdeltoid bursa injection in adults with shoulder pain: a systematic review and meta-analysis. Semin Arthritis Rheum, 2015, 45: 374–378. [[Medline](#)] [[Cross-Ref](#)]
- 16) Bodner G, Bernathova M, Galiano K, et al.: Ultrasound of the lateral femoral cutaneous nerve: normal findings in a cadaver and in volunteers. Reg Anesth Pain Med, 2009, 34: 265–268. [[Medline](#)] [[CrossRef](#)]
- 17) Liberati A, Altman DG, Tetzlaff J, et al.: The PRISMA statement for reporting systematic reviews and meta-analyses of studies that evaluate healthcare interventions: explanation and elaboration. BMJ, 2009, 339: b2700. [[Medline](#)] [[Cross-Ref](#)]
- 18) Higgins J, Green S: Cochrane Handbook for Systematic Reviews of Interventions Version 5.1.0. The Cochrane Collaboration, 2011.
- 19) Higgins JP, Green S: Cochrane Handbook for Systematic Reviews of Interventions. Cochrane Book Series, 2008, 187–241.
- 20) DerSimonian R, Laird N: Meta-analysis in clinical trials. Control Clin Trials, 1986, 7: 177–188. [[Medline](#)] [[CrossRef](#)]
- 21) Egger M, Davey Smith G, Schneider M, et al.: Bias in meta-analysis detected by a simple, graphical test. BMJ, 1997, 315: 629–634. [[Medline](#)] [[CrossRef](#)]
- 22) Ioannidis JP, Trikalinos TA: The appropriateness of asymmetry tests for publication bias in meta-analyses: a large survey. CMAJ, 2007, 176: 1091–1096. [[Medline](#)] [[CrossRef](#)]
- 23) Demirci A, Efe EM, Türker G, et al.: [Iliohypogastric/ilioinguinal nerve block in inguinal hernia repair for postoperative pain management: comparison of the anatomical landmark and ultrasound guided techniques]. Rev Bras Anestesiologia, 2014, 64: 350–356. [[Medline](#)] [[CrossRef](#)]
- 24) Nan Y, Zhou J, Ma Q, et al.: [Application of ultrasound guidance for ilioinguinal or iliohypogastric nerve block in pediatric inguinal surgery]. Zhonghua Yi Xue Za Zhi, 2012, 92: 873–877. [[Medline](#)]
- 25) Aveline C, Le Hetet H, Le Roux A, et al.: Comparison between ultrasound-guided transversus abdominis plane and conventional ilioinguinal/iliohypogastric nerve blocks for day-case open inguinal hernia repair. Br J Anaesth, 2011, 106: 380–386. [[Medline](#)] [[CrossRef](#)]
- 26) van Schoor AN, Boon JM, Bosenberg AT, et al.: Anatomical considerations of the pediatric ilioinguinal/iliohypogastric nerve block. Paediatr Anaesth, 2005, 15: 371–377. [[Medline](#)] [[CrossRef](#)]
- 27) Abdellatif AA: Ultrasound-guided ilioinguinal/iliohypogastric nerve blocks versus caudal block for postoperative analgesia in children undergoing unilateral groin surgery. Saudi J Anaesth, 2012, 6: 367–372. [[Medline](#)] [[CrossRef](#)]
- 28) Park SD: Reliability of ultrasound imaging of the transversus deep abdominal, internal oblique and external oblique muscles of patients with low back pain performing the drawing-in maneuver. J Phys Ther Sci, 2013, 25: 845–847. [[Medline](#)] [[CrossRef](#)]
- 29) Abe M: Ultrasound measurement of the median nerve for carpal tunnel syndrome of the non-handicapped and the handicapped. J Phys Ther Sci, 2004, 16: 107–114. [[CrossRef](#)]
- 30) Tao W, Fu Y, Hai-Xin S, et al.: The application of sonography in shoulder pain evaluation and injection treatment after stroke: a systematic review. J Phys Ther Sci, 2015, 27: 3007–3010. [[Medline](#)] [[CrossRef](#)]