

Acute Herpes Simplex Viral Esophagitis Occurring in 5 Immunocompetent Individuals With Eosinophilic Esophagitis

Dorothee Zimmermann, MD¹, Dominique H. Cribiez, MD¹, Evan S. Dellon, MD², Christian Bussmann, MD³, David Pfeifer, MD⁴, Matthias Froh, MD⁵, and Alex Straumann, MD⁶

¹Division of Gastroenterology/Hepatology, Department of Medicine, Kantonsspital, Lucerne, Switzerland

²Division of Gastroenterology and Hepatology, University of North Carolina School of Medicine, Chapel Hill, NC

³Division of Pathology, Histopathology Viollier, Basel, Switzerland

⁴Division of Pathology, Kantonsspital, Lucerne, Switzerland

⁵Division of Gastroenterology, Department of Medicine, Kantonsspital, Olten, Switzerland

⁶Swiss EoE Clinic, Olten, Switzerland

Abstract

Herpes simplex esophagitis (HSE) is an acute, severe viral infection of the esophagus, rarely occurring in immunocompetent individuals. Eosinophilic esophagitis (EoE) is a rare immune-mediated esophageal disorder. We recently observed 5 severe HSE cases in diagnosed EoE patients. Four of the 5 patients had active, untreated EoE at the time of infection, so HSE is not likely a side effect of swallowed topical corticosteroids, the first-line medical treatment of EoE. However, this coincidence of these 2 rare conditions raises the question of a causal relationship between these 2 forms of esophagitis, and whether active EoE might predispose to HSE infection.

Introduction

Eosinophilic esophagitis (EoE) is a chronic inflammatory disease of the esophagus characterized clinically by symptoms related to esophageal dysfunction and histologically by an eosinophil-predominant inflammation.¹ It is diagnosed with increasing frequency, and many patients have an atopic background.¹ Treatment of EoE aims to improve the quality of life of patients, to prevent severe esophageal injury from prolonged food bolus impactions, and to reduce the risk of esophageal tissue remodeling from uncontrolled eosinophilic inflammation. Swallowed topical steroids as well as dietary allergen avoidance have proven efficacy for EoE, and are considered first-line treatment modalities.¹

Recently, there have been isolated reports of EoE complicated by esophagitis from herpes simplex virus (HSV).²⁻⁷ Herpes simplex esophagitis (HSE) is an infection occurring quite commonly in immunocompromised patients, mainly resulting from viral reactivation.⁸ However, HSE rarely occurs in immunocompetent individuals. So far, only a limited number of case reports comprising immunocompetent individuals with well-documented HSE have been published.^{8,9} In these individuals, HSE typically occurs as a primary infection with a self-limited course.⁸ There is evidence that impairment of the mucosal barrier may enhance esophageal HSV infection.⁸ The most common symptoms are odynophagia, fever, and chest pain.⁸ Typical endoscopic findings are multiple ulcers and friable mucosa, mostly localized in the mid or distal esophagus.⁸ Diagnosis is usually established by histopathological examination with immunohistochemical staining, viral culture, or polymerase chain reaction (PCR).⁹ Serology is only useful to diagnose primary infection when seroconversion has been documented.⁹

ACG Case Rep J 2016;3(3):165-168. doi:10.14309/crj.2016.38. Published online: April 15, 2016.

Correspondence: Dorothee Zimmermann, Division of Gastroenterology/Hepatology, Department of Medicine, Kantonsspital Lucerne, Lucerne, Switzerland (dozimmermann@gmx.net).



Copyright: © 2016 Zimmermann et al. This work is licensed under a Creative Commons Attribution-NonCommercial-NoDerivatives 4.0 International License. To view a copy of this license, visit <http://creativecommons.org/licenses/by-nc-nd/4.0>.

Case Report

Case 1: A 25-year-old woman with previously diagnosed but untreated EoE presented with acute odynophagia, dysphagia, and retrosternal pain. Esophagoscopy showed deep esophageal ulcers, decreased vascular pattern, and rings. Histologic analysis revealed acute, ulcerative inflammation with granulocytic infiltration. HSV and CMV (cytomegalovirus) immunostainings were negative. Nevertheless, diagnosis of HSV infection was established with serologic analysis (high titer of HSV-1 IgM antibodies, HSV-1 IgG negative) and treatment with acyclovir was initiated. After a few days, symptoms resolved completely. Follow-up esophagogastroscope (EGD) 5 weeks later showed active eosinophilic esophagitis but no evidence of persistent HSV.

Case 2: A 27-year-old woman with a 5-year history of EoE was admitted for acute, severe dysphagia and retrosternal/epigastric pain during pregnancy. She had not been treated for EoE over the prior 2 years. EGD revealed whitish exudates in the distal esophagus and mild esophageal rings (Figure 1). Diagnosis of herpes simplex esophagitis (HSE) was established through histological analysis showing squamous epithelial cells with viral-inclusion-bodies, immunohistochemically positive for HSV (Figure 2). Blood glucose was normal and HIV serology was negative. Treatment with acyclovir and a proton pump inhibitor (PPI) was started. Symptoms resolved within 2–3 weeks and treatment with swallowed fluticasone was initiated. On follow-up EGD after 3 months, the ulcers had healed leaving esophageal scars. There were also slight furrows and decreased vascular pattern in the distal esophagus, consistent with the histologically confirmed moderately active EoE.

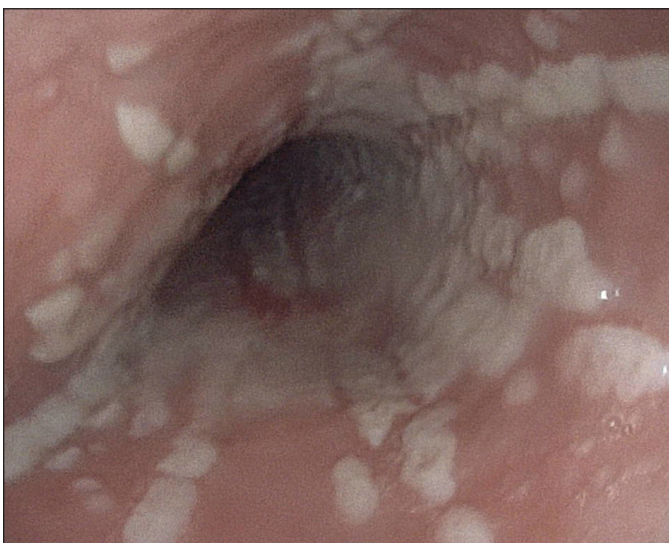


Figure 1. Patient 2 endoscopy showing white exudates in the mid- and distal esophagus during episode of HSE.

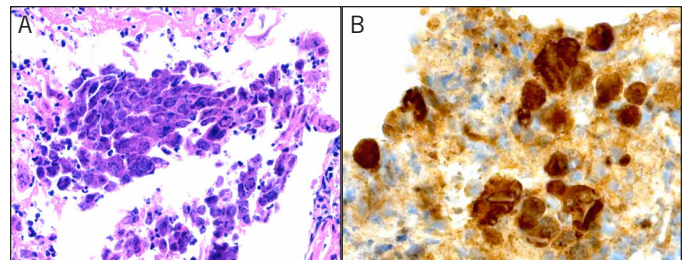


Figure 2. Patient 2 esophageal biopsy showing (A) inflammation (fibrin and neutrophils) and squamous cells with nuclear HSV inclusions, few of them multinucleated, and (B) immunohistochemical staining with positive nuclei in squamous cells.

Case 3: A 29-year-old man with a history of intolerance to certain fruits, intermittent dysphagia, and epigastric pain presented for suspected esophageal fish bone impaction. EGD showed the typical picture of EoE with mild rings in the proximal esophagus as well as furrows, white exudates, and 1 solitary ulcer in the distal esophagus. Histology showed esophageal eosinophilia (37 eosinophils per high-power field) and virus-associated alterations of the epithelium that were immunohistochemically positive for HSV. Normal blood glucose and a negative HIV test indicated immunocompetency. The next day, his symptoms worsened and he developed fever. A 7-day course of acyclovir and PPI was started. Symptoms quickly resolved and the patient stopped PPI after few weeks. At 6-month follow-up, the patient felt well, although he still experienced mild, intermittent dysphagia after ingestion of certain fruits. Because these episodes were infrequent and well tolerated, he declined follow-up EGD. This patient's history is strongly suggestive of pre-existing EoE at the time he developed HSE. However, the formal criteria for a definitive diagnosis of EoE were not fulfilled, since a follow-up EGD and a PPI trial were lacking.

Case 4: A 30-year old man with a 6-year history of EoE refractory to topical steroid treatment, but with a histologic response to systemic steroids, experienced a deterioration of symptoms (odynophagia, dysphagia, and retrosternal pain)

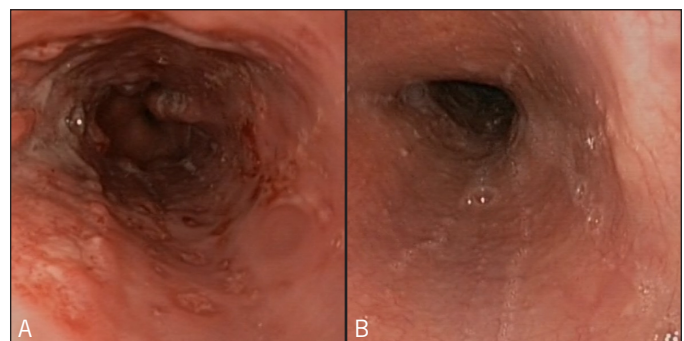


Figure 3. Patient 5 endoscopy showing (A) esophageal ulcers during episode of HSE, and (B) slight edema of esophageal mucosa 2 months after resolution of HSE.

while on treatment with oral viscous budesonide 1 mg/d for 2 months. EGD showed erosions and punctate ulcerations in the mid- and distal esophagus that were not present on prior EGDs. Histologic examination revealed signs of eosinophilic inflammation and a PCR of esophageal tissue was positive for HSV. Therapy with acyclovir was initiated and symptoms improved. On follow-up EGD 4 months later, HSE had healed, but there were signs of active EoE.

Case 5: A 28-year-old man presented with acute sore throat, retrosternal and epigastric pain, odynophagia, and fever. He had no prior esophageal symptoms. His medical history included allergic asthma and allergic rhinoconjunctivitis. EGD showed multiple ulcers in the distal esophagus (Figure 3). Biopsies taken from the ulcers were immunohistochemically positive for HSV. In biopsies taken from normal appearing mucosa, there were no signs of eosinophilic esophagitis. He was given a PPI and an antacid for 2 weeks. Since symptoms resolved spontaneously before the results of immunohistochemical analysis became available, no antiviral therapy was administered. An HIV test was negative and blood glucose was normal. Nine weeks later, when the patient was symptom-free, endoscopic follow-up showed complete healing of the ulcers, but white exudates in the distal esophagus mucosa and slight edema (Figure 3). Surprisingly, histological analysis of esophageal biopsies revealed increased intraepithelial eosinophils (100 eosinophils per high-power field). Since the patient had no symptoms, no specific therapy was initiated. He declined another follow-up endoscopy and a PPI trial. He was lost to follow-up, so it remains unclear whether this patient had true EoE, nonspecific postinfectious EoE, or PPI-responsive EoE.

Discussion

HSE is typically a severe infection that rarely occurs in healthy, immunocompetent individuals.⁸ EoE is also rare. Several case reports showing a coincidence of EoE and HSE have been published.²⁻⁷ In our patients, the order of the 2 inflammatory events varied, but it is very likely that at least 4 of the 5 patients had active EoE at the onset of HSV infection, and were not under treatment before viral infection occurred. Though incidental, non-causative coexistence cannot be ruled out, based on the current knowledge, 3 hypotheses must be considered.

First, active EoE may predispose to HSV. Untreated EoE is associated with an impaired mucosal integrity, and this barrier dysfunction could provide a route of invasion for viral agents such as HSV into the esophageal mucosa.^{2-4,10} Second, HSV infection may trigger EoE. This hypothesis is based on cases that were first diagnosed with HSE and who subsequently developed EoE, as diagnosed on follow-up examinations.³ However, 3 of our 5 patients had confirmed

EoE prior to HSV infection, which argues against this hypothesis. Third, topical corticosteroids may induce or enhance HSV infection. Administration of swallowed topical steroids frequently allows for local infection with *Candida albicans*.¹ It is therefore tempting to speculate that a steroid-induced mucosal immune deficiency could elevate the risk not only for fungal but also for viral infections. However, in 4 of our 5 patients, as well as in the majority of cases described in the literature, HSV infection occurred in the absence of topical steroid therapy, strongly refuting the hypothesis that HSE is a steroid-related complication. However, based on this small case series, we cannot rule out this possibility.

The increasing number of reports of severe HSE occurring in active, mainly untreated EoE patients indicate that untreated EoE may increase the risk of HSV infection. This suggests that appropriate anti-eosinophil treatment could potentially protect EoE patients from this severe complication. Prevention of HSE may warrant an intensive therapeutic approach for active EoE, should our hypothesis be corroborated by further evidence.

Disclosures

Author contributions: D. Zimmermann wrote the manuscript and reviewed the literature. DH Criblez, ES Dellon, and A. Straumann wrote and edited the manuscript. C. Bussmann and D. Pfeifer provided the histology information. M. Froh provided data. A. Straumann is the article guarantor.

Financial disclosure: None to report.

Informed consent was obtained for this case report.

Disclaimer: This case series was presented as a poster at the Annual Meeting of the Swiss Society of Gastroenterology; October 1–2, 2015; Interlaken, Switzerland.

Received November 14, 2015; Accepted January 15, 2016

References

1. Dellon ES, Gonsalves N, Hirano I, et al. ACG clinical guideline: Evidence-based approach to the diagnosis and management of esophageal eosinophilia and eosinophilic esophagitis (EoE). *Am J Gastroenterol*. 2013;108(5):679–92; quiz 693.
2. Žaja Franulovic O, Lesar T, Busic N, Tešović G. Herpes simplex primo-infection in an immunocompetent host with eosinophilic esophagitis. *Pediatr Int*. 2013;55(3):e38–41.
3. Squires KA, Cameron DJ, Oliver M, de Fonseca Junqueira JC. Herpes simplex and eosinophilic oesophagitis: The chicken or the egg? *J Pediatr Gastroenterol Nutr*. 2009;49(2):246–50.
4. Monsanto P, Almeida N, Cipriano MA, et al. Concomitant herpetic and eosinophilic esophagitis: A causality dilemma. *Acta Gastroenterol Belg*. 2012;75(3):361–3.
5. Sehgal S, Darbari A, Bader A. Herpes simplex virus and eosinophilic esophagitis. *J Pediatr Gastroenterol Nutr*. 2013;56(1):e1.

6. Lindberg GM, Van Eldik R, Saboorian MH. A case of herpes esophagitis after fluticasone propionate for eosinophilic esophagitis. *Nat Clin Pract Gastroenterol Hepatol*. 2008;5(9):527–30.
7. Machicado JD, Younes M, Wolf DS. An unusual cause of odynophagia in a patient with eosinophilic esophagitis. *Gastroenterology*. 2014;147(1):37–8.
8. Canalejo Castrillero E, Garcia Duran F, Cabello N, García Martínez J. Herpes esophagitis in healthy adults and adolescents: Report of 3 cases and review of the literature. *Medicine (Baltimore)*. 2010;89(4):204–10.
9. Ramanathan J, Rammouni M, Baran J, Jr., Khatib R. Herpes simplex virus esophagitis in the immunocompetent host: An overview. *Am J Gastroenterol*. 2000;95(9):2171–6.
10. Sherrill JD, Kc K, Wu D, et al. Desmoglein-1 regulates esophageal epithelial barrier function and immune responses in eosinophilic esophagitis. *Mucosal Immunol*. 2014;7(3):718–29.

Publish your work in ACG Case Reports Journal

ACG Case Reports Journal is a peer-reviewed, open-access publication that provides GI fellows, private practice clinicians, and other members of the health care team an opportunity to share interesting case reports with their peers and with leaders in the field. Visit <http://acgcasereports.gi.org> for submission guidelines. Submit your manuscript online at <http://mc.manuscriptcentral.com/acgcr>.