

# Mechanisms of regional ischaemic changes during dipyridamole echocardiography in patients with severe aortic valve stenosis and normal coronary arteries

Monica Baroni, Stefano Maffei, Marco Terrazzi, Cataldo Palmieri, Fabrizio Paoli, Andrea Biagini

## Abstract

**Objective**—Vasodilator stress echocardiography can cause myocardial ischaemia in patients with severe aortic valve stenosis and angiographically normal coronary arteries. The aim of the study was to determine the mechanism of ischaemia in this clinical model.

**Methods**—The study group comprised patients with severe aortic valve stenosis and normal coronary arteries: 25 patients (17 males, eight females; age 63 (SD 11) years) underwent a high dose (up to 0.84 mg/kg over 10 min) dipyridamole echocardiography test both before (2–4 d) and after (10–15 d) aortic valve replacement. Mean aortic pressure gradient was 96 (15) mm Hg, with a left ventricular mass index of 228 (49) g/m<sup>2</sup>. The dipyridamole echocardiography test was well tolerated and interpretable in all patients.

**Results**—Dipyridamole infusion induced chest pain in seven patients before and in no patient after surgery (28 v 0%,  $P < 0.01$ ), ST segment depression in 12 patients before and two after surgery (48 v 8%,  $P < 0.01$ ), and a transient regional dyssynergy in 10 patients before and two after surgery (40 v 8%,  $P < 0.01$ ). In the preoperative evaluation, patients with an echocardiographically positive dipyridamole echocardiography test were comparable with patients with negative test as far as left ventricular mass index [240 (67) v 230 (64) g/m<sup>2</sup>, NS] and mean aortic pressure gradient [95 (22) v 92 (21) mm Hg, NS] were concerned. When compared to the preoperative assessment, the resting echo assessment in the postoperative evaluation showed unchanged values of left ventricular mass index [pre 228 (49) g/m<sup>2</sup> v post 220 (36) g/m<sup>2</sup>, NS], but markedly decreased values of mean aortic gradient [pre 95 (15) mm Hg v post 22 (5) mm Hg,  $P < 0.01$ ] and left ventricular wall stress index [pre 134 (30) g/cm<sup>2</sup> v post 89 (19) g/cm<sup>2</sup>].

**Conclusions**—Dipyridamole echocardiography is a suitable clinical technique for assessing the ischaemic vulnerability of the left ventricle in severe aortic valve stenosis with angiographically normal coronary arteries. The frequent disappearance of the ischaemic response early after aortic valve replacement suggests that haemodynamic factors such as com-

pressive diastolic wall stress or afterload reduction are important components of myocardial ischaemic vulnerability under these circumstances.

(Heart 1996;75:492-497)

Keywords: aortic stenosis; dipyridamole; echocardiography.

Experimental<sup>1-3</sup> and clinical evidence<sup>4-6</sup> shows that the subendocardium of patients with chronic pressure overload from severe aortic valve stenosis is susceptible to ischaemia, even in the presence of normal epicardial coronary arteries. In a previous study from our laboratory, we showed that the dipyridamole echocardiography test may be considered a safe, feasible, and reasonably accurate tool for non-invasive identification of coronary artery disease in patients with aortic valve stenosis.<sup>7</sup> In particular, a dipyridamole induced transient dyssynergy had excellent sensitivity (100%) but limited specificity (74%) for the detection of angiographically assessed coronary artery disease.<sup>7</sup>

At least two possible and not mutually exclusive explanations may account for these "false positive" stress echocardiographic results (that is, a regional dyssynergy occurring with angiographically normal coronary arteries): (1) left ventricular hypertrophy, which may reduce coronary flow reserve per se<sup>8</sup> and alter the lower range of coronary subendocardial autoregulation<sup>9,10</sup>; and (2) haemodynamic factors such as increased systolic pressure, prolongation of ejection, and compressive diastolic radial wall stress which may play a critical role in eliciting ischaemia in a hypertrophic left ventricle.<sup>11,12</sup> We designed the present study to determine the underlying mechanisms (morphological versus haemodynamic) of myocardial ischaemia in patients with aortic valve stenosis and no significant coronary artery disease. A dipyridamole echocardiography test was performed in patients with aortic valve stenosis and angiographically normal coronary arteries, both immediately before (two to four days) and soon after (10 to 15 days) aortic valve replacement, when the haemodynamic variables but not left ventricular mass or left ventricular structure had changed in comparison to the preoperative assessment.<sup>13</sup>

CNR Institute of  
Clinical Physiology,  
Pisa, Italy  
M Baroni  
S Maffei  
M Terrazzi  
C Palmieri  
F Paoli  
A Biagini

Correspondence to:  
Dr Monica Baroni MD,  
CNR Institute of Clinical  
Physiology, Via P Savi 8  
56100 Pisa, Italy.

Accepted for publication  
11 October 1995

## Methods

### STUDY PATIENTS

Between 1989 and 1993, 63 hospital inpatients with aortic valve stenosis referred to our cardiovascular department were initially considered for a dipyridamole echocardiography test. All patients had a complete physical examination, chest x ray, and 12-lead electrocardiogram. The diagnosis of aortic valve stenosis was always confirmed by cross sectional and Doppler echocardiography (Aloka SSD 870). A 2.5 MHz probe with continuous wave and pulsed wave Doppler or a non-imaging transducer or both was used. Aortic valve gradient was measured through the estimation of peak aortic velocity recorded by continuous wave Doppler from the apical, suprasternal, or right parasternal windows.<sup>14</sup> The highest velocity was used for analysis of peak pressure gradient and mean pressure gradient through the aortic valve. Left ventricular outflow tract velocity was measured from the apex by pulsed wave Doppler with the sample volume just proximal to the aortic valve. Left ventricular outflow tract diameter was measured by cross sectional echo. Aortic valve area was derived from continuity equation. Measurements were done on the average of five cardiac cycles. Left ventricular mass index was calculated according to the method proposed by the American Society of Echocardiography corrected by Devereux formula.<sup>15</sup> End diastolic diameter and per cent fractional shortening were measured according to the recommendations of the American Society of Echocardiography.<sup>16</sup> Wall stress index was derived non-invasively from data obtained from echocardiographic M mode measurements of left ventricular diameter and posterior wall thickness (calculated at end diastole) and the systolic blood pressure, according to the formula proposed by Quinones *et al.*<sup>17</sup> In the calculation, the value of pressure gradient across the stenotic valve and the prosthetic valve was added to systolic blood pressure measured by cuff sphygmomanometer.

Exclusion criteria for dipyridamole echocardiography were: a technically poor acoustic window ( $n = 5$ ); severe global left ventricular dysfunction with ejection fraction  $< 35\%$  ( $n = 6$ ); and severe concomitant asthmatic disease requiring chronic theophylline treatment ( $n = 0$ ). No patient refused to enter the study. In 17 patients it was not possible to carry out the test after surgery for one of the following reasons: (1) deterioration of the acoustic window ( $n = 4$ ); (2) occurrence of perioperative complications ( $n = 5$ ); (3) unwillingness of the patient to repeat the study ( $n = 8$ ); or (4) presence of coronary artery disease ( $n = 10$ ). A vessel was considered to have significant obstruction if its quantitatively assessed diameter was narrowed by 50% or more in comparison with the prestenotic tract.

Overall, 25 patients (age 63.3 (SD 11.2) years, range 19 to 78; 17 male, eight female) finally entered the study. Cardiac catheterisation was always performed within one week of dipyridamole echocardiography. All patients

were given a mechanical prosthetic aortic valve replacement (St Jude Medical).

All patients gave their informed consent before entering the study.

### DIPYRIDAMOLE ECHOCARDIOGRAPHY TEST

Intravenous dipyridamole was infused at the dose of 0.56 mg/kg in 4 min followed by 4 min of no dose, and then 0.28 mg/kg in 2 min, according to a generally accepted protocol<sup>18</sup> already described in detail in previous studies from our laboratory.<sup>19</sup> Baseline evaluation included 12-lead electrocardiogram, blood pressure evaluation, and all possible standard echocardiographic views. During the procedure, blood pressure and 12-lead electrocardiograms were taken every 2 min; cross sectional echocardiograms were recorded continuously and up to 5 min after the end of dipyridamole infusion. Patients were instructed to avoid coffee and tea for at least 3 h before the test and to stop all cardiac medications for at least 24 h. Aminophylline (up to 240 mg over 3 min) was injected, as needed. Electrocardiographic tracings were considered diagnostic of myocardial ischaemia when an ST segment shift of at least 0.20 mV, 0.08 s after the J point, was recorded.

Cross sectional echocardiographic videotaped images obtained by a commercially available scanner (Aloka SSD 870) were analysed by two independent observers unaware of other data; in case of disagreement, a third observer whose judgement was binding reviewed the data. Off-line digital acquisition of videotaped images for side by side rest-stress comparison in a cine-loop format was performed by an array processor based computer for medical image processing (Mipron, Kontron). Wall motion abnormalities were evaluated by dividing the left ventricle into 16 segments according to the recommendations of the American Society of Echocardiography,<sup>16</sup> and were graded (based on the subjective impression) as normal-hyperkinetic (score = 1), hypokinetic (score = 2), akinetic (score = 3), or dyskinetic (score = 4). The wall motion score index was derived by summation of individual segment scores divided by the number of interpreted segments. Inadequately visualised segments were not scored. Positivity of the test was linked to the detection of a transient dyssynergy, absent or of lesser degree during the basal examination.<sup>19</sup> Regions already akinetic or dyskinetic in the baseline study were not considered for analysis. The test was stopped when new obvious wall motion abnormalities were detected. In positive tests, the dipyridamole time, that is the time in minutes from the beginning of drug infusion to the development of the stress induced dyssynergy, was also evaluated.

### ANGIOGRAPHIC STUDY

Patients underwent ventriculography (when feasible) and selective right and left coronary arteriography using either the Judkins or the Sones technique; multiple views of each vessel were obtained. One independent observer (CP), blind to stress test results, analysed the

coronary angiograms. In case of any irregularity of the vessel, a caliper assisted quantitative evaluation was performed after magnification of the region of interest.

The per cent diameter stenosis was measured in the region in which it appeared most severe. A vessel was considered to have significant obstruction if its diameter was reduced by 50% or more. The previously assessed intra-observer and interobserver variability in our laboratory were 7% and 6%, respectively.<sup>20</sup>

Left ventricular end diastolic pressure values were obtained in only 12 patients.

#### STATISTICAL ANALYSIS

Continuous variables are expressed as mean (SD). Differences in continuous variables were evaluated by the Student *t* test for paired values. Differences in dichotomous variables were evaluated by using the  $\chi^2$ ; a Fisher's exact test was used when appropriate. A *P* value < 0.05 was the predetermined level of significance.

#### Results

All patients had severe aortic valve stenosis with mild regurgitation. The aetiology was degenerative. One patient had a bicuspid valve.

Sixteen patients (64%) had history of chest pain, nine (36%) had syncope, and 14 (57%) had dyspnoea. None had a clinically documented previous myocardial infarction. Seven patients were New York Heart Association (NYHA) class II. The transvalvar aortic pressure gradient evaluated by Doppler echocardiography was 96 (15) mm Hg (table 1); the aortic valve area was 0.65 (0.11) cm<sup>2</sup>.

No significant difference in terms of left ventricular-aortic pressure gradient was found between patients with angina and patients without: 94 (12) mm Hg *v* 92 (10) mm Hg.

Mean left ventricle end diastolic pressure (obtained only in 12 patients) was 17 (12) mm Hg. No patient had a significant narrowing of coronary arteries (> 50%). In one patient prominent calcifications of the proximal portion of left anterior descending coronary artery and a hypoplastic right coronary artery were found; two patients had irregularities of the

left anterior descending artery and two had narrowing of the right coronary artery of less than 50%. In no patient was an aortocoronary bypass graft performed.

#### PREOPERATIVE RESTING ECHOCARDIOGRAPHY FINDINGS

Nineteen patients had normal resting wall motion, and six had abnormal motion, consisting of anterior septal hypokinesia in four, inferior hypokinesia in one, and diffuse global hypokinesia in one. The mean resting wall motion score index (evaluated on all 25 patients) was 1.07 (0.2). The mean left ventricular mass index was 228.5 (49.3) g/m<sup>2</sup>. The estimated left ventricular wall stress index was 133.9 (30.2) g/cm<sup>2</sup> (table 1).

#### DIPYRIDAMOLE ECHOCARDIOGRAPHY TEST

There were no serious complications related to dipyridamole infusion, and the test was completed in all patients both before and after surgery. Two dimensional echocardiographic studies were adequate for analysis in all patients. Only mild changes in systemic haemodynamics—consisting of a small though statistically significant increase in heart rate—occurred during dipyridamole infusion, both before and after surgery (table 2). In the post-operative evaluation, a slight rise in resting heart rate was detectable in comparison to the preoperative assessment, probably due to the relative anaemia.

#### PREOPERATIVE EVALUATION

Ten patients (40%) had a positive dipyridamole echocardiography test (table 3). Nine patients (36%) developed transient dyssynergy with ST segment depression or chest pain, while one patient (4%) showed only a transient dyssynergy.

Fifteen patients did not develop transient dyssynergy during dipyridamole infusion and therefore had a negative test: one patient (4%) had chest pain without associated dyssynergy or electrocardiographic changes; four patients (16%) had diagnostic ST segment depression without dyssynergy (table 3).

In the 15 patients with a negative dipyridamole echocardiography test, the rest and peak stress wall motion score index was 1.09 (0.26). In the 10 patients with a positive test, the wall motion score index was 1.05 (0.9) at rest and 1.15 (0.22) at peak stress (*P* < 0.01). The dipyridamole time in the 10 patients with a positive test was 9.4 (1.35) min.

No statistically significant differences in terms of left ventricular-aortic pressure gradient [positive 95 (22) mm Hg *v* negative 92 (21) mm Hg, NS], mean aortic valve area [positive 0.65 (0.11) cm<sup>2</sup> *v* negative 0.66 (0.2) cm<sup>2</sup>, NS], or left ventricular mass index [positive 240.4 (67.7) g/m<sup>2</sup> *v* negative 229.7 (64.3) g/m<sup>2</sup>, NS] were found between the group with positive test and the group with a negative one (table 3).

No correlation between a positive test and a history of chest pain was found: 16 patients had a clinical presentation with chest pain, but only eight (50%) had a positive test, while five

Table 1 Haemodynamic indices before and after aortic valve replacement. Values are mean (SD)

	Preoperative	Postoperative
Mean aortic gradient (mm Hg)	96.0 (15.0)	22.0 (0.5)*
Left ventricular mass index (g/m <sup>2</sup> )	228.5 (49.0)	219.7 (36.1)
Left ventricular wall stress index (g/cm <sup>2</sup> )	133.9 (30.2)*	89.4 (18.8)*

\**P* < 0.05 *v* preoperative value.

Table 2 Haemodynamic response to dipyridamole stress. Values are mean (SD)

	Preoperative		Postoperative	
	Rest	Dipyridamole	Rest	Dipyridamole
SBP (mm Hg)	115 (5)	121 (6)	119 (6)	124 (7)
DBP (mm Hg)	73 (11)	80 (13)	68 (8)	77 (8)
HR (beats/min)	72 (12)	90 (11)*	85 (11)	95 (8)*

SBP, systolic blood pressure; DBP, diastolic blood pressure; HR, heart rate.

\**P* < 0.05 *v* rest.

Table 3 Preoperative dipyridamole echocardiography test results. Values are mean (SD)

	Patients with positive test (10)	Patients with negative test (15)
Mean aortic gradient (mm Hg)	95.0 (22.0)	92.0 (21.0)
Left ventricular mass index (g/m <sup>2</sup> )	240.4 (67.7)	229.7 (64.3)
Dipyridamole induced dyssynergy	10.0	0.0
Dipyridamole induced angina	5.0	2.0
Dipyridamole induced ST segment depression	8.0	4.0

No significant differences.

(55%) of the nine patients without evidence of angina had a positive test.

A typical example of not significantly narrowed coronary arteries and a positive test is shown in fig 1.

#### POSTOPERATIVE EVALUATION

Patients underwent the dipyridamole echocardiography test, under the same conditions, 10–15 d after aortic valve replacement. Sixteen patients had normal resting wall motion (including patients with postsurgical septum), while nine had abnormal resting wall motion consisting of anterior septal hypokinesia in four, inferior hypokinesia in one, lateral hypokinesia in one, and diffuse global hypokinesia in three.

Only two patients (8%) had a positive test (one woman, one man). Both had transient dyssynergy and ST segment depression, as they did during the test performed preoperatively. One of them had abnormal resting wall motion.

The incidence of dipyridamole induced transient dyssynergy, ST segment depression, and chest pain, both before and after aortic valve replacement, is shown in fig 2.

In the two patients with a positive test after aortic valve replacement, the left ventricular mass index was 345.2 g/m<sup>2</sup> in one (the woman) and 254 g/m<sup>2</sup> in the other. In the female patient the aortic stenotic valve was replaced with a St Jude M 23A mechanical

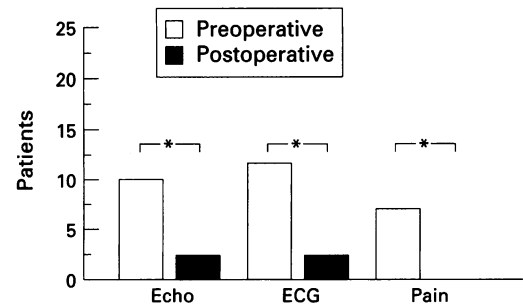


Figure 2 Bar graph showing the incidence of dipyridamole induced transient dyssynergy (ECHO), ST segment depression (ECG), and chest pain (PAIN) both before (empty columns) and after (filled columns) aortic valve replacement. Asterisk indicates statistical significance:  $P < 0.01$ .

prosthesis and in the male with a St Jude M 25A.

The pressure gradient across the native aortic valve and across the prosthetic valve were respectively: 149 v 30 mm Hg and 85 v 18 mm Hg. The left ventricular wall stress index was 154.8 g/cm<sup>2</sup> (preoperative) v 64.2 g/cm<sup>2</sup> (postoperative) in the female patient, and 95.34 v 64.18 g/cm<sup>2</sup> in the male patient.

In the 23 patients with a negative dipyridamole echocardiography test, the rest and peak stress mean wall motion score index was 1.17 (0.3). In the two patients with a positive test, the mean index was 1.15 (0.2) at rest and 1.5 at peak stress.

The dipyridamole time in the two patients with positive test was 10 min.

#### POSTOPERATIVE RESTING ECHOCARDIOGRAPHY FINDINGS

When compared to preoperative assessment, the resting echo assessment in the postoperative evaluation showed unchanged values of left ventricular mass index [pre, 228 (49) g/m<sup>2</sup> v post, 220 (36) g/m<sup>2</sup>, NS] and a markedly decreased mean aortic gradient [pre 95 (15) mm Hg v post 22 (5) mm Hg,  $P < 0.01$ ] and left ventricular wall stress index [pre 134 (30) g/cm<sup>2</sup> v post 89 (19) g/cm<sup>2</sup>].

#### Discussion

Severe aortic stenosis is often accompanied by inducible myocardial ischaemia detectable with vasodilator stress echocardiography, even in the absence of angiographically significant coronary artery disease. Aortic valve replacement immediately improves left ventricular haemodynamics and relieves the symptomatic, electrocardiographic, and echocardiographic evidence of ischaemia at a time when left ventricular hypertrophy is still increased at preoperative values.

#### MECHANISM OF MYOCARDIAL ISCHAEMIA IN AORTIC VALVE STENOSIS WITH ANGIOGRAPHICALLY NORMAL CORONARY ARTERIES

Transient subendocardial underperfusion is the most likely explanation for chest pain, ST segment depression, and regional dyssynergy frequently elicited by dipyridamole infusion in

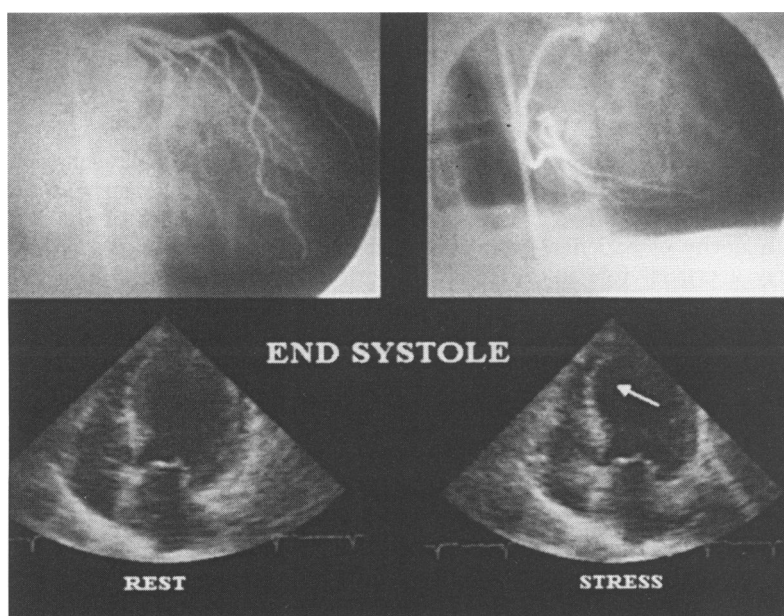


Figure 1 Top: images of left coronary artery and right coronary artery with irregularities of the lumen and the quantitative evaluation; bottom: the images of positive echo stress in the same patients described.

patients with aortic stenosis. Such underperfusion may occur in spite of angiographically normal coronary arteries because of the presence of left ventricular hypertrophy and haemodynamic factors, such as increased systolic pressure, prolongation of the ejection phase, and raised intramural pressure compressing the coronary arteries, which may exhaust the vasodilator reserve of the subendocardium under resting conditions, since the myocardial oxygen demands of the subendocardium are greater than those of the subepicardium.<sup>1-3</sup> At that point, infusion of a vasodilator decreases subepicardial resistance, thus resulting in absolute or relative subendocardial underperfusion.<sup>3</sup> If this underperfusion is transmurally extended so as to involve a critical mass of at least 30–40% of the entire wall thickness, a transient dyssynergy is detectable.<sup>21</sup>

#### LEFT VENTRICULAR HYPERTROPHY AS A CAUSE OF ISCHAEMIA IN AORTIC STENOSIS

Experimental data show that in dogs with marked left ventricular hypertrophy, an ischaemic stress such as exercise, pacing, or pharmacologically induced vasodilatation can induce a redistribution of coronary blood flow from the subendocardium, with deterioration of contractile function.<sup>1,3</sup> Marcus *et al*<sup>5</sup> have shown a reduction in the velocity of coronary blood flow during reactive hyperaemia at the time of operation in patients with severe aortic valve stenosis. Such mechanisms might account for the ischaemic response during dipyridamole observed in these patients. The “morphological” mechanism of induced ischaemia was almost certainly the one prevailing in the two patients who had a positive response after aortic valve replacement. At that time, left ventricular mass index was unchanged in comparison with preoperative values, and previous studies by Monrad *et al* have shown that changes in myocardial ultrastructure—such as proliferation of fibroblasts and collagen fibres in the interstitial space—had no time to regress.<sup>13</sup>

#### HAEMODYNAMIC MECHANISMS AS A CAUSE OF ISCHAEMIA IN AORTIC VALVE STENOSIS

In eight patients (80% of the subset with a preoperative positive response) the test turned negative soon after aortic valve replacement. This suggests that in the majority of patients haemodynamic factors play a crucial role in determining the ischaemic vulnerability of the hypertrophic left ventricle. Operation immediately reduces the aortic gradient and wall stress, and therefore the compressive radial forces,<sup>12</sup> while in the short term it cannot affect structural alterations which, in chronic left ventricular hypertrophy, might lead to reduced reserve—such as rarefaction of the capillary bed or interstitial fibrosis.<sup>13</sup> This interpretation is consistent with studies showing that, in dogs with experimentally induced left ventricular hypertrophy, adenosine reduces the endocardial/epicardial blood flow ratio and does not greatly increase the blood flow to the endocardium, and that this effect is blunted by a

reduction of diastolic endocardial radial wall stress (which can interfere with endocardial coronary reserve).<sup>12</sup> Another equally valid reason for lower ischaemic vulnerability of the hypertrophic left ventricle immediately after valve replacement is the decrease in oxygen need due to afterload reduction

#### POSSIBLE MECHANISMS OF REGIONAL DYSFUNCTION DURING VASODILATOR STRESS

An unexpected finding of the present study was the regional nature of the ischaemic changes, which should be specific for the presence of coronary atherosclerosis and not of diffuse ischaemia due to a global imbalance between myocardial oxygen supply and demand.

An explanation for this finding might be that coronary luminal narrowing was assessed by a less than ideal method (coronary angiography), and analysed in a less than ideal fashion with caliper assessment of per cent diameter stenosis. Although this method is inherently inaccurate, especially for the assessment of diffuse disease, its simplicity and ease of execution favour its continuing use. However, the presence of occult diffuse coronary disease was not likely in many of these patients, in view of data provided by necropsy studies<sup>11</sup> and intracoronary ultrasound<sup>22</sup> in patients of similar age (average 63 years). In addition, five patients had some “non-critical” coronary narrowing, which could easily translate in a critical reduction in regional coronary flow reserve.

In the extreme haemodynamic conditions of the patients studied (mean gradient 96 mm Hg), even the increase of almost 20 beats/min induced by dipyridamole, in a maximally vasodilated bed, can be a sufficient stimulus to evoke regional ischaemia.

The underestimation of the angiographically mild or inapparent coronary stenoses can also explain another finding of this study: the absence of correlation of the ischaemic changes with the haemodynamic severity of the aortic stenosis preoperatively. The normalisation of the afterload after valve replacement is sufficient in most cases to reduce the functional significance of these mild atherosclerotic changes.

In conclusion, the dipyridamole echocardiography test is a suitable clinical tool to assess the ischaemic vulnerability of the left ventricle in severe aortic stenosis with angiographically normal coronary arteries. The frequent disappearance of the ischaemic response early after aortic valve replacement suggests that haemodynamic factors are a more important component of the vulnerability in chronic left ventricular hypertrophy than structural alterations.

This study was partially supported by a grant from the National Research Council (CNR) of Italy

1 Nakano K, Corin WJ, Sapann JF, Biederman RWW, Denslow S, Carabello BA. Abnormal subendocardial blood flow in pressure overload hypertrophy is associated with pacing-induced subendocardial dysfunction. *Circ Res* 1989;65:1555–64.

2 Hittinger L, Shannon R, Kohin S, Manders T, Kely P, Vatner S. Subendocardial dysfunction during exercise and recovery in dogs with left ventricular hypertrophy [abstr]. *Circulation* 1989;80:299.

- 3 Bache RJ, Vrobel TR, Arentzen CE, Ring WS. Effect of maximal coronary vasodilatation on transmural myocardial perfusion during tachycardia in dogs with left ventricular hypertrophy. *Circ Res* 1981;49:742-50.
- 4 Bertrand ME, LaBlanche JM, Tilmant PY. Coronary sinus blood flow at rest and during isometric exercise in patients with aortic valve disease. Mechanism of angina pectoris in presence of normal coronary arteries. *Am J Cardiol* 1981;47:199-205
- 5 Marcus ML, Dot DB, Hiratzka LF, *et al*. Decreased coronary reserve. A mechanisms for angina pectoris in patients with aortic stenosis and normal coronary artery disease. *N Engl J Med* 1982;307:1362-6.
- 6 Smucker ML, Tedesco CL, Manning SB. Demonstration of an imbalance between coronary perfusion and excessive loads as a mechanism of ischemia during stress in patients with aortic stenosis. *Circulation* 1988;78:573-82.
- 7 Maffei S, Baroni M, Sgorbini L, *et al*. Dipyridamole echocardiography test in patients with severe aortic valve stenosis, as screening tool of a coexisting coronary artery disease [abstr]. *Eur Heart J* (suppl) 1994;15:68
- 8 Vogt M, Motz WH, Schwartzkopf B, Strauer BE. Pathophysiology and clinical aspects of hypertensive hypertrophy. *Eur Heart J* 1993;14(suppl D):2-7.
- 9 Harrison DG, Florentine MS, Brooks LA, Cooper SM, Marcus ML. The effect of hypertension and left ventricular hypertrophy on the lower range of coronary autoregulation. *Circulation* 1988;77:1108-15.
- 10 Polese A, DeCesare N, Montorsi P, *et al*. Upward shift of the lower range of coronary flow autoregulation in hypertensive patients with hypertrophy of the left ventricle. *Circulation* 1991;83:845-53.
- 11 Braunwald E. Valvular heart disease. In: Braunwald E, ed. *Heart disease. A textbook of cardiovascular medicine*. 4th ed. Philadelphia: WB Saunders Co, 1992:1035-43.
- 12 Hittinger L, Mirsky I, Shen YT, *et al*. Hemodynamic mechanisms responsible for reduced subendocardial coronary reserve in chronic pressure overload left ventricular hypertrophy [abstr]. *Circulation* 1994;90:I-258.
- 13 Monrad ES, Hess OM, Murakami T, *et al*. Time course of regression of left ventricular hypertrophy after aortic valve replacement. *Circulation* 1988;77:1345-50.
- 14 Skjaerpe T, Hegrenaes L, Hatle L. Non-invasive estimation of valve area in patients with aortic stenosis by Doppler ultrasound and two-dimensional echocardiography. *Circulation* 1985;72:810-8.
- 15 Devereux RB, Koren MJ, Okin PM, Kligfield P. Methods for detection of left ventricular hypertrophy: application to hypertensive heart disease. *Eur Heart J* 1993;(suppl D):8-15.
- 16 American Society of Echocardiography Committee on standards, subcommittee on quantitation of two-dimensional echocardiograms: Schiller NB, Shah PM, Crawford M, *et al*. Recommendations for quantitation of the left ventricle by two-dimensional echocardiography. *J Am Soc Echocardiogr* 1989;2:358-67.
- 17 Quinones MA, Mokotoff DA, Nouri S, Winters WL, Miller RR. Noninvasive quantification of left ventricular wall stress. Validation of method and application to assessment of chronic pressure overload. *Am J Cardiol* 1980;45:782-90.
- 18 Picano E, Marini C, Pirelli S, *et al*, on behalf of the EPIC study group. Safety of intravenous high-dose dipyridamole echocardiography. *Am J Cardiol* 1992;70:252-6.
- 19 Biagini A, Maffei S, Baroni M, *et al*. Early assessment of coronary reserve after by-pass surgery by dipyridamole transesophageal echocardiography stress test. *Am Heart J* 1990;120:1097-101.
- 20 Chunzeng L, Picano E, Pingitore A, *et al*. Complex coronary artery lesion morphology influences results of stress echocardiography. *Circulation* 1995;91:1669-75.
- 21 Weiss JL, Bulkley BH, Hutchins GM, Mason SJ. Two-dimensional echocardiography recognition of myocardial injury in man: comparison with postmortem studies. *Circulation* 1981;63:401-6.
- 22 Nissen SE, Gurley JG, Grims CL, *et al*. Intravascular ultrasound assessment of lumen size and wall morphology in normal subjects and patients with coronary artery disease. *Circulation* 1991;84:1087-99.