

# Transcatheter occlusion of the arterial duct with Cook detachable coils: early experience

Orhan Uzun, Stephen Hancock, Jonathan M Parsons, David F Dickinson, John L Gibbs

## Abstract

**Objective**—To assess the effectiveness of modified, controlled release Gianturco coils for transcatheter occlusion of the arterial duct.

**Design**—Prospective study, approved by local medical ethics committee.

**Setting**—Tertiary paediatric cardiac centre.

**Patients**—43 patients with left to right shunting through the arterial duct, two of whom had a residual leak after surgical ligation and three had residual shunting after previous Rashkind umbrella implantation.

**Intervention**—Transcatheter delivery of one or more coils to the arterial duct.

**Main outcome measures**—Complete occlusion of the arterial duct, based on intention to treat and judged by Doppler echocardiography. Absence of flow disturbance in the branch pulmonary arteries and the descending aorta following the procedure. Assessment of cost of the disposable items used.

**Results**—At a median follow up period of three months complete duct occlusion was achieved in 37 (86%) of the 43 patients. No flow disturbance in the branch pulmonary arteries or the descending aorta was detected in any patient. The median cost of disposable items used during the procedure was £342.

**Conclusions**—The Cook detachable coil is an effective and financially attractive alternative to the Rashkind umbrella for closure of the arterial duct.

(Heart 1996;76:269-273)

Keywords: coil occlusion; arterial duct (ductus arteriosus).

Transcatheter occlusion of the arterial duct (ductus arteriosus) has been attempted with several different devices with varying success. Despite initial enthusiasm, none of these techniques has proven to be superior to surgical ligation when judged by complete occlusion of the duct or cost-effectiveness. The Rashkind double umbrella was considered to be the treatment of choice for patients with isolated left to right ductal shunting at our centre between 1989 and 1994; we found residual ductal shunting in 21% of patients and the mean cost of consumables for the procedure

was £3198. This incidence of residual shunting and the high cost of the procedure led us to investigate an alternative device. Early experience at other centres using simple Gianturco embolisation coils has met with some success<sup>1-4</sup> but the absence of any mechanism to control the release of the coil has led to a reluctance for the technique to be widely employed. The Cook detachable coil (Cook UK Ltd) is a Gianturco coil modified such that it is attached to a delivery wire which allows control over both the positioning of the coil and its release. This design has the additional advantage that retrieval of the coil is possible up until the moment it is released from the delivery wire. The coils are available with diameters of 5 or 8 mm and in variable lengths which result in the deployed coil having three, four, or five turns.

## Methods

### PATIENTS

All patients referred to our centre with a left to right ductal shunt as their primary cardiac anomaly were considered for entry to the study, but patients who were in overt heart failure were excluded. In each case written information explaining the study and the alternative choices of surgery or umbrella implantation in place of coil occlusion was provided. The study was approved by the local medical ethics committee and informed consent was obtained in each case.

The patient's ages ranged between six weeks and 67 years (median 30 months) and their weights between 2.7 and 90 (median 13) kg. Two patients also had a small ventricular septal defect, three had previous Rashkind umbrella implantation and a residual shunt (one of whom also had congenital complete heart block and a permanent epicardial pacemaker), two had a residual leak after surgical ligation of the duct, one had Down's syndrome, and another with multiple abnormalities also had mild valvar pulmonary stenosis and an atrial septal defect. The 67 year old patient had ischaemic heart disease and the duct was electively occluded before coronary artery bypass grafting.

### PROCEDURES

The procedures were performed under general anaesthesia in all cases except for the patient awaiting coronary artery bypass surgery. Femoral vascular access was used in each case. In 20 patients venous catheterisation alone

Department of  
Paediatric Cardiology,  
Killingbeck Hospital,  
York Road, Leeds  
LS14 6UQ,  
United Kingdom  
O Uzun  
S Hancock  
J M Parsons  
D F Dickinson  
J L Gibbs

Correspondence to:  
Dr J L Gibbs.

Accepted for publication  
29 May 1996

was used, two patients had only arterial catheterisation, and the remaining 21 had both arterial and venous catheterisation. Antibiotic prophylaxis (a cephalosporin) was given at the start of the procedure and continued for two days. Heparin (50 units/kg) was given to patients who had arterial catheterisation. A 4F sheath and catheter was used for all arterial catheterisation and either a 4F or a 6F sheath was used for venous catheterisation. Aortography was performed in the lateral projection and the minimum diameter of the duct was crudely assessed by visual comparison of the angiographic appearance of the duct and the diameter of the catheter. The coils were delivered using either 5.5F (Cook UK Ltd) or 4F (Microvena Corporation, USA) multipurpose catheters with a single end hole.

If the duct appeared less than 3 mm in diameter we initially attempted occlusion with a single 5 mm diameter coil, the choice of the coil length (the number of turns of the coil) depending on the length and shape of the duct. If the duct appeared to be 3 mm or larger in diameter we initially attempted to occlude it with a single 8 mm diameter coil, proceeding to further coil implantation if a murmur was still present or if a residual shunt was thought unlikely to close spontaneously. Later in the series we chose to implant two 5 mm diameter coils simultaneously (either using an arterial and venous approach together or two venous catheters) in the ducts of 3 mm or larger, with the aim of interlocking the coils together more effectively and therefore hopefully avoiding the use of 8 mm coils. The shape and length of the duct had little effect on the choice of coil size, but if the duct appeared short with a very small aortic ampulla we tended to use shorter (three or four turn) 5 mm coils, and if it appeared long we used the longest (five turn) 5 mm coil. We initially used repeat aortography to assess residual shunting, but after the first 19 cases immediate as well as later assessment of ductal patency after coil implantation was made by echocardiography rather than angiography. Clinical examination, echocardiography, and plain chest radiography were carried out the morning after coil implantation. Clinical examination and echocardiography were repeated after one and three months, with further follow up planned after one year.

A record was kept of all disposable items used for each procedure (including contrast, coils which were wasted, and any equipment used for device retrieval), and the total cost, including value added tax (VAT), of these items was calculated.

### Results

Results were analysed prospectively, based on intention to treat. The narrowest diameter of the duct ranged from 1 to 5 mm (mean 2.2 mm). Pulmonary artery systolic pressure ranged from 20 to 70 (median 24) mm Hg. Of the 43 patients a single coil was used in 28 cases, two coils were used in 14 cases, and

three were implanted in one patient. Fluoroscopy time ranged from 2.9 to 57.5 min (median 7.2 min).

Complete occlusion of the duct before the patient left the catheter laboratory was achieved in 26 patients (60%); 64% of immediately detected residual shunts had resolved spontaneously by the following morning. Twelve cases (27%) still had a residual shunt the following morning. In six of these (13%) the shunt was still present at the median follow up time of three months. Complete duct occlusion therefore occurred in 60% of patients immediately, rising to 72% by the following morning, and 86% three months later. The murmur was abolished in 38 (88%) of the 43 patients at follow up. We have not yet seen any further spontaneous resolution of residual shunts occurring later than one month after implantation.

One child, who had a tiny residual shunt (without any murmur) immediately after implantation of three coils had an easily detectable shunt with a clearly audible murmur the following morning despite the coils remaining, apparently undisplaced, within the duct.

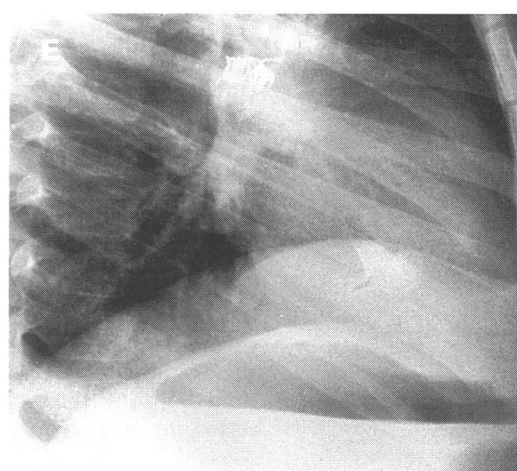
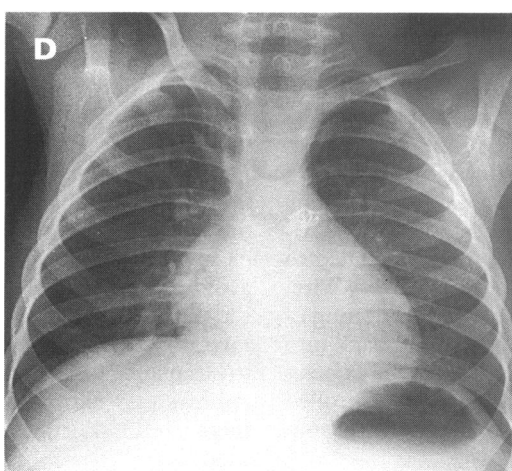
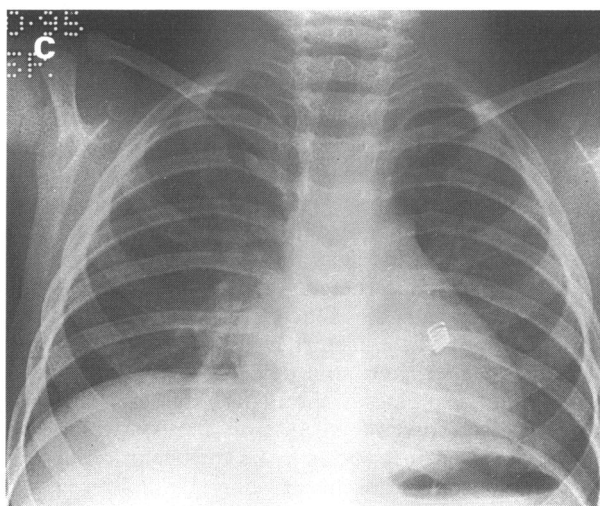
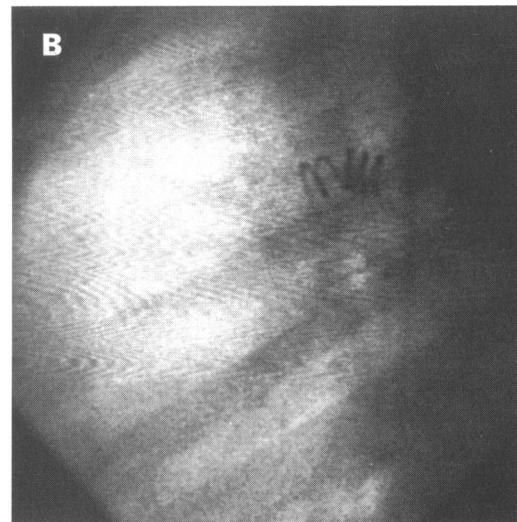
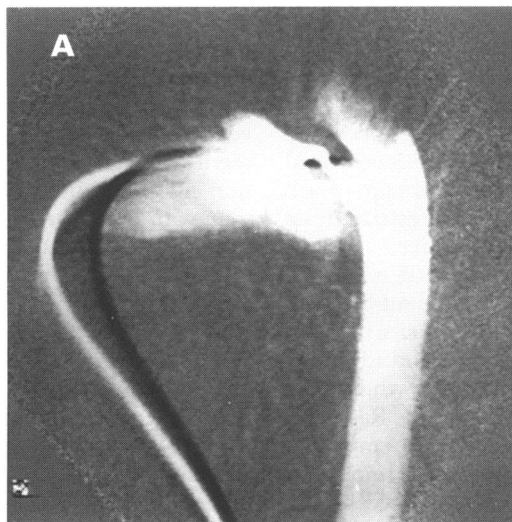
No obstruction to flow in the left pulmonary artery or the descending aorta was detected in any patient. A case is illustrated in the figure.

### COMPLICATIONS

Coil embolisation to the pulmonary artery was the only complication encountered, occurring during the procedure in three patients and after the patient had returned to the ward in two. Immediate embolisation in one case was related to difficulty in releasing a second coil from the delivery wire. Persistent attempts to release the second coil resulted in dislodgement of both coils (one to each pulmonary artery). Both coils were retrieved by snare (Microvena Corporation, USA) and two further coils were then successfully implanted. In the second case of immediate embolisation a 5 mm diameter coil with five turns appeared to be in a very satisfactory position in a 2.5 mm duct, but embolised to the left pulmonary artery within a few minutes. The coil was again retrieved without difficulty and the duct was then successfully occluded with two coils (one 8 mm, one 5 mm) implanted serially. In the third case we elected to retrieve an 8 mm coil from the duct because of partial prolapse of the coil into the origin of the left pulmonary artery after release; the coil was only loosely snared and embolised to the right pulmonary artery, from which it was easily retrieved, and the procedure was completed by simultaneous implantation of a pair of 5 mm coils (one delivered from each side of the duct).

Of the two cases of late embolisation (after the patients returned to the ward and before the following morning), single coils (one 5 mm and one 8 mm) had been implanted. The 5 mm coil initially appeared ideally sited in a tortuous duct of 2 mm diameter. The 8 mm coil had already migrated slightly toward the

(A) Aortography in the lateral projection showing a small (diameter approximately 2 mm), tortuous duct. (B) Delivery of a single 5 mm × five turn coil into the duct was uneventful and the coil position appears very satisfactory. (C) The chest radiograph, taken the morning after coil implantation, shows the coil to have embolised to the left pulmonary artery at some stage during the 12 h after implantation. (D) and (E) Chest radiographs in the posteroanterior and lateral projections after successful retrieval of the embolised coil and delivery of two further coils. Simultaneous implantation of one coil from each side of the duct allowed the coils to be neatly interlocked and complete occlusion of the duct was achieved.



pulmonary trunk after release, but was left in situ as it appeared stable 30 minutes later. In both these cases the coil had embolised to the left pulmonary artery and was retrieved using a snare; the duct was then successfully occluded using two coils in one patient, but in the other no further attempt to occlude the duct was made. In the latter case the threaded part of the coil was avulsed from the coil during snaring and embolised to the distal left pulmonary artery. As the fragment was so small (0.038 inches × approximately 3 mm) no attempt to retrieve it was made and no ill effects were observed.

#### COST

The cost of each coil is £76.40 and the delivery wire (reusable for further coil implantation in the same patient) is £99. The total cost of disposable items used for each procedure ranged from £259 to £1352 with a median cost of £342.

#### Discussion

The introduction of non-surgical methods of closing the arterial duct has led to careful scrutiny of all methods of closing the duct. It is clear that surgery is imperfect, with not only

the inevitable morbidity associated with thoracotomy but with residual shunts being reported in up to 23% of cases.<sup>5</sup> The very first attempts at transcatheter occlusion of the duct using the Porstmann plug<sup>6</sup> proved successful in older patients (90% complete occlusion) but the minimum introducer diameter of 4.2 mm (approximately size 13F) restricted its clinical value. The Botallooccluder,<sup>7</sup> a variation on the theme of a plug, also met with modest success in occluding the duct but also required a minimum introducer size of 12F and was associated with serious morbidity in a small percentage of patients in whom the device embolised to the aorta. The Rashkind double umbrella, the most widely employed device for duct occlusion, requires a minimum introducer size of 8F (unless modified by the operator<sup>8</sup>), and residual shunts have been reported in up to 23% of patients at late follow up.<sup>9</sup> Furthermore, and particularly with the larger Rashkind device, umbrella implantation may be associated with a small risk of stenosis at the origin of the left pulmonary artery due to partial occlusion of the orifice by the proximal half of the umbrella.<sup>10</sup> Early results with the DuctOcclud (PFM, Germany), a new device consisting of a preshaped metal coil, appear promising and it may be introduced through a 4F catheter.<sup>11</sup> However, both the Rashkind and the DuctOcclud devices are expensive. These factors have led to a search for a cheaper alternative device.

Gianturco embolisation coils (stainless steel coils with interwoven Dacron fibres), which have been in use for 20 years for occlusion of other vascular anomalies, may be delivered through small catheters, are economically very attractive, and may effectively occlude the arterial duct.<sup>1-4</sup> However they have not been widely adopted because of the relative lack of control of coil positioning and the lack of controlled release, such that the coil cannot be withdrawn back into the delivery catheter at any stage. The Cook detachable coil is a Gianturco coil which has been modified by adding a short threaded extension at the proximal end of the coil, by which it is attached to the distal threaded portion of a delivery wire. This provides fine control of the positioning of the coil, enables retrieval of the coil back into the delivery catheter even after the coil is positioned in the duct, and provides controlled release of the coil by unscrewing the wire from the coil.

#### TECHNIQUE

For coil delivery a single end hole multipurpose 5.5F catheter (Cook UK) is recommended by the coil manufacturers. A lumen of at least 0.038 inches is necessary for introduction of the coils. In older children we used the recommended catheter, introduced through a 6F sheath. It is possible, at extra expense, to obtain 4F catheters with a sufficiently large lumen (Microvena Corporation, USA, for example). The nature of both the 5.5F and the 4F delivery catheters dictates that a guide wire is often required in order to cross the duct and advance the catheter into the descending

aorta. With increasing experience we have favoured using a 4F delivery catheter for all coils implanted using arterial access and for coils implanted in infancy, even when using venous access alone. We have found assessment of residual shunting after coil implantation no more difficult with echocardiography than with repeat angiography. When a residual leak was detected and deemed significant after implantation and release of one coil, recrossing the duct to deliver a second or third coil proved surprisingly safe. We observed slight displacement of the initial coil during delivery of a subsequent coil in one case but this did not prevent successful delivery of the second device. In our youngest patient the duct was recrossed with a guide wire without difficulty, but there was alarming displacement of the first coil towards the descending aorta at every repeated attempt to pass a 4F catheter over the wire; attempts to implant a second coil were abandoned and repeat echocardiography 20 minutes later showed the residual shunt to have spontaneously resolved. As our experience increased, if we anticipated that more than one coil would be required, we chose to deploy two 5 mm coils simultaneously, persisting in our desire to avoid using the larger 8 mm coil. Simultaneous deployment of one coil from each side of the duct allowed more controlled interlocking of the two coils, perhaps providing a better substrate for thrombosis and occlusion of the duct than using two simultaneous approaches from the pulmonary artery.

#### RESIDUAL SHUNTS

The importance of a small residual shunt early after coil implantation is difficult to judge, and it is clear that these may sometimes resolve spontaneously. Careful consideration of any residual shunt detectable while the patient is still on the catheter table is particularly important because (in contrast to the Rashkind umbrella) further devices may be implanted immediately with relative ease. We still find it difficult to judge which residual shunts may close spontaneously, and on occasion have avoided further coil implantation by patiently repeating the echocardiogram at 10 minute intervals for up to 30 minutes. We choose not to implant a further coil if the shunt jet appears very narrow on echocardiography and there is no murmur audible with a stethoscope.

Seventeen patients left the catheter table with a small residual shunt; in 11 (64%) of these the residual shunt had resolved by the following morning. While six cases had a shunt detectable both early and the following morning, five further residual shunts were detected in patients whose ducts were thought to be completely occluded on the catheter table. In three of these the shunt was very small and there was no murmur so it is possible that the small residual shunt had been missed at immediate echocardiography. However, as in one case the newly detected shunt was due to the coil having embolised to the pulmonary artery, and in another child a trivial shunt had

become easily detectable overnight with a murmur reappearing, it is possible that minor as well as major migration of the coils may occur after the patient has left the catheter laboratory.

#### COIL EMBOLISATION

In our experience coils may embolise to the pulmonary artery after release, particularly when a single small (5 mm) coil is implanted into a duct of 3 mm or larger diameter, despite the control over delivery afforded by the delivery wire. Fortunately, we found retrieval of embolised coils from the pulmonary artery using a snare usually straightforward (this may be facilitated by the introduction of a long 6F or 8F sheath to the pulmonary trunk). We believe our persistent attempts to implant the smaller diameter coils, singly if possible, is justified on the basis of avoidance of obstruction to the origin of the left pulmonary artery, although it is likely that a lower threshold for initial implantation of an 8 mm coil and multiple coils is likely to reduce the risk of embolisation (personal communication, K Walsh, Alder Hey Hospital, Liverpool). As our experience has increased we have tended to deploy a greater proportion of the coil into the aortic end of the duct, sometimes leaving as little as one full turn of the coil in the pulmonary artery. This may increase the chance of complete occlusion using a single coil and seems to have no detectable effect on coil stability within the duct.

#### RADIATION EXPOSURE

In our early experience we used both arterial and venous catheterisation and assessed ductal patency by repeat aortography. Later in the study when we anticipated use of a single coil we successfully avoided arterial catheterisation in the majority by performing the initial aortogram with a single venous catheter through the duct, subsequent assessment of residual shunting being by echocardiography alone. This approach is attractive in that it avoids morbidity associated with arterial access and considerably reduces radiation exposure.

#### COST

The median cost of disposables for duct coil implantation in our series of patients was £342, a saving of approximately 90% when compared to the average cost of implantation of a Rashkind umbrella in our centre. We find the prospect of duct occlusion using a 4F catheter sufficiently attractive to warrant the greater expense of the smaller catheter. However, the cost of the consumables used for coil implantation can be reduced further (by about £100) by using the larger 5.5F delivery catheter recommended by the coil manufacturer.

#### THE LEARNING CURVE

As our experience and confidence increased we found the complication rate, radiation exposure (the number of angiograms as well as

the duration of fluoroscopy), and the cost of the procedure fell. Although, in the first half of the study (22 patients) embolisation of a coil occurred in 9%, in the second half (21 patients) no embolisation was recorded; the mean number of angiograms per patient fell from 2.5 to 1; the mean duration of fluoroscopy fell from 17.5 minutes to 7.9 minutes; and the average cost of disposable items fell from £491 to £369.

#### CONCLUSIONS

Complete duct occlusion assessed three months after coil implantation was achieved in 37 (86%) of the 43 patients. Increasing experience with the technique is likely to reduce the incidence of residual shunts. Whether further late spontaneous resolution of residual shunts will occur as reported with the Rashkind umbrella<sup>12-14</sup> remains to be seen. Comparison of our own experience of the Rashkind umbrella with our early experience with the Cook detachable coil suggests that the coil produces superior results in terms of complete duct occlusion. Successful occlusion of the duct in a 2.7 kg infant with a large shunt and pulmonary hypertension using only venous access with a 4F catheter has led us to broaden our indications to attempt non-surgical closure of the duct. The cost of coil occlusion is approximately one tenth that of occlusion with the umbrella.

- 1 Cambier PA, Kirby WC, Wortham DC, Moore JW. Percutaneous closure of the small (< 2.5 mm) patent ductus arteriosus using coil embolisation. *Am J Cardiol* 1992;69:815-6.
- 2 Lloyd TR, Fedderly R, Mendelsohn AM, Sandhu SK, Beekman RH. Transcatheter occlusion of patent ductus arteriosus with Gianturco coils. *Circulation* 1993;88:1412-20.
- 3 Moore JW, George L, Kirkpatrick SE, et al. Percutaneous closure of the small patent ductus arteriosus using occluding spring coils. *J Am Coll Cardiol* 1994;23:759-65.
- 4 Hijazi ZM, Geggel RL. Results of anterograde transcatheter closure of patent ductus arteriosus using single or multiple Gianturco coils. *Am J Cardiol* 1994;74:925-9.
- 5 Sorensen KE, Kristensen BO, Hansen OK. Frequency of occurrence of residual ductal flow after surgical ligation by colour-flow mapping. *Am J Cardiol* 1991;67:653-4.
- 6 Postmann W, Wierny L, Warnke H, Gertsberger G, Romaniuk PA. Catheter closure of patent ductus arteriosus. 62 cases treated without thoracotomy. *Radiol Clin North Am* 1971;9:203-18.
- 7 Verin VE, Savaliev SV, Kolody SM, Prokubovski VI. Results of transcatheter closure of the patent ductus arteriosus with the Botallooccluder. *J Am Coll Cardiol* 1993;22:1509-14.
- 8 Gatzoulis MA, Rigby ML, Redington AN. Umbrella occlusion of persistent arterial duct in children under two years. *B Heart J* 1994;72:364-7.
- 9 Tynan M. Transcatheter occlusion of persistent arterial duct. Report of the European registry. *Lancet* 1992;340:1062-6.
- 10 Fadley F, Al-Halees Z, Galal O, Kumar N, Wilson N. Left pulmonary artery stenosis after transcatheter occlusion of persistent arterial duct. *Lancet* 1993;341:559-60.
- 11 Le TP, Ness MB, Redel DA, Weinzheimer HR. A new transcatheter occlusion technique with retrievable, double-disk shaped coils—first clinical results in occlusion of patent ductus arteriosus [abstr]. *Cardiology in the Young* 1993;3(suppl 1):38.
- 12 Latson LA. Residual shunts after transcatheter closure of patent ductus arteriosus. A major concern or benign "techno-malady"? *Circulation* 1991;84:2591-3.
- 13 Hosking MCK, Benson LN, Musewe N, Dyck JD, Freedom RM. Transcatheter occlusion of the persistently patent ductus arteriosus. Forty-month follow-up and prevalence of residual shunting. *Circulation* 1991;84:2313-7.
- 14 Musewe NN, Benson LN, Smallhorn JF, Freedom RM. Two dimensional echocardiographic and colour flow Doppler evaluation of ductal occlusion with the Rashkind prosthesis. *Circulation* 1989;80:1706-10.