

## CASE REPORT

## Multiple coronary artery-left ventricular fistulae: haemodynamic quantification by intracoronary Doppler ultrasound

Achim Meissner, Markus Lins, Gunhild Herrmann, Rüdiger Simon

### Abstract

**Multiple coronary artery-left ventricular fistulae involving all three major coronary arteries are extremely rare. Clinical findings are heterogeneous but include a history of typical or atypical angina pectoris in most cases. Coronary arteriography in a 65 year old woman who presented with chest pain at rest revealed multiple fine fistulae arising from the left anterior descending, left circumflex, and right coronary arteries. Left-to-left shunt was estimated by measurements of coronary artery flow velocity with intravascular Doppler ultrasound.**

(*Heart* 1997;78:91-93)

**Keywords:** coronary fistulae; intracoronary ultrasound; coronary anomaly

Department of Cardiology, 1<sup>st</sup> Medical Clinic, University of Kiel, Schittenhelmstrasse 12, D-24105 Kiel, Germany

Correspondence to: Dr Meissner.

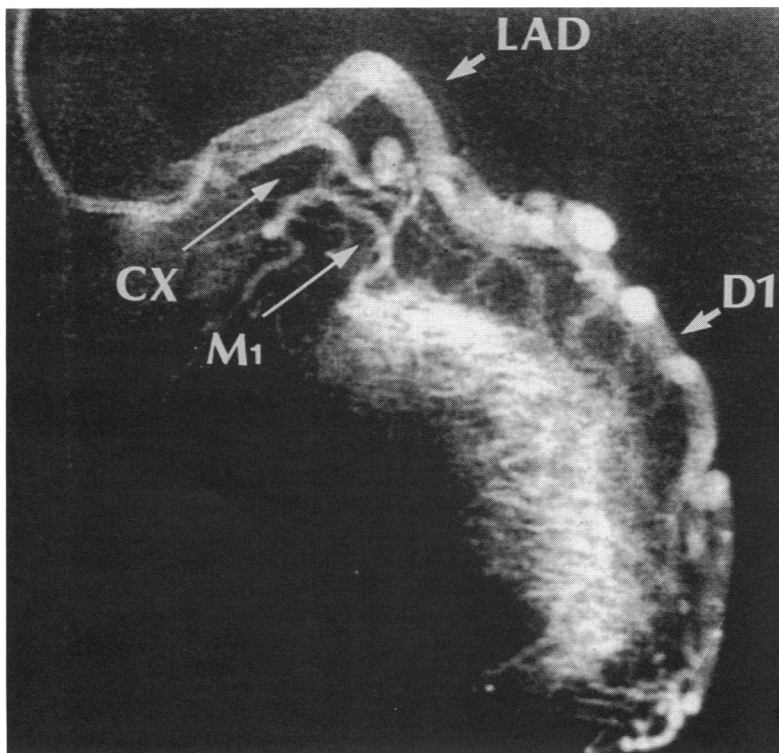
Accepted for publication 24 March 1997

Congenital coronary artery fistulae are a rare finding in about 0.2% of patients undergoing cardiac catheterisation.<sup>1,2</sup> In more than 90% of these cases a single fistula is draining into right heart chambers or the pulmonary artery with an ensuing left-to-right shunt. Multiple fistulous communications to the left ventricle involving all three major coronary arteries are a rare anomaly with fewer than 20 documented cases in the literature.<sup>3</sup> We report the first case in which a quantitative estimate of left-to-left shunt was obtained by measurement of coronary artery flow velocity with intravascular Doppler ultrasound.

### Case report

A 65 year old woman was admitted to our intensive care unit with chest pain at rest. She had a 10 year history of non-insulin dependent diabetes mellitus, hypertension, and hypercholesterolaemia. The patient smoked 20 cigarettes per day and reported no previous episodes of angina pectoris or dyspnoea. Physical examination revealed a normal first and second heart sound and an uncharacteristic systolic murmur grade 2/6 in the second right intercostal space. Murmurs were also found over the femoral and carotid arteries pulses on both sides. Blood pressure was 150/80 mm Hg. There were no pulmonary rales and no ankle oedema. The electrocardiogram showed sinus rhythm (65 beats/min) with minor (0.1 mV) ST segment elevations in leads II, III, and aVF. This appeared suggestive of acute myocardial infarction and prompted thrombolytic treatment with intravenous recombinant tissue plasminogen activator (rtPA). In addition, the patient received intravenous heparin, aspirin, and nitrates. Serum enzyme activities of creatinine kinase (CK) and CK-MB reached a maximum of 266 and 35 U/l, respectively. Chest x ray appeared normal. The clinical course was uneventful and the patient was transferred to the ward after two days.

In the bicycle exercise test a submaximal workload (150 W) was achieved after one week. No clinical or electrocardiographical signs of myocardial ischaemia were inducible. Heart catheterisation and coronary angiography were performed on day 14. Left ventricular angiography revealed a normal sized hyper-



*Figure 1* Selective coronary arteriography (30° right anterior oblique view) showing the left anterior descending (LAD) and circumflex (CX) arteries. Multiple fine fistulae arising from the first diagonal branch (D1) and the first marginal branch (M1) communicate with the left ventricular cavity.

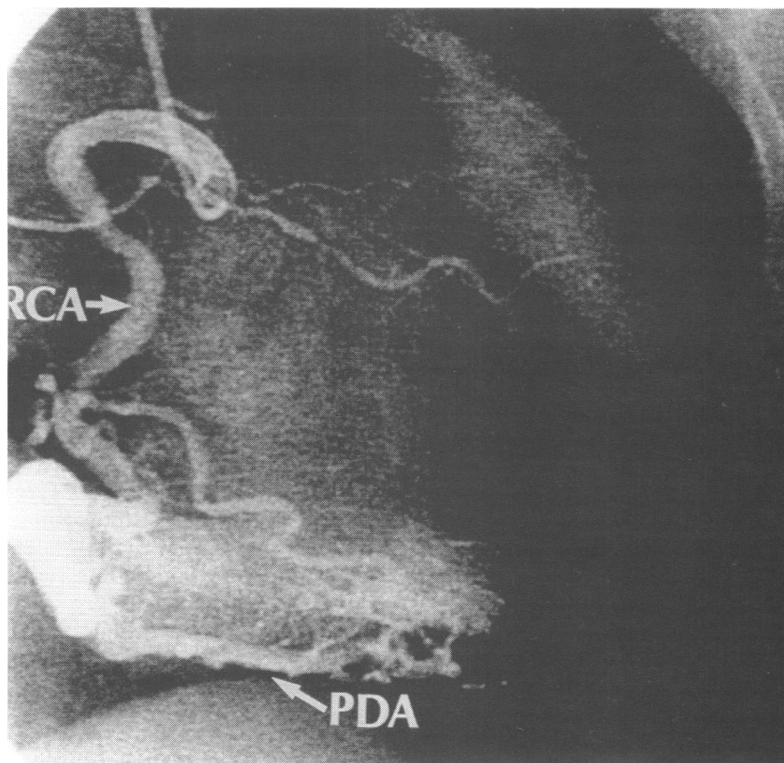


Figure 2 Selective coronary arteriography (30° right anterior oblique view) showing the right coronary artery (RCA). A maze of fine vessels arise from the posterior descending artery (PDA) and communicate with the left ventricular cavity.

trophic left ventricle (end diastolic volume index 76 ml/m<sup>2</sup>) without regional wall motion abnormalities, and an ejection fraction of 69%. Selective arteriography of the left coronary artery was perturbed by the precipitous dilution of the contrast medium resulting from accelerated flow. The proximal part of the left anterior descending artery (LAD), the first diagonal branch, and the first posterolateral

branch of the left circumflex artery appeared tortuous and dilated with multiple fine fistulae to the cavity of the left ventricle (fig 1). The dominant right coronary artery (RCA) also presented a dilated, tortuous morphology with multiple fine communications to the left ventricular cavity via the posterior descending artery (fig 2). Atherosclerotic irregularities with a narrowing of less than 50% of the vessel diameter were visible in the middle segment of the RCA.

Coronary artery flow velocity was measured with a commercially available Doppler guidewire technique (0.018 inch diameter Flowire and FloMap system, Cardiometrics Inc, Mountain View, California, USA) (fig 3). Coronary artery luminal diameters were determined by computer assisted quantitative coronary angiography and amounted to 6.8 and 6.6 mm in the proximal RCA and LAD, respectively. An estimate of coronary artery flow rate was obtained by the following equation:<sup>4</sup>

$$Q_D = (\pi \times D^2) \times 0.25 \times 0.5 \times APV$$

where  $Q_D$  = Doppler derived time-average flow,  $D$  = vessel diameter, and  $APV$  = time average of the spectral peak velocity. Accordingly, coronary flow rate was calculated as 700 ml/min and 960 ml/min in the proximal LAD and RCA, respectively. Measurements of cardiac output with the right ventricle to pulmonary artery thermodilution bolus technique gave an average of 4.8 l/min.

The patient was discharged on an oral anti-hypertensive (diltiazem), an antidiabetic (glibenclamide), aspirin, and a cholesterol-lowering drug (lovastatin). During three years of follow up no further clinical episodes of myocardial ischaemia or heart failure occurred.

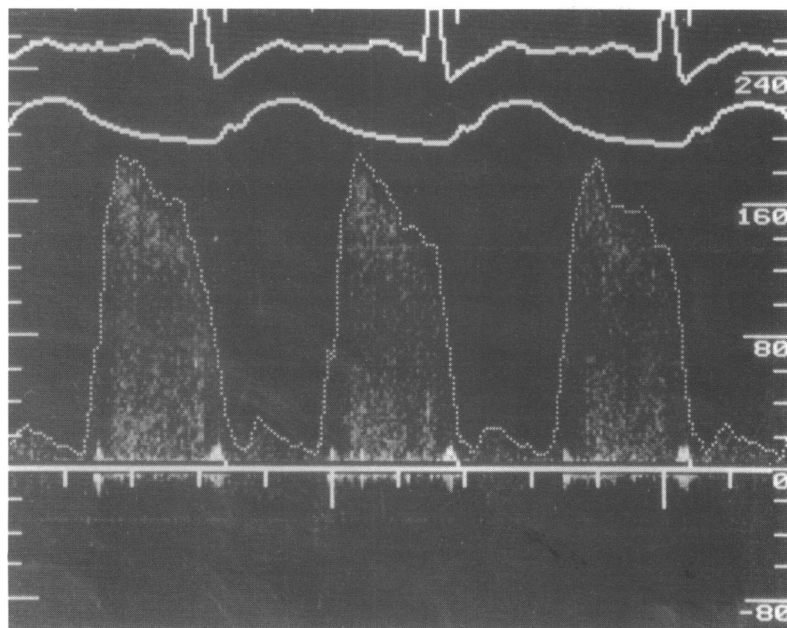


Figure 3 Phasic flow velocity spectrum in the right coronary artery. Top tracing, ECG; Middle tracing, aortic pressure; Bottom tracing, Doppler signal. Vertical axis, flow velocity in cm/s. Peak flow velocity amounted to 180 cm/s and time average of spectral peak velocity to 85 cm/s giving a coronary flow rate of 960 ml/min (vessel diameter 6.8 mm).

## Discussion

Multiple coronary artery-left ventricular fistulae are an uncommon anomaly. According to a recent review, microfistulae originating from all three major coronary arteries and draining in the left ventricle have been reported in only 16 cases.<sup>3</sup> The pathogenetic origin of the malformation is obscure. Morphological studies suggest a partial persistence of embryonic myocardial sinusoids that arise from endothelial protrusions into the intertrabecular spaces.<sup>5,6</sup> Fetal regression of these structures results in the formation of the Thebesian vessels of the adult heart. Thus, interference with developmental changes might produce an abnormally prominent Thebesian system with the morphological appearance of multiple coronary microfistulae.

Most patients in whom this anomaly is diagnosed present with typical or atypical angina pectoris in adult life. The clinical syndrome has been attributed to a coronary steal situation due to the shunting of blood via the low resistance fistulae.<sup>7</sup> Surprisingly, ischaemic responses during exercise stress testing and thallium scintigraphy were not unanimously observed in the reported cases including the

present one. In retrospect, the singular appearance of an acute coronary syndrome in our patient most probably resulted from a transitory thrombogenic transformation of the atherosclerotic plaque in the middle segment of the RCA. According to the literature, all patients experienced their first anginal attacks during advanced adulthood (older than 40 years) despite the assumed congenital origin of the malformation. Therefore, the clinical and prognostic relevance of the suspected ischaemic syndrome in multiple coronary artery-left ventricular fistulae appears to be uncertain.<sup>5</sup>

Haemodynamic quantification of shunt flow might provide further insight into the pathophysiology of this anomaly. In the present case, total flow through the left and right epicardial coronary artery was calculated as 1660 ml/min by using a Doppler guidewire technique. In comparison, total myocardial blood flow in healthy adults has been determined as 150–300 ml/min at rest.<sup>8</sup> Thus, total left ventricular output might be estimated as the sum of shunt flow (1400 ml/min) plus systemic flow (4800 ml/min). Accordingly, left-to-left shunt flow would amount to approximately 23% of total left ventricular output. It has been speculated that the considerable shunt volume draining into the left ventricle might result in diastolic overload imitating the haemodynamic situation of aortic regurgitation.<sup>9</sup> In contrast, the estimated shunt fraction of 23% in our patient cannot be expected to have any negative impact on left

ventricular function for it would be classified as being mild even in subjects with aortic regurgitation. Accordingly, no left ventricular enlargement or reduction in ejection fraction were found. The clinical course of the patient was completely uneventful before and after the first anginal episode that led to coronary angiography and diagnosis. In view of these haemodynamic and clinical findings, the question remains whether this entity has any pathophysiological significance or has to be considered as a normal variation due to a prominent Thebesian system.<sup>5,10</sup>

- 1 Gillebert C, Van Hoof R, Van de Werf F, De Geest H. Coronary artery fistulas in an adult population. *Eur Heart J* 1986;7:437–42.
- 2 Hobbs RE, Millit HD, Raghavan PV, Moodie DS, Sheldon WC. Coronary artery fistulae: a 10-year review. *Cleveland Clin Q* 1982;49:191–7.
- 3 Coussement P, De Geest H. Multiple coronary artery-left ventricular communications: an unusual prominent Thebesian system. *Acta Cardiologica* 1994;49:165–73.
- 4 Coucette JW, Corl D, Payne HM, Flynn AE, Goto M, Nassi M, et al. Validation of a Doppler guide wire for intravascular measurement of coronary artery flow velocity. *Circulation* 1992;85:1899–911.
- 5 Cha SD, Maranhao V, Goldberg H. Silent coronary artery-left ventricular fistula: a disorder of the Thebesian system? *Angiology* 1978;29:169–73.
- 6 Black IW, Loo CKC, Allan RM. Multiple coronary artery-left ventricular fistulae: clinical, angiographic, and pathologic findings. *Cathet Cardiovasc Diagn* 1991;23:133–5.
- 7 Duckworth F, Mukharji J, Vetrovec GW. Diffuse coronary artery to left ventricular communications: an unusual cause of demonstrable ischaemia. *Cathet Cardiovasc Diagn* 1987;13:133–7.
- 8 Simon R. Coronary circulation. In: Lentner C, ed. *Geigy scientific tables, volume 5, heart and circulation*. Basel: Ciba Geigy Ltd, 1990:173–81.
- 9 Reddy K, Gupta M, Hamby RI. Multiple coronary arterio-ventricular fistulas. *Am J Cardiol* 1974;33:304–6.
- 10 Sheikhzadeh A, Stierle U, Langbehn AF, Thoran P, Diederich KW. Generalized coronary arterio-systemic (left ventricular) fistula. *Jpn Heart J* 1986;27:533–44.

## SHORT CASES IN CARDIOLOGY

### Intractable vasospastic angina

C Kurata, A Shimane

A 48 year old woman with drug refractory vasospastic angina had been in our hospital for nine months. Electrocardiograms recorded during angina attacks showed marked elevation of ST segments in the precordial, inferior, and/or lateral leads, often with ventricular arrhythmia or atrioventricular block (fig 1). Coronary angiography revealed no atherosclerotic stenosis, and intracoronary injection of acetylcholine induced total occlusion of the left anterior descending and right coronary arteries despite continuation of high dose calcium antagonists (fig 2).

Calcium antagonists (nifedipine, nisoldipine, amlodipine, benidipine, diltiazem, and verapamil), nitrates (isosorbide dinitrate, isosorbide mononitrate, and nitroglycerin),

nicorandil or various combinations of drugs could not prevent her attacks. Blood concentrations of drugs such as diltiazem and nicorandil were much higher than normal therapeutic values. She did not have signs of a generalised vasospastic disorder such as Raynaud's phenomenon nor a family history of coronary artery disease or sudden death. The patient had stopped smoking after admission. Her attacks occurred not only between midnight and early morning but also in the daytime. The trigger of attacks such as emotional distress, exercise, cold, alcohol, or coffee could not be specified. Her regular menstrual cycle with normal variation of blood oestrogen concentrations was not related to the incidence of attacks.

Department of  
Medicine III,  
Hamamatsu  
University School of  
Medicine,  
Hamamatsu, Japan  
C Kurata  
A Shimane

Correspondence to:  
Dr C Kurata, Department of  
Medicine III, Hamamatsu  
University School of  
Medicine, 3600 Handa-cho,  
Hamamatsu 431-31, Japan.

Accepted for publication  
29 April 1997