

PRACTICE OBSERVED

Use of fax facility improves decision making regarding thrombolysis in acute myocardial infarction

Vinjamur S Srikanthan, Allistair C H Pell, Neeraj Prasad, Graham W Tait, Alan P Rae, Kerry J Hogg, Francis G Dunn

Abstract

Background—Electrocardiography is the fundamental investigation for decision making regarding thrombolytic treatment in acute myocardial infarction (MI). Increasing the accuracy of ECG analysis by input from consultant staff may assist in management decisions in patients with suspected MI.

Aims—To evaluate a system whereby out of hours ECGs can be faxed to the consultant to aid in decision making regarding thrombolytic treatment.

Methods—112 patients with suspected MI were assessed on admission by the senior house officer (SHO) who faxed to a cardiology consultant the ECG trace and a pre-designed form with information on: clinical assessment of the patient; interpretation of the ECG; and views regarding administration of thrombolytic treatment including choice of agent. The consultant reviewed the information and communicated his views to the SHO. Subsequent diagnosis was recorded in all patients and the forms were analysed in regard to areas of agreement and disagreement between the SHO and the consultant.

Results—A diagnosis of MI was confirmed in 52 of the 112 patients (46.4%). The consultant agreed with the SHO's decision on thrombolysis in 98 patients (87.5%). The reason for disagreement in the remaining 14 patients (12.5%) was SHO misinterpretation of the ECG (10 patients) and clinical assessment (four patients). Eight patients were saved unnecessary thrombolytic treatment and four received it when they otherwise would not have. Additionally the choice of thrombolytic agent was changed in six patients from streptokinase to tissue plasminogen activator.

Conclusion—The use of a fax machine assists in decision making with regard to thrombolytic treatment and provides support to junior doctors in what can be a difficult, yet critical decision.

Keywords: telefacsimile; coronary care; myocardial infarction; thrombolytic treatment

Thrombolytic treatment has had a major impact on mortality and morbidity following acute myocardial infarction (MI).¹ Appropriate interpretation of the electrocardiogram is the most important step in the decision whether to administer thrombolytic treatment.^{2,3} However, doubts have been raised about the interpretation of ECGs by junior staff with limited experience in cardiology.⁴

Improving the diagnostic accuracy of MI from the ECG on admission will have a major benefit to patient care in terms of better use of thrombolytic treatment. With the advent of telefacsimile machines it is now possible for a consultant cardiologist to have an ECG faxed to his or her residence out of working hours and thus contribute directly to decision making concerning thrombolytic treatment. This study examined the effect of providing continuous consultant access by fax on patient management in a coronary care unit, particularly with regard to appropriate administration of thrombolytic treatment.

Patients and methods

Patients with chest pain of cardiac origin arriving at the hospital out of working hours (1800 to 0800) who were admitted to the coronary care unit from May to December 1995 were included in this study. The study group comprised 112 patients (62 males (55.4%), 50 females (44.6%)) with a mean age of 65 years (range 34 to 88). Nine senior house officers (SHO) and four consultants participated in the study. The admitting SHO took a history, performed a clinical examination, and interpreted the 12 lead ECG.

A pre-designed proforma was completed by the SHO with information including history, ECG findings, decision on thrombolysis, and choice of thrombolytic agent to be used. The SHO provided reasons if thrombolytic treatment was not to be given. Fax machines were installed in the coronary care unit and in the home of the consultant on call for the unit. The guidelines for ECG diagnosis of MI were based on standard criteria (1 mm ST elevation in two

Department of
Cardiology, Stobhill
NHS Trust, Balornock
Road, Glasgow
G21 3UW, UK

Correspondence to:
Dr Dunn.

Accepted for publication
29 May 1997

(Heart 1997;78:198-200)

Table 1 Comparison of ECG interpretation by senior house officers and consultants of 112 patients presenting with suspected MI

ECG diagnosis	SHO	Consultant	Final diagnosis
Anterior MI	26	20	22
Inferior MI	32	29	29
LBBB	7	7	7
No MI	47	56	54

Final diagnosis was based on ECG and cardiac enzyme changes. LBBB, left bundle branch block.

standard ECG leads or 2 mm ST elevation in two precordial chest leads, or the presence of left bundle branch block or true posterior MI in a patient with a history consistent with an acute MI). A copy of the ECG and the proforma was faxed to the consultant who immediately interpreted the ECG and discussed management by telephone with the SHO. Appropriate treatment was instituted.

The patient records were analysed at the time of discharge from hospital. Serial cardiac enzymes and ECG changes were evaluated by an independent observer to assess the appropriateness of the initial decision by the SHO and consultant. A diagnosis of MI was confirmed on serial daily ECG and cardiac enzyme changes appropriate for MI.

Results

Based on the SHO's interpretation of symptoms 67 patients had a history consistent with MI and 45 patients were considered unlikely to have an MI. The interpretation of the ECG on admission by the SHO compared with the interpretation by the consultant is shown in table 1.

The SHO would have given thrombolytic treatment to 52 of the 112 patients (49.1%). The consultant agreed with the SHO's decision in 98 of the 112 patients (42 to receive and 56 not to receive thrombolytics). There was disagreement in 14 of the 112 patients (12.5%). The reasons for disagreement were based on ECG interpretation in 10 patients and clinical considerations in four.

For 10 patients the consultant recommended withholding thrombolytic treatment, eight of whom had no subsequent evidence of MI. Of the four patients who received thrombolytic treatment after the consultant's intervention, all four had initial ECG criteria for thrombolysis and subsequent enzyme changes consistent with an MI.

Seven patients with a final diagnosis of MI did not receive thrombolytic treatment. The reasons for withholding thrombolytic treatment in these patients was a non-diagnostic ECG on admission in five patients and clinical reasons in two.

There was disagreement about the choice of thrombolytic agent in six patients with acute MI (table 2). The consultant preferred to use recombinant tissue plasminogen activator

instead of the SHO's choice of streptokinase. Five of these patients had a confirmed MI with good reperfusion changes on ECG but one patient did not have serial ECG or enzyme changes of MI.

Seven patients had left bundle branch block on ECG at the time of admission. Three of these patients were considered by the SHO to have a history suggestive of MI but one was outside the time window for thrombolytic treatment. The SHO suggested the other two patients be given streptokinase, however the consultant considered only one appropriate on the basis of history. The final analysis confirmed MI only in that patient considered appropriate for thrombolytic treatment by the consultant.

Thus, a total of 20 of 112 decisions (17.8%) (14 on need for thrombolytics and six on choice of thrombolytic agent) were changed by the consultant, and 17 of 112 (15.1%) patients benefited by the use of a fax machine and discussion with the consultant.

Discussion

This study highlights the differences in interpretation of the ECG between an SHO and a consultant cardiologist with subsequent consequences on thrombolytic treatment. We found that 17 patients (15.1%) benefited from appropriate treatment as a result of this method of consultation. Four patients who were later confirmed to have sustained an MI received thrombolysis only after the intervention of the consultant. Additionally, as thrombolytic treatment is not without risk, especially when administered to patients with a diagnosis other than MI,^{3,5} consultant intervention correctly prevented its use in eight patients. Consultant intervention also benefited five patients who received tissue plasminogen activator rather than streptokinase.⁶

Some patients will still not receive thrombolytic treatment in spite of the presence of trained physicians. This is mainly because of late diagnosis or delayed manifestations on ECG that are known to occur in some patients. The benefit of thrombolysis in such patients is not proved.³ The number of patients in this study who missed thrombolytic treatment for similar reasons was small. This is because some patients with non-diagnostic ECG on arrival in hospital are at times sent to the acute medical receiving unit depending upon the availability of beds in the coronary care unit.

This study has demonstrated that a system of faxing the ECG and pertinent clinical information to consultant staff aids in improving the selection of appropriate patients for thrombolytic treatment. However, not all patients with suspected MI require their ECGs to be dealt with in this way as this could result in a small but unnecessary delay in the prescription of treatment. In particular, there was good agreement in diagnosis between SHOs and consultants among patients with acute inferior MI and left bundle branch block. However, there does seem to be misinterpretation of the ECG by SHOs among patients with suspected anterior MI despite the availability of guidelines.

Table 2 Choice of thrombolytic agent by senior house officers and consultants

	SHO	Consultant
Streptokinase	39	30
Tissue plasminogen activator	13	16
Total	52	46

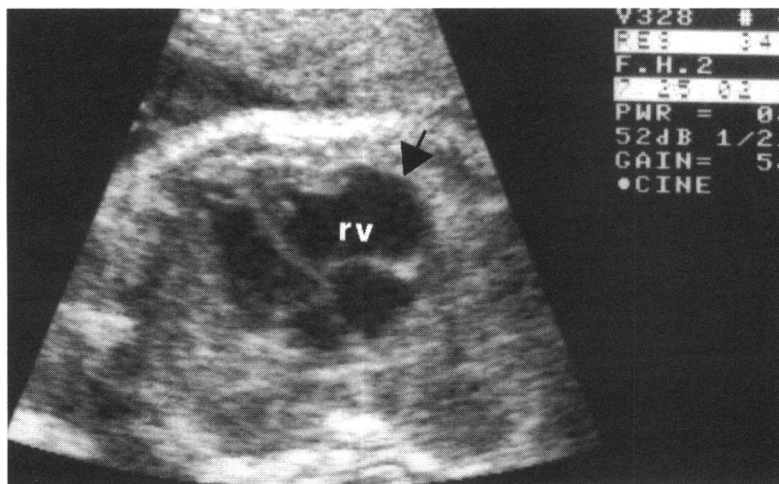
We suggest that a fax facility be available in the coronary care unit and the consultant's home to be used when:

- There is doubt that ECG criteria have been met
- There is a mismatch between the clinical assessment and the ECG
- There are other abnormalities such as previous MI or left ventricular hypertrophy making the ECG interpretation difficult.

- 1 Gruppo Italiano Per Lo Studio Della Streptochinasi nell'Infarto Miocardico (GISSI). Effectiveness of intravenous thrombolytic treatment in acute myocardial infarction. *Lancet* 1986;i:397-401.
- 2 Timmis AD. Early diagnosis of acute myocardial infarction. Electrocardiography is still the best. *BMJ* 1991;301:941-2.
- 3 Curzen NP, Clarke B, Gray HH. Intravenous thrombolysis for suspected myocardial infarction: a cautionary note. *BMJ* 1990;300:513-14.
- 4 White T, Woodmansey P. Improving the interpretation of electrocardiograms in an accident and emergency department. *Postgrad Med J* 1995;71:132-5.
- 5 Butler J, Davies AH, Westaby S. Streptokinase in acute aortic dissection. *BMJ* 1990;300:517-19.
- 6 The Gusto Investigators. An international randomized trial comparing four thrombolytic strategies for acute myocardial infarction. *N Engl J Med* 1993;329:673-2.

IMAGES IN CARDIOLOGY

Echocardiographic appearances of right ventricular dysplasia in the fetus



A 32 year old woman was referred for fetal echocardiography at 24 weeks' gestation because routine screening had shown an abnormal four chamber view of the heart. The echocardiogram showed aneurysmal dilatation of the free wall of the right ventricle (rv, arrowed) with marked thinning of the myocardium at this site as well as dyskinetic wall motion. There were frequent ectopic beats that appeared to be ventricular in origin, but there was no evidence of sustained tachycardia. The pregnancy was terminated and histology of the right ventricular wall confirmed the clinical diagnosis, showing features typical of right ventricular dysplasia.

A BENETTONI
MA RUSTICO
F FONTALIRAN