

CASE REPORT

Abdominal actinomycosis presenting as appendicitis: two case reports and review

Ken Liu^{1,2,*}, David Joseph², Ken Lai³, James Kench¹, and Meng Chong Ngu^{1,2}¹Faculty of Medicine, University of Sydney, Sydney, NSW, Australia, ²Department of Gastroenterology, Concord Hospital, Concord, NSW, Australia, and ³Ken Lai Pathology, Strathfield, NSW, Australia

*Correspondence address. Department of Gastroenterology, Concord Hospital, Hospital Road, Concord, NSW 2139, Australia. Tel: +61297675000, +61402894634; Fax: +61297676767; E-mail: kenliu51@hotmail.com

Abstract

Abdominal actinomycosis (AA) is a rare infection caused by filamentous Gram-positive anaerobic bacteria *Actinomyces*. We report two cases of adults with AA who initially presented with clinical and radiological features of appendicitis. Both patients underwent appendectomy with histopathology diagnostic for actinomycosis of the appendix and subsequently completed prolonged courses of oral penicillin. AA is a rare differential diagnosis for appendicitis and should be considered especially in patients with a chronic, indolent course and nonspecific abdominal symptoms. A high index of suspicion may avoid unnecessary surgery, as treatment with prolonged antibiotic therapy is very effective.

INTRODUCTION

Actinomycosis is a rare granulomatous disease caused by filamentous Gram-positive anaerobic bacteria *Actinomyces*. Infection of the abdomen or abdominal actinomycosis (AA) often presents with nonspecific symptoms, which can mimic inflammatory bowel disease, diverticulitis and even carcinoma [1, 2]. We report two adult cases of AA who initially presented with a clinical picture of appendicitis.

CASE PRESENTATION 1

A 53-year-old male presented with right lower abdominal pain for 12 months. The intermittent cramp-like discomfort occurred every 2 weeks, lasting for 2–3 days before self-resolving without medical treatment. It was associated with documented fevers up to 39°C. The patient was completely well between episodes of

pain and had no significant past medical history. There was mild tenderness in the right lower quadrant on examination with no peritonism or mass felt. Laboratory investigations were unremarkable with white cell count and C-reactive protein (CRP) within reference ranges.

Abdominal computed tomography (CT) revealed a 9-mm distended appendix with surrounding mesenteric stranding suggestive of appendicitis (Fig. 1). There was no appendicolith, free gas or collection seen. The patient underwent a prompt surgical review and a laparoscopic appendectomy was arranged. At operation, the appendix was thickened and densely adherent to ileal mesentery. The appendix was excised and histologic examination showed foci of *Actinomyces* in the lumen (Fig. 2). No acute inflammation was seen; however, lymphoid hyperplasia and chronic inflammatory cells were present in muscularis propria and serosa. The patient was diagnosed with AA of the appendix and treated with intravenous (i.v.) penicillin followed by 6 months of oral penicillin. It was subsequently

Received: February 22, 2016. Accepted: March 29, 2016

Published by Oxford University Press and JSCR Publishing Ltd. All rights reserved. © The Author 2016.

This is an Open Access article distributed under the terms of the Creative Commons Attribution Non-Commercial License (<http://creativecommons.org/licenses/by-nc/4.0/>), which permits non-commercial re-use, distribution, and reproduction in any medium, provided the original work is properly cited. For commercial re-use, please contact journals.permissions@oup.com

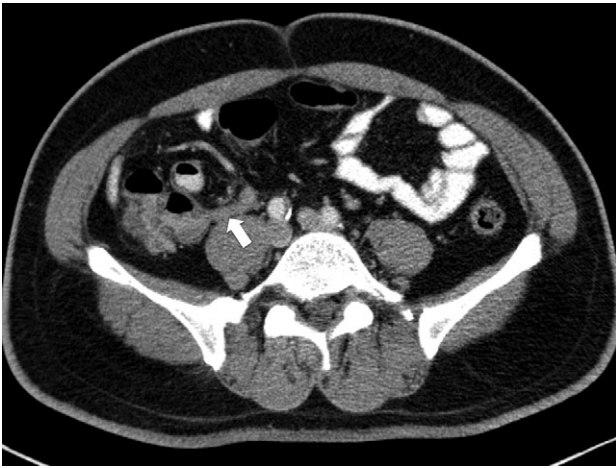


Figure 1: Abdominal CT of Case 1. The appendix is distended and demonstrates surrounding mesenteric stranding (arrow). There is no appendicolith and no free gas or discrete collection to suggest perforation.

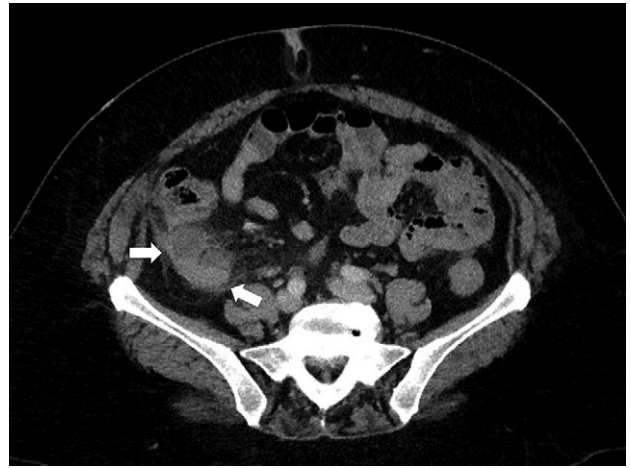

Figure 3: Abdominal CT of Case 2. Markedly thickened retrocaecal appendix with associated periappendiceal fat stranding. Associated with the body of the appendix is a collection located posterior to the ascending colon (arrows).

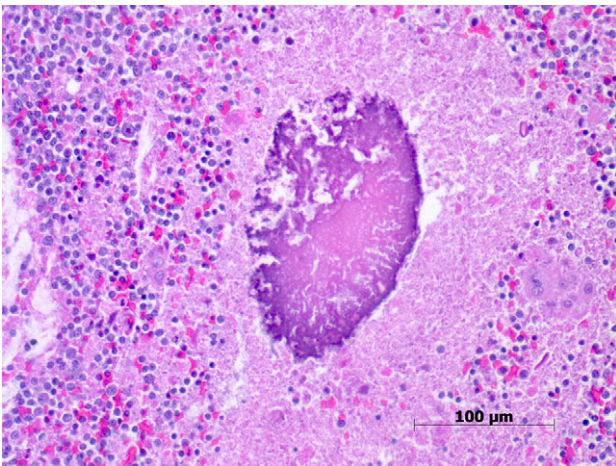


Figure 2: Histopathology of Appendix for Case 1. Focus of actinomycosis with surrounding chronic inflammatory cells and foamy macrophages (haematoxylin-eosin stain, original magnification $\times 200$).

noted that the patient had chronic gingivitis requiring regular dental review.

CASE PRESENTATION 2

A 54-year-old woman presented with an 8-day history of progressively worsening right iliac fossa pain associated with fevers and increased frequency of bowel motions. Her medical background was significant for thalassemia trait and obesity. On examination, she was febrile (38°C) and tender in the right iliac fossa over McBurney's point with no peritonitis. She had a normal white cell count and an elevated CRP of 126 mg/L. Abdominal CT showed a markedly thickened appendix of 18 mm with periappendiceal fat stranding and a $30 \times 30 \times 43$ mm collection posterior to the ascending colon (Fig. 3).

The patient was commenced on i.v. ampicillin, gentamicin and metronidazole. CT-guided drainage of periappendiceal collection was performed with 5 ml of purulent material aspirated. Cultures revealed mixed bowel flora. The patient's fevers and abdominal pain settled with the above treatment and she was discharged on oral antibiotics. An elective laparoscopic

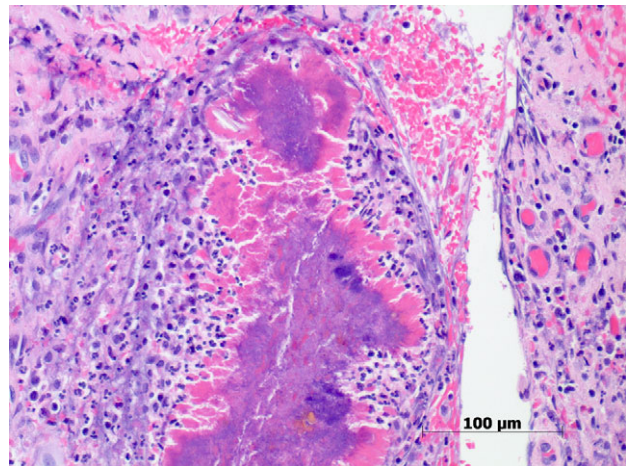


Figure 4: Histopathology of appendix for Case 2. Sulfur granules showing clusters of Gram-positive filamentous non-spore forming actinomyces with adjacent neutrophilic infiltrate. The filaments are surrounded by eosinophilic proteinaceous material which represents a host reaction (haematoxylin-eosin stain, original magnification $\times 200$).

appendicectomy performed 6 weeks later showed a retrocaecal appendix with multiple adhesions, which were removed. On histology, sections of the appendix showed suppurative granulomatous inflammation with clusters of filamentous organisms consistent with *Actinomyces* (Fig. 4). The patient recovered from the operation and commenced on a prolonged course of penicillin.

DISCUSSION

Actinomyces are normal commensals of the oral cavity, gastrointestinal and urogenital tracts but can become pathogenic when the mucosa barrier is breached. Actinomycosis is rare with an incidence between 1/300,000 and 1/1,000,000 [3]. *Actinomyces israelii* is the most frequent human pathogen accounting for up to 90% of infections [4]. Orofacial infection is the commonest form of disease in 50% of cases, followed by AA in 20% of cases. Although the pathogenesis of AA is poorly understood, the critical step appears to be the disruption of the

mucosal barrier. The appendix and ileocaecal region appear to be most commonly involved [3]; however, cases of hepatic, retroperitoneal, adrenal and pelvic AA have also been described [5]. Actinomycosis mostly affects middle-aged adults and is more common in males [4]. Predisposing factors of AA include recent abdominal surgery, bowel perforation, neoplasia, poor oral hygiene and intrauterine contraceptive devices [3]. These insults can precede clinical presentation by several weeks to many years [5].

Diagnosis of AA is notoriously difficult. Often referred to as 'the great pretender' [6], AA carries a broad differential diagnosis both clinically and radiologically. Fewer than 10% of cases are diagnosed prior to surgery [7]. Symptoms such as abdominal pain, fever and weight loss are usually nonspecific [3]. Given the rarity of AA, other diagnoses are entertained first leading to morbidity associated with delayed diagnosis and unnecessary surgery. A clue that points to actinomycosis as a cause is the indolent, slowly progressive nature of the infection which was seen in our first case.

Laboratory investigations provide little value in diagnosis. Cross-sectional imaging with CT or magnetic resonance imaging are useful for determining the anatomic location and extent of disease but are nonspecific [8]. Common features of AA include bowel thickening, and either solid or cystic masses with contrast enhancement. In later stages of infection, infiltration across tissue planes can be seen with fistulae formation to the abdominal wall, perianal area, other organs or between bowel loops. There still lacks a good, non-invasive, diagnostic test for AA to prevent unnecessary surgery.

A definitive diagnosis is obtained by visualization of characteristic sulfur granules and/or culture of *Actinomyces* obtained from needle aspiration of a collection or from a surgical specimen. Although diagnosis of AA by colonoscopy and biopsy has been reported [9], endoscopic biopsies usually demonstrate chronic inflammation without sulfur granules due to limited depth of tissue sampling. Sulfur granules represent colonies of *Actinomyces* and, although highly suggestive, are not pathognomonic of actinomycosis. They can also occur in nocardiosis, botryomycosis and *Aspergillus* infections [3]. Adding to the difficulty in diagnosis, *Actinomyces* must be cultured on selective agar medium under anaerobic conditions for at least 7 days [5].

Antibiotics are the mainstay of actinomycosis treatment. The traditional regimen of i.v. penicillin G (18–24 million units/day) for 2–6 weeks followed by oral penicillin V or amoxicillin for 6–12 months [4] is reasonable for extensive disease. Cure after limited courses of 3 months or less have been reported for treating pelvic actinomycosis [10]. Although no guidelines exist, the duration of antibiotics depends on initial extent of disease and clinical and radiological response to treatment. Doxycycline, clindamycin or erythromycin are acceptable alternatives for penicillin-allergic patients. Surgery is usually reserved for bulky necrotic lesions, large abscesses, fistulas or inability to exclude malignancy. Once a diagnosis of AA [5] is made, the prognosis is favorable in more than 90% of cases after medical and surgical therapy.

In conclusion, AA is a rare differential diagnosis for appendicitis and should be considered in patients with an indolent course and nonspecific abdominal symptoms. The diagnosis of AA relies on histologic examination and is infrequently made by routine investigations prior to invasive procedures.

Treatment with prolonged antibiotic therapy either alone or in combination with surgery is very effective.

CONSENT

Written informed consent was obtained from the two patients for publication of this case report and any accompanying images.

ACKNOWLEDGEMENTS

None to declare.

AUTHOR'S CONTRIBUTIONS

All coauthors have seen and agree with the contents of the manuscript.

We certify that the submission is original work and has not been published previously elsewhere.

Ken Liu: drafting of the manuscript, literature review and research; David Joseph: critical revision of the article, final approval of the article; Ken Lai: critical revision of the article, provision of histopathology pictures; James Kench: critical revision of the article, provision of histopathology pictures; Meng Chong Ngu: initial conception of article idea, critical revision of the article and final approval of the article.

CONFLICT OF INTEREST STATEMENT

None declared.

REFERENCES

- Dayan K, Neufeld D, Zissin R, Bernheim J, Paran H, Schwartz I, et al. Actinomycosis of the large bowel: unusual presentations and their surgical treatment. *Eur J Surg* 1996;**162**:657–60.
- Yeguez J, Martinez S, Sands L, Hellinger M. Pelvic actinomycosis presenting as a malignant large bowel obstruction: a case report and review of the literature. *Am Surg* 2000;**66**: 85–90.
- Wong V, Turmezei T, Weston V. Actinomycosis. *BMJ* 2011;**343**: d6099.
- Russo T. *Agents of actinomycosis*. 7th edn. Mandell G, Bennett J, Dolin R, eds. Elsevier Churchill Livingstone, 2010.
- Liu V, Val S, Kang K, Velcek F. Case report: actinomycosis of the appendix - an unusual cause of acute appendicitis in children. *J Ped Surg* 2010;**45**:2050–52.
- Acevedo F, Baudrand R, Letelier L, Gaete P. Actinomycosis: a great pretender. Case reports of unusual presentations and a review of the literature. *Int J Infect Dis* 2008;**12**: 358–62.
- Harris L, Kakani P, Selah C. Actinomycosis. Surgical aspects. *Am Surg* 1985;**51**:262–4.
- Lee I, Ha H, Park C, Kim J, Kim J, Kim T, et al. Abdominopelvic actinomycosis involving the gastrointestinal tract: CT features. *Radiology* 2001;**220**:77–80.
- Kim J, Han D, Lee H, Kim J, Sohn J, Hahm J. Diagnosis and partial treatment of actinomycosis by colonoscopic biopsy. *Gastrointest Endosc* 2004;**60**:162–4.
- Atad J, Hallak M, Sharon A, Kitzes R, Kelner Y, Abramovici H. Pelvic actinomycosis. Is long-term antibiotic therapy necessary? *J Reprod Med* 1999;**44**:939–44.