

Unstable angina pectoris *Clinical, angiographic, and myocardial scintigraphic observations*¹

Michael S. Donsky, George C. Curry, Robert W. Parkey, Steven L. Meyer,
Frederick J. Bonte, Melvin R. Platt, and James T. Willerson

From the Departments of Internal Medicine (Cardiac Unit), Radiology (Nuclear Medicine) and Surgery (Division of Cardiovascular Surgery) at the University of Texas (Southwestern) Medical School, Dallas, Texas, and Parkland Memorial Hospital, Dallas, Texas, U.S.A.

The clinical, left ventricular and coronary angiographic data, and the technetium-99m stannous pyrophosphate (^{99m}Tc-PYP) myocardial scintigraphic results are presented in 31 patients with unstable angina pectoris. One-third of these patients had positive ^{99m}Tc-PYP myocardial scintigrams in a pattern suggesting limited and diffuse subendocardial necrosis. The positive ^{99m}Tc-PYP myocardial scintigrams occurred without diagnostic electrocardiographic and cardiac enzyme changes suggestive of myocardial infarction; positive scintigrams seemed to occur more commonly in patients with continuing pain after admission and in those without previous history of myocardial infarction. The positive ^{99m}Tc-PYP myocardial scintigrams did not correctly predict coronary anatomical patterns except that positive scintigrams occurred only in patients with coronary artery disease. Neither did the positive scintigrams necessarily occur in that group of patients with the poorest ventricular function though the 2 patients with the lowest ejection fractions both had positive ^{99m}Tc-PYP myocardial scintigrams. Finally, when positive ^{99m}Tc-PYP scintigrams are the only evidence suggestive of limited subendocardial infarction in patients with unstable angina pectoris, they do not appear to have any prognostic significance in terms of longevity or response to pharmacological or surgical therapy, though the follow-up period so far is short.

Unstable angina pectoris is an expression of ischaemic heart disease comprising several heterogeneous syndromes intermediate between chronic, stable angina and acute myocardial infarction (Sampson and Eliaser, 1937; Beamish and Storrie, 1960; Wood, 1961; Resnik, 1962; Vakil, 1964). Attempts to define its natural history have been beset by imprecise and variable diagnostic criteria, differences in patient populations, and in some instances lack of arteriographic confirmation of obstructive coronary artery disease (Fulton *et al.*, 1972; Krauss, Hutter, and DeSanctis, 1972; and Gazes *et al.*, 1973). Clinical recognition of these syndromes has

assumed increased importance since the demonstration that myocardial infarction is often preceded by premonitory symptoms (Solomon, Edwards, and Killip, 1969; Hochberg, 1971; Nixon and Bethell, 1974). Rapid advances in the technique of coronary artery revascularization have led to the application of this surgical procedure to patients with certain unstable anginal syndromes. The major objectives in these situations are the prevention of acute myocardial infarction and the prolongation of life (Lambert *et al.*, 1971; Favaloro *et al.*, 1971; Vogel *et al.*, 1971; Bolooki *et al.*, 1972; Vogel *et al.*, 1975).

A new myocardial scintigraphic technique, using technetium-99m stannous pyrophosphate, has recently been shown to add another dimension to our ability to recognize acute myocardial infarction in man and in animals (Parkey *et al.*, 1974; Willerson *et al.*, 1975 a, b; Bonte *et al.*, 1974). The application of this new imaging technique to 31 patients with

Received 15 August 1975.

¹This work was supported in part by grants from the Harry S. Moss Heart Fund and the Ischemic Heart Disease Specialized Center of Research (SCOR). Dr. Willerson is an Established Investigator of the American Heart Association; Dr. Parkey is a Scholar in Radiological Research, James Picker Foundation.

unstable angina pectoris, together with a description of the clinical, left ventriculographic, and coronary arteriographic findings, forms the basis for this report.

Methods

The 31 patients studied were admitted to the coronary care unit at Parkland Memorial Hospital, Dallas, Texas. There were 19 men; the age range was 34 to 68 years (mean 52 years). Unstable angina for the purposes of this study was defined as either crescendo angina or acute coronary insufficiency.

Acute coronary insufficiency represented that situation in which a single relatively prolonged episode of chest pain occurred in a patient with a background of stable angina pectoris. Eight patients presented with a history of stable angina in the past and one or more recent episodes of angina lasting more than 30 minutes, simulating acute myocardial infarction. The presenting episode of pain was more severe than previous ones and was not entirely relieved by nitroglycerin.

Twenty-three patients exhibited a crescendo angina pattern. This was defined as a definite and progressive change in the pattern of stable angina without any demonstrable precipitating cause such as increased physical activity, emotional stress, or discontinuance of medical therapy. Specifically, their angina was more frequent, of longer duration, less responsive to nitroglycerin, and occurred with less provocation than previously.

The cardiac rhythm was continuously monitored graphically in the coronary care unit. Standard 12-lead electrocardiograms and serial serum enzyme determinations were performed for at least 3 consecutive days after hospital admission. Myocardial infarction was considered to have been excluded if there were: 1) no rise in serum AST or CK above normal values in the absence of intramuscular injections; 2) no new QRS abnormalities on the electrocardiogram; and 3) non-specific alterations of the ST segment and T wave that were of transient nature only. A diagnosis of previous

myocardial infarction was established in 12 patients by either review of previous records or by the presence of diagnostic Q waves on the electrocardiogram.

All patients had myocardial imaging performed approximately 60 minutes after the intravenous injection of 15 mCi of technetium-99m tagged to 5 mg stannous pyrophosphate ($^{99m}\text{Tc-PYP}$). The technical aspects and historical background of this imaging process have been reported previously from our institution (Parkey *et al.*, 1974; Willerson *et al.*, 1975 a, b). The majority of the myocardial scintigrams were obtained at the patient's bedside using a portable Nuclear Data scintillation camera. Scintigrams were generally obtained within 24 hours of admission and many of the patients had at least one follow-up scintigram 2 to 4 days after admission. The imaging was done in at least three views: anterior, left anterior oblique, and left lateral.

The myocardial scintigrams were graded on a 0 to 4+ scale according to the degree of uptake of the radionuclide over a certain region of the heart, as described previously (Parkey *et al.*, 1974; Willerson *et al.*, 1975 a, b). A negative scintigram is shown in Fig. 1. Acute transmural myocardial infarction presents as an intense, localized area of increased activity (3 to 4+) over the anatomical region of the heart corresponding to electrocardiographic localization of the infarct (Fig. 2) (Parkey *et al.*, 1974; Willerson *et al.*, 1975 a, b). Acute subendocardial infarction, on the other hand, is characterized scintigraphically by faintly positive, diffuse $^{99m}\text{Tc-PYP}$ myocardial uptake (2+) (Fig. 3) which is generally difficult to localize (Willerson *et al.*, 1975 a, b).

Cardiac catheterization with selective coronary arteriography was performed in each of these patients after the completion of the diagnostic studies described above. These studies were done 3 to 14 days after admission and after propranolol had been discontinued for at least 24 hours. Left ventriculography was performed in the right anterior oblique position, and filming was done at 60 frames/s with a 35 mm camera. Left ventricular end-diastolic and end-systolic volumes were determined by the area length method (Kasser and Kennedy, 1969). Left ventricular ejection fraction was calculated as the ratio of stroke volume to end-diastolic volume. Coronary

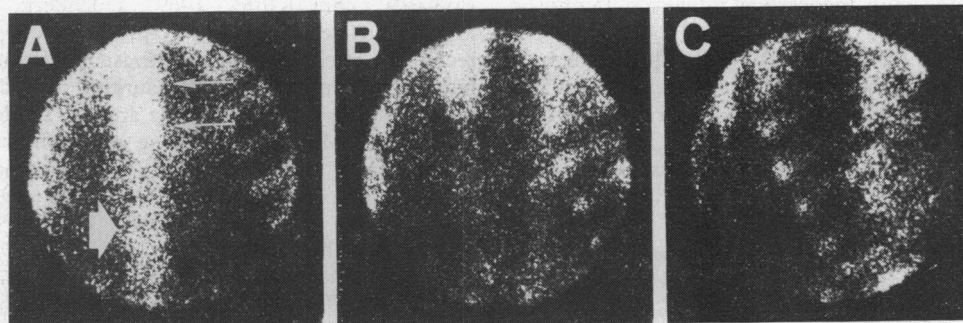


FIG. 1 A negative $^{99m}\text{Tc-PYP}$ scintigram. Panel A is an anterior view, panel B a left anterior oblique view, and panel C a left lateral view. Note the uptake in the sternum and vertebral column (arrows point to these structures in panel A). Also note the faint uptake of the $^{99m}\text{Tc-PYP}$ in the ribs.

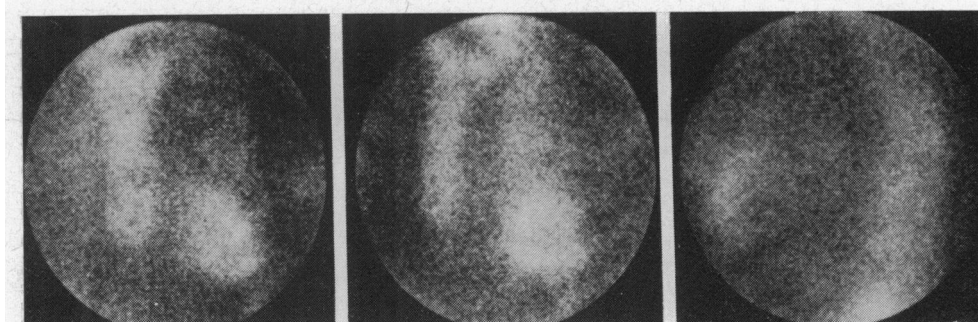


FIG. 2 A ^{99m}Tc -PYP myocardial scintigram that shows an anterior and apical myocardial infarction. The three views are the same as in the preceding figure. Note the increased uptake of the ^{99m}Tc -PYP in the anterior and apical regions of the heart.

arteriographic lesions were considered significant if they produced at least a 70 per cent reduction in luminal diameter.

Initial treatment in all patients consisted of sublingual isosorbide dinitrate and oral propranolol hydrochloride as needed for control and prevention of further attacks of ischaemic pain. Every attempt was made to relieve the chest pain in these patients before subjecting them to cardiac catheterization and in nearly every instance this was successful (see 'Results').

Results

The results of the ^{99m}Tc -PYP myocardial imaging in these patients were of interest. Twenty patients had negative ^{99m}Tc -PYP myocardial scintigrams (Table 1). Eleven patients (Table 2) (35% of the entire group) showed faint and diffusely positive uptake of the ^{99m}Tc -PYP in a 2+ positive pattern (Parkey *et al.*, 1974; Willerson *et al.*, 1975 a, b). This pattern (Fig. 4) is similar to

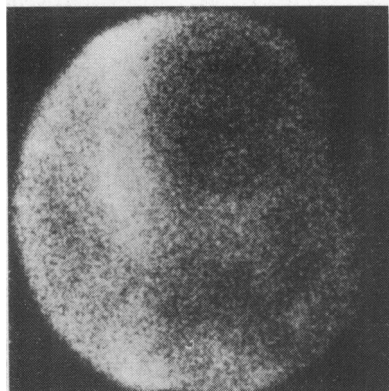


FIG. 3 A ^{99m}Tc -PYP scintigram obtained in a patient with an acute subendocardial myocardial infarction. Note the characteristic faint and diffuse uptake of the ^{99m}Tc -PYP in this type of infarction.

that observed in patients with acute subendocardial infarction (Willerson *et al.*, 1975 a, b). However, none of these 11 patients exhibited any of the enzymatic or electrocardiographic criteria indicating the presence of myocardial necrosis.

The clinical features, coronary arteriographic findings, and left ventricular ejection fractions are detailed in Tables 1 and 2. A comparison of clinical features between these two scintigraphic groups (Table 3) shows an identical mean age, that previous myocardial infarction appeared to be slightly more common in those with negative scintigrams, and that the crescendo pattern of angina and recurrence of angina after the initiation of strict bed-rest tended to be more characteristic of those patients with positive scintigrams. Of interest is the fact that all the patients with positive ^{99m}Tc -PYP scintigrams had crescendo angina except for two who had coronary insufficiency (Tables 1 and 2).

Left ventricular function, as determined by the left ventricular ejection fraction, showed only a tendency (not statistically significant) towards slightly poorer ventricular performance in those patients with positive ^{99m}Tc -PYP myocardial scintigrams. The 2 patients (patients CO and LJ) with the lowest ejection fractions both had positive ^{99m}Tc -PYP myocardial scintigrams (Table 2). Two patients (JM and GW) with positive scintigrams had ventriculographic studies inadequate for volume determinations because of ventricular ectopic beats during angiography (Table 2).

Coronary arteriography was uneventfully performed in all patients; the results are summarized in Tables 1 and 2. Three patients had angiographically normal coronary arteries, an incidence of 10 per cent for the entire group. Each of these 3 patients had a negative myocardial scintigram. Isolated lesions of single coronary arteries were observed in 4 patients, 2 of whom (JM and DD) had disease localized to circumflex marginal vessels in

TABLE 1 20 patients with unstable angina pectoris and negative ^{99m}Tc -PYP myocardial scintigrams

Patient	Age and sex	Previous MI	Clinical syndrome	Angina in CCU	EF (%)	Sites of stenosis
LE	49 M	0	CI	0	68	0
ES	34 M	0	CI	0	61	0
CJ	45 F	0	CA	0	58	0
MS	39 F	0	CA	+	58	L
EJ	46 M	+	CA	0	52	L, C
AR	44 F	0	CA	0	65	C, R
DP	62 M	+	CA	0	65	LM, L, C, R
LR	46 F	0	CA	0	64	L, R
DO	52 F	+	CI	+	59	L, C, R
LC	50 F	+	CI	0	63	L, C, R
DF	66 M	0	CA	+	47	LM, C, R
DW	38 M	+	CI	0	61	L, C, R
FC	61 M	+	CA	+	63	L, C, R
JV	35 M	+	CI	0	60	LM, L, C, R
FR	51 M	+	CA	0	45	L, C, R
CB	68 F	0	CA	0	65	LM, L, C, R
AA	62 F	+	CA	0	41	L, C, R
TH	66 M	+	CA	0	41	L, C, R
JB	51 M	0	CA	0	39	LM, L, C, R
CM	58 M	0	CA	0	43	L, C, R

CI, coronary insufficiency; CA, crescendo angina; EF, ejection fraction; L, left anterior descending coronary artery; LM, left main coronary artery; C, circumflex coronary artery; R, right coronary artery.

TABLE 2 11 patients with unstable angina pectoris and 2+ positive ^{99m}Tc -PYP myocardial scintigrams

Patient	Age and sex	Previous MI	Clinical syndrome	Angina in CCU	EF (%)	Sites of stenosis
JM	55 M	0	CA	+	*	C
DD	50 F	0	CA	+	57	C
CO	55 M	0	CA	0	22	L, C
LJ	53 M	+	CI	0	26	L, C, R
JW	48 M	0	CA	0	45	L, C, R
BW	56 M	0	CA	+	56	L, C, R
SW	51 M	0	CA	0	59	LM, L, R
EL	61 M	0	CA	+	57	LM, L, C, R
EB	59 M	+	CI	0	39	C, R
GW	37 F	0	CA	+	*	L
CT	53 F	0	CA	+	71	L, C, R

Abbreviations as in Table 1.

*Accurate measurement impossible because of frequent ventricular premature beats during left ventricular angiography.

association with positive ^{99m}Tc -PYP myocardial scintigrams. Triple-vessel involvement was present in 19 patients (61%), with 7 showing significant stenosis of the left main coronary artery before its bifurcation into anterior descending and circumflex branches. Apart from the absence of normal coronary arteriograms in those patients with positive ^{99m}Tc -PYP myocardial scintigrams, there were no differences in the distribution of coronary arteriographic abnormalities between the two groups of patients.

The institution of strict bed-rest and the initiation of treatment with sublingual isosorbide dinitrate and propranolol hydrochloride were highly successful in most patients in producing relief of

pain. Whereas pain did recur after admission in 10 patients, in only 3 of these was there a poor response to intensive medical therapy. The short-term follow-up in these patients over an average period of 6 months includes 18 patients who received only medical treatment and subsequently had a total of 6 major ischaemic events: 4 deaths and 2 nonfatal myocardial infarctions. None of these 6 events occurred sooner than 2 weeks after admission; 4 occurred in patients unsuitable for surgical intervention because of poor left ventricular function or unsuitable distal vessels for bypass grafts, one of whom was a patient with a 2+ positive ^{99m}Tc -PYP myocardial scintigram. Permission for necropsy was not obtained in this patient. Surgical revas-

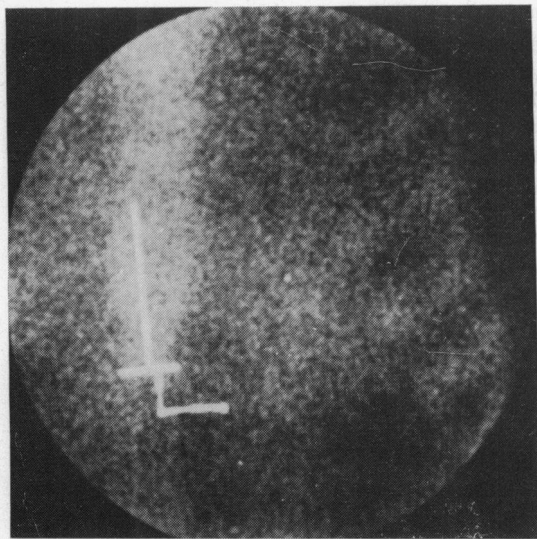


FIG. 4 A ^{99m}Tc -PYP myocardial scintigram obtained from a patient with unstable angina pectoris. Note the faint and diffuse uptake of the ^{99m}Tc -PYP in a pattern very similar to that shown in the preceding figure in which a subendocardial infarction was present.

cularization was carried out in 13 patients, including 5 patients with left main coronary artery lesions and 5 patients with 2+ faintly and diffusely positive ^{99m}Tc -PYP myocardial scintigrams. There has been one operative death and one perioperative infarct in the surgical group so far. The operative death occurred in a patient with a negative ^{99m}Tc -PYP scintigram; the perioperative infarct occurred in a patient with a positive scintigram preoperatively; the patient survived.

Discussion

The various surgical, pharmacological, and physiological techniques developed for the treatment of ischaemic heart disease have attained a degree of sophistication whereby their application

TABLE 3 Comparison of clinical and certain cardiac catheterization features in patients with and without positive ^{99m}Tc -PYP scintigrams

	Negative myocardial scintigram (20)	Positive myocardial scintigram (11)
Age (yr)	52	52.5
Crescendo angina	14 (70%)	9 (82%)
Previous MI	10 (50%)	2 (18%)
Angina in CCU	4 (20%)	6 (55%)
Ejection fraction	56%	48%

to patients with unstable angina may have prophylactic value. Therefore, these interventions deserve careful, controlled study in the future (Fowler, 1971). Myocardial scintigraphy may be of assistance in such investigations. The observation that 35 per cent of our unstable angina patients had positive ^{99m}Tc -PYP myocardial scintigrams identical to those seen after acute subendocardial myocardial infarction raises an obvious question. Had these patients already sustained a minor degree of subendocardial necrosis undetectable by standard diagnostic methods or did they have severe ischaemia which was potentially reversible? Experimental studies done at our institution in dogs suggest that the ^{99m}Tc -PYP is accumulated by irreversibly damaged myocardial cells (Buja *et al.*, 1975 a, b); it has not been possible so far to show that ischaemic but non-necrotic cells take up ^{99m}Tc -PYP. The cellular basis for the accumulation of ^{99m}Tc -PYP by infarcted myocardium is thought to be the labelling of calcium which is deposited in crystalline form in and near mitochondria in necrotic cells, but the possibility that polymorphonuclear labelling or even that some other mechanism may play a part has not yet been excluded (Buja *et al.*, 1975 a, b). In experimental animals histological examination of these regions has confirmed the correlation between myocardial necrosis and increased isotope uptake (Botvinick *et al.*, 1975; Stokely *et al.*, 1976). The possibility does exist, however, that the faintly and diffusely positive ^{99m}Tc -PYP myocardial scintigrams obtained in one-third of the patients with unstable angina indicate cells which are severely ischaemic, but not necessarily destined for necrosis. Appropriate follow-up scintigraphic data are not available at this time and it is not possible to comment on evolutionary changes which may occur in the ^{99m}Tc -PYP myocardial scintigrams in these patients spontaneously or after surgical revascularization. Such information might be particularly useful in prospective studies designed to evaluate various surgical and medical interventions in unstable angina. It is also possible, of course, that the positive ^{99m}Tc -PYP myocardial scintigrams are false positives. This seems unlikely to us since with more than 800 patients studied at our institution using this myocardial imaging technique we have no other sizeable patient group without myocardial infarction but with positive ^{99m}Tc -PYP myocardial scintigrams, even though many patients with relatively stable angina pectoris have been studied. Previous investigators have convincingly shown that at necropsy in many patients with coronary artery disease, there may be scattered areas of myocardial necrosis with no corresponding electrocardiographic or enzyme evidence

of myocardial infarction during life (Allison *et al.*, 1963; Hudson, 1965; Eliot and Edwards, 1974). Thus, it seems possible that the positive ^{99m}Tc -PYP scintigrams obtained in one-third of our patients with unstable angina pectoris do indeed indicate limited areas of subendocardial necrosis undetected by traditional means of diagnostic evaluation, viz. electrocardiograms and enzymes.

The higher than expected incidence of significant lesions involving the left main coronary artery in our patients is consistent with some other previous observations (Vogel *et al.*, 1975; Conti *et al.*, 1973). However, the patients with left main coronary artery lesions could not be identified on the basis of the ^{99m}Tc -PYP myocardial scintigrams in this study. Also the finding of normal coronary arteriograms in 10 per cent of our patients with unstable angina pectoris is similar to that reported in other series (Conti *et al.*, 1973; Alison *et al.*, 1975; Scanlon *et al.*, 1973; Fischl, Herman, and Gorlin, 1973).

There does appear to be a tendency for patients with positive ^{99m}Tc -PYP myocardial scintigrams not to have a previous history of myocardial infarction but to have a clinical presentation of crescendo angina with continuing chest pain after admission, as compared with those patients with negative scintigrams. A possible explanation is that these patients have larger amounts of viable but yet severely ischaemic myocardium with small islands of cell death.

The best treatment for patients with unstable angina is at present unknown. In some centres these patients are considered virtual surgical emergencies. In a recently published large series of unstable angina, 85 per cent of the patients treated with propranolol were notably improved, allowing for a 'cooling off' period, followed by semi-elective coronary artery bypass surgery (Alison *et al.*, 1975). The fact that no myocardial infarctions or deaths occurred within 2 weeks of admission to hospital in our series suggests further that definitive cardiac catheterization and coronary arteriography can probably be safely postponed for several days after admission especially in those patients who lose their pain with strict bed-rest and appropriate drug treatment.

The brief follow-up period of both medically and surgically treated patients in this study suggests that a 2+ faintly and diffusely positive ^{99m}Tc -PYP scintigram in this setting without other evidence of myocardial infarction is of no immediate prognostic value. Of the 8 severe ischaemic events, 6 occurred in those patients with negative myocardial scintigrams. We do not therefore delay either necessary cardiac catheterization or cardiac surgery when the

^{99m}Tc -PYP myocardial scintigram is 2+ positive in patients with unstable angina who have no electrocardiographic or enzymatic evidence of infarction. On the other hand, we would treat the patient as having a myocardial infarct rather than as unstable angina pectoris, when the ^{99m}Tc -PYP myocardial scintigram is 3-4+ positive, or there is a scintigram that is positive and becomes negative in association with a single prolonged episode of pain suggesting infarction, or a positive scintigram associated with traditional evidence of myocardial infarction.

Any conclusions about the specific role of the ^{99m}Tc -PYP imaging technique in the long-term management of patients with unstable angina would be premature at present. However, it seems probable that at least some if not all of these patients with unstable angina pectoris and 2+ diffusely and faintly positive ^{99m}Tc -PYP myocardial scintigrams have already sustained a small area of subendocardial infarction undetectable by less sensitive diagnostic tests. The ^{99m}Tc -PYP myocardial scintigram should be a valuable aid in future investigations into the natural history of unstable angina, and in the evaluation of other diagnostic methods that will be developed which are capable of detecting very small amounts of myocardial damage. It should also be of help in evaluating therapeutic measures that are designed to interrupt the progression of unstable angina pectoris to myocardial infarction.

We are grateful to Dr. Max Buja at the University of Texas (Southwestern) Medical School for discussion and advice.

References

- Alison, H. W., Moraski, R. E., Mantle, J. A., Rackley, C. E., and Russell, R. O., Jr. (1975). Coronary anatomy and arteriography in patients with unstable angina pectoris. *American Journal of Cardiology*, **35**, 118.
- Allison, R. B., Rodriguez, F. L., Higgins, E. A., Jr., Leddy, J. P., Abelmann, W. H., Ellis, L. B., and Robbins, S. L. (1963). Clinicopathologic correlations in coronary atherosclerosis. Four and hundred thirty patients studied with postmortem coronary angiography. *Circulation*, **27**, 170.
- Beamish, R. E., and Storrie, V. M. (1960). Impending myocardial infarction: recognition and management. *Circulation*, **21**, 1107.
- Bolooki, H., Vargas, A., Ghahramani, A., Sommer, L. S., Orvald, T., and Jude, J. R. (1972). Aortocoronary bypass graft for preinfarction angina. *Chest*, **61**, 247.
- Bonte, F. J., Parkey, R. W., Graham, K. D., Moore, J., and Stokely, E. M. (1974). A new method for radionuclide imaging of myocardial infarcts. *Radiology*, **110**, 473.
- Botvinick, E., Lappin, H., Townsend, R., Shames, D., Tyberg, J., and Parmley, W. (1975). Non-invasive quantitation of myocardial infarction with ^{99m}Tc (Sn) pyrophosphate: correlation between creatine phospho-

- kinase depletion and radionuclide uptake. *American Journal of Cardiology*, **35**, 123.
- Buja, L. M., Parkey, R. W., Bonte, F. J., Stokely, E. M., Harris, R. A., and Willerson, J. T. (1975a). Morphologic correlates of technetium-99m stannous pyrophosphate imaging of acute myocardial infarcts. *Clinical Research*, **23**, 39A.
- Buja, L. M., Parkey, R. W., Dees, J. H., Stokely, E. M., Harris, R. A., Jr., Bonte, F. J., and Willerson, J. T. (1975b). Morphologic correlates of technetium-99m stannous pyrophosphate imaging of acute myocardial infarcts in dogs. *Circulation*, **52**, 596.
- Conti, C. R., Brawley, R. K., Griffith, L. S. C., Pitt, B., Humphries, J. O., Gott, V. L., and Ross, R. S. (1973). Unstable angina pectoris: morbidity and mortality in 57 consecutive patients evaluated angiographically. *American Journal of Cardiology*, **32**, 745.
- Eliot, R. S., and Edwards, J. E. (1974). Pathology of coronary atherosclerosis and its complications. In *The Heart*, 3rd ed., p. 1003. Ed. by J. W. Hurst. McGraw-Hill, New York.
- Favaloro, R. G., Effler, D. B., Cheanvechai, C., Quint, R. A., and Sones, F. M. (1971). Acute coronary insufficiency (impending myocardial infarction and myocardial infarction). Surgical treatment by the saphenous vein graft technique. *American Journal of Cardiology*, **28**, 598.
- Fischl, S. J., Herman, M. V., and Gorlin, R. (1973). The intermediate coronary syndrome. Clinical, angiographic and therapeutic aspects. *New England Journal of Medicine*, **288**, 1193.
- Fowler, N. O. (1971). 'Preinfarctional' angina. A need for an objective definition and for a controlled clinical trial of its management. *Circulation*, **44**, 755.
- Fulton, M., Duncan, B., Lutz, W., Morrison, S. L., Donald, K. W., Kerr, F., Kirby, B. J., Julian, D. G., and Oliver, M. F. (1972). Natural history of unstable angina. *Lancet*, **1**, 860.
- Gazes, P. C., Mobley, E. M., Jr., Faris, H. M., Jr., Duncan, R. C., and Humphries, G. B. (1973). Preinfarctional (unstable) angina—a prospective study—ten year follow-up. *Circulation*, **48**, 331.
- Hochberg, H. M. (1971). Characteristics and significance of prodromes of coronary care unit patients. *Chest*, **59**, 10.
- Hudson, R. E. B. (1965). *Cardiovascular Pathology*, p. 665. Williams and Wilkins, Baltimore.
- Kasser, I. S., and Kennedy, J. W. (1969). Measurement of left ventricular volumes in man by single-plane cineangiocardiology. *Investigative Radiology*, **4**, 83.
- Krauss, K. R., Hutter, A. M., and DeSanctis, R. W. (1972). Acute coronary insufficiency: course and follow-up. *Archives of Internal Medicine*, **129**, 808.
- Lambert, C. J., Adam, M., Geisler, G. F., Verzosa, E., Nazarian, M., and Mitchel, B. F. (1971). Emergency myocardial revascularization for impending infarctions and arrhythmias. *Journal of Thoracic and Cardiovascular Surgery*, **62**, 522.
- Nixon, P. G. F., and Bethell, H. J. N. (1974). Preinfarction ill health. *American Journal of Cardiology*, **33**, 446.
- Parkey, R. W., Bonte, F. J., Meyer, S. L., Atkins, J. M., Curry, G. C., Stokely, E. M., and Willerson, J. T. (1974). A new method for radionuclide imaging of acute myocardial infarction in humans. *Circulation*, **50**, 540.
- Resnik, W. H. (1962). The significance of prolonged anginal pain (preinfarction angina). *American Heart Journal*, **63**, 290.
- Sampson, J. J., and Eliaser, M., Jr. (1937). The diagnosis of impending acute coronary artery occlusion. *American Heart Journal*, **13**, 675.
- Scanlon, P. J., Nemickas, R., Moran, J. F., Talano, J. V., Amirparviz, F., and Pifarre, R. (1973). Accelerated angina pectoris. Clinical, hemodynamic, arteriographic, and therapeutic experience in 85 patients. *Circulation*, **47**, 19.
- Solomon, H. A., Edwards, A. L., and Killip, T. (1969). Prodromata in acute myocardial infarction. *Circulation*, **40**, 463.
- Stokely, E. M., Buja, L. M., Lewis, S. E., Parkey, R. W., Bonte, F. J., Harris, R. A., Jr., and Willerson, J. T. (1976). Sizing of acute myocardial infarcts in dogs with technetium-99m stannous pyrophosphate myocardial scintigrams. *Journal of Nuclear Medicine*, **17**, 1.
- Vakil, R. J. (1964). Preinfarction syndrome—management and follow-up. *American Journal of Cardiology*, **14**, 55.
- Vogel, J. H. K., McFadden, R. B., Love, J. W., and Jahnke, E. J. (1971). Emergency vein bypass for the preinfarction syndrome. *Chest*, **59**, 606.
- Vogel, R., Pappas, G., Levitt, P., Battock, D., and Steele, P. (1975). Results of medical and surgical management of high-risk unstable angina. *American Journal of Cardiology*, **35**, 175.
- Willerson, J. T., Parkey, R. W., Bonte, F. J., Meyer, S. L., Atkins, J. M., and Stokely, E. M. (1975a). Technetium-stannous pyrophosphate myocardial scintigrams in patients with chest pain of varying etiology. *Circulation*, **51**, 1046.
- Willerson, J. T., Parkey, R. W., Bonte, F. J., Meyer, S. L., and Stokely, E. M. (1975b). Acute subendocardial myocardial infarction in patients; its detection by technetium 99-m stannous pyrophosphate myocardial scintigrams. *Circulation*, **51**, 436.
- Wood, P. (1961). Acute and subacute coronary insufficiency. *British Medical Journal*, **1**, 1779.

Requests for reprints to Dr. James T. Willerson, Ischemic Heart Center, L5-134, The University of Texas Health Science Center at Dallas, 5323 Harry Hines Boulevard, Dallas, Texas 75235, U.S.A.