

Clinical and topographical range of callosal infarction: a clinical and radiological correlation study

Maurice Giroud, Raymond Dumas

Abstract

A prospective clinical and radiological correlation study was performed to determine the frequency, and the clinical and radiological features of callosal infarction. From 1 January 1993 to the end of December 1993 282 cases of cerebral infarction seen in the Neurology service of the University Hospital of Dijon were studied prospectively. Eight cases with callosal ischaemic lesions were identified by CT and MRI. A callosal disconnection syndrome occurred in only five of eight patients, related to a single, large infarct or several infarctions in the anterior part of the corpus callosum. Clinical features were characterised by left ideomotor apraxia, construction apraxia, and left agraphia in all five cases. Alien hand was noted in only two cases. There were gait disorders in three cases with MRI features of multiple lacunes in a large part of the corpus callosum, and also the subcortical areas of both hemispheres. It is emphasised that callosal infarctions are not rare and that they contribute to the clinical features of strokes. As well as the classic incomplete callosal disconnection syndrome, these callosal ischaemic lesions may induce non-specific gait disorders.

(*J Neurol Neurosurg Psychiatry* 1995;59:238-242)

Keywords: infarction; corpus callosum; disconnection; gait disorders

Cerebrovascular disease has played a major part in the understanding of callosal disconnection syndromes and enabled Liepmann and Maas to show the role of the callosal lesion in the genesis of unilateral apraxia.¹ The anatomical and clinical correlations are not easy to demonstrate in many cases because infarction is not usually limited to the corpus callosum, and multiple infarctions often coexist. Early studies² on callosal symptoms preceded MRI and CT but more recent studies have used these techniques.³ Lesions of the corpus callosum producing disturbances of higher brain function are often recognised as disconnection syndromes of which unilateral left hand apraxia, agraphia, and tactile anomia are the most common.^{1,2,4-6} Because of the absence of systematic studies on the range of clinical and imaging features

of callosal infarction, we performed this population based MRI study to determine the prevalence of the involvement of the corpus callosum in ischaemic strokes and to establish the clinical features.

Patients and methods

From 1 January 1993 to the end of December 1993, we examined prospectively all the patients with ischaemic stroke admitted to the neurological service of the University Hospital of Dijon (France).⁷ Our aims were firstly, to detect a clinical callosal syndrome in any patient with the usual features of an ischaemic stroke, and secondly, to detect callosal infarction by CT and MRI. An ischaemic stroke was defined as an acute neurological deficit, lasting more than 24 hours, with spontaneous improvement.

Clinical symptoms related to a callosal syndrome were systematically collected by the five senior neurologists of the service according to established criteria.^{1-6,8} These were left hand ideomotor apraxia, left hand agraphia, left hand tactile anomia, left alien hand syndrome (as described by Brion and Jedynak⁹ with three characteristics: inability to recognise the arm as one's own when held by the other arm with the eyes closed; a feeling of loss of control of left arm movements; and personification of the left arm), left visual anomia, left auditory extinction, and alexia without agraphia.

Proximal and distal motor examination of the limbs, locomotor ability, sensory stretch reflex examination, visual examination, tests for language (fluency, repetition, writing, reading), buccolinguofacial apraxia, gnosias of famous faces, colours, right-left and finger test, visuospatial and visuoconstructive tasks (drawing a cube, orientation on a map of France), memory functions, frontal functions, and neglect (line bisection test, simultaneous application of sensory, visual, or auditory stimuli), were studied. An ischaemic stroke was defined by a hypodense abnormality on CT and by a hyposignal on T1 weighted image and a hypersignal on T2 weighted image with gadolinium uptake after day 7 on MRI. T1 weighted images were acquired on a 1.5 Tesla Siemens MRI machine, with a short TR (480 ms) and a short TE (15 ms), and T2 weighted images with a TR of 250 ms and a TE of 20 ms. We determined the presence and the topographic localisation of callosal

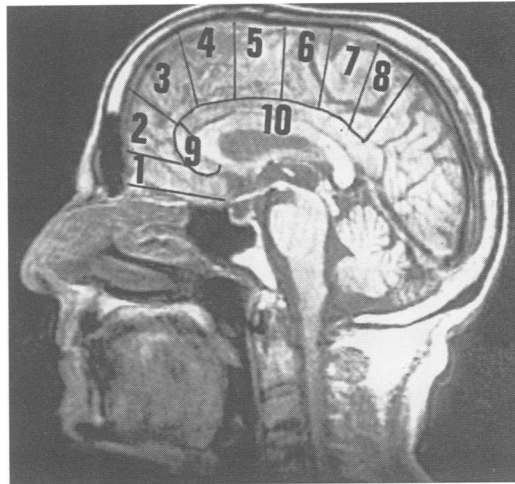
The Neurology Service, General Hospital, University of Burgundy, Dijon, France

M Giroud
R Dumas

Correspondence to:
Dr M Giroud, Hôpital
Général, 3 Rue du
Faubourg Raines, 21000
Dijon, France.

Received 13 December 1994
and in final revised form
2 May 1995
Accepted 11 May 1995

Figure 1 Areas supplied by the branches of the ACA: (1) orbitofrontal artery, (2) frontopolar artery, (3) anterior internal frontal artery, (4) middle internal frontal artery, (5) posterior internal frontal artery, (6) paracentral artery, (7) precuneal artery, (8) internal parieto-occipital artery, (9) callosomarginal artery, (10) pericallosal artery.



ischaemic stroke on CT with the templates defined by Matsui and Mirano¹⁰ and on MRI from the atlas of Duvernoy.¹¹ Figure 1 shows the classification of the territory of the anterior cerebral artery (ACA) used.¹² Doppler ultrasound examination of the cervical arteries, electrocardiography, and two dimensional transthoracic echocardiography were performed on all patients. Angiography was performed on 32. Serological and blood examinations excluded syphilis, hypercoagulability, hyperfibrinogenaemia, and homocystinaemia in all the patients. We prospectively collected data on age (years), sex, hypertension (systolic blood pressure greater than 160 mm Hg/90 mm Hg), diabetes mellitus (serum glucose greater than 1.40 g/l), dyslipidaemia (fasting cholesterol serum higher than 2.5 g/l or fasting serum triglycerides greater than 1.5 g/l), cigarette smoking (≥ 20 packs per year), previous stroke or transient ischaemic attack (focal cerebral dysfunction presumably ischaemic in origin lasting less than 24 hours without any sequelae), previous myocardial infarction with ECG sequelae, atrial fibrillation, presence of echocardiographic abnormalities such as left ventricular hypertrophy or akinesia, mitral valve prolapse, patent foramen ovale, or

aneurysm of the interatrial septum, and significant atheroma of the internal carotid arteries (narrowing of 50% or more of the lumen as documented by Doppler ultrasonography). The presumed causes of stroke were defined according to the criteria used by Adams *et al.*¹³ Large vessel disease was considered as the cause of the infarcts when there was a stenosis of 50% or more in one carotid artery on Doppler ultrasonography or on angiography. Microangiopathy due to hypertension was diagnosed when infarction was in the territory of a deep perforating artery in the absence of another aetiology. Potential cardiac sources of embolism were considered if cardiac arrhythmia, valvulopathy, or cardiac failure with dilatation of ventricular cavities were present.

Results

Of 282 patients with ischaemic strokes collected during the 12 months, eight patients (2.7%; three women, five men (mean age 68, range 61 to 82 years)) had a radiologically identifiable callosal infarction. Four patients had a right sided associated cerebral infarct, one a left sided associated infarct, and three an infarction only in the corpus callosum. Table 1 summarises the clinical features and the radiological findings.

TWO MAIN PATTERNS OF CALLOSAL SYNDROME
Classic callosal disconnection syndrome

Left hand apraxia was noted in six patients (3-8). It was easy to see in the patient (No 7) with right hemiplegia, but more difficult in the other five cases. All these six patients could not perform actions with their left hand on verbal commands after motor recovery. Four patients (5-8) also had impaired imitation and object use with the left hand on command. In these six patients, the body of the callosum was involved. The left hand apraxia was associated with a constructive apraxia. Alien hand syndrome occurred in only two patients, those with an extended callosal infarction (7 and 8).

Left hand agraphia was apraxic in four

Table 1 Clinical and MRI features of callosal infarction

Patients	Left tactile anomia	Left ideomotor apraxia	Left agraphia	Left visual anomia	Left hemideafness	Constructive apraxia	Left tactile alexia	Alien hand	Frontal gait disorders	MRI features
1	0	0	0	0	0	0	0	0	+	
2	0	0	0	0	0	0	0	0	+	
3	0	+	0	0	0	+	0	0	+	
4	0	+	0	0	0	+	0	0	0	
5	0	+	+	0	+	+	0	0	0	
6	0	+	+	0	0	+	0	0	0	
7	+	+	+	0	0	+	+	+	0	
8	0	+	+	0	0	+	0	+	0	

|||: associated internal frontal infarction.

patients (5–8) because they had the ability of left hand writing with anagram letters. The right hand was neither agraphic nor apraxic in all of these cases. Left tactile anomia occurred in one case (No 7) with ischaemic lesions occurring within the four fifths of the corpus callosum and associated with internal frontoparietal ischaemia. Left visual anomia was not found. Left hemideafness as studied by the dichotic test, occurred in only one patient (No 5). Left tactile alexia was present in one patient (No 7).

Gait disorders of frontal type

Of eight patients with callosal infarction established by radiology, three had no specific clinical symptoms (Nos 1–3). The syndrome was characterised by gait disorders with locomotor difficulties of frontal type. The patients used a wide base with feet rooted to the ground. Gait consisted of shuffling with short steps (*marche à petit pas*) and freezing, with no arm swing, and slight extension of the trunk. In patient 1, there were lacunes in the genu of the corpus callosum, in patient 2, there were lacunes in the middle part of the corpus callosum. Patient 3 had a small infarction in the middle of the corpus callosum. All three patients had lacunes in the white matter of the centrum ovale.

MOTOR DYSFUNCTION

Patient 4 had crural monoplegia and hemiplegia was predominantly in the legs in patients 5–8.

OTHER DEFICITS

Hemihypoesthesia ipsilateral to the hemiplegia was seen in patients 7 and 8 both on upper and lower limbs. Hemineglect was present and forced grasping occurred in the same two patients.

STROKE TOPOGRAPHY

Two types of ischaemic lesions were identified by CT and MRI: lacunes <10 mm diameter in the corpus callosum associated with bilateral subcortical lacunes, in white matter in two patients (1 and 2; fig 2) and large infarctions in six patients (3 to 8), associated with leukoaraïosis in patient 3 (fig 3) and with a small infarction in the ipsilateral centrum ovale in patient 7 (fig 4). Patient 4 had two separated infarctions within the corpus callosum (fig 5). Patients 6 and 8 showed an anterior right corpus callosum infarction (fig 6)

also involving the ipsilateral internal frontal area on MRI, corresponding to the ACA territory. Patient 5 had a large infarction in the middle part of the corpus callosum associated with a right internal frontal infarction on MRI, corresponding to the ACA territory. We found in total 13 cases of ACA territory infarctions out of 282 cerebral infarctions.

RISK FACTORS (TABLE 2)

Hypertension was the most frequent risk factor. It occurred alone in patients 1 and 2 and was associated with diabetes mellitus in patients 4 and 7, with dyslipidaemia in

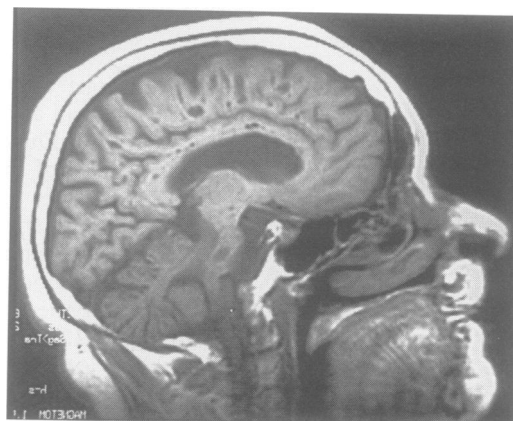


Figure 2 (patient 1) Several lacunes <10 mm diameter all along the corpus callosum but also within the ovale centrum on sagittal T1 weighted MRI.

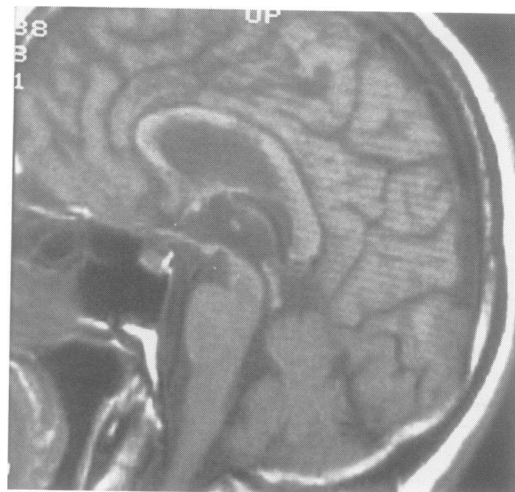


Figure 3 (patient 3) Large infarct in the middle of the corpus callosum, on sagittal T1 weighted MRI.

Table 2 Deficits, risk factors and causes of stroke in the patients with callosal infarction

Patients	Sex	Age (years)	Hemiplegia	Hemihypoesthesia	Other deficits	Risk factors	Presumed cause of stroke
1	F	63	0	0	0	HT	SVD
2	M	68	0	0	0	HT	SVD
3	M	61	0	0	0	0	SVD
4	F	69	Left L	0	0	HT + DM	SVD
5	M	82	Left U + L	0	0	HT + DL + CA	LVD
6	M	72	Left U + L	0	0	HT + DL + CA	LVD
7	F	62	Right U + L	Right U + L	FG + HN	HT + DM + DL + CA	LVD
8	M	69	Left U + L	Right U + L	FG + HN	A + HT	CE

U = upper limb; L = lower limb; FG = forced grasping; HN = hemineglect; A = arrhythmia; DL = dyslipidaemia; DM = diabetes mellitus; HT = hypertension; CA = carotid atheroma; SVD = small vessel disease; LVD = large vessel disease; CE = cardioembolism.

Figure 4 (patient 7)
Infarction involving the left posterior part of the corpus callosum and the ovale centrum, on horizontal T2 weighted MRI.

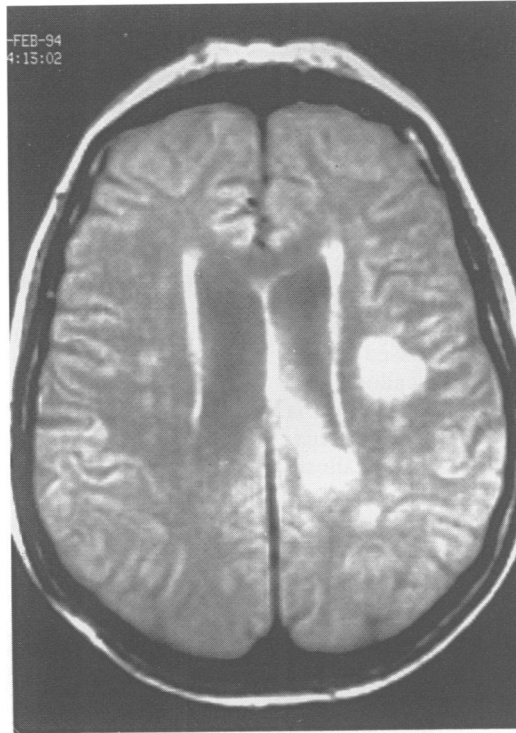


Figure 5 (patient 4)
Two small infarctions in the middle of the corpus callosum on sagittal T1 weighted MRI.

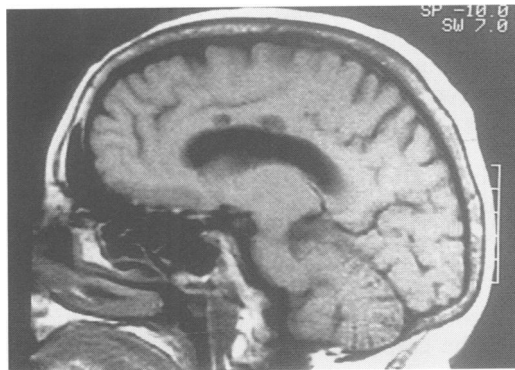
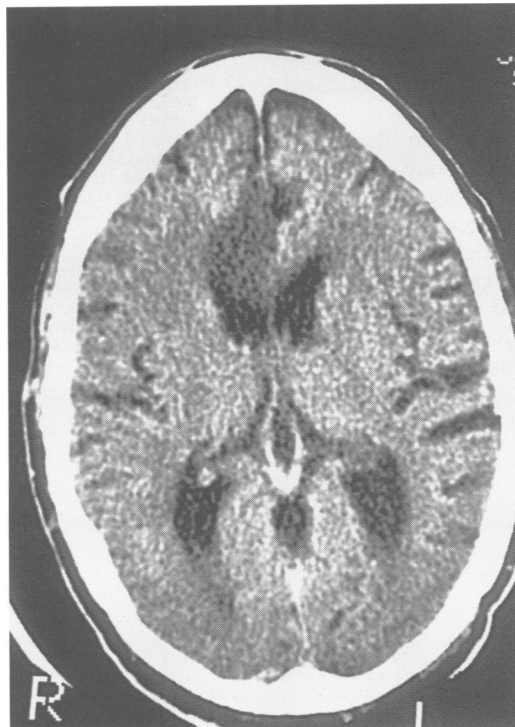


Figure 6 (patient 6)
Infarction of the right ACA territory involving the right anterior part of the corpus callosum on horizontal CT.



patients 5, 6, and 7, with stenosis of the internal carotid artery in patients 5 and 6, and with atrial fibrillation in patient 8. Patient 3 had no apparent risk factors.

PRESUMED CAUSES OF STROKE (TABLE 2)

Small vessel occlusion was presumed to be the cause of the callosal infarction in four patients (1–4), large vessel occlusion in three patients (5–7), and cardioembolism in one patient (8).

Discussion

Previous studies based on CT and on selected postmortem studies have underestimated the frequency of infarction of the corpus callosum. By using MRI in a well defined cohort study, it is possible to know exactly the extent of callosal involvement in comparison with other anatomical structures implicated in ischaemic stroke. We found 13 patients with ACA territory infarctions out of 282 ischaemic strokes (4.6%). These data are similar to the 4% found by Bogousslavsky *et al*¹⁴ in another hospital based study. Among these 13 patients we recorded eight (61%) cases of callosal infarction by CT and MRI, a percentage similar to that found by Bogousslavsky and Regli,³ but greater than the 36% reported by Hung and Ryu⁸ before MRI was available.

The earliest descriptions of the supply areas of the ACA were by Duret in 1874,¹⁵ by Foix and Hillemand in 1925,¹² and Critchley in 1930.² The ACA irrigates the medial surface of the frontal and parietal lobes, the anterior limb of the internal capsule, the head of the caudate, and the corpus callosum (fig 1). Infarction of the entire vascular territory of the ACA is rare (4%).⁸ In most instances, the infarction is subtotal, involving individual branches, singly or in combination.

Despite advances in diagnostic technology, involvement of the corpus callosum in ACA syndromes has not been well recognised on epidemiological, clinical, or radiological grounds.^{16–18} There are many reasons for this: spontaneous onset of callosal infarction is rare,¹⁹ manifestations depend largely on the site and size of the infarct, which is related to the site of occlusion, and motor dysfunction may hide the neuropsychological effects of a lesion in the corpus callosum. In 1907, Liepmann and Maas¹ described a 70 year old carpenter who had transcortical motor aphasia, apraxia, and agraphia of the left arm, and right hemiplegia. The left apraxic hand did not improve with imitation or actual object usage, and the left hand agraphia did not improve with the use of anagram letters. A postmortem examination showed a left ACA infarction with damage extending from the first frontal convolution through the white matter to the paracentral lobule with involvement of the anterior two thirds of the corpus callosum. A callosal lesion would disconnect the left hemisphere from the right premotor cortex and cause apraxia isolated to the left hand.^{21,22} We found ideational apraxia and construction apraxia exclusively limited to the left extremities.

Only two patients (7 and 8) showed alien

hand signs.^{9,23} These had been thought to be secondary to callosal dysfunction but recently were attributed to damage of the medial frontal cortex, including the supplementary motor area and cingulate gyrus contralateral to the alien hand.²³ This correlation was clear in patients 7 and 8. Grasp reflex and motor or verbal perseveration were found in these two patients. Therefore, infarction localised to the anterior one third of the corpus callosum was associated with an ideomotor apraxia and a construction apraxia as shown by patients 3–8. When infarction encompassed more than the anterior two thirds of the callosal corpus, we found an associated tactile anomia (patient 7). There was no visual anomia, because no case showed a posterior callosal lesion.

As well as the well known classic callosal disconnection syndrome, we have identified a pure gait disorder syndrome related to lacunes in the anterior part of the corpus callosum. The gait disorder with locomotor difficulty described in this paper seems to be a frontal type,²⁴ with small step height or “marche à petits pas”, with a wide base, a reduced number of steps per minute, with the feet rooted to the ground, shuffling with short steps and freezing, with imbalance, loss of arm swing, and slight extension of the trunk. The patients have considerable difficulties initiating the leg movements required to walk (yet can perform the movements of pedalling a bicycle well when lying on the bed), and turn. This impairment of gait may be related to an involvement of efferents from the leg area of the motor cortex.^{24,25} We think that the lacunes in the anterior part of the corpus callosum may compromise the afferent pathways from the minor forceps to the frontal cortex, but lacunes outside the corpus callosum could explain this gait disorder in three patients. The last question focuses on the fact that lacunes may be present within the corpus callosum due to involvement of perforating branches of the ACA and this localisation is underestimated in the medical literature.^{26,27}

In summary, MRI shows that there has been an underestimated frequency of callosal infarction in ACA territory infarction. Secondly, the callosal infarction may contribute to the neurological deficit. Thirdly, as well as the classic anterior callosal disconnection syndrome, we found gait disorders in patients with lacunes affecting the anterior part of the corpus callosum.

- 1 Liepmann H, Maas O. Fall von linksseitiger agraphie und apraxie bei rechtsseitiger Lähmung. *J Psychol Neurol* 1907;10:214–30.
- 2 Critchley M. The anterior cerebral artery and its syndromes. *Brain* 1930;53:120–65.
- 3 Bogousslavsky J, Regli F. Infarctus du territoire de l'artère cérébrale antérieure gauche. I. Corrélations clinico-tomodensitométriques. *Rev Neurol (Paris)* 1987;143:21–31.
- 4 Geschwind N, Kaplan E. A human cerebral disconnection syndrome. A preliminary report. *Neurology* 1962;12:675–85.
- 5 Watson RT, Heilman KM. Callosal apraxia. *Brain* 1983;106:391–403.
- 6 Bogen JE. Split-brain syndromes. In: Frederiks JAM, ed. *Handbook of clinical neurology*. Vol 1 (45): *Clinical neuropsychology*. Amsterdam: Elsevier, 1985:99–106.
- 7 Giroud M, Milan C, Beuriat P, Gras P, Essayagh E, Arveux P, Dumas R. Incidence and survival rates during a two year period of intracerebral and subarachnoid haemorrhages, cortical infarcts, lacunes, and transient ischaemic attacks. The stroke registry of Dijon: 1895–1989. *Int J Epidemiol* 1991;20:892–9.
- 8 Hung TP, Ryu SJ. Anterior cerebral artery syndromes. In: JF Toole, ed. *Handbook of clinical neurology. Vascular diseases*. Part I. New York: Elsevier, 1988:339–52.
- 9 Brion S, Jedynak CP. Les troubles du transfert inter-hémisphérique. *Rev Neurol (Paris)* 1972;126:257–66.
- 10 Matsui-T, Hirano A. *An atlas of human brain for CT*. Tokyo: Igaku-Shoin, 1978.
- 11 Duvernoy HM. *Le cerveau humain. Surface, coupes sérieuses tridimensionnelles et IRM*. Paris: Springer-Verlag, 1992.
- 12 Foix C, Hillemand P. Les syndromes de l'artère cérébrale antérieure. *Encéphale* 1925;20:209–32.
- 13 Adams HP, Bendixen BH, Kappelle LJ, Biller J, Love BB, Gordon DL, Marsh EEIII, and the TOAST investigators. Classification of subtypes of acute ischemic stroke: definitions for use in a multicenter clinical trial. *Stroke* 1983;24:35–41.
- 14 Bogousslavsky J, Van Melle G, Regli F. Stroke registry: analysis of 1000 consecutive patients with first stroke. *Stroke* 1988;19:1083–92.
- 15 Duret H. Recherches anatomiques sur la circulation de l'encéphale. *Arch Physiol Norm Pathol (2 ème série)*. 1874;1:316–54.
- 16 Bories J, Derhy S, Chiras J. CT in hemispheric ischaemic attacks. In: J Bories, ed. *Cerebral ischaemia. A neuroradiological study*. Berlin: Springer Verlag, 1985:18–33.
- 17 Ryu SJ. The Chang Gung stroke registry. *Chang Gung Med J* 1986;9:204–16.
- 18 Radü EW, Moseley IF. Carotid artery occlusion and computed tomography: a clinicoradiological study. *Neuroradiology*. 1978;17:7–12.
- 19 Habib M, Ceccaldi C, Poncet M. Syndrome de déconnexion calleuse par infarctus jonctionnel hémisphérique gauche. *Rev Neurol (Paris)* 1990;146:19–24.
- 20 Heilman KM. Apraxia. In: Heilman KM, Valenstein E, eds. *Clinical neuropsychology*. New York: Oxford University Press, 1979:159–85.
- 21 Geschwind N. The apraxias: neural mechanisms of disorders of learned movement. *American Scientist* 1975;63:188–95.
- 22 Yamadori A, Osumi Y, Ikeda H, Kanazawa Y. Left unilateral agraphia and tactile anomia. Disturbances seen after occlusion of the anterior cerebral artery. *Arch Neurol* 1980;37:88–91.
- 23 Goldberg G, Mayer NH, Togliola JV. Medial frontal cortex infarction and the alien hand sign. *Arch Neurol* 1981;38:683–6.
- 24 Sudarsky L, Simon S. Gait disorder in late-life hydrocephalus. *Arch Neurol* 1987;44:263–7.
- 25 Fisher CM. Hydrocephalus as a cause of disturbance of gait in the elderly. *Neurology* 1982;32:1358–63.
- 26 Chamorra A, Sacco RL, Mohr JP, Foulkes MA, Kase CS, Tatemichi TK, et al. Clinical-computed tomographic correlations of lacunar infarction in the Stroke Data Bank. *Stroke* 1991;22:175–81.
- 27 Yamanchi H, Fukuyama H, Ogawa M, Ouchi Y, Kimura J. Callosal atrophy in patients with lacunar infarction and extensive leukoaraiosis. An indicator of cognitive impairment. *Stroke* 1994;25:1788–92.