

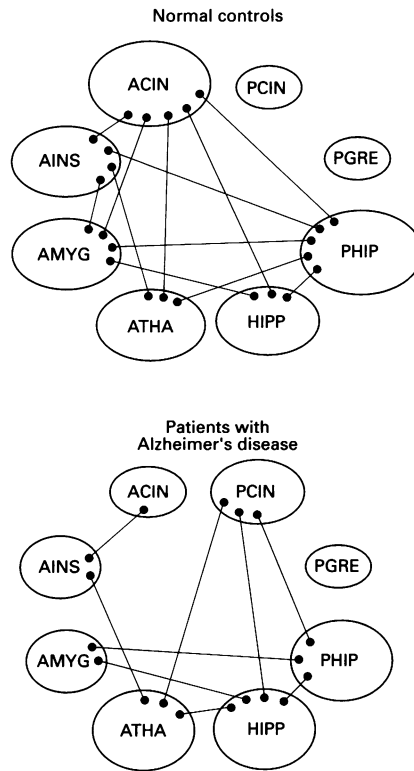
to a degree consistent with the severity of cognitive decline. By contrast, the primary sensory, motor, and visual cortices, brain stem, basal ganglia, and cerebellum seem largely spared.<sup>1</sup> Limbic system structures are known to be affected neuropathologically in Alzheimer's disease<sup>2</sup>; however, their functional state remains relatively unexplored. We therefore used PET technology (Neuro-PET camera; 6 mm resolution; fluorodeoxyglucose tracer) to evaluate 37 patients who met NINCDS-ADRDA criteria for probable Alzheimer's disease and 21 age, sex, and education matched normal controls. Metabolic values in the amygdala, hippocampus, posterior gyrus rectus, anterior insula, parahippocampal gyrus, posterior and anterior cingulum, and anterior thalamus were determined with circular regions of interest (7.8 mm diameter) and then normalised to the brain stem metabolic value, which showed no statistically significant differences between patients (mean (SD) 5.5 (0.8) mg/100 ml/min), and controls (5.5 (0.9) mg/100 ml/min). As there were no significant laterality or interaction effects, homologous structures from the two hemispheres were averaged.

Patients with Alzheimer's disease showed statistically significant hypometabolism in the amygdala (mean ratio (SD): patients 0.90 (0.12); controls 1.01 (0.10)), hippocampus (patients 0.91 (0.10); controls 1.06 (0.13)), posterior gyrus rectus (patients 1.10 (0.17); controls 1.30 (0.19)), anterior insula (patients 1.23 (0.20); controls 1.43 (0.17)), and parahippocampus (patients 0.95 (0.09); controls 1.05 (0.14)) ( $P < 0.05$ ; analysis of variance (ANOVA) with Bonferroni correction). Decreases ranged from 10–16% below values of control subjects. Metabolism in the posterior and anterior cingulum and the anterior thalamus did not differ significantly from normal controls. Thus it seems that relative reductions in glucose metabolism in Alzheimer's disease, although widespread, are not uniform throughout the limbic system, but rather mainly affect specific regions. These regions generally correspond with those having the highest density of neuropathological abnormalities.<sup>2</sup>

*Interregional metabolic correlations*

Regions	Normal controls	Patients with Alzheimer's disease
<b>Amygdala:</b>		
Hippocampus	0.607*	0.598**
Anterior insula	0.610*	NS
Parahippocampus	0.549*	0.518**
Anterior cingulum	0.705**	NS
<b>Hippocampus:</b>		
Parahippocampus	0.836**	0.577**
Posterior cingulum	NS	0.531**
Anterior cingulum	0.744**	NS
Anterior thalamus	NS	0.430*
<b>Anterior insula:</b>		
Parahippocampus	0.599*	NS
Anterior cingulum	0.551*	0.798**
Anterior thalamus	0.632*	0.639**
<b>Parahippocampus:</b>		
Posterior cingulum	NS	0.424*
Anterior cingulum	0.740**	NS
Anterior thalamus	0.592*	NS
<b>Posterior cingulum:</b>		
Anterior thalamus	NS	0.476*
<b>Anterior cingulum:</b>		
Anterior thalamus	0.568*	NS

\* $p < 0.01$ ; \*\* $p < 0.001$ ; Pearson correlation coefficient: right and left mean; no correction for multiple comparisons. Regions with no significant correlations are not shown.



*Interregional connection patterns; ACIN = anterior cingulum; AINS = anterior insula; AMYG = amygdala; ATHA = anterior thalamus; HIPP = hippocampus; PHIP = parahippocampus; PGRE = posterior gyrus rectus; PCIN = posterior cingulate.*

Functional interactions between limbic structures also seemed substantially abnormal in Alzheimer's disease. Differences between patients and controls in interregional metabolic correlations<sup>3</sup> (table) suggest that the anterior cingulum, which showed the greatest decrease in significant correlations to other regions in the Alzheimer's disease brain, may be decoupled from the amygdala, anterior thalamus, hippocampus, and parahippocampus (figure). In addition, the anterior insula may be disconnected from the amygdala and the parahippocampus, and the parahippocampus from the anterior thalamus. The posterior cingulum on the other hand, which did not correlate with any other region in normal controls, may have increased interactions with the anterior thalamus and hippocampal and parahippocampal formations in Alzheimer's disease, as may the hippocampus with the anterior thalamus. This altered pattern of functional interaction likely contributes to the memory impairment associated with Alzheimer's disease. Regions relatively unaffected by the degenerative processes of the disease may become dysfunctional due to selective disconnection, raising the possibility of experimental intercession with the aim of restoring function to these areas.

RAFAEL BLESA  
Hospital Clinic i Provincial,  
Universitat de Barcelona, Barcelona, Spain  
ERICH MOHR  
University of Ottawa/Faculty of Medicine,  
Ottawa, Canada

ROBERT S MILETICH  
Dent Neurologic Institute, Buffalo,  
New York, USA  
THOMAS N CHASE  
Experimental Therapeutics Branch,  
NINDS, National Institutes of Health,  
Bethesda, Maryland, USA

Correspondence to: Dr Rafael Blesa, Neurologia, Hospital Clinic, Villarroel 170, Barcelona, Spain 08036.

- Weinstein HC, Scheltens P, Hijdra A, et al. Neuro-imaging in the diagnosis of Alzheimer's disease. II. Positron and single photon emission tomography. *Clin Neurol Neurosurg* 1993;95:81–91.
- Arnold SE, Hyman BT, Flory J, et al. The topographical and neuroanatomical distribution of neurofibrillary tangles and neuritic plaques in the cerebral cortex of patients with Alzheimer's disease. *Cereb Cortex* 1991; 1:103–16.
- Horwitz B. Brain metabolism and blood flow during aging. *Electroencephalogr Clin Neurophysiol Suppl* 1987;39:396–402.

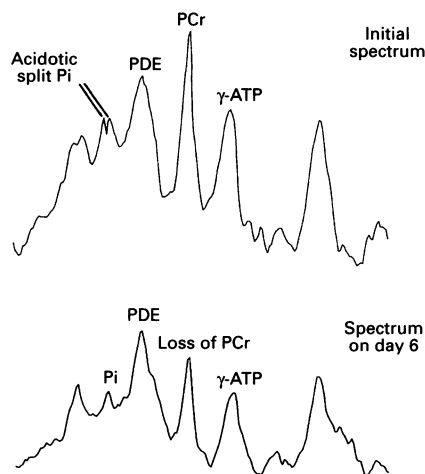
**Delayed ischaemia after subarachnoid haemorrhage: a role for small vessel changes**

Vasospasm complicating subarachnoid haemorrhage is common and associated with morbidity and mortality. Vasospasm has, however, a variable relation with ischaemia, raising the possibility of other factors being important in disturbing blood flow.<sup>1</sup> We describe a patient with phosphorus magnetic resonance spectroscopy (MRS) changes of ischaemia, and decreased cerebral perfusion demonstrated by single photon emission computed tomography (SPECT), but without evidence of vasospasm with angiography or transcranial Doppler.

The patient, a 62 year old right handed woman, presented with a sudden severe headache and loss of consciousness. At admission, she was alert (Glasgow coma scale (GCS) 15/15), with meningism but no focal neurology. Computed tomography confirmed subarachnoid blood concentrated in the right sylvian fissure. On day 3, the first MRS study was performed with our normal protocol.<sup>2</sup> Spectra from the left hemisphere were normal. On the right side, (the side of the haemorrhage), the inorganic phosphate (Pi) peak split at a depth of 4–6 cm (figure), suggesting an area of normal pH and an acidotic region with pH 6.35.

On day 6 she deteriorated, becoming confused, (GCS 13/15). Repeat spectroscopy (figure) showed decreased phosphocreatine and adenosine triphosphate peaks in the region which had been acidotic, whereas the acidosis was resolving (pH 6.8). These are the spectroscopic changes of ischaemia progressing to infarction. Decreasing blood flow inhibits aerobic metabolism and anaerobic glycolysis with lactic acid production occurs,<sup>3</sup> explaining the acidosis on day 3. With further metabolic compromise, high energy phosphate compounds may no longer be maintained. With their loss, membrane ion pumps fail and cell death occurs.<sup>3</sup> With cell death, lactic acid production ceases, the acidosis resolving.

Also on day 6, SPECT (using 500 MBq of technetium-99m hexamethylpropylene amine oxime and an IGE-400XCT camera) was performed. The right frontal lobe was greatly underperfused (mean counts (SD)



*Phosphorus spectra from the right hemisphere. The initial spectrum on day 3 showed a split inorganic phosphate (Pi) peak, suggesting that there was tissue of normal pH and acidotic tissue with pH 6.35. The second spectrum, of the same region on day 6, showed a loss of adenosine triphosphate (ATP) and phosphocreatine (PCr), associated with clinical deterioration. PDE = phosphodiester peak.*

relative to the cerebellum 0.58 (0.06), significantly ( $P < 0.05$ ) less than a symmetric region of interest from the left frontal lobe, 0.87 (0.04)).

Despite these SPECT and spectroscopy changes, there was no evidence of vasospasm. Daily transcranial Doppler studies (using a Scimed PC Dop machine) demonstrated middle cerebral artery velocities within the normal range (right mean velocity (SD) 43 (4.3) cm/s, left 35 (5.6)). Angiography, performed for clinical evaluation on day 7, showed a middle cerebral artery aneurysm, and confirmed the absence of vasospasm.

Subsequently the patient recovered, the aneurysm being clipped on day 11. Postoperatively she re-bleed, developing a left hemiplegia apparent immediately after the operation. Postoperative recovery was further complicated by vasospasm detected with transcranial Doppler. This resolved, and the SPECT was repeated on day 25. Perfusion had increased in the right frontal lobe, which was significantly ( $P < 0.05$ ) hyperaemic (0.98 (0.08) compared with 0.82 (0.06) contralaterally). There was, however, an area with persistently low counts (0.63 (0.06)) in keeping with an established infarct.

The clinical deterioration was typical of delayed ischaemia, six days after the presenting haemorrhage. The SPECT showed hypoperfusion, and spectroscopy a sequence of events reflecting ischaemia with lactic acidosis progressing to infarction. Repeat CT excluded hydrocephalus and rebleeding as causes of the deterioration, and in the absence of any metabolic derangement, a diagnosis of clinical vasospasm might be made. The striking finding was the absence of vasospasm either angiographically, or with serial transcranial Doppler studies. Angiography remains the "gold standard" for diagnosing vasospasm. The angiogram, first SPECT, and second spectroscopy examination were all performed within 24 hours of the clinical deterioration. As vasospasm persists for days, if

it was the cause of the deterioration we would have expected to see it. Angiography and transcranial Doppler, however, examine the large and medium sized intracranial arteries, whereas SPECT assesses perfusion through the microcirculation. The normal angiography and transcranial Doppler examinations, but abnormal SPECT, suggest that there may be relevant changes in small vessels beyond the resolution of the angiogram.

This is similar to a case described by Soucy *et al.*<sup>4</sup> Hypoperfusion on SPECT was not associated with vasospasm on angiography performed two days before, or five days later, raising the possibility of "subradiological vasospasm". There is also support for the existence of small vessel disease from postmortem studies, changes in the small arteries and capillaries being noted, but presumed to be the result of ischaemia, rather than the cause of it.<sup>5</sup>

The changes in this patient must have started by day 3 to account for the acidosis seen spectroscopically. The improvement in perfusion by day 25 (despite additional operative trauma and postoperative vasospasm), suggests that any change can reverse in three weeks. This is similar to the time course of angiographic vasospasm. Striking radiological changes in the large vessels may have drawn attention away from the possibility of coexistent changes in the small vessels. Such changes may be as important, or in some patients like this, more important than large vessel changes. This may explain discrepancies between angiographic vasospasm and cerebral ischaemia.

This concept of small vessel changes does not render angiographic vasospasm unimportant. If small vessel resistance increases, any vasospasm affecting large vessels may compromise the circulation much more than if the small vessels are unaffected. Findings of impaired cerebrovascular reactivity accounting for discrepancies between angiographic vasospasm and cerebral ischaemia may also be explained. These adaptive responses occur primarily at a level of the small vessels, so measuring changes in cerebrovascular reactivity may be a functional assessment of the small vessel changes detected in these imaging studies.

In summary, the vascular changes complicating subarachnoid haemorrhage may be more extensive than is appreciated angiographically, extending to the small vessels. If such changes coexist with angiographic vasospasm, this could explain why angiographic changes correlate poorly with clinical ischaemia.

JEREMY G ROWE  
NIGEL SOPER  
RONALD OUWERKERK  
RICHARD S C KERR  
GEORGE K RADDA  
BHEESHMA RAJAGOPALAN  
MRC Magnetic Resonance Spectroscopy Unit and  
Department of Nuclear Medicine,  
John Radcliffe Hospital, and  
Department of Neurosurgery,  
Radcliffe Infirmary, Oxford

Correspondence to: Dr J G Rowe, MRC Magnetic Resonance Spectroscopy Unit, John Radcliffe Hospital, Headington, Oxford OX3 9DU, UK.

1 Pickard JD, Nelson R, Martin JL. Pathophysiology of aneurysmal subarachnoid haemorrhage. In: Teasdale G, Miller J, eds. *Current neurosurgery*. London: Churchill Livingstone, 1992:1-38.

- 2 Brooke NSR, Ouwerkerk R, Adams CBT, Radda GK, Ledingham JGG, Rajagopalan B. Phosphorus-31 magnetic resonance spectra reveal prolonged intracellular acidosis in the brain following subarachnoid haemorrhage. *Proc Natl Acad Sci USA* 1994;91:1903-7.
- 3 Siesjo BK. Pathophysiology and treatment of focal cerebral ischaemia. Part 1: pathophysiology. *J Neurosurg* 1992;77:169-84.
- 4 Soucy JP, McNamara D, Mohr G, Lamoureux F, Lamoureux J, Danais S. Evaluation of vasospasm secondary to subarachnoid hemorrhage with technetium-99m HMPAO tomoscintigraphy. *J Nucl Med* 1990;31:972-77.
- 5 Hughes JT, Schianchi PM. Cerebral artery spasm: a histological study at necropsy of the blood vessels in cases of subarachnoid hemorrhage. *J Neurosurg* 1978;48:515-25.

### Neurosyphilis presenting with dissociative symptoms

A 62 year old man was admitted as an emergency to a medical ward with a five day history of expressive dysphasia. The onset was acute and the dysphasia variable, becoming more pronounced when he was anxious. He had a 20 year history of insulin dependent diabetes, but there was nothing else of note. There was no psychiatric history. His wife was also in hospital; she had been diagnosed as having probable Creutzfeldt-Jakob disease three weeks before the onset of his difficulties. Her deterioration after initial presentation had been rapid, and she also had pronounced expressive dysphasia in the late stages of her illness. Before admission, the man had an episode of expressive dysphasia after visiting his wife in hospital and another while on the ward visiting her. His wife's resuscitation status and the possibility of a postmortem had been discussed with the patient within 24 hours of the onset of his speech problems.

According to a mental state examination carried out after admission, he was very anxious and agitated; the agitation and dysphasia prevented cognitive function testing at this point. Physical and neurological examination were normal. Investigations at this time showed that full blood count, plasma viscosity, urea and electrolytes, liver function tests, thyroxine, and thyroid stimulating hormone were all within normal limits; plasma glucose was raised at 14.2 mmol/litre. A chest radiograph and ECG were normal, as was a carotid scan. In view of the circumstances of the presentation, a provisional diagnosis of a dissociative disorder was made and a psychiatric opinion sought.

Ten days after admission, he became increasingly agitated, emotionally labile, and tearful, and his speech was so slurred that cognitive assessment was still not possible. In view of this deterioration, he was transferred to an acute general psychiatric ward. His wife died eight days later. He seemed to take this news well, becoming less agitated and dysphasic. Cognitive function testing at this point showed significant impairment (mini mental state examination = 18/30). Brain CT showed advanced cerebral atrophy with no focal abnormalities, and there was excessive slow wave activity in the left temporal and anterior regions on the EEG. Autoantibody screening was normal. In view of these findings, he was trans-