

Optical Coherence Tomography Angiography in Retinal Diseases

K. V. Chalam, MD, PhD; Kumar Sambhav, MD

Department of Ophthalmology, University of Florida College of Medicine, Florida, USA

Abstract

Optical coherence tomography angiography (OCTA) is a new, non-invasive imaging system that generates volumetric data of retinal and choroidal layers. It has the ability to show both structural and blood flow information. Split-spectrum amplitude-decorrelation angiography (SSADA) algorithm (a vital component of OCTA software) helps to decrease the signal to noise ratio of flow detection thus enhancing visualization of retinal vasculature using motion contrast. Published studies describe potential efficacy for OCTA in the evaluation of common ophthalmologic diseases such as diabetic retinopathy, age related macular degeneration (AMD), retinal vascular occlusions and sickle cell disease. OCTA provides a detailed view of the retinal vasculature, which allows accurate delineation of microvascular abnormalities in diabetic eyes and vascular occlusions. It helps quantify vascular compromise depending upon the severity of diabetic retinopathy. OCTA can also elucidate the presence of choroidal neovascularization (CNV) in wet AMD. In this paper, we review the knowledge, available in English language publications regarding OCTA, and compare it with the conventional angiographic standard, fluorescein angiography (FA). Finally, we summarize its potential applications to retinal vascular diseases. Its current limitations include a relatively small field of view, inability to show leakage, and tendency for image artifacts. Further larger studies will define OCTA's utility in clinical settings and establish if the technology may offer a non-invasive option of visualizing the retinal vasculature, enabling us to decrease morbidity through early detection and intervention in retinal diseases.

Keywords: Optical Coherence Tomography Angiography (OCTA); Split-spectrum Amplitude Decorrelation Angiography (SSADA); Diabetic Retinopathy; Age Related Macular Degeneration; Choroidal Neovascularization

J Ophthalmic Vis Res 2016; 11 (1): 84-92.

INTRODUCTION

Optical coherence tomography (OCT) has emerged as an important imaging modality in the evaluation and

management of retinal diseases. The noninvasive nature of the test and its ability to image intraocular structures *in vivo* with resolution approaching that of histological sections has made OCT particularly useful for detection and quantification of macular and optic nerve head pathologies.^[1]

Recently, several OCT based angiography methods have been developed for noninvasive 3-dimensional vascular mapping at the microcirculation level.^[2] Optical coherence tomography angiography (OCTA)

Correspondence to:

K. V. Chalam, MD, PhD. Department of Ophthalmology, University of Florida College of Medicine, 580 West 8th Street, Tower 2, 3rd Floor, Jacksonville, FL 32209, USA. E-mail: kchalam@jax.ufl.edu

Received: 28-11-2015

Accepted: 30-12-2015

Access this article online

Quick Response Code:



Website:

www.jovr.org

DOI:

10.4103/2008-322X.180709

This is an open access article distributed under the terms of the Creative Commons Attribution-NonCommercial-ShareAlike 3.0 License, which allows others to remix, tweak, and build upon the work non-commercially, as long as the author is credited and the new creations are licensed under the identical terms.

For reprints contact: reprints@medknow.com

How to cite this article: Chalam KV, Sambhav K. Optical coherence tomography angiography in retinal diseases. *J Ophthalmic Vis Res* 2016;11:84-92.

is a new non-invasive imaging technique that employs motion contrast imaging to high-resolution volumetric blood flow information generating angiographic images in a matter of seconds. The use of the split-spectrum amplitude decorrelation angiography (SSADA) algorithm^[3] improves the signal to noise ratio of flow detection; thus the application of this algorithm in OCTA can assist visualization retinal vasculature.^[4,5]

COMPARISON OF OCTA WITH FUNDUS FLUORESCIN ANGIOGRAPHY (FFA)

Fundus fluorescein angiography (FA) is a vitally important diagnostic tool for evaluating patients with retinal pathologies. It is an invasive test that requires intravenous administration of dye and imaging for at least 10-15 minutes. FA provides two-dimensional image sets that allow dynamic visualization of blood flow with a wide field of view; therefore, patterns of dye leakage, pooling, and staining can be appreciated and are well-documented in the literature.^[6] However, FA cannot separately visualize the intraretinal structures of major capillary networks; the images of superficial and deep capillaries overlap, so 2 of the 3 major capillary networks (superficial retinal, deep retinal and choriocapillaries) do not appear to be imaged well despite the retina being a nearly transparent structure.^[5] Weinhaus et al^[7] have reported that FA does not image the deeper capillary plexus well in monkey eyes. FA has other drawbacks that can limit its widespread use; it is invasive, relatively expensive, time-consuming, and not an ideal technique for use on a regular basis in a busy clinical setting. Although considered safe, the dye poses risks ranging from nausea to allergic reactions, including anaphylaxis in rare instances. For evaluation of patients requiring frequent follow-up examinations or those that may not tolerate injection of the intravenous dye, a rapid non-invasive technique to visualize retinal and choroidal vessels would be beneficial.

OCTA, in comparison, is a non-invasive technique that acquires volumetric angiographic information without the use of dye. Each three-dimensional scan set takes approximately six seconds to obtain. The en-face images obtained can then be scrolled to visualize individual vascular plexuses and segment the inner retina, outer retina, choriocapillaris, or other areas of interest. Spaide et al^[2] have demonstrated that FA does not image the radial peripapillary or the deep capillary networks well. However, OCT angiography can image all layers of the retinal vasculature without dye injection [Figure 1a-c].

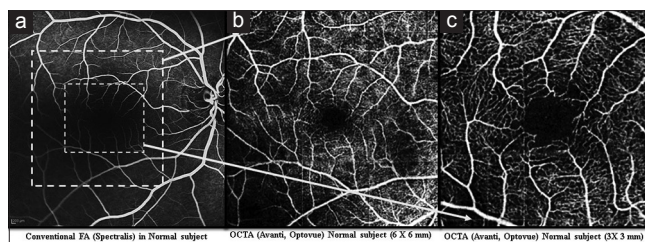


Figure 1. Comparison of images of fundus fluorescein angiography (a) to OCTA images of superficial plexus (b and c) in a normal subject. Early images of FA (15.2 sec) shows normal fillings of arteries and veins. OCTA (6 × 6 mm) of superficial plexus (b) showing normal capillary network with better resolution of smaller capillary network. OCTA (3 × 3 mm) of superficial plexus (c) showing clear delineation of foveal avascular zone and well defined capillary network.

PRINCIPLES OF OCTA

The most widely available prototype system of OCTA is the RTVue XR Avanti (Optovue Inc., Fremont, California, USA). This instrument has an A-scan rate of 70,000 scans per second, using a light source centered on 840 nm and a bandwidth of 50 nm. The tissue resolution is 5 mm axially and there is a 15-mm beam width.

Image Acquisition

Two sets of imaging are performed at one assessment. Each image set comprises of two raster volumetric patterns (one vertical priority and one horizontal priority) covering options of 2 × 2 mm, 3 × 3 mm, 6 × 6 mm, and 8 × 8 mm. An orthogonal registration algorithm (in-built software which has the ability to correct some motion artifacts) is used to produce merged 3-dimensional OCT angiograms. Each volume set is composed of 216 line-scan locations at which 5 consecutive B-scans were obtained. The results of 2 sets of images obtained are averaged using inbuilt software.

Split-spectrum Amplitude Decorrelation Angiography (SSADA)

The SSADA algorithm compares consecutive B-scans obtained at the same location to detect blood flow in vessels using motion contrast.^[2-5] After processing the volume scans, decorrelation of the images (1 – correlation), is calculated. The imaging characteristics of the scan for stationary tissues, show high correlation from one frame to the next. However, imaging characteristics of blood flowing through vessels change reflectance over successive scans causing a low correlation between frames (or a high decorrelation). The resultant correlated frames are evaluated and statistical outliers are removed to reduce the possibility of tissue-motion artifacts. Furthermore, the spectrum of the light source is split

into 4 components to decrease the noise present in the image and each component is then used to perform the decorrelation step separately. Finally, the results of all 4 components are averaged and a block of information is generated that contains the levels of decorrelation (ranging from 0 to1). This split-spectrum strategy trades some of the axial resolution for decreased noise and for higher transverse resolution.

Segmentation and Perfusion Indices of OCT-Angiography Image

The retina is a laminar structure with corresponding stratification of blood supply and retinal segmentation into specific layers allows en-face visualization of the corresponding vascular supply for that layer. In-built automated software processes the image-information generating sets of perfusion indices (vessel density and flow index) for four en-face sections of the retina. Vessel density is defined as the percentage area occupied by vessels in the segmented area and flow index is defined as the average decorrelation values in the segmented area. The 4 en-face zones include: i) The superficial plexus, the capillary network in ganglion cell layer; ii) the deep plexus, a network of capillaries between the outer boundary of the inner plexiform layer and the midpoint of the outer plexiform layer (total thickness, 55 microns); iii) the outer retina (photoreceptors), does not have vessels, however, perfusion indices are still obtained, and iv) the choriocapillaries (choroid) with offshoot of 30 microns [Figure 2]. For each one of the en-face zones, the software acquires perfusion indices separately in parafoveal (central, 3 mm) and perifoveal (between 3-6 mm) areas [Figure 3]. Central capillary free foveal avascular zone (FAZ) is excluded automatically from measurements of the perfusion indices. However, values for FAZ area (mm²) can be obtained in the central area using the in-built software [Figure 4a and b].

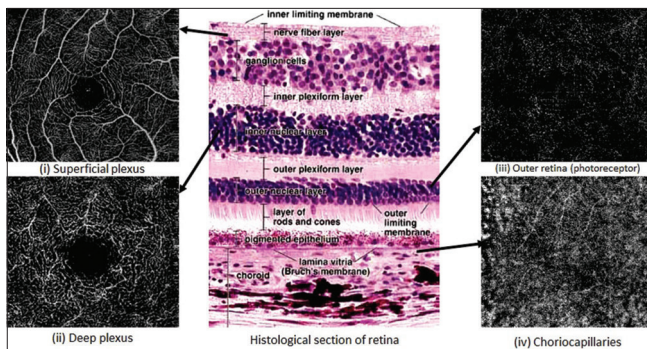


Figure 2. The location of different en-face zones in relation to histology of the human retina. The four en-face zones include, (i) the superficial plexus, the capillary network in ganglion cell layer and nerve fiber layer; (ii) the deep plexus, a network of capillaries in the inner plexiform layer with offshoot of 55 micron; (iii) the outer retina (photoreceptors), and (iv) the choriocapillaries (choroid) with offshoot of 30 microns.

ARTIFACTS WITH OCTA

In any imaging system used in medicine, the image formed of tissue passes through a series of rules. Unfortunately, even with the best imaging method, the image is not perfect and there are extra or missing pieces of information or translation, called “artifacts”. Spaide et al^[8] described various artifacts seen in OCTA images. These artifacts occur due to OCT image acquisition, intrinsic characteristics of the eye, eye motion, image processing, and display strategies. Because of the potential of artifacts, clinical evaluation along with viewing of the image is usually required for interpreting the results, much like what happens in modern radiology practice. In the usual clinical settings, images obtained by OCTA are excluded from analysis or interpretation if they have: i) Poor quality (with a signal strength index ≤ 40) or ii) residual motion artifacts (discontinuous vessel pattern or hazy images).

OCTA IN NORMAL EYES

Despite the use of newly available OCTA, there is limited information on normative database and its applicability in retinal pathologies. Matsunaga et al^[9] in a series on 5 healthy subjects reported that OCTA generates high-resolution, noninvasive angiograms qualitatively

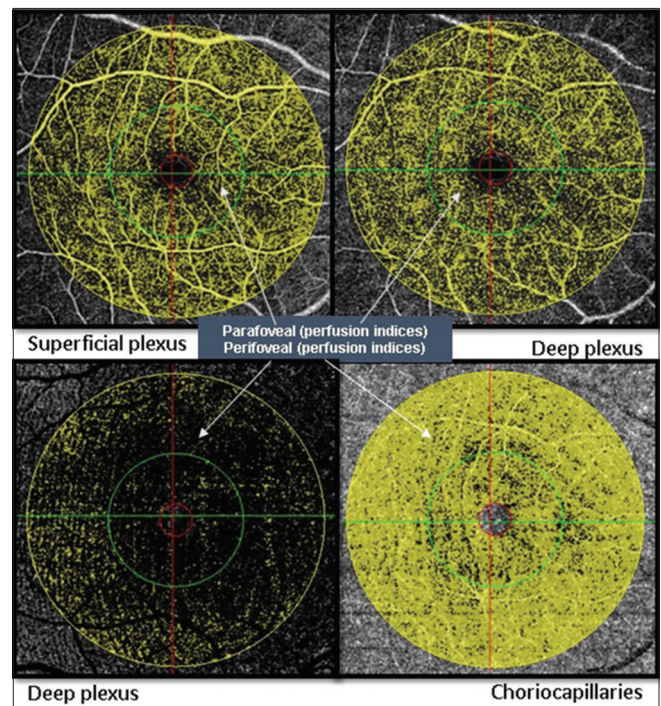


Figure 3. Graphical representation of 4 en-face zone. Each enface zone is divided into inner parafoveal (1-3 mm) and outer perifoveal (3-6 mm) regions. Perfusion indices (vessel density and flow index) are obtained separately for perifoveal and parafoveal regions sparing central foveal avascular zone of 1 mm.

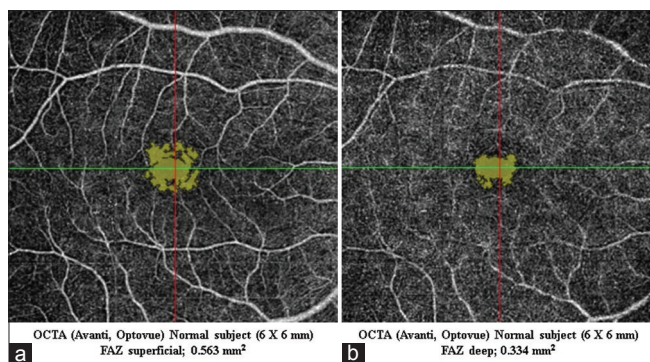


Figure 4. Optical coherence tomography angiography (OCTA) of the foveal avascular zone (FAZ) obtained using inbuilt software (mm²). (a) FAZ area in the superficial plexus of a normal subject; (b) the FAZ area obtained in the deep plexus of a normal subject.

comparable to conventional fluorescein angiography in normal subjects. The fovea is histologically comprised of a region solely containing cones with elongated outer segments underlying a capillary-free zone, designated as the FAZ. A number of studies on normal population have demonstrated variations in foveal thickness, FAZ shape, and FAZ area.^[10-13] The human retinal capillary network is composed of distinct layers of vessels and capillaries including the superficial (inner), and the deep (outer) vascular plexus.^[14] Samara et al^[15] described the use of OCTA for measurement of the FAZ area (using Image J software, Wayne Rasband, National Institutes of Health, Bethesda, Maryland, USA) of both the superficial and deep capillary plexuses in 70 healthy eyes and determined correlations with age and sex. They reported that the FAZ area is variable in the normal population with mean values of 0.266 ± 0.097 mm² in the superficial plexus (range, 0.071-0.527 mm²) and 0.495 ± 0.227 mm² in the deep plexus (range, 0.160-0.795 mm²). FAZ area was significantly larger in the deep plexus ($P < 0.0001$) as compared to the superficial plexus. No significant correlation was found between the area of the superficial or deep plexus FAZ, and age or sex. Savastano et al^[16] described retinal vascular anatomy by OCTA in 52 healthy eyes by analyzing the morphologic features of the superficial and deep networks. They reported existence of separate vascular networks in the inner retina: The superficial network (in the nerve fiber layer and the ganglion cell layer) and the deep network (in the outer plexiform layer). Both networks were interconnected with numerous vertical vessels.

OCTA IN DIABETICS

Diabetic retinopathy (DR) is one of the leading causes of blindness worldwide and patients tormented with this sight-threatening disease are expected to grow as dietary habits are changing especially in developing

nations. OCTA has already shown promise in being able to identify changes in DR.^[17] Ishibazawa et al^[18] reported that OCTA can clearly visualize microaneurysms and areas of retinal non-perfusion enabling closer observation of each layer of the retinal capillaries; therefore OCTA may be clinically useful to evaluate the microvascular status and effectiveness of treatments for DR. Agemy et al^[19] described progressive changes in DR as an easy quantitative interpretation of changes in retinal vascularity [Figure 5a-c]. They have shown a significant decrease in retinal capillary perfusion density with increase in severity of DR [Figure 6a-d]. de Carlo et al^[20] conducted a study on 61 eyes with diabetes mellitus with no clinical diabetic retinopathy and 28 control eyes of healthy subjects and reported that OCTA was able to image foveal microvascular changes not detected by clinical examination. FAZ area was 0.348 (0.1085-0.671) mm² in diabetic eyes and 0.288 (0.07-0.434) mm² in control eyes ($P = 0.04$). FAZ remodeling was seen more often in diabetic than in control eyes (36% vs. 11%) and so was capillary nonperfusion (21% of diabetic eyes vs. 4% of control eyes). Takase et al^[21] have also reported variations in the FAZ areas in diabetic eyes with and without diabetic retinopathy. The FAZ area in the superficial layer was 0.25 ± 0.06 mm² in 19 healthy eyes, 0.37 ± 0.07 mm² in 24 diabetic eyes without retinopathy and 0.38 ± 0.11 mm² in 20 eyes with DR. Diabetic eyes showed statistically significant FAZ enlargement compared to healthy eyes, irrespective of the presence of DR [Figure 7a-d].

OCTA IN AMD

Age-related macular degeneration (AMD) is the leading cause of irreversible vision loss in the United States in the 65 years and older age group. AMD is broadly classified into wet (exudative) and dry forms. Wet AMD is heralded by the formation of choroidal neovascular membrane (CNV), it accounts for approximately 15% of AMD cases and makes up the majority of cases with vision loss.^[22] Wet AMD is classified into 3 types. Type I CNV (occult), the most common type, originates in the choroid and extends mainly between Bruch's membrane and the retinal pigment epithelium (RPE). Type II CNV extends between the RPE below and retina above (the least common type). Type III CNV also called retinal angiomatous proliferation (RAP) is the second most common form of wet AMD.^[23] Palejwala et al^[24] reported the applicability of OCTA for early detection of CNV. In their series, they were able to detect early CNV (type I), which was difficult to identify using conventional FA and SD-OCT. El Ameen et al^[25] characterized Type II CNV using OCTA. In their cohort of 14 patients, all demonstrated a hyperflow vascular lesion in the outer retina, with a glomerulus (4/14) or medusa shape (10/14), surrounded by a dark halo, proving that OCTA

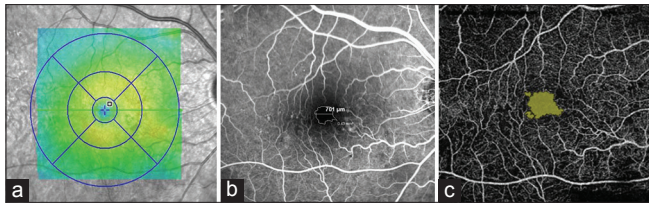


Figure 5. Images of a patient with non-proliferative diabetic retinopathy but no macular edema. (a) Macular thickness map using spectral domain optical coherence tomography (SD-OCT). (b) Conventional fluorescein angiography (FA) with leaking micro aneurysm and ischemia temporal to the fovea. (c) optical coherence tomography angiography (OCTA) image of the superficial plexus of the same patient shows better delineation of the ischemic area as compared to FA.

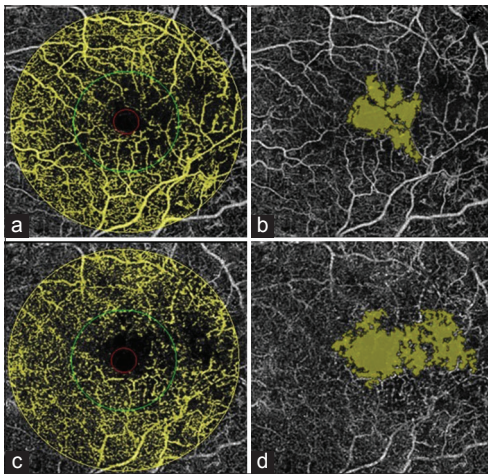


Figure 7. Image of a patient with mild non-proliferative diabetic retinopathy and diabetic macular edema. (a and b) Showing the en-face image of the superficial plexus with distortion of foveal avascular zone (FAZ). (c and d) Showing the en-face image of the deep plexus with distortion of FAZ, more profound than in superficial plexus. This happens due to accumulation of fluid in retinal layers.

is highly sensitive in detecting CNV [Figure 8a-c]. There are reports^[26,27] where OCTA has been able to identify a distinct neovascular complex in RAP lesions. The neovascular complex of RAP appears as a small tuft of bright, high-flow tiny vessels with curvilinear morphology located in the outer retinal layers with a feeder vessel communicating with the inner retinal circulation.

Coscas et al^[28] evaluated 80 eyes with wet AMD using OCTA scanning and identified different patterns of CNV. Their cohort also underwent traditional multimodal imaging, based on FA, indocyanine green angiography (ICGA), and spectral domain OCT (SD-OCT) to assess the need for treatment. Based on OCTA findings, they classified wet AMD into two patterns. Pattern I, if it showed all or at least three of the following five features. 1) A well-defined (lacy-wheel or sea-fan shaped) CNV lesion in contrast to one with long

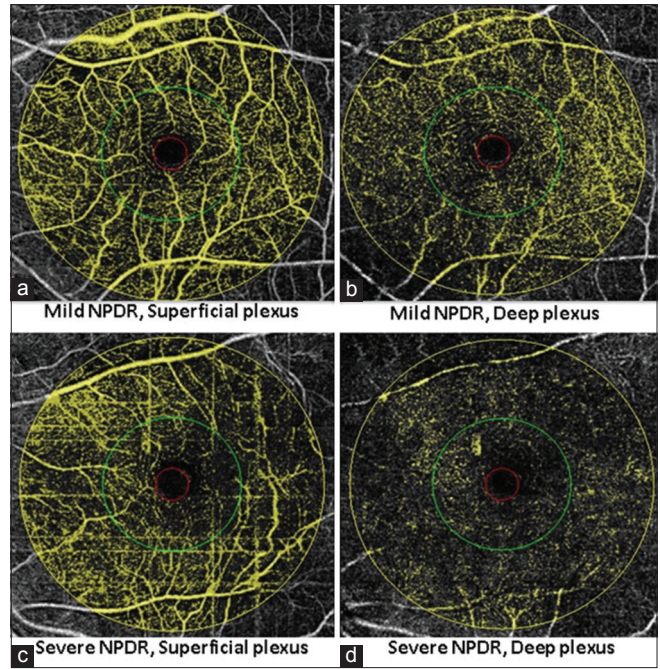


Figure 6. Images of a patient with mild non-proliferative diabetic retinopathy (a and b) in comparison to a patient with severe non-proliferative diabetic retinopathy (c and d). There is decrease in perfusion indices (vessel density and flow index) as the severity of diabetic retinopathy increases.

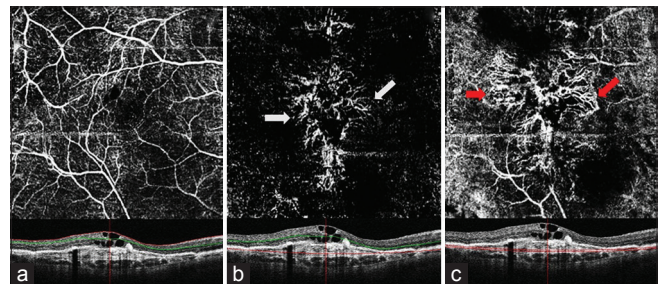


Figure 8. Optical coherence tomography angiography (OCTA) of a patient with CNV (mixed type) with corresponding spectral domain OCT. (a) The OCTA image of superficial plexus, with associated foveal cystic changes. (b) "Medusa head" appearance of neo-vascular (NV) membrane in the photoreceptor zone (white arrows). (c) NV membrane extends in the deeper choroid (red arrows) with extensive arborization.

filamentous linear vessels. 2) Branching, numerous tiny capillaries, typical of a recent lesion, in contrast to rare large mature vessels, typical of a mature one. 3) Presence of anastomoses and loops. 4) Morphology of the vessel termini, assessing the presence of a peripheral arcade in contrast to a "dead tree" appearance. 5) Presence of a perilesional hypointense halo considered as regions of choriocapillaris alteration, either corresponding to flow impairment steal or localized atrophy. A perilesional hypointense halo was only reported to be visible in an en face section external to Bruch's membrane, and after exclusion of possible masking effects due to

intraretinal, subretinal or sub-RPE blood, and fluid or pigment accumulation. A CNV lesion was considered as Pattern II, if it showed less than three of the previously reported OCTA features. Jia et al^[4] reported that OCTA can provide depth-resolved information of CNV and quantitative information regarding CNV flow and area. Moulton et al^[29] demonstrated choriocapillaris alterations surrounding the CNV. de Carlo et al^[30] described characteristics as well as the sensitivity and specificity of detection of CNV using OCTA. In their cohort of 48 eyes, specificity of CNV detection on OCTA as compared with FA was high (91%) but sensitivity was 50% (4/8).

Monthly injections of anti-vascular endothelial growth factor (VEGF) agents is highly successful and currently the treatment of choice for wet AMD.^[31] Lumbroso et al^[32] observed morphologic changes of CNV vessels using OCTA, over weeks after treatment with intravitreal anti-VEGF injections and noted alternating regression and progression phases. Twenty-four hours after injection, there was a decrease in the dimensions of CNV with loss of smaller vessels and narrowing of larger vessels. Between days 7 and 12, there was continued decrease in the size of CNV, whereas the central trunk remained unchanged. The maximum decrease in vessels was noted between days 13 and 18. Re-proliferation was noted after day 28 [Figure 9a-f].

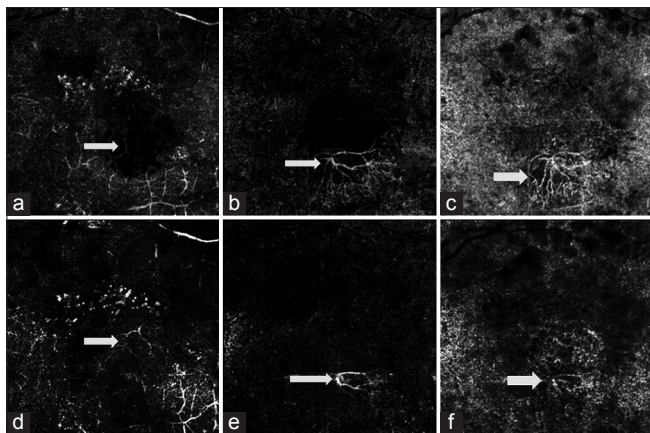


Figure 9. Optical coherence tomography angiography (OCTA) images of a patient with choroidal neovascularization (CNV) before (a-c) and 2 weeks after treatment with anti VEGF (d-f). (a) OCTA image of the deep plexus, with cystic changes causing obliteration of vascular reflection. (b) NV membrane in the photoreceptor zone. (c) NV membrane extending in the deeper choroid. (d) OCTA of the deep retinal plexus after treatment with anti-VEGF. Vessels in the deeper retinal plexus are better visualized due to regression of cystic changes. (e) Regression of the NV membrane in the photoreceptor zone. Obliteration of smaller vessels and decrease in the size of main feeder trunk is noted. (f) Regression in the size of NV membrane is also noted in the choriocapillaris layer.

OCTA IN IDIOPATHIC MACULAR TELANGIECTASIA

Macular telangiectasia Type 2 (MacTel2) is a disease of the macular area, in which neurodegenerative changes (loss of Muller cells) play a central role.^[33-35] Abnormalities in the MacTel area include whitening of the inner retina, crystal deposits in the nerve fiber layer, breakdown of the external limiting membrane/ellipsoid zone, cyst formation in the inner retina, cavitation of the outer retina, perifoveal capillary leakage, parafoveal venular dilation, pigment proliferation in the retina, and subretinal neovascularization.^[36] Zeimer et al^[37] attempted to establish an association between morphologic findings noted on OCTA and FA in patients with MacTel type 2. On OCTA, they noted retinal vascular pathology in the deep capillary network including enlargement of vessels and larger intervascular spaces, dilated, dendritic appearance of vessels, telangiectasis, reduction and/or loss of capillary density, and the presence of anastomoses toward the superficial capillary network. Vascular changes could appear at any stage of the disease. RPE-proliferations were often associated with “contraction” of surrounding vessels. Their OCTA finding showed comparable results to that of vascular changes in FA, proposing ectatic capillaries mainly in the deeper capillary network in early stages of the disease. With progression of disease, vascular changes were noted in the superficial capillary network. Later, new vessels were seen in the avascular outer retina and an irregular pattern appeared in the underlying choriocapillaris.

OCTA IN RETINAL VESSEL OCCLUSION

Retinal vein occlusions (RVOs) are one of the major causes of vision loss and impairment. The commonly accepted pathophysiology of central retinal vein occlusion (CRVO) and branch retinal vein occlusion (BRVO) is thrombosis of the retinal vein, leading to variably impaired capillary perfusion and retinal ischemia.^[38] Kashani et al^[39] reported findings in OCTA of 26 eyes with RVO. They showed that OCTA findings were consistent with clinical, anatomic and fluorescein angiographic findings including areas of impaired vascular perfusion, retinal atrophy, vascular dilation, shunt vessels, and some forms of intraretinal edema. Hence, OCTA in conjunction with SD-OCT could be at least equally effective as FA for evaluation and management of macular complications in patients with retinal vein occlusions [Figure 10a-c]. Bonini Filho et al^[40] described the retinal microvasculature of eyes with

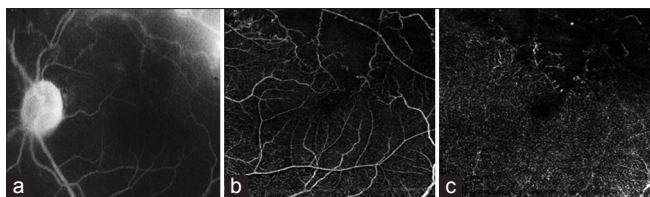


Figure 10. Comparison of fluorescein angiography image (a) in branch retinal vein occlusion with that of optical coherence tomography angiography (OCTA) images obtained at the superficial (b) and deep (c) retinal plexus. Ischemic area due to capillary drop out is better delineated using OCTA. However, leaking vessels due to neovascularization are not identified using OCTA.

nonarteritic retinal artery occlusion (RAO) based on OCTA and concluded that OCTA can accurately discern retinal capillary plexuses at different levels in eyes with RAO. OCTA may be sensitive enough for characterizing the extent of macular ischemia and monitoring vascular flow changes during the course of RAO.

MISCELLANEOUS CONDITIONS

OCTA in Sickle Cell Retinopathy

In asymptomatic sickle cell retinopathy, SD-OCT shows temporal macular thinning,^[41] the cause of which is not well understood. Histopathologic studies of sickle cell retinopathy and other vaso-occlusive diseases have shown selective atrophy of inner retinal layers (ganglion cell layer, inner nuclear layer, and Müllerian glia of the retina) in several eyes after retinal infarction.^[41] Han et al^[42] reported that OCTA is probably more sensitive than FA in identifying these early areas of non-perfusion in patients with sickle cell disease where alteration of the deep capillary network is noted [Figure 11a-c].

OCTA in Central Serous Chorioretinopathy

Idiopathic central serous chorioretinopathy (ICSC) typically affects the young and middle aged population. Patients usually develop one (or sometimes more) small area (s) of serous detachment of RPE in the macula or paramacular area, generally associated with serous detachment of the overlying and surrounding retina. Demonstration of ICSC is based on angiographic pooling of subretinal fluid, appearance of defects in the RPE, and typical dye leakage from the choroid into the subretinal space. Most cases have good prognosis with spontaneous resolution along with good visual recovery. However, a few can have compromised visual outcome. This can be due to the recurrent nature of the disease or to development of secondary neovascular membranes. Bonini Filho et al^[43] reported that OCTA has high sensitivity and specificity; comparable to FA for detection of CNV in eyes with chronic ICSC.

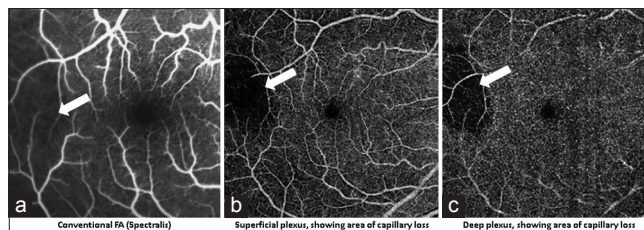


Figure 11. Conventional fluorescein angiography (FA, a) in comparison to optical coherence tomography angiography (OCTA) images of the superficial (b) and deep (c) plexus in a patient with sickle cell disease. Temporal area of thinning (confirmed using spectral domain OCT) showed capillary dropout on OCTA, which is not as clearly visible on FA. (b) Temporal area of avascularity in superficial plexus, calculated using in built software was 2.204 mm². (c) Temporal area of avascularity calculated using in built software in deep plexus was 1.972 mm².

Limitations of OCTA

Despite the potential benefits of OCT angiography, our expectations of technology must be tempered, given our limited experience. With any new technique, we must first validate the accuracy and reproducibility of the data. A large multi-centric multi-ethnic study comparing this modality with FA may also be instructive in order to better understand the significance of vascular patterns observed with OCTA and to correlate this to sites of leakage. A major challenge is to develop automated repeatable segmentation algorithms that reliably identify specific retinal vascular layers, even in the diseased and poorly fixating eyes. At this time, the identification of neovascular tissue must be performed manually, a time-consuming task as compared with review of FA images. Further limitations include suboptimal correction for eye motion artifacts and projection artifact from superficial vessels during imaging of deeper layers.

Distinguishing pathologic vessels from the normal vasculature may be challenging in certain cases. Moreover, the SSADA technique has relatively poor axial resolution (~15 μm) due to signal averaging, limiting the identification of small-caliber vessels. Using the current commercially available technology, OCTA is more prone to artifacts than FA. The larger superficial retinal vessels cause a “ghost image” producing shadow artifacts, when segmenting deeper layers, especially in the outer retina. This can make it more difficult to appreciate the presence of abnormal vasculature in deeper layers and have a bearing on perfusion index. Because OCTA uses the principle that movement in the back of the eye represents blood flow, it is prone to motion artifact. White lines (representing decorrelation signals) appear in areas of the scan if the patient loses fixation or moves. Conversely, blinks appear as a black line across the scan because the OCT signal is blocked from reaching the retina and

the software, thus, detects no movement. Blood cells should be the only moving object in the retina and some non-vascular structures such as fine tissue may also cause a decorrelation signal, especially if the patient is moving or poorly fixating. OCTA may also miss areas of slow blood flow such as in microaneurysms or fibrotic CNV. Since OCTA relies on changes between consecutive B-scans, it will detect flow only above a minimum threshold, the slowest detectable flow, which is determined by the time between the two sequential OCT B-scans. Consequently, lesions which have flow below the slowest detectable flow cannot be visualized using this imaging technique. Increasing the time between consecutive OCT B-scans could allow for increased flow detection while it would offer a trade-off due to increased movement artifact. Finally, it remains unknown how the additional information gained from this technique can be used in routine clinical practice.

The Future of OCTA

This powerful feature has enormous implications for understanding tissue perfusion in the absence of obvious morphological changes. A flow index of the retina and optic nerve head can be used to ascertain perfusion compromise even before the presence of clinically visible signs. Incorporation of an eye-tracking device that corrects for eye movements during the scanning process and also coupled with follow-up function that leads to highly reproducible retinal perfusion measurements will lay the foundation of its practical applicability. This will eventually improve inter-operator and inter-session repeatability. In the future, faster scanning speeds would help obtain larger fields of view with higher resolution and decrease motion artifacts. Use of higher wave length (swept-source) monochromatic light will also enable acquisition of more accurate information of deeper structures.

SUMMARY

OCTA is an evolving field; however, the fact that it can detect flow compromise, prior to the appearance of clinically meaningful changes is intriguing. OCTA will also be advantageous in improving patient care by decreasing disease morbidity through earlier detection and intervention. Further studies are required in larger cohorts to establish the possible association between retinal flow compromise and its bearing on retinal pathologies. Future innovations in both hardware and software technologies are expected to aid in the assessment of chorioretinal diseases in more detail.

Financial Support and Sponsorship

Nil.

Conflicts of Interest

There are no conflicts of interest.

REFERENCES

- Grover S, Murthy RK, Brar VS, Chalam KV. Normative data for macular thickness by high-definition spectral-domain optical coherence tomography (spectralis). *Am J Ophthalmol* 2009;148:266-271.
- Spaide RF, Klancnik JM Jr., Cooney MJ. Retinal vascular layers imaged by fluorescein angiography and optical coherence tomography angiography. *JAMA Ophthalmol* 2015;133:45-50.
- Jia Y, Tan O, Tokayer J, Potsaid B, Wang Y, Liu JJ, et al. Split-spectrum amplitude-decorrelation angiography with optical coherence tomography. *Opt Express* 2012;20:4710-4725.
- Jia Y, Bailey ST, Wilson DJ, Tan O, Klein ML, Flaxel CJ, et al. Quantitative optical coherence tomography angiography of choroidal neovascularization in age-related macular degeneration. *Ophthalmology* 2014;121:1435-1444.
- Jia Y, Wei E, Wang X, Zhang X, Morrison JC, Parikh M, et al. Optical coherence tomography angiography of optic disc perfusion in glaucoma. *Ophthalmology* 2014;121:1322-1332.
- Witmer MT, Parlitsis G, Patel S, Kiss S. Comparison of ultra-widefield fluorescein angiography with the Heidelberg Spectralis® noncontact ultra-widefield module versus the Optos® Optomap®. *Clin Ophthalmol* 2013;7:389-394.
- Weinhaus RS, Burke JM, Delori FC, Snodderly DM. Comparison of fluorescein angiography with microvascular anatomy of macaque retinas. *Exp Eye Res* 1995;61:1-16.
- Spaide RF, Fujimoto JG, Waheed NK. Image artifacts in optical coherence tomography angiography. *Retina* 2015;35:2163-2180.
- Matsunaga D, Yi J, Puliafito CA, Kashani AH. OCT angiography in healthy human subjects. *Ophthalmic Surg Lasers Imaging Retina* 2014;45:510-515.
- Bresnick GH, Condit R, Syrjala S, Palta M, Groo A, Korth K. Abnormalities of the foveal avascular zone in diabetic retinopathy. *Arch Ophthalmol* 1984;102:1286-1293.
- Wu LZ, Huang ZS, Wu DZ, Chan E. Characteristics of the capillary-free zone in the normal human macula. *Jpn J Ophthalmol* 1985;29:406-411.
- Arend O, Wolf S, Jung F, Bertram B, Pöstgens H, Toonen H, et al. Retinal microcirculation in patients with diabetes mellitus: Dynamic and morphological analysis of perifoveal capillary network. *Br J Ophthalmol* 1991;75:514-518.
- John D, Kuriakose T, Devasahayam S, Braganza A. Dimensions of the foveal avascular zone using the Heidelberg retinal angiogram-2 in normal eyes. *Indian J Ophthalmol* 2011;59:9-11.
- Snodderly DM, Weinhaus RS, Choi JC. Neural-vascular relationships in central retina of macaque monkeys (*Macaca fascicularis*). *J Neurosci* 1992;12:1169-1193.
- Samara WA, Say EA, Khoo CT, Higgins TP, Magrath G, Ferenczy S, et al. Correlation of foveal avascular zone size with foveal morphology in normal eyes using optical coherence tomography angiography. *Retina* 2015;35:2188-2195.
- Savastano MC, Lumbroso B, Rispoli M. *In vivo* characterization of retinal vascularization morphology using optical coherence tomography angiography. *Retina* 2015;35:2196-2203.
- Hwang TS, Jia Y, Gao SS, Bailey ST, Lauer AK, Flaxel CJ, et al. Optical coherence tomography angiography features of diabetic retinopathy. *Retina* 2015;35:2371-2376.
- Ishibazawa A, Nagaoka T, Takahashi A, Omae T, Tani T, Sogawa K, et al. Optical coherence tomography angiography in diabetic retinopathy: A prospective pilot study. *Am J Ophthalmol* 2015;160:35-44.e1.

19. Agemy SA, Sripsema NK, Shah CM, Chui T, Garcia PM, Lee JG, et al. Retinal vascular perfusion density mapping using optical coherence tomography angiography in normals and diabetic retinopathy patients. *Retina* 2015;35:2353-2363.
20. de Carlo TE, Chin AT, Bonini Filho MA, Adhi M, Branchini L, Salz DA, et al. Detection of microvascular changes in eyes of patients with diabetes but not clinical diabetic retinopathy using optical coherence tomography angiography. *Retina* 2015;35:2364-2370.
21. Takase N, Nozaki M, Kato A, Ozeki H, Yoshida M, Ogura Y. Enlargement of foveal avascular zone in diabetic eyes evaluated by en face optical coherence tomography angiography. *Retina* 2015;35:2377-2383.
22. Age-Related Eye Disease Study Research Group. Risk factors associated with age-related macular degeneration. A case-control study in the age-related eye disease study: Age-Related Eye Disease Study report number 3. *Ophthalmology* 2000;107:2224-2232.
23. Jung JJ, Chen CY, Mrejen S, Gallego-Pinazo R, Xu L, Marsiglia M, et al. The incidence of neovascular subtypes in newly diagnosed neovascular age-related macular degeneration. *Am J Ophthalmol* 2014;158:769-779.e2.
24. Palejwala NV, Jia Y, Gao SS, Liu L, Flaxel CJ, Hwang TS, et al. Detection of nonexudative choroidal neovascularization in age-related macular degeneration with optical coherence tomography angiography. *Retina* 2015;35:2204-2211.
25. El Ameen A, Cohen SY, Semoun O, Miere A, Srour M, Quaranta-El Maftouhi M, et al. Type 2 neovascularization secondary to age-related macular degeneration imaged by optical coherence tomography angiography. *Retina* 2015;35:2212-2218.
26. Kuehlewein L, Dansingani KK, de Carlo TE, Bonini Filho MA, Iafe NA, Lenis TL, et al. Optical coherence tomography angiography of type 3 neovascularization secondary to age-related macular degeneration. *Retina* 2015;35:2229-2235.
27. Miere A, Querques G, Semoun O, El Ameen A, Capuano V, Souied EH. Optical coherence tomography angiography in early type 3 neovascularization. *Retina* 2015;35:2236-2241.
28. Coscas GJ, Lupidi M, Coscas F, Cagini C, Souied EH. Optical coherence tomography angiography versus traditional multimodal imaging in assessing the activity of exudative age-related macular degeneration: A new diagnostic challenge. *Retina* 2015;35:2219-2228.
29. Moulton E, Choi W, Waheed NK, Adhi M, Lee B, Lu CD, et al. Ultrahigh-speed swept-source OCT angiography in exudative AMD. *Ophthalmic Surg Lasers Imaging Retina* 2014;45:496-505.
30. de Carlo TE, Bonini Filho MA, Chin AT, Adhi M, Ferrara D, Bauman CR, et al. Spectral-domain optical coherence tomography angiography of choroidal neovascularization. *Ophthalmology* 2015;122:1228-1238.
31. Rosenfeld PJ, Brown DM, Heier JS, Boyer DS, Kaiser PK, Chung CY, et al. Ranibizumab for neovascular age-related macular degeneration. *N Engl J Med* 2006;355:1419-1431.
32. Lumbroso B, Rispoli M, Savastano MC. Longitudinal optical coherence tomography – Angiography study of type 2 naive choroidal neovascularization early response after treatment. *Retina* 2015;35:2242-2251.
33. Powner MB, Gillies MC, Zhu M, Vevis K, Hunyor AP, Fruttiger M. Loss of Müller's cells and photoreceptors in macular telangiectasia type 2. *Ophthalmology* 2013;120:2344-2352.
34. Shen W, Fruttiger M, Zhu L, Chung SH, Barnett NL, Kirk JK, et al. Conditional Müller cell ablation causes independent neuronal and vascular pathologies in a novel transgenic model. *J Neurosci* 2012;32:15715-15727.
35. Spaide RF, Klancnik JM Jr., Cooney MJ. Retinal vascular layers in macular telangiectasia type 2 imaged by optical coherence tomographic angiography. *JAMA Ophthalmol* 2015;133:66-73.
36. Charbel Issa P, Gillies MC, Chew EY, Bird AC, Heeren TF, Peto T, et al. Macular telangiectasia type 2. *Prog Retin Eye Res* 2013;34:49-77.
37. Zeimer M, Gutfleisch M, Heimes B, Spital G, Lommatzsch A, Pauleikhoff D. Association between changes in macular vasculature in optical coherence tomography- and fluorescein – Angiography and distribution of macular pigment in type 2 idiopathic macular telangiectasia. *Retina* 2015;35:2307-2316.
38. MacDonald D. The ABCs of RVO: A review of retinal venous occlusion. *Clin Exp Optom* 2014;97:311-323.
39. Kashani AH, Lee SY, Moshfeghi A, Durbin MK, Puliafito CA. Optical coherence tomography angiography of retinal venous occlusion. *Retina* 2015;35:2323-2331.
40. Bonini Filho MA, Adhi M, de Carlo TE, Ferrara D, Bauman CR, Witkin AJ, et al. Optical coherence tomography angiography in retinal artery occlusion. *Retina* 2015;35:2339-2346.
41. Murthy RK, Grover S, Chalam KV. Temporal macular thinning on spectral-domain optical coherence tomography in proliferative sickle cell retinopathy. *Arch Ophthalmol* 2011;129:247-249.
42. Han IC, Tadarati M, Scott AW. Macular vascular abnormalities identified by optical coherence tomographic angiography in patients with sickle cell disease. *JAMA Ophthalmol* 2015;133:1337-1340.
43. Bonini Filho MA, de Carlo TE, Ferrara D, Adhi M, Bauman CR, Witkin AJ, et al. Association of choroidal neovascularization and central serous chorioretinopathy with optical coherence tomography angiography. *JAMA Ophthalmol* 2015;133:899-906.