

LETTERS TO THE EDITOR

Longus cervicis colli "myositis" (syn: retropharyngeal tendinitis)

Acute spontaneous pain in the neck and dysphagia are both common symptoms, but the combination of the two is rare and can cause a challenging anatomical and diagnostic puzzle. This report draws attention to a clinically diagnosable condition—"retropharyngeal tendinitis"—which is often unrecognised.

A 42 year old secretary in excellent health fell, in the sitting position, into a stream. She had minor abrasions of the limbs but did not hurt her neck or head. Ten days later she developed a stiff neck. Turning the neck to the left side was painful, making driving difficult. After two days pain increased; prescribed methocarbamol failed to provide relief. On day 3 she had painful difficulty in swallowing, not in the throat but in the right side of the neck "as if the muscles and ligaments were strained", and painful movement was relieved when flexing her neck.

She consulted a neurophysiologist who found no neurological abnormality apart from painful restriction of rotation and lateral flexion, with no visible abnormality in the throat and no external bruising, swelling, or lymphadenopathy. No neurophysiological, radiological, or systemic studies were undertaken.

Dysphagia increased until she could swallow only small sips of water. She held her neck to ease swallowing. She also took to holding her head with both hands to enable her to lay her head on the pillow, and to sit up when getting out of bed. Sleeping in a soft collar provided slight relief. On the seventh day pain improved; swallowing remained difficult, but caused no pain in the throat, only in the side of the neck. By day 10, pain was less severe, movements less limited, and the next day she could swallow solid foods and liquids. On the 12th day symptoms had all resolved, and 15 months later she had had no recurrence and no other illness. When she sought neurological opinion she was largely recovered and displayed no physical abnormality to justify radiography or MRI.

The unusual combination of such distinctive symptoms suggests a lesion in the

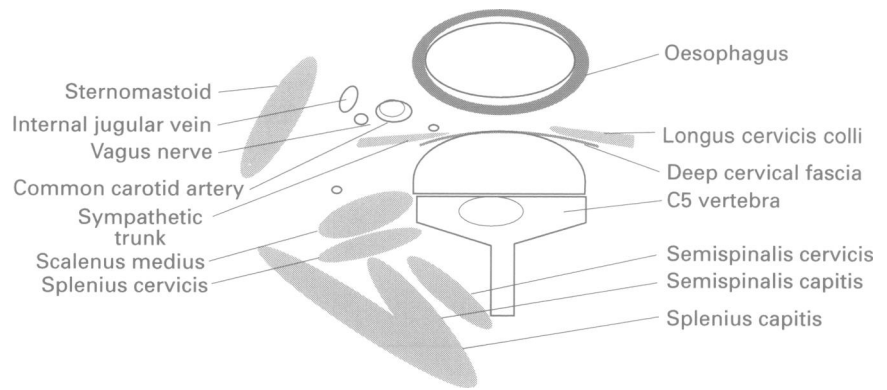


Figure 2 Diagrammatic transverse section through neck to show arrangement of deep cervical fascia and longus cervicis colli.

retropharyngeal space involving the prevertebral muscles. I draw attention to a clinically diagnosable condition, "retropharyngeal tendinitis",^{1,2} which is not well known, or is unrecognised. The salient features are: (1) The curious location of pain, mainly in the side of the neck. This is quite different from that experienced in common neck sprains of whiplash injury, which are maximal in the posterior neck muscles with radiation to the shoulders, occiput, and interscapular regions. (2) Pain aggravated by movement like acute disk lesions or whiplash injury, but unlike these mechanical lesions, is relieved by anteroflexion. The patient prefers to sit upright, and lays down with great difficulty. (3) Pain is dramatically increased by swallowing. (4) Painful dysphagia is felt not in the throat, but in the side of the neck. Patients may be obliged to hold their necks to allow swallowing. (5) The illness is unaccompanied by fever or systemic disturbance and is self limiting.

Kaplan and Eacey¹ described similar features and showed calcification in the tendon of the longus colli muscle. Fahlgren added three more cases³ and noted increased radiological thickness of the prevertebral soft tissues which he compared with normal subjects. Confirmation by CT and MRI were added in another case report.⁴

Ekbom *et al* have described seven such cases in whom radiography and MRI confirmed a smooth homogeneous soft tissue swelling with increased signal intensity on T2 weighted images in the acute stages, regressing or disappearing in remission. Swelling was anterior to C1-2 in all cases and in some it extended through the whole cervical spine, with calcification at C1-2 in five of the seven patients.⁵ Control subjects (n = 12) showed a mid-sagittal thickness of prevertebral soft tissues of 2.5 (SD 0.8) mm at C1, 2.3 (SD 0.5) mm at C2, 3.3 (SD 0.8) mm at C4; compared with 8.6 (SD 2.4) mm at C1, 6.1 (SD 1.5) mm at C2, and 6.6 (SD 2.3) mm at C4 in patients (fig 1). Diagnosis can be confirmed by acute and follow up lateral x-ray films of the neck. Computed tomography and MRI can supplement this simple investigation, when there is doubt.

The main structure in the prevertebral space (fig 2) is the longus cervicis colli which consists of three interconnecting parts: lower oblique, upper oblique and vertical portions. They arise from the T2-4 vertebral bodies and their anterior tubercles, and insert into C5-6 vertebrae, the atlas, and bodies of C2-4 respectively. Its nerve supply is the anterior primary rami of C3 through C8. It acts as a flexor and rotator of the neck.

Importantly, the lower half is related to the oesophagus.

The pathology is described as "retropharyngeal tendinitis", but the maximum radiographic change is between the atlas and C4, and extends caudally, so that the muscle belly is contained in the swelling. "Longus cervicis myositis" would be a better designation. I would surmise that in some instances of trauma, a haematoma or contusion could produce the same syndrome. In published cases, oedema of the longus cervicis is demonstrated on imaging, and its resolution suggests an inflammatory lesion. There was no evidence of an inflammatory lesion in my patient. In the absence of a known sprain, and, with an onset 10 days after her fall, a traumatic cause is uncertain. In whiplash injury pain can be delayed,⁶ but is always evident within 48 hours. Treatment is symptomatic with spontaneous complete recovery in seven to 14 days.

J M S PEARCE
304 Beverley Road,
Anlaby,
Hull HU10 7BG, UK

- 1 Kaplan MJ, Eacey RD. Calcific tendinitis of the longus colli muscle. *Ann Otol Rhinol Laryngol* 1984;93:215-9.
- 2 Ring D. Calcific tendinitis of longus cervicis colli. *J Bone Joint Surg—A* 1994;76:1635-42.
- 3 Fahlgren H. Retropharyngeal tendinitis: three probable cases with an unusually low epicentre. *Cephalalgia* 1988;8:105-10.
- 4 Arterian DJ, Lipman JK, Scidmore GK, Brant-Zawadzki M. Acute neck pain and dysphagia due to tendinitis of the longus colli: CT and MRI findings. *Neuroradiology* 1989;31:166-9.
- 5 Ekbom K, Torhall J, Annell K, Träff J. Magnetic resonance imaging in retropharyngeal tendinitis. *Cephalalgia* 1994;14:266-9.
- 6 Pearce JMS. Polemics of chronic whiplash injury [editorial]. *Neurology* 1994;44:1993-8.

Cholinesterase inhibition in Parkinson's disease

Senile dementia of the Alzheimer type (SDAT) is associated with degeneration of the nucleus basalis, and consequently with a cholinergic deficit. Recent trials with the acetylcholinesterase inhibitor tacrine have shown promise for partial reversal of this dementia in some patients.^{1,2} Those patients with Alzheimer's disease with some of the clinical stigmata of Lewy body dementia may respond best to tacrine.^{3,4}

On the other hand, Parkinson's disease was long ago associated with a cholinergic deficit, which may be more profound than that seen in SDAT,⁵ suggesting a theoretical reason for giving a procholinergic drug in

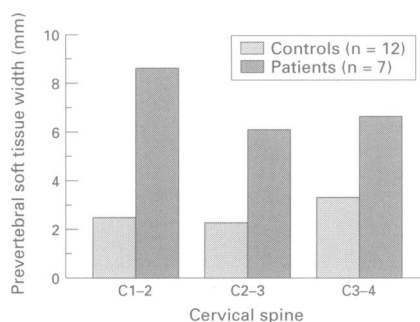


Figure 1 Prevertebral soft tissue width in retropharyngeal tendinitis and controls (data from Ekbom *et al*⁵).

this condition. Moreover, in the later stages of Parkinson's disease, a debilitating confusional state with psychotic features is common. Although in some cases this parkinsonian dementia overlaps SDAT, there is presumably a high incidence of pure Lewy body dementia in parkinsonian patients with dementia. As anticholinergic drugs have mild antiparkinsonian effects, however, it is likely that many neurologists will instinctively think that a procholinergic drug will worsen the rigidity.

We report here the results of a pilot study on the use of tacrine in patients with parkinsonian dementia. Seven patients were selected for the study (five men and two women, age range 66 to 82, mean 73.9 years). Patients were selected according to the following criteria: (a) diagnosis of Parkinson's disease before the onset of dementia; (b) rigidity that had initially responded to levodopa; (c) a confusional state incorporating visual hallucinations and exacerbated by dopaminergic drugs; (d) a normal brain MRI or CT within two months of the study, to exclude multi-infarct dementia and reduce the possibility of concurrent SDAT.

All patients had carried the diagnosis of Parkinson's disease for several years before the onset of dementia (mean 7.6 (range 3-18) years). The diagnosis was made in each case on the basis of a syndrome of progressive rigidity and bradykinesia. Four patients also had a mild resting tremor at the time of diagnosis. In each case these presenting symptoms had initially responded well to levodopa, and all patients were taking levodopa at the time of entry into the study. No patient had exhibited dyskinesias as a result of treatment with levodopa. None was currently using dopamine agonists, although four had previously used such drugs but had discontinued them because of worsening confusion. Selegiline had also been used in all patients before the study, and in all patients this drug had been discontinued for the same reason. None had used selegiline within four months of the start of the study. Four subjects had severe motor disability (Hoehn and Yahr stage 5) and were confined to a wheelchair or bedridden. Two were stage 4, and could walk with assistance, and one was stage 3, but had had a recent series of falls. Patients had baseline serum glutamic oxaloacetic transaminase and glutamic pyruvic transaminase studies and were started on tacrine at 10 mg four times daily. Liver function tests were obtained on a weekly basis. After two weeks, if transaminase concentrations remained stable, the dose was increased to 20 mg three times daily and maintained at that level for at least two months. All patients underwent Folstein (mini mental state) testing immedi-

ately before treatment, and again after two months of treatment. Unified Parkinson's disability rating scale (UPDRS) scores were also obtained before and after treatment, and the motor categories by direct examination, and the daily activity scores by interview of the spouse or care giver. All patients were maintained on levodopa without change during the trial.

In all cases the frequency of hallucinations was greatly reduced after treatment, and in five cases hallucinations were essentially eliminated. All seven patients showed much improvement in both Folstein scores (mean improvement 7.1, range 3 to 13, $P < 0.0001$) and UPDRS scores (items 1-31: mean score before treatment 79.3, mean score after treatment 29.6, $P < 0.0001$). The table shows these results. Although there was no characteristic pattern of mental change, improvements were seen mainly in the categories of orientation, attention (serial 7s), and visuospatial awareness (copying a geometric figure). In addition, all patients were able to walk independently, improvements in gait corresponding roughly to improvements in mentation. There was no characteristic pattern of motor improvement, and in most patients improvements were seen in most categories of the UPDRS.

One patient (No 2) showed further improvements, according to her family, and underwent repeat Folstein and UPDRS testing seven months after initiation of treatment. At this time the Folstein score had risen to 28/30 (compared with 15/30 before treatment), and the UPDRS had shown a further reduction from 25 to 8. No further improvements were noted in any other patient by their families, and no other patient was retested. On the other hand patient No 4, who had the longest history of Parkinson's disease (15 years), started to decline after six months of treatment with tacrine, indicating possible limits to the duration of benefit in some patients.

In this pilot study of the use of tacrine in parkinsonian dementia, considerable improvements were seen in all patients. The finding of motor improvement was unexpected. Before starting this investigation it was thought that even if the dementia ameliorated patients might become more rigid, as anticholinergic drugs have slight antiparkinsonian motor effects. Indeed there is at least one reported case in which rigidity is said to have developed in a patient with Alzheimer's disease treated with tacrine.⁶ In our study, on the contrary, patients became less rigid. This finding may perhaps be understood if the degenerating cholinergic neurons in Parkinson's disease are not striatal interneurons but cortical projections, at least some of which are involved (directly or indirectly) in the generation of movements.

Definitive conclusions regarding the pathogenesis of this effect, however, must await confirmation and further study.

The psychotic confusional state seen in the later stages of Parkinson's disease is a common and significant source of morbidity. Our results suggest that low dose tacrine is efficacious in its treatment. In our study population tacrine dispensed with the need for conventional antipsychotic medications, and was associated with motor improvements. Although these preliminary findings are highly suggestive, caution should be exercised in their interpretation until confirmed by a blinded placebo controlled study, preparations for which are underway.

MICHAEL HUTCHINSON

ENRICO FAZZINI

Department of Neurology,
New York University Medical Center,
550 First Avenue,
New York NY 10016, USA

Correspondence to: Dr M Hutchinson.

- Knapp MJ, Knopman DS, Solomon PR, Pendlebury WW, Davis CS, Gracon SI. A 30-week randomized controlled trial of high-dose tacrine in patients with Alzheimer's disease. The Tacrine Study Group. *JAMA* 1994;271:985-91.
- Davis KL, Thal LJ, Gamzu ER, et al. A double-blind, placebo-controlled multicenter study of tacrine for Alzheimer's disease. The Tacrine Collaborative Study Group. *N Engl J Med* 1992;327:1253-9.
- Wilcock GK, Scott MI. Tacrine for senile dementia of Alzheimer's or Lewy body type [letter]. *Lancet* 1994;344:544.
- Levy R, Eagger S, Griffiths M, et al. Lewy bodies and response to tacrine in Alzheimer's disease [letter]. *Lancet* 1994;343:176.
- Nakano I, Hirano A. Parkinson's disease: neuron loss in the nucleus basalis without concomitant Alzheimer's disease. *Ann Neurol* 1984;15:415-8.
- Ott BR, Lannon MC. Exacerbation of parkinsonism by tacrine. *Clin Neuropharmacol* 1992;15:322-5.

Central diabetes insipidus: a complication of herpes simplex encephalitis

Secondary diabetes insipidus occurs as a result of damage to the hypothalamic-neurohypophyseal system due to opportunistic infections in AIDS, in neonates, and in children with acute bacterial meningitis. Diabetes insipidus after herpes encephalitis in adults is rare.

Five days before admission, a 42 year old woman developed a prodromal influenza-like illness with rapid onset of headache, behaviour disorder, and clouding of consciousness and became increasingly disoriented and lethargic. She was admitted to hospital because of a tonic-clonic seizure. Her temperature was 38.5°. The Glasgow coma scale score was 12 and she had neck stiffness and bilateral Babinski's sign. The CSF showed mononuclear pleocytosis (600 white cells/ml), 131mg/dl protein, and 80 mg/dl glucose. The EEG suggested encephalitis. Head CT showed an area of low attenuation in the left temporal region. Treatment with acyclovir was started and also amikacin for a urinary infection. Brain MRI showed hyperintensive lesions in the left temporal and frontal lobes and insular cortex, a midline shift to the right, and involvement of the right temporal and frontal lobes highly suggestive of herpes simplex virus encephalitis. There was a significant rise in the titre of serum antibodies

Dementia and motor disability scores in patients with Parkinson's disease before and two months after treatment with tacrine

Patient No	Age (y)	PD (y)	Dementia (y)	MMS pre-Rx	MMS post-Rx	UPDRS pre-Rx	UPDRS post-Rx
1	82	4	1	21	24	34	17
2	72	2	0.5	15	24 (28)*	89	25 (8)*
3	77	6	1	15	23	91	31
4	69	15	2	15	21	86	28
5	78	4	1	15	26	87	44
6	66	5	0.5	16†	24†	65	21
7	74	4	0.25	19	24	103	41

PD = Parkinson's disease duration; MMS = mini mental state score (Folstein) out of 30; UPDRS = unified Parkinson's disability rating scale (items 1-31); pre/post Rx = before/after treatment; *at 7 months after initiation of treatment; †scored out of 29.