

Paragonimiasis in a Child from Assam, India

JASHBEER S. ROY¹, PARTHA PRATIM DAS², AMRIT KR BORAH³, JAYANTA KR DAS⁴

ABSTRACT

Paragonimiasis or lung fluke infection is one of the neglected tropical parasitic disease which is found worldwide. Several endemic foci have been discovered in the Northeast India. Pulmonary paragonimiasis presenting with haemoptysis is generally mistaken for pulmonary tuberculosis. Herein, we present a case of pulmonary paragonimiasis, which initially presented with haemoptysis and remained undiagnosed for two years. The patient was treated with Praziquantel 25mg/kg thrice daily for two days along with the supportive care. Subsequently, on follow up after three months the patient had improved with no fever and cough.

Keywords: Bile stained eggs, Haemoptysis, Pulmonary tuberculosis

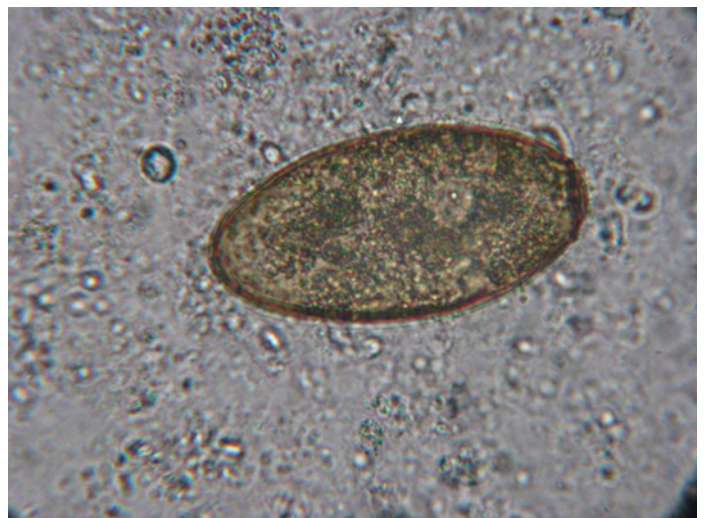CASE REPORT

An eight-year-old school going boy from a tea garden of upper Assam presented to the Pediatrics outdoor with haemoptysis for 1 day. He had similar symptoms for which he was admitted in the Department of Pediatrics in our institute about two and half years ago and discharged after 10 days of stay as his condition improved. He was treated for pneumonitis based on radiological findings, with antibiotic Cefpodoxime and supportive treatment with multivitamins, iron supplement and Tranexamic acid injection.

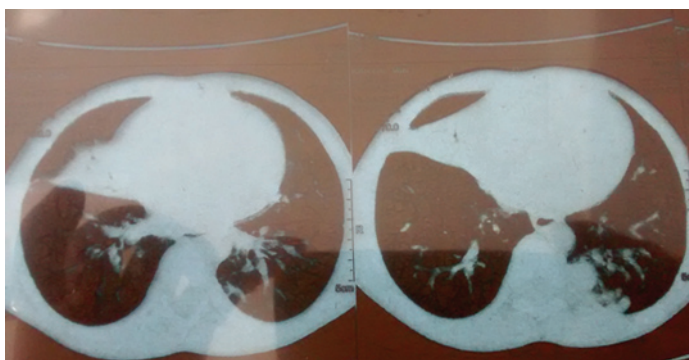
This time the patient was found to weigh 15 kg which was low for his age. Pallor was the only clinical finding he had. There was no fever, cough, chest pain, diarrhoea or any skin lesions. His Complete Blood Count (CBC) showed TLC-10500/Cumm, Hb%-9.6gm/dl, ESR-50mm (AEFH), DLC-N31%, L45%, E17% and M7%, absolute eosinophil count-1785/Cumm, & Platelets-2.4 lakhs/Cumm. Peripheral Blood Examination (PBS) showed hypochromia, microcytosis, normal total count, platelets adequate and increased eosinophil count. Chest X-ray (PAview) showed bilateral paracardiac opacities. HRCT thorax showed Consolidation with air bronchogram involving the medial segment of the right middle lobe with patchy nodular opacities in the subpleural location in post basal segment of left lower lobe [Table/Fig-1]. Sputum was send for Gram stain, Ziehl Neelsen & culture sensitivity. A direct wet mount was done as it was a haemoptysis case and the high power examination revealed plenty of bile stained operculated eggs of 50-60µm x 80-120 µm, which was identified as *Paragonimus westermani* [Table/Fig-2]. Gram stained smear also showed ova like structure [Table/Fig-3]. No acid fast bacilli were found in Ziehl Neelsen stain. Stool examination by both normal saline mount and

concentration method showed ova of *Paragonimus westermani* along with ova of *Trichuris trichiura* and *Enterobius vermicularis* [Table/Fig-4].

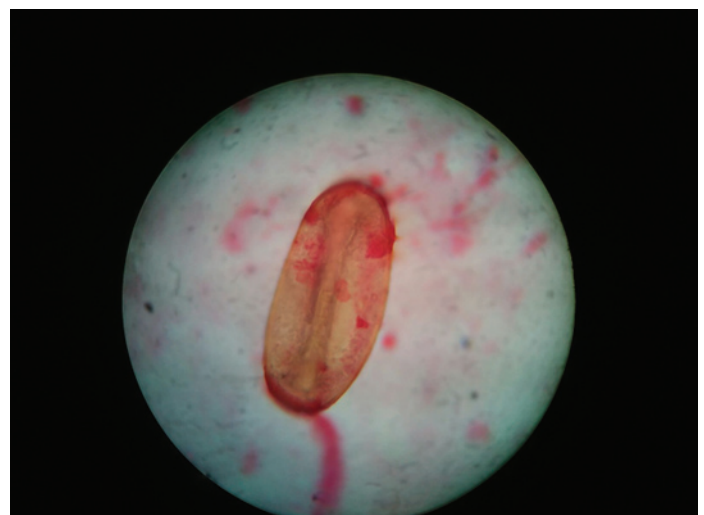
The patient was initially treated with Trenexamic acid, antibiotics –Inj Amikacin and Amoxyclav. After the stool report, he was started on Praziquantel 25mg/kg thrice daily for two days along with tablet



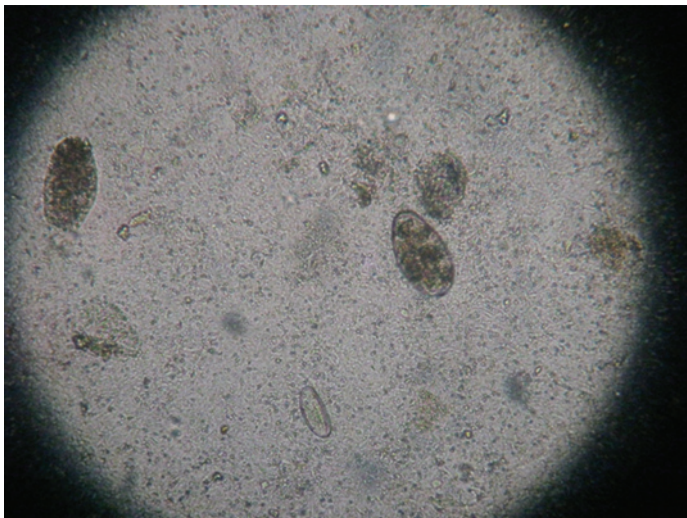
[Table/Fig-2]: Direct wet mount of sputum, 40X, showing operculated egg of *Paragonimus westermani*.



[Table/Fig-1]: HRCT Thorax showing consolidation of Right middle lobe and nodular opacities in left lower lobe.



[Table/Fig-3]: Gram stain preparation showing ova like structure.



[Table/Fig-4]: Normal saline mount of stool.

Albendazole. On follow up after three months the patient had improved with no fever and cough. Repeat examination of induced sputum and stool were negative for Paragonimus.

DISCUSSION

Paragonimiasis or lung fluke infection is one of the neglected tropical parasitic disease which is found worldwide. Several endemic foci have been discovered in the Northeast India [1-3]. Among the Paragonimus species, *Paragonimus heterotremus* is found to be the most common to cause Paragonimiasis in this part of the country [4]. Infection results from ingestion of raw, inadequately cooked, or pickled crabs/crayfish, which contains metacercarial, the infective stage [5]. Pulmonary paragonimiasis presenting with haemoptysis is generally mistaken for pulmonary tuberculosis [4].

In Assam, fresh water crabs belonging to the species *Sartoriana spinigera* has been found to be infected with metacercariae of *P. westermani* [3,4]. Two recent case reports of pulmonary paragonimiasis from Nagaland and Manipur suggests the endemicity of the infection in this region, Assam sharing the borders of both the states [6,7]. Another recent case report from Uttar Pradesh suggests the need of proper laboratory evaluation

of patients presenting with haemoptysis, in which operculated egg of *Paragonimus westermani* was observed on microscopic examination of post flexible fiberoptic bronchoscopy sputum [8]. In the above mentioned case reports the patients were misdiagnosed and treated as pulmonary tuberculosis. The patient in our case belonged to a tea tribe and had the habit of frequently eating/consuming raw crabs prepared at his home. This case was incidentally detected as Paragonimiasis as we did the wet mount examination of the sputum before doing the stain examination. The diagnosis was made based on the clinical features and laboratory findings of the patient which demonstrated the causative species as *P. westermani*. The physicians thought this could be some other infective lung condition and most probably didn't have Paragonimiasis in their mind. But high eosinophil count in blood along with anaemia in a patient of haemoptysis should have alerted clinician to rule out Paragonimiasis. Our case was fortunately diagnosed after two years and even though he did not have haemoptysis during this period, he was anaemic and malnourished.

CONCLUSION

The present case highlights the importance of history and need for a detailed laboratory evaluation for early diagnosis of pulmonary paragonimiasis. Also in all cases of haemoptysis from endemic region like ours, pulmonary paragonimiasis should be considered as a differential diagnosis along with pulmonary tuberculosis.

REFERENCES

- [1] Singh TS, Mutum S, Razaque MA, Singh YI, Singh EY. Paragonimiasis in Manipur. *Indian J Med Res.* 1993;97:247-52.
- [2] Narain K, Devi Rekha K, Mahanta J. Paragonimus and paragonimiasis-A new focus in Arunachal Pradesh, India. *Curr Sci.* 2003;84:985-87.
- [3] Singh TS, Sugiyama H, Umehara A, Hiese S, Khalo K. Paragonimus heterotremus infection in Nagaland: A new focus of paragonimiasis in India. *Indian J Med Microbiol.* 2009;27:123-27.
- [4] Singh TS, Sugiyama H, Rangsiruji A. Paragonimus and paragonimiasis in India. *Indian J Med Res.* 2012;136:192-204.
- [5] Kagawa FT. Pulmonary paragonimiasis. *Semin Respir Infect.* 1997;12:149-58.
- [6] Prasad KJ, Basu A, Khana S, Wattal C. Pulmonary Paragonimiasis Mimicking Tuberculosis. *J Assoc Physicians India.* 2015;63:82-83.
- [7] Singh TS, Hiromu S, Devi KR, Singh WA. First case of Paragonimus westermani infection in a female patient in India. *Indian J Med Microbiol.* 2015;33:S156-59.
- [8] Kalhan S, Sharma P, Sharma S, Kakria N, Dudani S, Gupta A. Paragonimus westermani infection in lung: A confounding diagnostic entity. *Lung India.* 2015;32:265-67.

PARTICULARS OF CONTRIBUTORS:

1. Demonstrator, Department of Microbiology, Assam Medical College & Hospital, Dibrugarh, Assam, India.
2. Demonstrator, Department of Microbiology, Assam Medical College & Hospital, Dibrugarh, Assam, India.
3. Assistant Professor, Department of Microbiology, Assam Medical College & Hospital, Dibrugarh, Assam, India.
4. Associate Professor, Department of Microbiology, Assam Medical College & Hospital, Dibrugarh, Assam, India.

NAME, ADDRESS, E-MAIL ID OF THE CORRESPONDING AUTHOR:

Dr. Jashbeer S. Roy,
Department of Microbiology, 2nd Floor, Basic Science Building, Assam Medical College & Hospital,
Dibrugarh, Assam-786002, India.
E-mail: jbroymc@gmail.com

FINANCIAL OR OTHER COMPETING INTERESTS: None.

Date of Submission: **Dec 03, 2015**
Date of Peer Review: **Jan 04, 2016**
Date of Acceptance: **Feb 11, 2016**
Date of Publishing: **Apr 01, 2016**