

## Editorial

Journal of  
**NEUROLOGY  
 NEUROSURGERY  
 & PSYCHIATRY**

### Surgery for Parkinson's disease

"The role of the three coordinates system would then be to define the minimal volume of tissue to be explored."  
 JB Brierley, E Beck. *J Neurol Neurosurg Psychiatry* 1959

Current pharmacological treatments for Parkinson's disease are not entirely adequate. A high proportion of patients chronically treated with levodopa and other dopaminergic drugs develop motor complications (fluctuations and dyskinesiae) and psychiatric complications.<sup>1,2</sup> Additionally, some specific motor functions such as gait, balance, speech, deglutition, etc, become less responsive as disease and duration of treatment increase. It seems that both "non-physiological" dopaminergic stimulation and disease progression simultaneously interact to induce such complications.<sup>2,3</sup> As a result, newer therapeutic avenues continue to be explored with two major aims: (1) to stop or slow down progression of disease and (2) to treat symptomatically the complications associated with chronic drug therapy.

There has been a resurgence of interest in surgical treatments. Current stereotactic surgical techniques for Parkinson's disease include thalamotomy, pallidotomy, chronic intracerebral stimulation, or deep brain stimulation and striatal grafting of dopaminergic fetal tissue. Grafting is still under evaluation<sup>4,5</sup> and is excluded from this review.

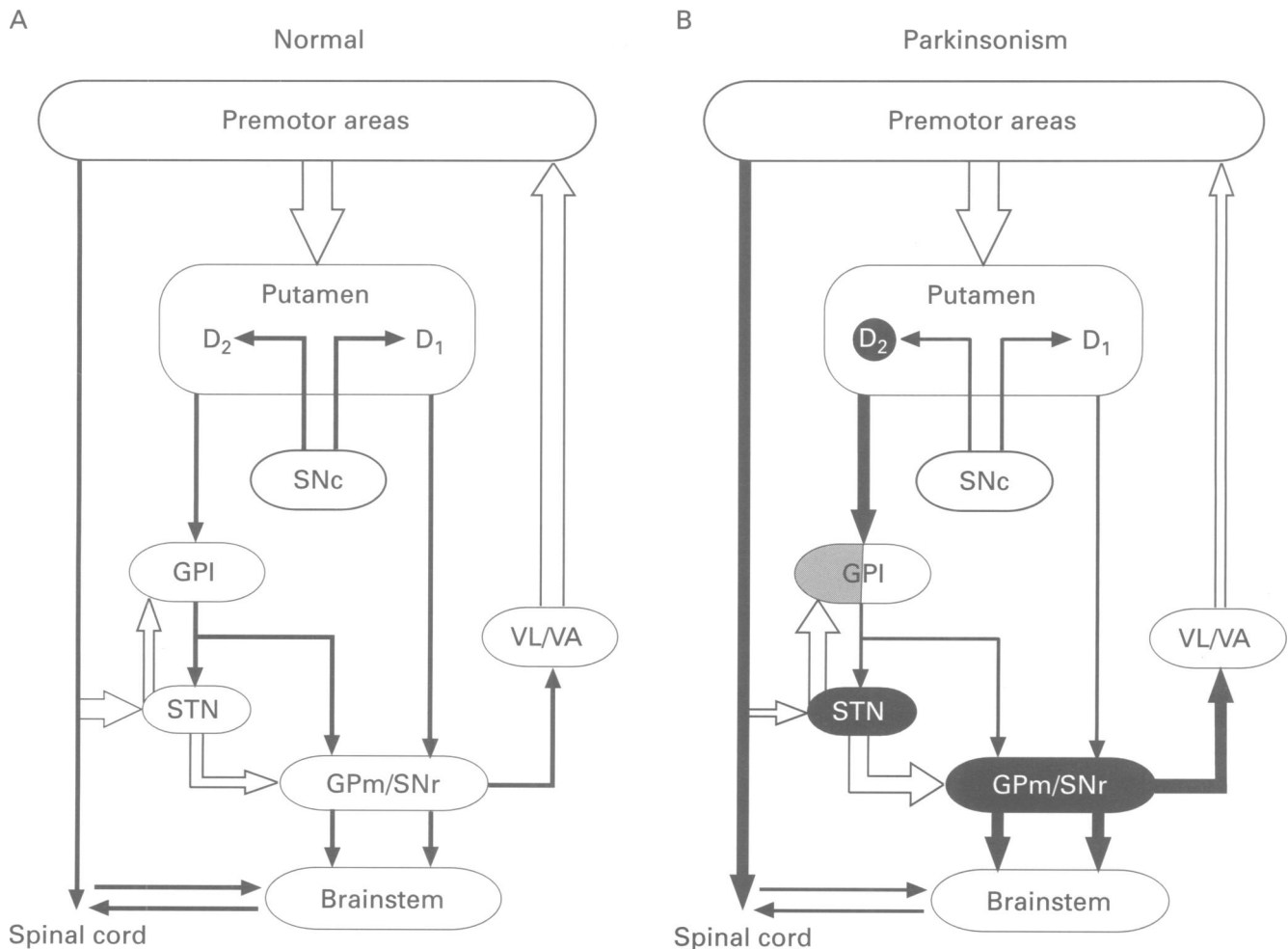
The recent attention to surgical approaches has occurred as a result of several factors. Firstly, studies using the model of parkinsonism induced by 1-methyl-4-phenyl-1, 2, 3, 6-tetrahydropyridine (MPTP), particularly in monkeys, have shown that hyperactivity in the subthalamic nucleus (STN) and medial globus pallidum (Gpm) is a hallmark of the parkinsonian state and that lesions of these nuclei can reverse all the signs of experimental parkinsonism.<sup>6</sup> Secondly, stereotactic surgery has become more precise and safer due to better stereotactic frames which provide high levels of mechanical accuracy, and to the development of high resolution brain CT and MRI. Finally, more refined electrophysiological techniques have allowed on line intraoperative assessment leading to precise recognition and mapping of the desired target and neighbouring structures—for example, the internal capsule or optic tract.

#### Historical perspective

Surgical approaches to the treatment of movement disorders were initially directed to the motor cortex and its efferents. The basal ganglia were first approached surgically in the late 1930s and 40s by Meyers, who lesioned

the head of the caudate nucleus and internal capsule and noted some improvement of tremor and rigidity. The globus pallidus and ansa lenticularis were the original targets for relief of parkinsonian tremor and rigidity in the 1950s after Cooper's finding that accidental ligation of the anterior choroidal artery stopped tremor in a patient with Parkinson's disease. Several strategies were employed by different neurosurgical groups. Guiot and Brion<sup>7</sup> lesioned the ansa lenticularis mechanically by a subfrontal approach. Bravo and Cooper<sup>8</sup> and Narabayashi and Okuma<sup>9</sup> used alcohol and procaine to lesion the pallidum. Clinical results were considered positive in general but were variable, as was the actual site of the lesions.<sup>10</sup> In 1960, Svennilson *et al.*,<sup>11</sup> reporting Leksell's experience, described the effect of thermolytic lesions of the pallidum in 81 patients. In the last 20 cases of this series, the lesion was moved from the classic anterodorsal to the posteroventral region of the Gpm. In this group, Leksell and colleagues realised that benefit was maximal, with over 95% relief of tremor and rigidity. They also noticed improvement in mobility in terms of "strength, range, speed, and precision". Gait and mobility of the trunk also benefited as well as activities of daily life. This article unfortunately had minor impact and received little attention, in part because at the time most neurosurgeons active in the field had changed their primary target to the thalamus. Hassler and Riechert<sup>12</sup> were the first to induce a thalamic lesion, but it was Cooper and Bravo<sup>13</sup> who reported that a lesion of the ventrolateral nucleus of the thalamus was the most effective site to relieve tremor. Other targets were also explored including Forel's fields (campotomy), the posterior subthalamic area, and the zona incerta. Despite such attempts, thalamotomy remained the standard surgical therapy for intractable parkinsonian tremor for many years. Indeed, Laitinen<sup>14</sup> in 1985 surveyed 16 stereotactic neurosurgeons to assess the target that they commonly used in parkinsonian patients. Thirteen surgeons chose the thalamic ventrolateral region, two Forel's fields, and one the zona incerta. Pallidotomy was not used by experts in the field.

In 1992, Laitinen *et al.*<sup>15</sup> described 38 patients with Parkinson's disease in whom he had performed a lesion of the posteroventral region of the Gpm, following Leksell's original concept. In all but one patient, this procedure induced "an almost complete relief of rigidity and hypokinesia". Although these results were difficult to judge with certainty because of insufficient information about critical clinical data such as the drug regimen before and after surgery, evaluation procedures, etc, it served to revitalise the field of surgery for Parkinson's disease and motivated interest specifically in pallidotomy.



(A) Schematic diagram of the basal ganglia-thalamocortical circuitry under normal conditions. Inhibitory connections are shown as filled arrows, excitatory connections as open arrows. (B) Activity changes in the basal ganglia-thalamocortical circuit in Parkinson's disease. Degeneration of the nigrostriatal pathway leads to differential changes in the two striatopallidal projections, indicated by the thickness of the connecting arrows. Subthalamic nucleus activity is increased leading to exaggerated basal ganglia inhibitory output to the thalamus and brainstem.

### Pathophysiological background

Of all the circuits passing through the basal ganglia, the "motor circuit" is the most relevant in the pathophysiology of the cardinal signs (akinesia/bradykinesia, rigidity, and tremor) of Parkinson's disease.<sup>16,17</sup> This "motor loop" includes the precentral motor areas (areas 4 and 6, supplementary motor area) and postcentral sensory fields (3a-b, 2,1), which project to the putamen in a somatotopically organised fashion. Detailed anatochemical studies have shown that putaminal output reaches the medial globus pallidus (GPm) and the substantia nigra reticulata (SNr) through two different projections which arise from separate putaminal neuronal populations (figure). There is a direct monosynaptic pathway from putamen to GPm that is GABAergic and colocalised with substance P and dynorphin and an indirect pathway which arises from GABA/enkephalinergic putaminal neurons and projects to the lateral globus pallidus (GPI). The GPI sends a GABAergic inhibitory projection to the sensorimotor region of the STN and also to the GPm.<sup>18</sup> The STN exerts a powerful excitatory drive on to the GPm and SNr, which finally project to the ventrolateral thalamus (VL) on their route to the premotor cortices. The output from the GPm (through the ansa lenticularis) and SNr to the thalamus is GABAergic and therefore inhibitory. Output of the basal ganglia is also directed to the brainstem. The GPm also projects to the non-cholinergic portion of the pedunculo-pontine nucleus and the SNr sends its efferents to the

superior colliculus and mesopontine tegmentum.<sup>19,20</sup> In addition, it has recently been shown that the cholinergic, GABAergic, and glutamatergic fibres project from the mesopontine tegmentum to the STN,<sup>21</sup> providing the anatomical basis for a functional interface between brainstem regions related to locomotion and posture and the basal ganglia.

The basic mechanisms underlying the cardinal features of the parkinsonian syndrome are now relatively well understood as a result of studies using the model of MPTP induced parkinsonism in monkeys. Loss of dopaminergic neurons in the substantia nigra compacta (SNc) reduces the normal inhibition of the nigrostriatal pathway on GABA-enkephalin neurons, which increases their activity, thus overinhibiting the GPI (figure). The inhibitory tone of GPI on the STN is reduced and the STN increases its activity well over normal to excite the GPm/SNr. Hyperactivity of the STN and overexcitation of its efferent targets can now be considered as the pathophysiological hallmark of the parkinsonian state. This has been shown by microelectrode recording and metabolic studies such as 2-deoxyglucose uptake and GAD mRNA in situ hybridisation in MPTP treated monkeys.<sup>22-25</sup> The pivotal role of increased STN activity in the origin of parkinsonism was further demonstrated by lesioning the STN in MPTP treated monkeys. A unilateral STN lesion induced a pronounced improvement in the contralateral limbs and in facial expression, flexor posture, spontaneous

activity, and even, albeit to a minor extent, of the limb ipsilateral to the STN lesion.<sup>26–28</sup> Hemichorea-ballism was not a major complication in most animals. In subsequent studies it has been found that inactivation of the sensorimotor region of the STN and GPM is critical for achieving frank amelioration of parkinsonian signs.<sup>29</sup> In addition to the behavioural observations, it was also shown that the STN lesion returned the GABA activity in both the GPM and SNr towards normal levels as judged by the expression of GAD mRNA.<sup>28</sup> The importance of the direct circuit in the pathophysiology of Parkinson's disease awaits future experiments.

Increased activity of the GPM/SNr leads to excessive inhibition of the thalamus and reduced thalamocortical activation. This probably accounts for the hypokinetic features of the disease. Excessive tonic discharges are not the only physiological abnormality of the basal ganglia in Parkinson's disease. Increasing evidence indicates that phasic oscillations in neuronal firing are responsible for tremor. It has been classically recognised that tremor cells are mainly recorded in the motor thalamus; however, phasic firing in synchrony with tremor in the limbs can also be recorded from the STN, GPM, and even GPI. In parkinsonian monkeys and patients with Parkinson's disease, a lesion of the GPM and particularly the STN may completely abolish tremor, suggesting a critical role of the STN-GPM axis in the origin of tremor in Parkinson's diseases.

#### Methodological aspects

The success of stereotactic procedures lies in accurate determination of the target and precise placement of the thermally induced lesion or electrode implantation. This involves three main steps: (1) neuroimaging the targeted area; (2) electrophysiological assessment; (3) lesioning or implanting the stimulation electrode.

Functional neurosurgery requires a stereotactic frame for coordinate estimation. Imaging of the brain is necessary to determine the coordinates of the anterior and posterior commissures (AC, PC), which allows calculation of the intercommissural line (AC-PC). Errors in determining the AC-PC line will lead to mistargeting. There is no final agreement as to which imaging method should be used. The AC and PC are best recognised by MRI, but this technique introduces distortion in the calculations and many teams still prefer to rely on brain CT or even ventriculography. In any event, neuroimaging has an inaccuracy of 2–3 mm due to uncontrollable variables and summation of errors. In addition, the surgical target in Parkinson's disease and other movement disorders is defined functionally, not anatomically. Thus surgical approaches for Parkinson's disease ultimately depend on physiological characterisation.

Electrophysiological assessment of the target is performed with the patient awake during the procedure. It consists of microelectrode recording, microstimulation, and stimulation with the lesioning electrode. Recording may be undertaken with either a microelectrode for single unit isolation or with a semimicroelectrode which allows simultaneous recording of multiple units and field potentials. Microelectrode recording is the essential tool for functional mapping of the basal ganglia. Typically for pallidotomy, we begin to record some 20–25 mm above the intended target (GPM), which allows us to identify and determine the extent of the striatum, the laminae, and the external and internal pallidum. The response of the optic tract to flash stimulation can also be recorded. Differences in neuronal discharge patterns and rates permit identification of the different nuclei and structures. The responses

to peripheral stimuli (stretching and deep palpation) and voluntary activation define the sensorimotor territory of the GPM. Moreover, microelectrode recording allows the plotting of the somatotopic organisation of the target area and the zones within the target nucleus where neuronal activity is most abnormal. Typically, three to five recording tracts are carried out to map the boundaries of the caudolateral GPM, the optic tract, and the internal capsule.

Bipolar microstimulation (100–300 Hz, 20–100  $\mu$ A) is carried out with the same electrode that is used for recording. The major aims of this technique are to locate precisely the optic tract, so as to know how ventrally the lesion can be made without provoking a visual field defect, and to examine the threshold for capsular stimulation to set the posterior and medial limit of the lesion when performing pallidotomy, and the lateral (internal capsule) and caudal (ventrocaudal nucleus) boundaries when performing a thalamotomy.

Stimulation through the lesioning probe is performed to confirm the location of the internal capsule and optic tract.

A proportion of functional neurosurgeons still think that stimulating with the lesioning probe is enough to avoid complications and ensure positive clinical results. We oppose such a view. Off targeting is a relatively common event for any neurosurgical team, but even when the first track is within the intended nucleus the area to lesion needs functional definition. Stimulation alone can also give rise to false positive signs such as evoking a visual response without actually having gone through the medial pallidus and does not allow the assessment of how medially or caudally stimulation is being given when obtaining a capsular response. Moreover, improvement of parkinsonian signs with stimulation is not consistent enough to serve as a definitive guide for lesioning.

For lesioning procedures, experience is required to make a lesion large enough to avoid recurrence but small enough not to damage adjacent structures. We think that such equilibrium is almost impossible to reach without microelectrode mapping of the sensorimotor areas.

Deep brain stimulation is a recently introduced technique which has been mainly developed by Benabid and Pollak in Grenoble. The stimulating electrode has a diameter of 1.3 mm and a length of 12 mm. The electrode tip contains four stimulating contact points, separated by 1.5 mm. Clinical experience suggests that current may spread some 4 mm around the active tip. Stimulation may be monopolar, taking, for example, the ground as reference, or bipolar, making as many combinations as possible among the four active sites. The final location of the electrode is usually decided on the basis of clinical benefit—for instance, tremor suppression. The electrode is initially connected to a percutaneous extension for testing, and definitive installation is carried out a few days later. The tip of the electrode is attached to a programmable pulse generator and the connections tunnelled under the skin. The neurostimulator is sited in a subcutaneous pocket under the clavicle. A commercially available stimulator (ITREL II, Medtronic, USA) is capable of stimulating at up to 185 Hz, giving a maximal amplitude of 10 volts and a pulse width of 60 to 450  $\mu$ s.

#### Clinical results

##### THALAMOTOMY

This is the only stereotactic procedure that continued to be undertaken, albeit infrequently, after levodopa and other drugs became available for Parkinson's disease. In general, there is little doubt as to the antitremor effect of

thalamotomy. However, there is some variability in the reported incidence of total abolition of unilateral tremor, ranging from 45.8% to 92%.<sup>10</sup> It is likely that such a large difference is related to different technical approaches. For example, Tasker's group<sup>30</sup> obtained a 45% abolition of tremor in patients operated on up to 1967 but the success rate grew to 86–96% in patients operated on during the 1970s.

Recurrence of tremor occurs in about 5%–10% of cases,<sup>31</sup> usually within the first three months.<sup>30</sup> If tremor remains absent after this period, it rarely ever returns in that limb. The optimal site for treating tremor by lesioning the thalamus is the area known as Vim (ventralis inter-medius) where neuronal activity synchronously firing with the tremor is recorded.<sup>32–33</sup> Rigidity of the contralateral limb is also improved by thalamotomy. In this case, the target is moved rostral to the Vim to lesion the ventralis oralis anterior/posterior.<sup>30,33</sup> The effect on rigidity has been reported as complete abolition in up to 92% of cases.<sup>30</sup> However, in the contemporary series of 75 patients reported by Tasker *et al.*, there was clinically significant improvement in only 40% of patients. A lesion involving the same region has also been found to abolish levodopa induced dyskinesia.<sup>34</sup>

Thalamotomy is thought to have no positive effect on cardinal signs of Parkinson's disease such as akinesia, bradykinesia, gait problems including start hesitation, and freezing, postural difficulties, and hypophonia.<sup>10,30,34</sup> The thalamic lesion has only a contralateral effect.

#### PALLIDOTOMY

The article commented on above by Laitinen *et al.*<sup>15</sup> was published just at the time when several experimental groups had conclusively shown the importance of the STN-GPm pathway in the pathophysiology of parkinsonism. At that time (1992) one of these groups (DeLong, Vitek, and Bakay at Emory University, Atlanta, USA) reintroduced posteroventral pallidotomy using intraoperative microrecording and stimulation to precisely localise the sensorimotor region of the GPm.<sup>35</sup> Subsequently, several teams have employed pallidotomy to treat patients with severe Parkinson's disease.<sup>36–39</sup> All but one group has reported positive results in terms of reduced "off" period disability, decreased "off" hours, improved daily living activities, and better night sleep. A dramatic reduction or even abolition of levodopa induced dyskinesiae has been a constant finding in all series. The effect of pallidotomy is mainly contralateral to the lesioned side but ipsilateral improvement has been noticed in some patients.<sup>36–39</sup>

Dogali *et al.*<sup>36</sup> compared the effect of unilateral pallidotomy in 18 patients with Parkinson's disease with that of another seven similarly affected patients who continued medical treatment. The Unified Parkinson's Disease Rating Scale (UPDRS) in the "off" state had improved by 65% 12 months after operation but had increased slightly in the non-operated patients. Lozano *et al.*<sup>39</sup> recently reported 14 patients followed up for six months after surgery. Standardised videotape recording was used to assess the patients blindly before and after pallidotomy. There was a 30% improvement in the UPDRS global motor score and 22% in the akinesia score. Scores of gait and instability also improved by 23% but did not reach significance. These arguably small percentage changes in the motor scores may reflect the relative insensitivity of the UPDRS and may be misleading as to the actual impact of pallidotomy.<sup>40</sup> In the same study, the Schwab and England (activity of daily life) scale score almost doubled indicating a very important functional benefit. We have performed detailed analysis of motor function in six patients before and three to six months after unilateral

pallidotomy. For tasks such as flexion of the thumb and elbow, wrist tapping, or flex and squeeze movements there was a 40% to 70% improvement mainly in the arm contralateral to the lesion.<sup>40</sup> Dogali *et al.*<sup>36</sup> also found significant improvement in the performance of several timed tests with the upper limb up to 12 months after pallidotomy. Scanning with PET in other centres has shown an increased activation of the dorsolateral prefrontal cortex and premotor areas,<sup>41,42</sup> which in our patients correlated with the motor benefit.<sup>40</sup> All these data strongly indicate that pallidotomy has a profound capacity to resolve some of the major pathophysiological abnormalities present in Parkinson's disease.

The only negative clinical results so far published are from Sutton *et al.*<sup>37</sup> who did not find substantial motor improvement apart from pronounced alleviation of levodopa induced dyskinesia in five patients, two of whom received staged bilateral surgery. Interestingly, an initial but transient effect was seen in some patients. Sutton *et al.*<sup>37</sup> did not use recording for mapping the sensorimotor region for the GPm, probably accounting for the partial effect. Another problem in this series is that two patients with short duration of disease were already in Hoehn and Yahr stage V and not responding to levodopa, casting doubt on whether they had idiopathic Parkinson's disease.

The personal experience in Emory University comprises over 100 patients with Parkinson's disease with a pallidotomy since 1992, about half of whom have been followed up for more than one year.

The effect of pallidotomy may be complete and radical in abolishing "on" dyskinesiae, diphasic dyskinesia, and "off" dystonic postures in the limbs contralateral to the lesion. Pain associated with dystonic spasms and rigidity is often totally abolished. Akinetic features such as hypomimia and flexed posture of the trunk as well as limb bradykinesia are also much improved by pallidotomy, which is the only current therapeutic approach capable of both inducing global motor improvement and eliminating dyskinesiae. Resting tremor also responds favourably, although it may not be completely controlled in some patients. The effect on other common problems in Parkinson's disease such as freezing of gait, speech, swallowing, etc, can also be notable, but is less predictable. The initial results indicate that patients who benefit most dramatically from pallidotomy are relatively young (aged 60 years or less) or patients with complications associated with chronic levodopa therapy. However, older patients also benefit from improved mobility, balance, and reduced motor fluctuations.

In patients with generalised Parkinson's disease, the benefit obtained after unilateral pallidotomy may not be sufficient to resolve disability. In such instances the question of contralateral surgery often arises. Bilateral pallidotomy has now been carried out in a few patients. One group<sup>38</sup> performs the procedure within a single surgical session. Our preliminary experience with bilateral staged procedures is not as positive. Hypophonia and swallowing difficulties may occur in some cases, but on the other hand some patients have obtained substantial benefit. For the time being, it may be sensible to consider pallidal stimulation if bilateral surgery is absolutely necessary and the patient cannot await further technical refinements and newer approaches.

As a rule, levodopa and other drugs are still needed after pallidotomy although the response becomes smoother and more predictable. It must be admitted that a definitive prospective study comparing the effect of pallidotomy against common pharmacological managements is needed to corroborate the efficacy of this procedure. Such a study is currently under way at Emory University.

### SUBTHALAMOTOMY

As indicated earlier, experimental studies indicate that the STN plays a critical part in the pathophysiology of parkinsonian signs. However, the fear of inducing hemiballism after a lesion of the STN and the potential risk of haemorrhage due to its high vascularisation has until now discouraged most neurosurgeons from targeting the structure. Using the MPTP model of Parkinson's disease in monkeys, it has been shown that a lesion of the STN is capable of inducing a dramatic improvement in the motor signs, mainly on the side contralateral to the lesion but also axially and to some extent ipsilaterally.<sup>26-28</sup> Hemichorea was encountered in about 60% of the animals, but it was transitory or did not interfere with motor control in any of them. Haemorrhages were not encountered in any monkey. Spontaneous vascular lesions in the region of the STN have been reported in three parkinsonian patients: all of them showed amelioration of the parkinsonian signs contralateral to the lesion. There were no dyskinesias in one case, transient hemichorea in another, and severe hemiballism in the third patient.<sup>43-45</sup> However, in the last case the haematoma extended beyond the STN. Whereas it is clear that lesions of the STN in normal monkeys or humans are often associated with hemiballism, the pathophysiological changes occurring in the parkinsonian state have led us to think that such a complication is less likely to develop in Parkinson's disease.<sup>28, 46</sup> Indeed, preliminary findings in a collaborative study carried out between the Centro de Restauración Neurológica, La Habana, Cuba (Drs Alvarez, Macias, and Muñoz, personal communication) and ourselves support this notion. A focal lesion of the STN has been made in four patients with severe Parkinson's disease with no or minimal dyskinesias induced by levodopa. The size and extent of the thermolytic lesion were carefully assessed by extensive recording and stimulation. Very robust motor benefit on the operated side and axial musculature was seen in all cases. One patient developed repetitive movements in the lower limb four days after the lesion, which did not interfere with motor performance and tended to regress. There was no other dyskinesia or complication. Obviously careful and extensive studies need to be done before reaching a definitive conclusion on the STN as a target for Parkinson's disease,<sup>46</sup> but these initial results are very encouraging as the magnitude of the therapeutic effect surpassed that achieved by any other lesioning technique presently available.

### DEEP BRAIN STIMULATION

Deep brain stimulation for Parkinson's disease was introduced in the late 1980s for the treatment of tremor, choosing the Vim as target<sup>47</sup> More recently, the technique has been widened to other targets such as the GPM and STN.<sup>48</sup>

Stimulation of the Vim has been shown to be very effective in suppressing the resting tremor of Parkinson's disease. Pollak *et al* have reported a dramatic effect in 54 of 61 patients.<sup>49</sup> Similar experiences with minor variations in the degree of benefit have been reported by several other groups. No serious side effects have resulted from bilateral stimulation of the Vim. The long term evolution is not always satisfactory, with the development of tolerance and rebound aggravation of the tremor when the stimulator is turned off in some cases.

Limousin *et al*<sup>50</sup> have described a dramatic improvement of all cardinal features of Parkinson's disease in three patients with chronic bilateral stimulation of the STN. Transient complications were seen in two cases and the emergence of hemiballism in one patient limited the current intensity and therefore the therapeutic effect.<sup>51</sup> This

group in Grenoble has now increased its experience to eight patients with similarly encouraging results. Implantation of deep brain stimulation into the GPM instead of the STN is also being investigated. Our ongoing experience also suggests a substantial clinical effect, but the clinical data so far presented in meetings and in brief reports is not yet sufficient to allow a final conclusion to be reached. A comparative study between bilateral STN and GPM stimulation is underway in Europe and the United States.

A natural question is to compare the advantages and disadvantages of DBS versus thermolytic lesioning. The major convenience of deep brain stimulation lies in its reversibility and in the minimal or absent damage caused to the brain. This makes it ideal for trying new targets and for bilateral procedures. The ability to change stimulating variables at any time is also a clear advantage of deep brain stimulation. On the other hand, the precise mechanism of action of deep brain stimulation is not yet understood and its use has some practical problems. For instance, it requires two surgical procedures (one for targeting and another for definitive electrode internalisation), the life of the battery is limited to a few years, depending on the current intensity, and tolerance to the therapeutic effect may develop. Finally, there is the problem of added expense for purchase of the stimulator itself and the need for intense personal dedication in the initial phase of treatment.

### SELECTION OF PATIENTS AND TECHNIQUE

A practical problem at present is patient selection. This important issue is basic but not necessarily always given sufficient attention. It is now clear that only patients with idiopathic Parkinson's disease should be considered for this type of surgery. Special effort is required to exclude patients with atypical signs,<sup>52</sup> indicative of a different pathological substrate. There is already evidence of patients with multiple system atrophy having been submitted to striatal grafting and lesioning procedures without success. Also, patients with Parkinson's disease with severe cognitive defects or pronounced cerebral atrophy on brain MRI and CT may not be good candidates.

The next problem is what technique should be offered depending on the clinically predominant features. This is an unresolved issue. In the meantime, we would suggest that patients in whom medically intractable tremor is the only complaint may benefit from thalamotomy or deep brain stimulation of the Vim. This will usually abolish or substantially reduce the tremor of Parkinson's disease. In patients, with and without tremor, in whom akinesia/rigidity and drug induced dyskinesias are the major sources of disability, pallidotomy is the best choice, particularly when the signs are asymmetric. Bilateral pallidal lesioning is a feasible approach but experience is still limited and not necessarily optimistic. Deep brain stimulation of the pallidum or STN may be the optimal option when bilateral surgery is anticipated.

### *Neurological complications associated with unilateral pallidotomy for Parkinson's disease in Emory University Hospital (128 patients)*

Complication	Number of patients	
	Transient	Permanent
Morbidity:		
Hemiparesis	2	1
Facial weakness	7	0
Frontal signs	3	0
Visual field defect	3	2
Seizure	3	0
Mortality:		
Subdural haematoma		1
Heart failure with neuroleptic malignant syndrome		1

## COMPLICATIONS OF SURGERY

Morbidity and mortality after functional surgery for Parkinson's disease arise mainly as a consequence of intracerebral haemorrhages and thermolytic lesioning of structures adjacent to the target site. The reported mortality from thalamotomy ranges from 0.4% to 6%. Recent experience with pallidotomy indicates an incidence of haemorrhages associated with severe clinical complications in about 2%–8% of patients. The possibility of increased risk of haemorrhages due to repeated microelectrode mapping during recording has been considered. The Emory series of more than 100 patients (table), in all of whom microelectrode recording was undertaken (average number of tracks four, range two to eight), does not suggest that this is the case. Haemorrhage has been the most common and serious complication. Acute symptomatic bleeding occurred in two patients. One experienced an acute hemiparesis secondary to bleeding at the lesion site and one developed diffuse subcortical bleeding presumably due to a bleeding tendency secondary to unsuspected preoperative high intake of aspirin. Three patients who experienced sudden improvement in parkinsonian signs were subsequently found to have small basal ganglia bleeds on MRI. Additionally, six patients (4%) were found to have small asymptomatic superficial haemorrhages by MRI. Six patients showed transient post-operative contralateral facial weakness. Two patients experienced (7–12 days) acute motor deficits (hemiparesis in one and facial weakness with dysarthria in the other) with MRI evidence of a small capsular infarction. Both recovered almost completely. Two patients had a partial field defect detected by postoperative visual field testing. Postoperative wound infection occurred in one patient and seizures occurred in two. Although no patients died during the operative period, two patients eventually died as a result of postoperative complications. One patient developed an acute subdural haematoma within 24 hours of surgery and another developed unexplained fever, encephalopathy, and severe rigidity consistent with a neuroleptic malignant syndrome several days after the surgery. Both patients died some months later. A similar experience was encountered by Lozano *et al.*<sup>39</sup> who also routinely performed microelectrode recording before lesioning. It should be realised that morbidity is always higher when a surgical technique is first started. The incidence of complications, in the authors' experience, has fallen dramatically once the procedure has become more standardised.

Persistent visual field deficits are a well known risk of pallidotomy. Laitinen *et al.*<sup>15</sup> reported an initial 14% incidence of such defects. However, we firmly believe that careful electrophysiological assessment can drastically reduce the frequency of this complication. A similar comment may be valid for the occurrence of hemiplegia after an inappropriate lesion of the internal capsule during either thalamic or pallidal surgery. Avoiding lesioning the ventrocaudalis nucleus to preserve somesthesia is also a fundamental aspect of thalamic surgery. This too requires experience and appropriate electrophysiological analysis. It must be admitted that at present definitive evidence that microrecording is essential for optimal basal ganglia surgery is lacking. However, anecdotal information from centres using less rigorous assessment methods should be viewed with extreme caution. The inconvenience and risk associated with a longer intervention because of careful electrophysiological assessment is, in our view, overcome by the higher probability of clinical success derived from accurately defining the target zone. A recent article<sup>53</sup> reporting the use of the gamma knife technique to perform pallidotomy is a good example.

Preliminary experience with deep brain stimulation sug-

gests a similar rate of haemorrhages to that for the classic lesioning procedures. The intensity and frequency of stimulation may be limited by sensory symptoms after Vim implantation and by involuntary movements when stimulating in the STN region.<sup>51</sup> Local infection is a potential but rare cause of electrode withdrawal.<sup>49</sup>

## Conclusions

Stereotactic surgery is regaining a privileged position in the therapeutic armamentarium against Parkinson's disease. In this new era, multidisciplinary teams are necessary to provide adequate clinical evaluation and management preoperatively and postoperatively, as well as for accurate targeting and intraoperative physiological assessment. Neurosurgical techniques will also improve so that the procedure may become safer, quicker, and more precise.

Undoubtedly, newer targets and techniques will become available in the near future leading to an even wider and brighter surgical panorama for patients with Parkinson's disease.

JA OBESO  
J GURIDI

*Centro de Neurologia y Neurocirugía Funcional,  
Clínica Quirón, San Sebastián, Spain*

JA OBESO

*Centro de Enfermedades Neurológicas y Neuroquirúrgicas,  
Hospiten, Tenerife, Spain*

M DeLONG

*Department of Neurology,  
Emory University Medical School, Atlanta, USA*

Correspondence to: Dr JA Obeso, Clínica Quirón, Parque Alkolea 7, 20012 San Sebastián, Spain.

- Marsden CD, Parkes JP, Quinn N. Fluctuations of disability in Parkinson's disease. Clinical aspects. In: Marsden CD, Fahn S, eds. *Movement disorders*. London: Butterworths, 1982:96–122.
- Obeso JA, Grandas F, Vaamonde J, *et al.* Motor complications associated with chronic levodopa therapy in Parkinson's disease. *Neurology* 1989;39 (suppl 2):11–9.
- Chase TN, Baronti F, Fabbrini G, *et al.* Rationale for continuous dopaminomimetic therapy of Parkinson's disease. *Neurology* 1989;39 (suppl 2):7–10.
- Widner H, Rehncrona S, Brunding P, *et al.* Transplantation of fetal dopamine neurons in Parkinson's disease: 1-year clinical and neurophysiological observations in two patients with putaminal implants. *Ann Neurol* 1992;31:155–65.
- Kordower JH, Freeman TB, Snow BJ, *et al.* Neuropathological evidence of graft survival and striatal reinnervation after the transplantation of fetal mesencephalic tissue in a patient with Parkinson's disease. *N Engl J Med* 1995;332:1118–24.
- Mitchell IJ, Clarke P, Boyce S, *et al.* Neural mechanisms underlying parkinsonian symptoms based upon regional uptake of 2-deoxyglucose in monkeys exposed to 1-methyl-4-phenyl-1,2,3,6-tetrahydropyridine. *Neuroscience* 1989;32:213–26.
- Guiot G, Brion S. Traitement des mouvements anormaux par la coagulation pallidale. Technique et résultats. *Rev Neurol* 1953;89:578–80.
- Bravo GJ, Cooper IS. A clinical and radiological correlation of the lesion produced by chemopallidectomy and thalamectomy. *J Neurol Neurosurg Psychiatry* 1959;22:1–10.
- Narabayashi H, Okuma T, Shikiba S. Procaine oil blocking of the globus pallidus. *Arch Neurol Psychiatry* 1956;75:36–48.
- Speelman JD. *Parkinson's disease and stereotaxic neurosurgery* [doctoral thesis]. Amsterdam: Rodopy, 1991.
- Svennilson E, Torvik A, Lowe R, Leksell L. Treatment of parkinsonism by stereotaxic therolesions in the pallidal region. *Acta Psychiatr Neurol Scand* 1960;35:358–77.
- Hassler R, Riechert T. Indikationen und localizations: Methode der gezielten himnoperationen. *Nervenarzt* 1954;25:411–47.
- Cooper IS, Bravo GJ. Chemopallidectomy and chemothalamectomy. *J Neurosurg* 1958;15:244–56.
- Laitinen LV. Brain targets in surgery for Parkinson's disease. Results of a survey of neurosurgeons. *J Neurosurg* 1985;62:349–51.
- Laitinen LV, Bergenheim T, Hariz MI. Leksell's posteroverentral pallidotomy in the treatment of Parkinson's disease. *Neurosurgery* 1992;76:53–61.
- Alexander GE, Crutcher MD. Functional architecture of basal ganglia circuits: neural substrates of parallel processing. *Trends Neurosci* 1990;13:266–71.
- DeLong MR. Primate models of movement disorders of basal ganglia origin. *Trends Neurosci* 1990;13:281–5.
- Parent A, Hazrati LN. Anatomical aspects of information processing in primate basal ganglia. *Trends Neurosci* 1993;16:308–9.
- Hikosaka O, Wurtz RH. Visual and oculomotor functions of monkey substantia nigra pars reticulata. Relation of the substantia nigra to the superior colliculus. *J Neurophysiol* 1983;49:1285–201.
- Scamati E. The pedunculo-pontine nucleus and related structures: Functional organization. In: Obeso JA, DeLong MR, Ohye Ch, Marsden CD, eds. *The basal ganglia and surgical treatment of Parkinson's disease*. *Advances in neurology*. New York: Raven Press, 1996 (in press).



- 21 Bevan MD, Bolam JP. Cholinergic, GABAergic and glutamate-enriched inputs from the mesopontine tegmentum to the subthalamic nucleus in the rat. *Neuroscience* 1995;15:7105-20.
- 22 Wichmann T, Bergman H, DeLong MR. The primate subthalamic nucleus. III. Changes in motor behaviour and neuronal activity in the internal pallidum induced by subthalamic inactivation in the MPTP model of parkinsonism. *J Neurophysiol* 1994;72:521-30.
- 23 Crossman AR, Mitchell IJ, Sambrook MA. Regional brain uptake of 2-deoxyglucose in 1-methyl-4-phenyl-1, 2, 3, 6-tetrahydropyridine (MPTP) induced parkinsonism in the macaque monkey. *Neuropharmacology* 1985;24:587-91.
- 24 Herrero MT, Levy R, Ruberg R, et al. Consequences of nigrostriatal denervation and L-DOPA therapy on the expression of glutamic acid decarboxylase (GAD) messenger RNA in the pallidum. *Neurology* 1996;47:219-24.
- 25 Vila M, Herrero MT, Levy R, et al. Consequences of nigrostriatal denervation on the  $\gamma$  aminobutyric acid neurons of substantia nigra pars reticulata and superior colliculus in parkinsonian syndrome. *Neurology* 1996;46:802-9.
- 26 Bergman H, Wichmann T, DeLong MR. Reversal of experimental parkinsonism by lesions of the subthalamic nucleus. *Science* 1990;249:1436-8.
- 27 Aziz TZ, Peggs D, Sambrook MA, Crossman AR. Lesion of subthalamic nucleus for the alleviation of 1-methyl-4-phenyl-1,2,3,6-tetrahydropyridine (MPTP) induced parkinsonism in the primate. *Mov Disord* 1991;6:288-93.
- 28 Guridi J, Herrero MT, Luquin MR, et al. Subthalamotomy in parkinsonian monkeys: behavioural and biochemical analysis. *Brain* 1996;119:1717-28.
- 29 Hamada I, DeLong MR. Excitotoxic acid lesions of the primate subthalamic nucleus result in reduced pallidal neuronal activity during active holding. *J Neurophysiol* 1992;68:1859-66.
- 30 Tasker RR. Thalamotomy. *Neurosurg Clin N Am* 1990;1:841-64.
- 31 Kelly PJ, Gillingham FJ. The long-term results of stereotaxic surgery and L-Dopa therapy in patients with Parkinson's disease. *J Neurosurg* 1980;53:332-7.
- 32 Lenz FA, Kwan HC, Martin RL, et al. Single unit analysis of the human ventral thalamic nuclear group. Tremor related activity in functionally identified cells. *Brain* 1994;117:531-43.
- 33 Ohye C, Shibasaki T, Hirai T, et al. Further physiological observations on the ventralis intermedius neurons in the human thalamus. *J Neurophysiol* 1989;61:488-500.
- 34 Narabayashi H, Yokochi F, Nakajima Y. Levodopa-induced dyskinesias and thalamotomy. *J Neurol Neurosurg Psychiatry* 1984;47:831-9.
- 35 Vitek J, DeLong MR. Posteroventral pallidotomy for Parkinson's disease: Clinical results after one year follow up. In: Obeso JA, DeLong MR, Ohye Ch, Marsden CD, eds. *The basal ganglia and surgical treatment of Parkinson's disease. Advances in neurology*. New York: Raven Press (in press).
- 36 Dogali M, Fazzini R, Kolodny P, et al. Stereotactic ventral pallidotomy for Parkinson's disease. *Neurology* 1995;45:753-61.
- 37 Sutton JP, Couldwell W, Lew MF, et al. Ventroposterior medial pallidotomy in patients with advanced Parkinson's disease. *Neurosurgery* 1995;36:1112-7.
- 38 Iacono RP, Shima F, Lonser RR. The results, indications and physiology of posteroventral pallidotomy for patients with Parkinson's disease. *Neurosurgery* 1995;36:1118-27.
- 39 Lozano AM, Lang AE, Galvez-Jimenez N, et al. Effect of GPi pallidotomy on motor function in Parkinson's disease. *Lancet* 1995;346:1383-7.
- 40 Obeso JA, Linazasoro G, Rothwell JC, et al. Assessing the efficacy of pallidotomy in Parkinson's disease. *Lancet* 1996;347:1490.
- 41 Ceballos-Bauman AO, Obeso JA, Vitek JL, et al. Restoration of thalamocortical activity after posteroventral pallidotomy in Parkinson's disease. *Lancet* 1994;344:814.
- 42 Grafton ST, Waters C, Sutton J, Lew MF, Couldwell W. Pallidotomy increases activity of motor association cortex in Parkinson's disease: a positron emission tomography study. *Ann Neurol* 1995;37:776-83.
- 43 Sellal F, Losovoski F, Hirsch E, et al. Contralateral disappearance of parkinsonian signs after subthalamic hematoma. *Neurology* 1992;42:255-66.
- 44 Vidakovic A, Dragasevic N, Rostic VS. Hemiballism: report of 25 cases. *J Neurol Neurosurg Psychiatry* 1994;57:945-9.
- 45 Inzelberg R, Korczyn A. Persistent hemiballismus in Parkinson's disease. *J Neurol Neurosurg Psychiatry* 1994;57:1013.
- 46 Guridi J, Luquin MR, Herrero MT, Obeso JA. The subthalamic nucleus: a possible target for stereotaxic surgery in Parkinson's disease. *Mov Disord* 1993;8:421-9.
- 47 Blond S, Caparros-Lefebvre D, Parker F, et al. Control of tremor and involuntary movement disorders by chronic stereotactic stimulation of the ventral intermediate thalamic nucleus. *J Neurosurg* 1992;77:62-8.
- 48 Benabid AL, Pollak P, Gervason C, et al. Long-term suppression of tremor by chronic stimulation of the ventral intermediate thalamic nucleus. *Lancet* 1991;337:403-6.
- 49 Benabid AL, Pollak P, Dongming G, et al. Chronic electrical stimulation of the ventral intermedius nucleus of the thalamus as a treatment of movement disorders. *J Neurosurg* 1996;84:203-14.
- 50 Limousine P, Pollak P, Benazzouz A, et al. Improvement in parkinsonian symptoms after bilateral subthalamic nucleus stimulation. *Lancet* 1995;345:91-5.
- 51 Limousine P, Pollak P, Hoffmann D, et al. Abnormal involuntary movements induced by subthalamic nucleus stimulation in parkinsonian patients. *Mov Disord* 1996;11:231-5.
- 52 Quinn NP. Multiple system atrophy—The nature of the beast. *J Neurol Neurosurg Psychiatry* 1989;52(suppl):78-89.
- 53 Friedman JH, Epstein M, Sanes J, et al. Gamma knife pallidotomy in advanced Parkinson's disease. *Ann Neurol* 1996;39:535-8.

---

## NEUROLOGICAL STAMP

---

### Crawford Williamson Long (1815-78)

In 1842 a country practitioner, Crawford Long of Jefferson, Jackson County, Georgia, had participated in "ether frolics". These were wild parties in which ether was inhaled for exhilarative effects. He noted that bruises or minor injuries sustained at the time were unaccompanied by pain. This suggested to him the possibility of using it more constructively to provide surgical anaesthesia and in 1842 he administered ether to a boy, James Venable, and painlessly excised a tumour of his neck. Long used ether on other patients but as a simple modest country practitioner few surgical cases came to him for treatment. However, he was probably the first physician to perform surgery using ether as an anaesthetic. He did not publish his discovery to the medical world until 1849, although he continued its use in surgery and obstetrics throughout his life. Long was postally honoured by the United States as a physician in 1940 (Stanley Gibbons 872, Scott 875).

L F HAAS

