

Acute Retinal Necrosis Associated with Epstein-Barr Virus in a Patient Undergoing Immunosuppressive Therapy

Chiaki Oe^a Miki Hiraoka^a Sachie Tanaka^b Hiroshi Ohguro^a

^aDepartment of Ophthalmology, School of Medicine, Sapporo Medical University, and

^bDepartment of Ophthalmology, JR Sapporo Hospital, Sapporo, Hokkaido, Japan

Key Words

Acute retinal necrosis · Epstein-Barr virus · Methotrexate · Polymerase chain reaction

Abstract

Acute retinal necrosis (ARN) is a rapidly progressive and severe retinitis resulting in a poor visual outcome. Infections caused by herpes viruses such as herpes simplex virus (HSV) types 1 and 2 or the varicella zoster virus (VZV) are known to be implicated in the development of ARN. In the present study, an 80-year-old female with ARN was examined. She had been affected with rheumatoid arthritis and had taken methotrexate for over 10 years. Her right eye showed clinical features of ARN, and her left eye showed mild retinitis. The genomic DNA in the aqueous humor and vitreous fluid from her right eye were analyzed by a comprehensive polymerase chain reaction (PCR) assay to screen infectious pathogens including viruses. The Epstein-Barr virus (EBV) was detected from both specimens, but neither HSV or VZV nor cytomegalovirus was detected. She underwent intraocular surgery following systemic corticosteroid and acyclovir applications. However, although the retinitis of her right eye was extinguished, the final visual outcome was blindness due to optic nerve atrophy. There are few reports indicating that EBV is associated with ARN development. The present findings suggest that EBV alone can be the causative agent of ARN.

© 2016 The Author(s)
Published by S. Karger AG, Basel

Introduction

Acute retinal necrosis (ARN) was first described in 1971 [1]. The typical clinical features of ARN include anterior uveitis and various retinal changes such as multifocal exudation, occlusive vasculopathy, retinal edema, retinal necrosis starting from the peripheral retina and extending to its posterior area, dense vitreous clouding and optic neuropathy. It can be unilateral or bilateral. The etiology of ARN is thought to be related to the retinal viral reactivation. The most common cause is the Herpesviridae family, particularly the varicella zoster virus (VZV) and herpes simplex virus (HSV) types 1 and 2 [2, 3].

The Epstein-Barr virus (EBV) is a DNA virus of the Herpesviridae family. It is believed that more than 90% of the subjects infected with EBV transmit it orally or through blood. EBV is known to cause mononucleosis syndrome and is also associated with Burkitt lymphoma and nasopharyngeal carcinoma. The virus exhibits affinity to B lymphocytes and nasopharyngeal epithelial cells [4]. However, primary infection with EBV in childhood is commonly subclinical, and in most cases, EBV-infected B lymphocytes are latent. The clinical symptoms in adulthood are magnified when the EBV in infected B cells is reactivated. The viral reactivation is often observed in an immunosuppressive state. The clinical feature of ocular disease by EBV infection is not clear.

Although the diagnosis of ARN is made by its typical ocular features, the examination of pathogens, especially herpes viruses, is important. For the last decade, the advances made in molecular analytical techniques, including genomic screening of multiple pathogens, were remarkable. It is now more preferable to test focal samples rather than conducting a serum antibody titer for viruses. The multiplex polymerase chain reaction (PCR) system has made it possible to detect multiple pathogens from small volume samples such as those in the aqueous humor and vitreous fluid [5]. The ample evidence of herpes virus existing in ocular fluid or ocular tissues can lead to a greater understanding of the etiology of ARN [6].

In this report, we describe a case of ARN in which EBV was detected in intraocular fluid. These findings suggest that EBV is implicated as a cause of ARN.

Case Presentation

The medical records of our patient with ARN were retrospectively reviewed. An 80-year-old woman developed blurred vision in both eyes 1 month before presenting to JR Sapporo Hospital. Upon entering, an examination found evidence of iritis, vitreous opacity, a mild vitreous hemorrhage and extensive multifocal exudation around the optic disc in her right eye (fig. 1a), as well as mild vitreous opacity, an optic disc hemorrhage and peripheral white granulomatous exudation in her left eye (fig. 1b). A fluorescein fundus angiography demonstrated hyperfluorescence of the optic disc and a wide range of occlusive vasculitis in her right eye (fig. 1c), and retinal vasculitis in the nasal area in her left eye (fig. 1d). The aqueous humor of the right eye was subsequently collected for pathogen analysis by the PCR system. Since the serological analysis was positive for cytomegalovirus (CMV) IgG, she was presumed to have CMV retinitis. She received ganciclovir (75 mg/day) orally, but this triggered no effective response. The uveoretinitis in her right eye deteriorated, and after 1 week, she was transferred to our hospital. Upon admittance, she disclosed that she had been taking oral methotrexate for over 10 years for rheumatoid arthritis.

The initial ophthalmic examination showed a best-corrected visual acuity of light perception in the right eye and 20/25 in the left eye. The intraocular pressure was 13 mm Hg in the right eye and 10 mm Hg in the left eye. A slit-lamp examination demonstrated moderate

cell infiltration in the anterior chamber, severe vitreous infiltration, an inferior vitreous hemorrhage and massive exudation in the posterior pole in her right eye. There was no sign of apparent progression in her left eye (fig. 1f). Both eyes showed substantial anterior chamber depth without goniosynechia, and mild senile cataracts.

Results of the laboratory investigations of serum including antinuclear antibodies, anti-double stranded DNA antibodies, an adult T-cell leukemia antigen and antineutrophil cytoplasmic antibodies were unremarkable except for a high rheumatoid factor value. Serological analyses indicated that there was no active infection of syphilis, tuberculosis, human T-cell lymphoma virus 1 or toxoplasma gondii. The virus antibody titer screen was negative for IgM and positive for IgG for HSV, VZV, and CMV. The EBV antibody test showed negative for either IgG against an early antigen or IgM against a viral capsid antigen and positive for both IgG against a viral capsid antigen and IgG against a nuclear antigen.

The patient received continuous administration of topical betamethasone and intravenous aciclovir (700 mg/day) upon admission. Due to the progressive symptoms in her right eye, vitrectomy, retinal photocoagulation and silicone oil tamponade were applied, and phacoemulsification surgery was conducted 5 days after admission. The fundus findings during surgery showed the occlusive vasculopathy of the entire retina, retinal fibrosis and retinal detachment with retinal breaks and vitreous traction (fig. 1e). The vitreous fluid was collected for cytology and pathogen screening. The cytological examination of infiltrated cells in vitreous fluid showed lymphocytes and a few neutrophils but no atypical cells. The culture examination using vitreous fluid was negative for bacteria or fungus. The genomic DNA in vitreous fluid was analyzed by comprehensive PCR to screen infectious pathogens including bacteria, parasites and viruses. The PCR analysis was performed in the laboratory for retinal regeneration at Riken's Center for Developmental Biology (Kobe, Japan), as previously described [5].

Both the aqueous humor that was collected at the former hospital and vitreous fluid that was collected during surgery showed high copies of EBV but were negative to HSV, VZV, CMV and other pathogens (table 1). Two days after surgery, the patient received oral valaciclovir (1,500 mg/day) and prednisolone (30 mg/day). The dosage of valaciclovir and prednisolone administration was reduced gradually without recurrence of retinitis or development of side effects. Retinal atrophy occurred in her right eye in the necrosis area, and optic nerve atrophy also developed. This resulted in a loss of light perception in the eye. The lesion in her left eye was diminished by the drug treatment. No relapse was observed in 1 year.

Discussion

In this report, we described a case of ARN. The genomic DNA analysis for virus testing of intraocular fluids showed a high copy number of EBV but was negative for HSV and VZV.

The clinical diagnosis of ARN is based on its characteristic ocular outcome. In addition, the high frequency in detecting VZV and HSV in intraocular fluid or tissues leads to the belief that the causative pathogens of ARN are VZV and HSV [2, 3, 7]. Since the predilection age of ARN is during adulthood, it is thought that the development of ARN is introduced by reactivation of latent viruses such as VZV and HSV. Due to advances in genomic DNA analysis, it is possible to screen pathogens using small sizes of local specimens. These results help elucidate the etiology of many diseases. In intraocular inflammation, the pathogen screening of the aqueous humor and vitreous fluid is not only harmless but also informative in the diagnosis and determination of the treatment. Recently, Sugita et al. [5] developed a two-step PCR protocol to examine multiple pathogens from small-volume ocular fluids. The first step

is to screen the genomic DNA of several pathogens by multiplex PCR. Every positive pathogen detected by multiplex PCR is then examined by real-time PCR for quantification of the pathogen load. In ARN, high copy numbers of HSV and VZV can be detected through this method [6]. This emphasizes that the reactivation of HSV or VZV in the eye is responsible for the development of ARN. In our case, several pathogens in ocular fluid were examined using this two-step PCR.

The initial infection of EBV is thought to occur in young children without any symptoms or with acute inflammatory diseases that are not recognized as being due to EBV. The major host cells of EBV are B lymphocytes, and infected B cells are persistent throughout life. However, EBV in infected B cells is mostly latent. Although the trigger has yet to be clarified, latent infected B cells can be stimulated to reactivate EBV, which results in the production of a large number of viruses [4]. The EBV reactivation is often observed in individuals undergoing immunosuppression. It is speculated that immunosuppression, either by medication or illness, makes the immune system lose control of EBV replication.

EBV DNA was detected even in ocular tissues from healthy donors by PCR [8]. This suggests that the large amount of EBV production by reactivation in the eye can lead to the development of intraocular diseases such as uveitis [9]. Previously, some uveitis cases were reported to be associated with EBV from the profile of EBV antibody titers in serum and the aqueous humor [10, 11]. In a recent report, patients receiving long-term systemic corticosteroids showed a high copy number of EBV DNA with severe intraocular inflammation [9].

There have been recent reports on the involvement of EBV in ARN. Several studies showed that EBV DNA was found in the ocular fluid of ARN patients who were also positive to VZV DNA [2, 3, 6, 9]. Those patients in whom both VZV and EBV were detected developed more severe symptoms than those with VZV alone [6].

However, there are also reports stating that only EBV is associated with ARN development. In these reports, EBV DNA was detected from ocular fluid and retinal tissues that were absent from HSV, VZV or CMV [12–14]. Among these cases, 1 patient was affected with a lymphoproliferative disorder, and another patient was receiving systemic methylprednisolone and infliximab. It is likely that the long-term application of methotrexate induced a reactivation of EBV in the eyes of our case. The virus load of the aqueous humor and vitreous fluid showed a high copy number of EBV (2.07×10^5 [5] and 5×10^6 copies/ml, respectively), with a lack of other pathogens. These results indicate that EBV alone is associated with the development of ARN in our case. The ophthalmic outcome of the right eye in our case was typical of ARN, other than the retinal necrosis lesions being severe in the peripapillary rather than peripheral area. Usui and Sakai [10] reported that the vasculitis is prominent in the peripapillary area in EBV-associated uveitis. It is possible that pathological change is dominant in the peripapillary area in EBV associated with ARN. The causative pathogens of ARN are known as VZV and HSV. Although to date there have been few cases of EBV-associated ARN, even with the addition of our present study, our results are informative in that they show that EBV activation in ocular tissue can lead to the development of ARN. Reviewing the characteristic traits among those EBV-associated ARN cases should help lead to a greater understanding of the pathology of ARN.

The present findings suggest EBV alone can cause ARN, especially in individuals undergoing immunosuppression. Because EBV exists in unaffected tissues, it is important to determine the pathogenic value of the virus load from local samples. Further investigation with increased numbers of case studies and statistical analysis may lead to the establishment of reliable criteria for EBV-associated ARN.

Acknowledgement

We would like to thank Dr. Sunao Sugita from the Laboratory for Retinal Regeneration at the Riken Center for Developmental Biology for his pathogen analysis by PCR.

Statement of Ethics

The present study protocol was approved by the Ethics Committee of the Sapporo Medical University School of Medicine.

Disclosure Statement

The authors declare that they have no conflicts of interest.

References

- 1 Urayama A, Yamada N, Sasaki T, Nishiyama Y, Watanabe H, Wakusawa S: Unilateral acute uveitis with retinal periarteritis and detachment. *Rinsho Ganka* 1971;25:607–619.
- 2 Lau CH, Missotten T, Salzmann J, Lightman SL: Acute retinal necrosis features, management, and outcomes. *Ophthalmology* 2007;114:756–762.
- 3 Hillenkamp J, Nolle B, Bruns C, Rautenberg P, Fickenscher H, Roeder J: Acute retinal necrosis: clinical features, early vitrectomy, and outcomes. *Ophthalmology* 2009;116:1971–1975e2.
- 4 Odumade OA, Hogquist KA, Balfour HH Jr: Progress and problems in understanding and managing primary Epstein-Barr virus infections. *Clin Microbiol Rev* 2011;24:193–209.
- 5 Sugita S, Shimizu N, Watanabe K, et al: Use of multiplex PCR and real-time PCR to detect human herpes virus genome in ocular fluids of patients with uveitis. *Br J Ophthalmol* 2008;92:928–932.
- 6 Sugita S, Iwanaga Y, Kawaguchi T, et al: Detection of herpesvirus genome by multiplex polymerase chain reaction (PCR) and real-time PCR in ocular fluids of patients with acute retinal necrosis. *Nippon Ganka Gakkai Zasshi* 2008;112:30–38.
- 7 Takase H, Okada AA, Goto H, et al: Development and validation of new diagnostic criteria for acute retinal necrosis. *Jpn J Ophthalmol* 2015;59:14–20.
- 8 Chodosh J, Gan YJ, Sixbey JW: Detection of Epstein-Barr virus genome in ocular tissues. *Ophthalmology* 1996;103:687–690.
- 9 Yamamoto S, Sugita S, Sugamoto Y, Shimizu N, Morio T, Mochizuki M: Quantitative PCR for the detection of genomic DNA of Epstein-Barr virus in ocular fluids of patients with uveitis. *Jpn J Ophthalmol* 2008;52:463–467.
- 10 Usui M, Sakai J: Three cases of EB virus-associated uveitis. *Int Ophthalmol* 1990;14:371–376.
- 11 Wong KW, D'Amico DJ, Hedges TR III, Soong HK, Schooley RT, Kenyon KR: Ocular involvement associated with chronic Epstein-Barr virus disease. *Arch Ophthalmol* 1987;105:788–792.
- 12 Hamam RN, Mansour A, El Mollayess G: Positive Epstein-Barr virus polymerase chain reaction in a case of acute retinal necrosis. *Can J Ophthalmol* 2012;47:e61–e62.
- 13 Schaal S, Kagan A, Wang Y, Chan CC, Kaplan HJ: Acute retinal necrosis associated with Epstein-Barr virus: immunohistopathologic confirmation. *JAMA Ophthalmol* 2014;132:881–882.
- 14 Hershberger VS, Hutchins RK, Witte DP, Schneider S, Harris RE, McGonegle SJ: Epstein-Barr virus-related bilateral acute retinal necrosis in a patient with X-linked lymphoproliferative disorder. *Arch Ophthalmol* 2003;121:1047–1049.

Oe et al.: Acute Retinal Necrosis Associated with Epstein-Barr Virus in a Patient Undergoing Immunosuppressive Therapy

Table 1. Results of pathogen analysis by multiplex PCR in ocular fluids of the patient

Pathogen	Aqueous humor	Vitreous fluid
HSV type 1	N.D.	N.D.
HSV type 2	N.D.	N.D.
VZV	N.D.	N.D.
CMV	N.D.	N.D.
EBV	2.07×10^5 copies/ml	5.0×10^6 copies/ml
Toxoplasma gondii	N.D.	N.D.
Tuberculosis	N.P.	N.D.
Candida	N.P.	N.D.

N.D. = Not detected; N.P. = not performed.

Oe et al.: Acute Retinal Necrosis Associated with Epstein-Barr Virus in a Patient Undergoing Immunosuppressive Therapy

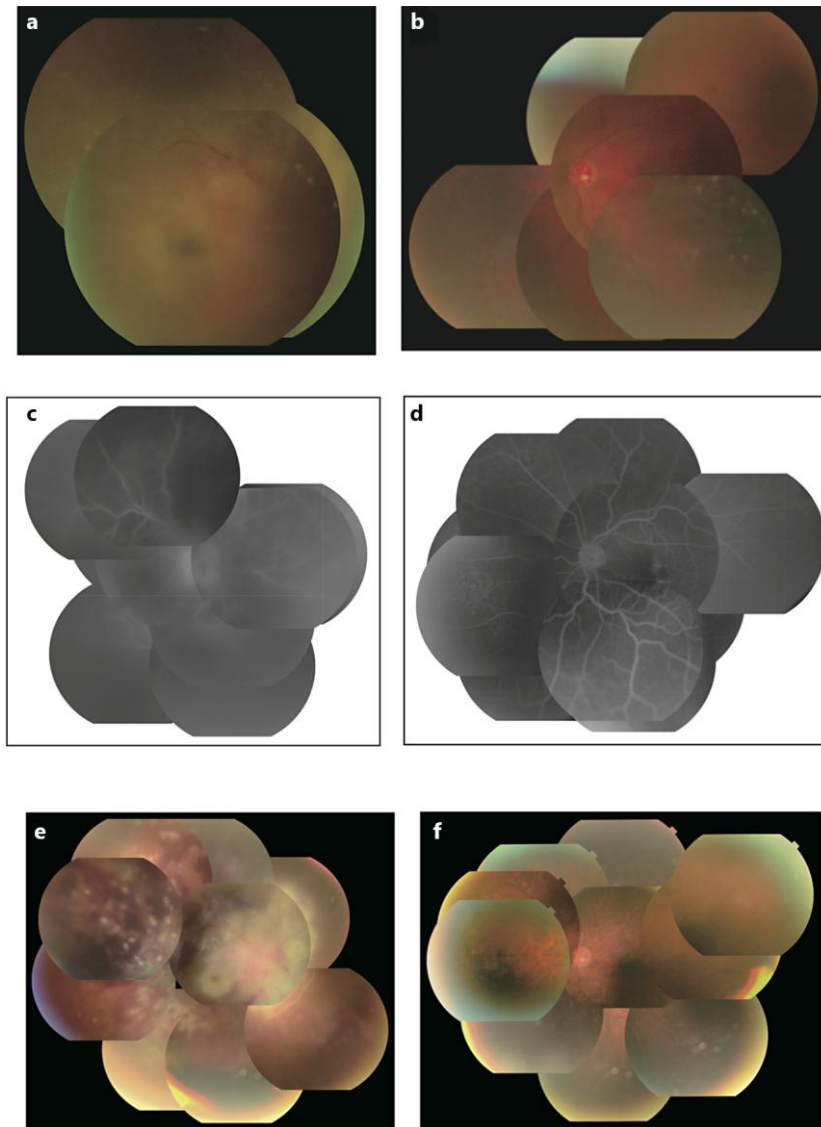


Fig. 1. Fundus photographs and fluorescein fundus angiography. **a** Fundus photographs of the right eye with vitreous opacity, a mild vitreous hemorrhage and extensive multifocal exudation around the optic disc. **b** Fundus photographs of the left eye with mild vitreous opacity, an optic disc hemorrhage and peripheral white granulomatous exudation. **c** Fluorescein fundus angiography of the right eye with hyperfluorescence of the optic disc and a wide range of occlusive vasculitis. **d** Fluorescein fundus angiography of the left eye with retinal vasculitis in the nasal area. **e** Fundus photographs of the right eye, showing the occlusive vasculopathy with multiple hemorrhages and exudation of the entire retina and retinal fibrosis. **f** Fundus photographs of the right eye without any sign of apparent progression.