

Sir,  
**Intravitreal fluocinolone acetonide (Iluvien) for treatment of refractory diabetic macular oedema in vitrectomised eyes**

This article has been corrected since Advance Online Publication and a corrigendum is also printed in this issue

We report the clinical efficacy and safety of intravitreal Iluvien implant in vitrectomised eyes of chronic diabetic macular oedema (DMO), irrespective of the timing of vitrectomy procedure.

**Case reports**

**Case 1** A 50-year-old diabetic female received multiple intravitreal anti-VEGF and triamcinolone (IVT) injections for chronic DMO (Figure 1), and subsequent vitrectomy

**Figure 1** Case 1: Left eye OCTs (a–d). (a) Severe vitreo-macular traction on chronic diabetic DM0. (b) Post-vitrectomy (pre-Iluvien) showed recurrent mild diffuse DMO persisting. (c) Partial resolution of DMO 1 week post Iluvien. (d) No evidence of recurrence after 1 year, without further adjunctive therapy. Abbreviations: CRT, central retinal thickness; OCT, optical coherence tomography; VA, visual acuity.

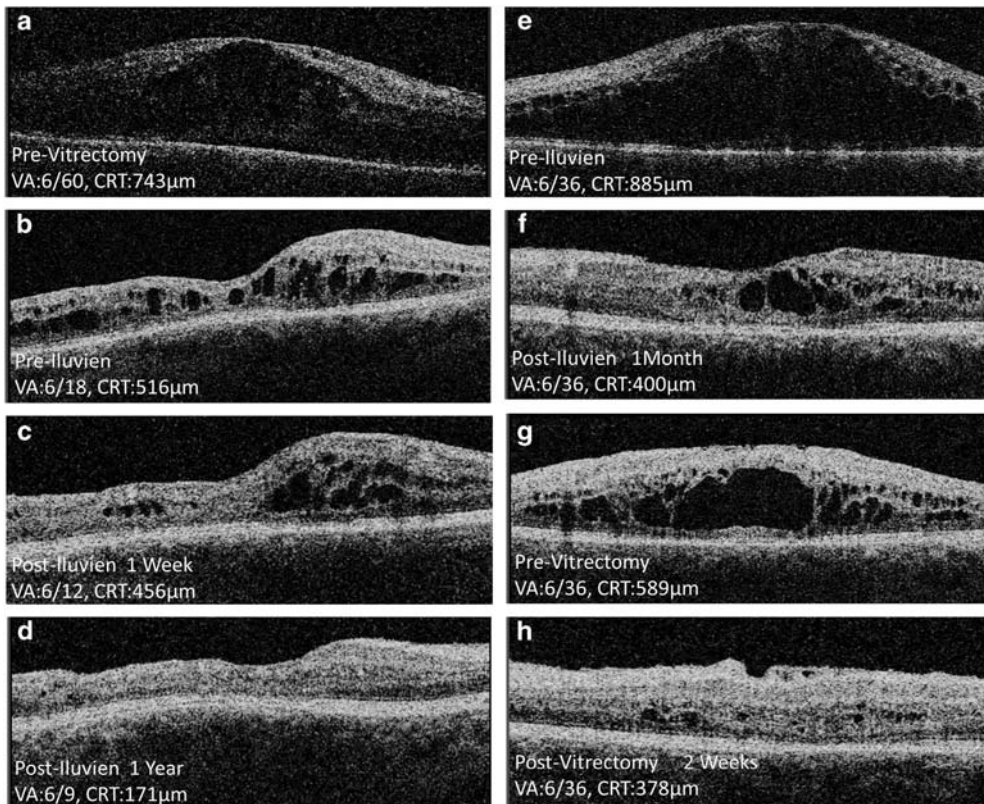
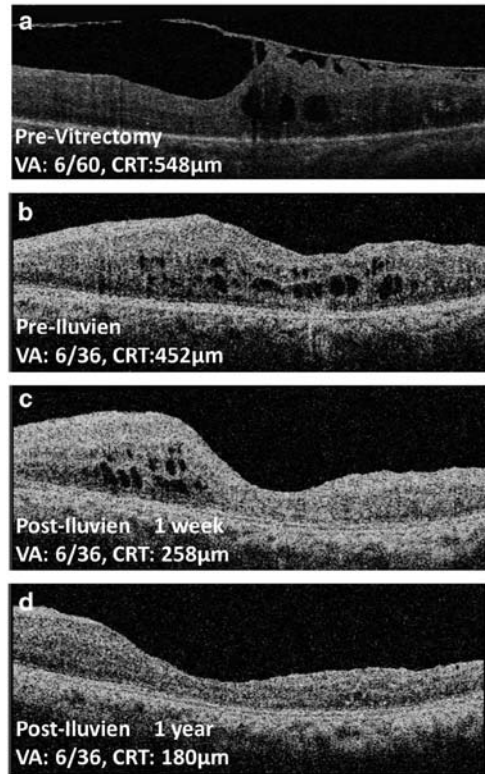


Figure 2 For caption see next page.

**Figure 2** Case 2: Right eye OCTs (a–d), left eye OCTs (e–h). (a) Recurrent vitreous haemorrhage and gross DMO before vitrectomy. (b) Recurrent persistent DMO, 3 years post vitrectomy (4 months post last triamcinolone injection). (c) Partial resolution of DMO 1 week post Iluvien. (d) DMO resolution was complete after 1 year, without further adjunctive therapy. (e) Pre-Iluvien left eye showed refractory gross DMO. (f) Incomplete resolution of DMO 1 month post Iluvien. (g) Recurrence was evident within few months. (h) Improved DMO 2 weeks post vitrectomy. Abbreviations: CRT, central retinal thickness; OCT, optical coherence tomography; VA, visual acuity.

for severe macular traction. Post-vitrectomy DMO was still present despite additional intravitreal therapies. She received Iluvien implant 7 months post vitrectomy. Post-Iluvien DMO resolved with no further adjunctive therapy up to 1 year.

**Case 2** A 48-year-old diabetic male with bilateral proliferative retinopathy and DMO received many laser and anti-VEGF therapies (Figure 2), but responded best to repeated IVT injections over a 9-year period. The right eye underwent vitrectomy for recurrent vitreous haemorrhage 3 years before bilateral Iluvien implantations. The right DMO resolved gradually over 1 year without adjunctive therapy; left eye DMO responded only briefly before recurring significantly. Vitrectomy (with the Iluvien implant preserved *in situ*) for the left eye was carried out a year later, and achieved DMO resolution post-vitrectomy.

#### Comment

Intravitreal steroids and anti-VEGF therapies were known to be effective and may have complementary effects on reducing retinal vascular permeability.<sup>1</sup> Surgical intervention as a means to treat unresponsive DMO however, showed inconclusive benefit in the absence of tractional DMO.<sup>2</sup> Study on non-diabetic rabbits suggested no differences in pharmacokinetics/concentration of short-term intravitreal steroid in vitrectomised *vs* non-vitrectomised eyes,<sup>3</sup> contradicting the positive results of clinical studies on diabetic patients.<sup>4,5</sup>

Given that patient 2 had a dramatic result in a previously vitrectomised eye and then a similar effect in other eye post-vitrectomy, concomitant systemic influence is unlikely to contribute to the positive outcomes. Both patients had good risk-factor control and experienced no adverse effects. Our cases demonstrated that intravitreal Iluvien could achieve desirable anatomical improvement in chronic DMO in vitrectomised eyes, in the first year without adjunctive therapy. It also raised an interesting concept that vitrectomy, indicated for varied clinical reasons, may enhance the performance of Iluvien implant when performed at any stage. Larger controlled studies nevertheless are needed to further evaluate the concept.

#### Conflict of interest

AM is an Advisory Board Member of Alimera Sciences. The remaining authors declare no conflict of interest.

#### References

- 1 Nehme A, Edelman J. Dexamethasone inhibits high glucose-, TNF-alpha-, and IL-1beta-induced secretion of inflammatory

and angiogenic mediators from retinal microvascular pericytes. *Invest Ophthalmol Vis Sci* 2008; **49**(5): 2030–2038.

- 2 Figueroa MS, Contreras I, Noval S. Surgical and anatomical outcomes of pars plana vitrectomy for diffuse nontractional diabetic macular edema. *Retina* 2008; **28**(3): 420–426.
- 3 Chang-Lin JE, Burke JA, Peng Q, Lin T, Orilla W, Ghosn C *et al.* Pharmacokinetics of a sustained-release dexamethasone intravitreal implant in vitrectomized and nonvitrectomized eyes. *Invest Ophthalmol Vis Sci* 2011; **52**(7): 4605–4609.
- 4 Lee SS, Ghosn C, Yu Z, Zacharias LC, Kao H, Lanni C *et al.* Vitreous VEGF clearance is increased after vitrectomy. *Invest Ophthalmol Vis Sci* 2010; **51**(4): 2135–2138.
- 5 Boyer DS, Faber D, Gupta S, Patel S, Tabandeh H, Li XL *et al.* Dexamethasone intravitreal implant for treatment of diabetic macular edema in vitrectomized patients. *Retina* 2011; **31**(5): 915–923.

A Kumar, Q Alfahad, A Mitra, S Elsherbiny and PL Lip

Birmingham and Midland Eye Centre, City Hospital, Birmingham, UK  
E-mail: pllipwoo@gmail.com

*Eye* (2016) **30**, 763–764; doi:10.1038/eye.2015.281;  
published online 22 January 2016

#### Sir, Cannula-associated ocular injuries during cataract surgery: the North East England Study

Cannula–syringe systems are frequently used during ophthalmic surgeries, including cataract surgery. Although rare, several reports in the literature have described the unfortunate incident of dislodged cannula from the syringe damaging the intraocular structures.<sup>1–4</sup> So far there was no study examined the incidence rate of cannula-associated ocular injury (COI) in the United Kingdom. Our study aims to determine the incidence rate, types and extent, clinical implications, and visual outcome of COI in the North East of England (NEE), UK.

A 10-item questionnaire-based online survey (Table 1) was sent to 81 ophthalmologists, including 48 consultants and 33 specialist doctors/trainees, in NEE to evaluate COI during cataract surgery between January 2005 and December 2014. Surgeons were divided into experienced surgeons (those who had performed  $\geq 1000$  cases of cataract surgery) and less experienced surgeons (those who had performed  $< 1000$  cases) for analytic purpose.

The survey response rate was 65% (53/81). Of the 75275 cataract surgeries over the 10-year period, 7 (0.009%) cases of dislodged cannula from syringe were reported (Table 2). Three (43%) cases of dislodged cannula resulted in intraocular injuries, yielding a COI incidence rate of