

The story of fatty heart

A disease of Victorian times

Evan Bedford

Obesity has long been regarded as shortening the expectation of life and still is by insurance companies today. Hippocrates (Aphorism 44) stated that very fat persons were apt to die earlier than those who were slender, and Celsus (Aphorism 11) stated that fat people were very subject to acute diseases and were strangled by a difficulty in breathing and often died suddenly (Sprenghell, 1708). Senac (1783) cited a case of sudden death in which fat spreading over the heart extinguished its movement. Corvisart (1806) described conversion of the muscular tissue of the heart into a fatty substance and compared it with the fatty changes in voluntary muscles in old people recognized by Vicq d'Azyr and Haller. He believed that in obese people the heart was oppressed and smothered by an immense quantity of fat which enveloped it on every side and that this sometimes caused sudden death. Laennec (1819) devoted a chapter in his *Treatise on Mediate Auscultation* to fatty heart and established it as a cardiological entity. He distinguished between surcharge of fat on the surface of the heart and fatty degeneration in which the muscular substance was transformed into fat exhibiting a yellowish pallor like dead leaves, a description that was repeated almost verbatim in most later accounts.

Passing on to the middle of the 19th century, we come to the important papers of Paget (1847), Ormerod (1849), and Richard Quain (1850) (Fig. 1). Paget emphasized that fatty degeneration implied fat not on but in the muscular fibres which became converted into fatty tubes. Quain's paper of 75 pages makes tedious reading today, but it established his reputation as the leading authority on the subject and Quain's fatty heart became a commonplace diagnosis as familiar and ominous to the lay public as coronary thrombosis is today. East (1957) cites George Eliot's *Middlemarch* in which young Dr. Lydgate, called to a patient with sudden dyspnoea,

diagnosed fatty degeneration of the heart and warned him that death from this disease was often sudden.

Quain and his contemporaries followed Laennec in distinguishing between fatty surcharge spreading over the surface of the heart (Fig. 2), especially the right ventricle, and infiltrating between the muscular fibres causing pressure atrophy with thinning of the ventricular wall, and fatty degeneration in which the muscle was pale, soft, and friable, and microscopical examination showed an accumulation of fatty droplets within the sarcolemma. The clinical features included a languid, feeble circulation, oppression in the chest, distress in breathing, coma, syncope, rupture of the heart, and sudden death. Quain's most important contribution was his recognition that localized fatty change was associated with obstruction of the nutrient coronary branch.

The next chapter in our story relates to Dublin where cardiology was flourishing at this time and where Cheyne, Stokes, Adams, Bellingham, and Hayden became obsessed with fatty heart as the most important form of myocardial disease. They sought to identify it with a clinical syndrome which included almost every known symptom of heart disease, but especially with recurrent pseudo-apoplectic attacks without residual paralysis, now known as Adams-Stokes attacks, Cheyne-Stokes breathing, and a slow pulse. While admitting that coronary sclerosis was often present, they maintained that fatty change and atrophy in the myocardium was the primary cause of the symptoms and that these were not necessarily accompanied by coronary disease. Sudden death was quite a frequent termination and so the evil reputation of fatty heart became firmly established. When Sir William Jenner spoke of fatty degeneration as a preservative lesion protecting the decaying vessels and so diminishing the risk of apoplexy, he was greeted by shouts of




FIG. I *Sir Richard Quain.*
Portrait by Sir John Millais in the Royal College of Physicians, London.

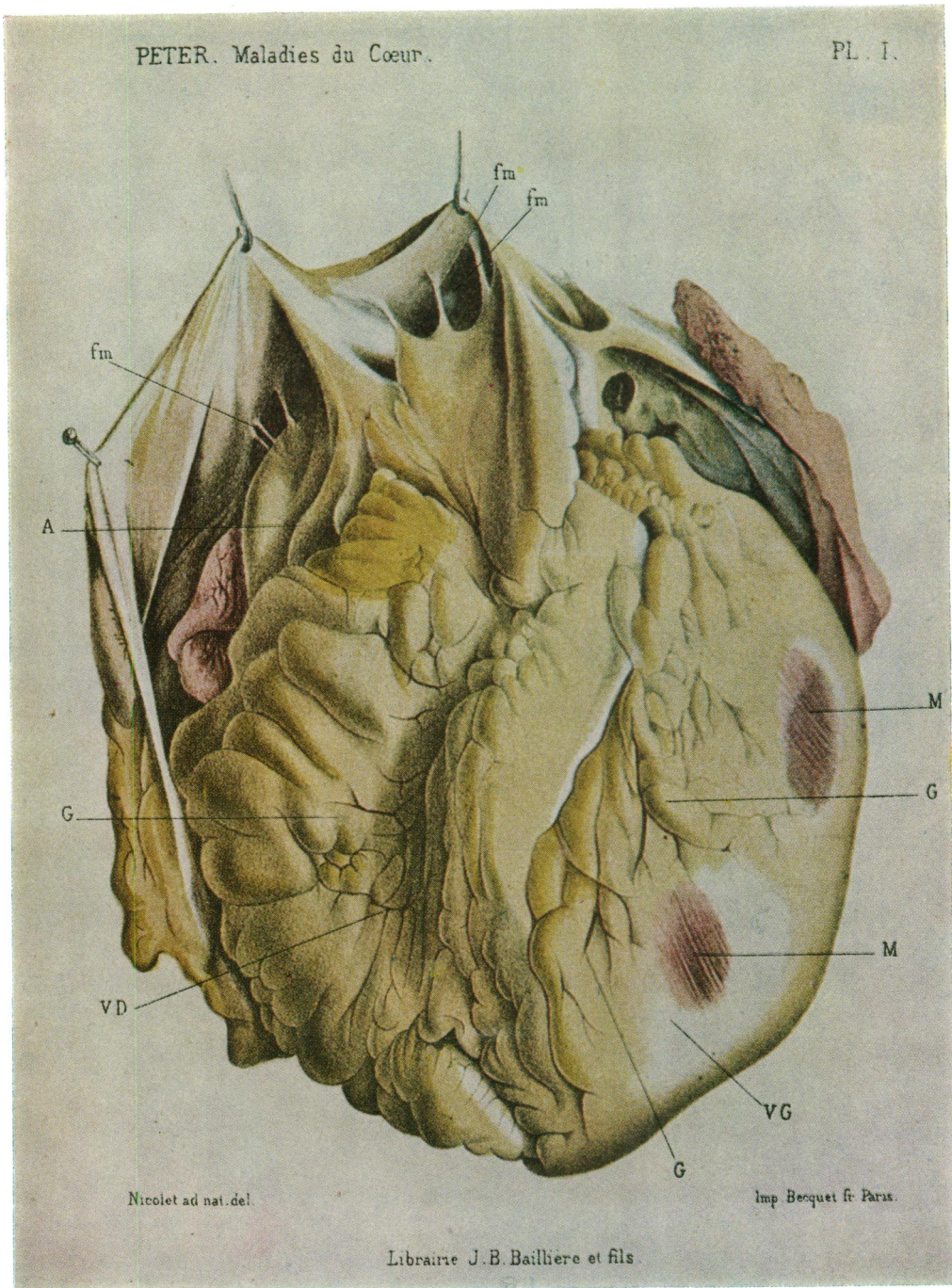


FIG. 2 Fatty myocarditis with enormous fatty surcharge due to alcoholism. VD, right ventricle; VG, left ventricle; G, fat; M, yellowish pink myocardium. (From C. F. M. Peter. *Traité Clinique et Pratique des Maladies du Cœur et de la Crosse de l'Aorte*, 1883.)


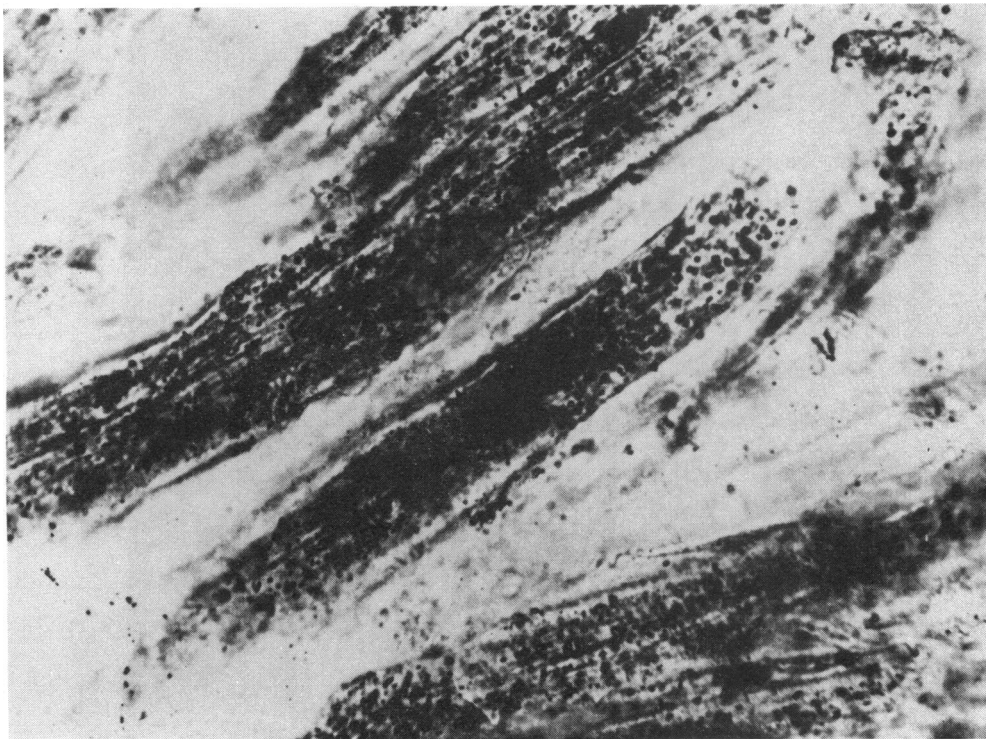


FIG. 3 *Microscopic appearances of heart muscle (unstained): normal fibres (left) and fatty degeneration (right), early and late stages of which are marked a and b.*
(From *Quain, R.*, *Medico-Chirurgical Transactions*, 1850, 33, *Plate III.*)



Photomicrograph of recent myocardial infarct showing fatty droplets and loss of striations in the muscle fibres. Frozen sections stained Oil red O $\times 710$.

(From *Morgan, A. D.* *Medical History*, 1968, 12.)

derisive laughter at the Pathological Society of London according to Fothergill (1879) who came to share Jenner's view.

Perusal of standard textbooks on heart disease from 1850 onwards shows the importance attached to fatty heart by physicians in this country, Europe, and America. Much space was devoted to it, for example 38 pages by Stokes (1854), 121 pages by Hayden (1875), 43 by Fothergill (1879), and 15 by Austin Flint (1859). In Germany, Rosenbach (1897) and von Dusch (1868), and in France, Peter (1883) and Barié (1912) described it at length in their textbooks. In general these authors recounted the symptoms given by the Irish physicians including the *arcus senilis* which was usually mentioned. Fothergill dealt especially with fatty degeneration as a late complication of cardiac hypertrophy from renal disease, what he called the stage of failing hypertrophy, and he even described a peculiar gait of patients with fatty heart who walked with a guarded, quiet, and distrustful step. Alcohol was often mentioned as a cause and the condition was stated to be common in publicans and London gin drinkers (see Fig. 3).

To conclude the story, I must cite Gallavardin's monograph (1900) of 180 pages, which provides a masterly review of the subject to date. He was familiar with coronary occlusion and cardiac infarction which was excluded from the series of hearts he investigated which exhibited either fatty speckling or generalized softening and pallor. He recognized two forms of fatty degeneration: the first with macroscopical endocardial speckling showed islets of fatty change in sections, and the second was a diffuse process only recognizable by microscopical examination. He found fatty degeneration common in cachectic, anoxaemic, and anaemic states, and concluded that there were no specific clinical symptoms.

Morgan (1968) has made a careful analysis of Quain's cases and others shown at the Pathological Society of London from 1848 onwards, and he concludes that 52 of Quain's 83 cases were examples of ischaemic heart disease and that many specimens from cases of sudden death or ruptured heart were examples of acute infarction. He portrays Quain's figures of fatty degeneration alongside a microscopical section of an acute infarction, and the similarity is remarkable (Fig. 3).

By the end of the century, fibroid disease and chronic myocarditis had supplanted fatty heart as the fashionable diagnosis, and these conditions were regarded as inflamma-

tory rather than ischaemic. In spite of the recognition of cardiac infarction due to coronary occlusion by pathologists before the turn of the century, it was not until Herrick's second paper (1919) aroused the interest of American physicians that it gradually permeated the field of clinical medicine, and in no time the so-called modern epidemic of coronary disease erupted.

Fatty heart represents an epoch in our changing conceptions of myocardial disease and in our changing diagnostic habits. Starting with hypertrophy and dilatation we pass on to fatty heart, next to fibroid disease and chronic myocarditis, and finally to ischaemic heart disease and cardiomyopathies. Though physicians have lost interest in fatty heart which has virtually disappeared from modern textbooks, pathologists still describe it in terms very similar to Laennec's. By no means all Quain's cases had ischaemic heart disease and we must bear in mind that severe anaemias and cachectic states were far more often encountered at necropsy in the last century than today, thanks to improved methods of diagnosis and treatment.

To describe acute infarction as localized fatty change in the territory of an occluded branch was quite reasonable, indeed: 'what's in a name? that which we call a rose, by any other name would smell as sweet' Quain's most serious error was in failing to identify the essential clinical features. Stokes was no coronarian in regard to anginal pain, and, as Gallavardin remarked, his idea of fatty heart lacked anatomical precision, but even if he failed to recognize ischaemic heart disease at least we must give him credit for emphasizing the importance of the myocardium as the key to cardiac pathology at a time when his contemporaries were almost entirely concerned with valvar disease and physical diagnosis.

I wish to thank the Treasurer of the Royal College of Physicians for permission to reproduce the portrait of Sir Richard Quain, and Professor A. D. Morgan for permission to reproduce Fig. 3 from his paper in *Medical History*.

References

- Barié, E. (1912). *Traité Pratique des Maladies du Coeur et de l'Aorte*, 3rd ed., p. 1125. Vigot frères, Paris.
- Corvisart, J. N. (1806). *Essai sur les Maladies et les Lésions Organiques du Coeur et des Gros Vaisseaux*. Migneret, Paris.
- von Dusch, T. (1868). *Lehrbuch der Herzkrankheiten*. W. Engelmann, Leipzig.
- East, T. (1957). *The Story of Heart Disease*. Dawson, London.

- Flint, A. (1859). *A Practical Treatise on the Diagnosis, Pathology and Treatment of Diseases of the Heart*. Blanchard and Lea, Philadelphia.
- Fothergill, J. M. (1879). *The Heart and its Diseases*, 2nd ed. Lewis, London.
- Gallavardin, L. (1900). *La dégénérescence Graisseuse du Myocarde*. J. B. Baillière, Paris.
- Hayden, T. (1875). *The Diseases of the Heart and Aorta*. Fannin & Co., Dublin.
- Herrick, J. B. (1919). Thrombosis of the coronary arteries. *Journal of the American Medical Association*, 72, 387.
- Laennec, R. T. H. (1819). *De l'Auscultation Médiante ou Traité du Diagnostic des Maladies des Poumons et du Coeur*, Vol. 2, p. 295. Brosson and Chaudé, Paris.
- Morgan, A. D. (1968). Some forms of undiagnosed coronary disease in nineteenth-century England. *Medical History*, 12, 344.
- Ormerod, E. L. (1849). Observations on the clinical history and pathology of one form of fatty degeneration of the heart. *London Medical Gazette*, 9, 739.
- Paget, J. (1847). Lectures on nutrition, hypertrophy, and atrophy. *London Medical Gazette*, 5, 227.
- Peter, C. F. M. (1883). *Traité Clinique et Pratique des Maladies du Coeur et de la Crosse de l'Aorte*. J. B. Baillière, Paris.
- Quain, R. (1850). Fatty diseases of the heart. *Medico-Chirurgical Transactions*, 33, 121.
- Rosenbach, O. (1897). *Die Krankheiten des Herzens und ihre Behandlung*. Urban and Schwarzenberg, Wien and Leipzig.
- Senac, J. B. (1783). *Traité de la Structure du Coeur, de son Action, et de ses Maladies*, 2nd ed. Vol. 2, p. 384. Mequignon, Paris.
- Sprengell, C. J. (1708). *The Aphorisms of Hippocrates and the Sentences of Celsus*. R. Bonwick (and others), London.
- Stokes, W. (1854). *Diseases of the Heart and Aorta*. Hodges and Smith, Dublin.

Requests for reprints to Dr. Evan Bedford, 62 Wimpole Street, London W1M 7DE.