

Echocardiography of the mitral valve in aortic valve disease¹

R. B. Pridie², R. Benham, and C. M. Oakley

From the Radio-Diagnostic Department, the London Hospital, Whitechapel, London E.1, and the Department of Medicine (Clinical Cardiology), Royal Postgraduate Medical School, Hammersmith Hospital, London W.12

Ultrasonic echocardiograms from the anterior cusp of the mitral valve have been obtained in 75 patients with aortic regurgitation in whom there was haemodynamic or surgical confirmation, or both, of the state of the mitral valve. Coincident mitral stenosis could be recognized from the echocardiogram in all cases by a slow diastolic closure rate and widening of the echo from the anterior mitral cusp. In many of these patients delayed systolic closure of the mitral valve was also seen. All patients with an Austin Flint murmur had either premature systolic closure of the valve and an accelerated diastolic closure rate or diastolic oscillations of the valve. The amplitude of excursion of the anterior mitral cusp was normal in patients with an Austin Flint murmur and reduced in patients with organic mitral stenosis.

It is suggested that the Austin Flint murmur may have two origins. It may be associated with premature mitral valve closure when a short diastolic filling time and a high left atrial pressure are accompanied by turbulent blood flow through the mitral valve, a situation similar to that in mitral stenosis. In patients without heart failure the Austin Flint murmur seems to be associated with rapid diastolic oscillations of the anterior cusp which when present are a diagnostic feature on the echocardiogram of patients with lone aortic regurgitation and which are not seen when there is associated mitral stenosis.

Echocardiograms of the mitral valve can therefore be used to differentiate organic from functional mitral diastolic murmurs in patients with aortic regurgitation. The method is very reliable.

When heart failure complicates aortic regurgitation echocardiography displays its mechanism. Apart from associated mitral stenosis, aortic regurgitation of recent onset (or exacerbation) can readily be distinguished from chronic aortic regurgitation with heart failure. The latter is associated with delayed mitral valve opening and with premature closure which is slight and does not precede the P wave of the electrocardiogram.

In acute aortic regurgitation the echocardiogram shows the singular combination of delayed diastolic opening together with gross prematurity of closure which often precedes the P wave. The resulting spectacular curtailment of the period when the mitral valve is open has precise diagnostic value. These features also are very reliable.

In 1862 Austin Flint described two patients with severe aortic regurgitation in whom he had heard a mitral presystolic murmur, but who at necropsy had no evidence of mitral valve disease. Just as in Austin Flint's time, it is still sometimes difficult to decide clinically the origin of a delayed mitral diastolic murmur in a patient with severe aortic regurgitation.

Received 25 August 1970.

¹ Part of this work was presented to the British Cardiac Society on 10 April 1969.

² Dr. Pridie's work is supported by the British Heart Foundation.

An opening snap is useful if present, but atrial fibrillation, left atrial enlargement, and pulmonary venous congestion can be indicators either of left ventricular failure in aortic regurgitation or of associated mitral stenosis. It is in such patients that clinical uncertainty usually arises.

Edler and Hertz in 1954 showed that the movements of the mitral valve could be demonstrated by using ultrasound, and that the mitral echocardiogram from a patient with mitral stenosis differs from that obtained

from a normal person. Other workers have confirmed these findings (Effert *et al.*, 1964; Segal *et al.*, 1966; Wharton and Lopez Bescos, 1970). It seemed that echocardiography might be a suitable way to differentiate the Austin Flint murmur from the bruit of organic mitral stenosis in those cases where doubt exists and that it might even obviate the need for diagnostic cardiac catheterization.

Material

Ultrasonic scans of the mitral valve were made on patients with severe aortic regurgitation who were being assessed with a view to valve replacement. In 75 of these patients there were adequate haemodynamic or surgical data, or both, for assessment of the state of the mitral valve. Their ultrasound records have been reviewed and form the basis of this paper.

Method

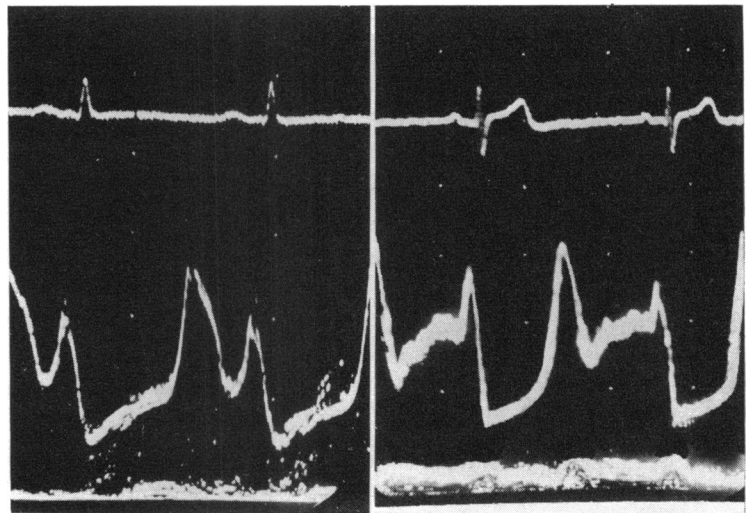
The equipment and technique used for ultrasound recording in our laboratory were the same as we have previously described (Pridie and Turnbull, 1968). Ultrasonic waves are produced by applying pulses of electricity from a source¹ to a transducer on the praecordium. Some of these waves are reflected back from the anterior cusp of the mitral valve to the transducer again and set up secondary electric currents which deflect the spot of an oscilloscope, the movement of which is recorded either directly using a Polaroid camera or by feeding the pulse through a conventional strip recorder.²

With the patient supine, upward movements of the anterior cusp of the mitral valve occur during valve opening and downward movements denote closure. The patterns of movement which are recorded from normal mitral valves are seen in Fig. 1. Mitral valve closure occurs at the beginning of ventricular systole, immediately after the QRS complex of the electrocardiogram which is recorded simultaneously ('systolic closure'). The cusp remains in the fully closed position until early in diastole, after completion of isovolumic relaxation, when it opens abruptly. The valve opens when the left ventricular pressure has fallen below the left atrial pressure. With valve opening the pressures equalize and thereafter fall together. With completion of rapid filling the anterior cusp returns to the semiclosed position ('diastolic closure'). A second mitral opening movement follows, and if the PR interval is long the valve returns to the semiclosed position before being slammed shut by the onset of ventricular systole. If the PR interval is less than 0.20 sec. ventricular systole closes the valve from the fully open position initiated by atrial contraction.

In mitral stenosis pressure equalization between the atrium and ventricle does not occur when the valve opens, so blood flows continuously from atrium to ventricle across a pressure gradient

¹ Eskoline 20 manufactured by Smith Kline Instruments.

² Mingograph manufactured by Elema-Schönander.



(a)

(b)

FIG. 1 Normal mitral echocardiograms.

(a) Heart rate 100/min. Diastolic closure rate 90 mm./sec. (b) Heart rate 50/min. Diastolic closure rate 120 mm./sec. At this heart rate the long period of diastasis is noteworthy. In between diastolic closure and atrial systole the mitral valve oscillates slowly in the semi-closed position after completion of ventricular rapid-filling. These slow oscillations are seen only during this period of the cycle and are to be distinguished from the much faster oscillations which occur during the rapid filling phase as well as later in diastole in some patients with aortic regurgitation (Fig. 3a). In this and subsequent figures vertical spots are 1 cm. apart and horizontal spots are $\frac{1}{2}$ sec. apart.

which in severe mitral stenosis persists throughout diastole; the ventricle is distended only slowly, and so the anterior cusp is only slowly pulled backwards (Fig. 2). In the normal subject the rate of diastolic closure is between 70 and 120 mm./sec. In mitral stenosis the slope is flatter and lies between zero and 20 mm./sec., being flatter and slower in severe stenosis than in mild stenosis. This slowing of the diastolic closure rate has been shown to be proportional to the reduction in the mitral valve orifice (Segal, Likoff, and Kingsley, 1966; Wharton and Lopez Bescos, 1970).

Results

Lone aortic regurgitation (55 patients)
The echocardiograms recorded from the patients with aortic regurgitation and in whom mitral stenosis was subsequently excluded showed up to four differences from the normal (Fig. 3):

(1) The valve often showed characteristic fast fine repetitive oscillations (13 patients).

(2) The diastolic closure rate of the mitral valve was more rapid than in the normal, and in 35 cases without mitral valve disease it was over 120 mm./sec.

(3) Valve closure sometimes occurred before the QRS complex of the electrocardiogram (29 patients).

(4) The valve tended to be slightly thickened (4 patients). The frequencies with which these findings occurred are summarized in the Table.

Aortic regurgitation with mitral valve disease Patients with a diastolic murmur due to organic mitral stenosis had a diastolic closure rate of less than 50 mm./sec., an abnormally wide echo, and diminished amplitude of movement. Two patients with less severe mitral stenosis and aortic regurgitation showed premature closure, but in the other 18 patients closure was normal or delayed.

The closure rate tended to be faster than in patients with lone mitral stenosis of comparable severity. In spite of this, all patients with associated mitral stenosis had a closure rate of less than 50 mm./sec.

This compares with patients with lone mitral stenosis and a valve area of less than 1.1 cm.² who usually have a closure rate of under 15 mm./sec. and most have rates under 10 mm./sec.

Aortic regurgitation with an Austin Flint murmur Nineteen patients with a delayed apical diastolic murmur and no other clinical or haemodynamic evidence of mitral stenosis were assumed to have Austin Flint murmurs. These patients all showed a closure rate above 120 mm./sec. and a fully mobile mitral valve. Nine of them showed diastolic fluttering of the valve and eleven had premature closure. All of these patients showed either premature closure or diastolic oscillations (Table).

Discussion

Diastolic closure rate Diastolic closure of the mitral valve to the midway position, which is seen on the normal echocardiogram just after full opening in early diastole, is associated with rapid distension of the ventricle during filling with tensing of the papillary muscles and chordae tendineae. In aortic reflux blood enters the ventricle simultaneously from the atrium and from the aorta through the leaking valve. Left ventricular distension is therefore faster as well as greater than normal, and the diastolic closure movement of the mitral cusp is likewise faster. It follows that in the presence of aortic regurgitation the rate of diastolic

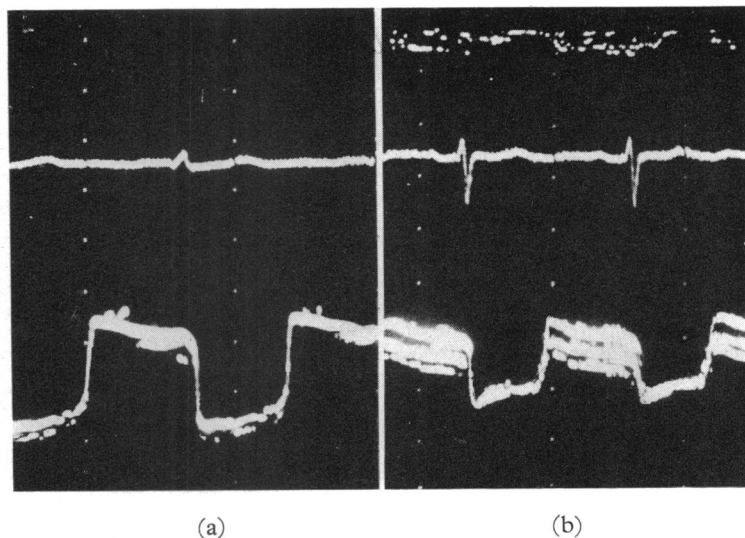


FIG. 2 *Echocardiograms from patients with lone mitral stenosis and sinus rhythm.* (a) *Thin mobile valve. The diastolic closure rate is under 10 mm./sec., but the amplitude of movement is nearly 3 cm.* (b) *Thick calcified and immobile valve. The diastolic closure rate is under 10 mm./sec. and the amplitude of movement is less than 2 cm. The echoes from the calcified valve are multiple.*

closure of the stenotic mitral valve is also relatively faster and the closure rate is no longer proportional to the mitral valve area as it is in lone mitral stenosis (Segal *et al.*, 1966; Wharton and Lopez Bescos, 1970). This acceleration of the diastolic mitral closure rate occurs, therefore, in patients with aortic regurgitation and mitral stenosis as well as in those with lone aortic reflux and a normal mitral valve, but when there is mitral stenosis the diastolic closure rate still remains well below the rate in aortic regurgitation without mitral stenosis. If the mitral valve is rigid and calcified, diastolic closure may still be virtually absent as it is in lone mitral stenosis with this sort of valve (Fig. 4a).

Thickening of echo The slight thickening of the echo obtained from patients without mitral stenosis is presumably a reflection of the mild sclerosis which the regurgitant aortic jet usually produces on the anterior cusp of the mitral valve. Cusp thickening is difficult to quantitate, because the velocity of ultrasound in the dense fibrous tissue of a thickened cusp is less than in blood and soft tissues. Consequently valve thickening tends to be exaggerated. However, it is not difficult to differentiate between the slight widening of

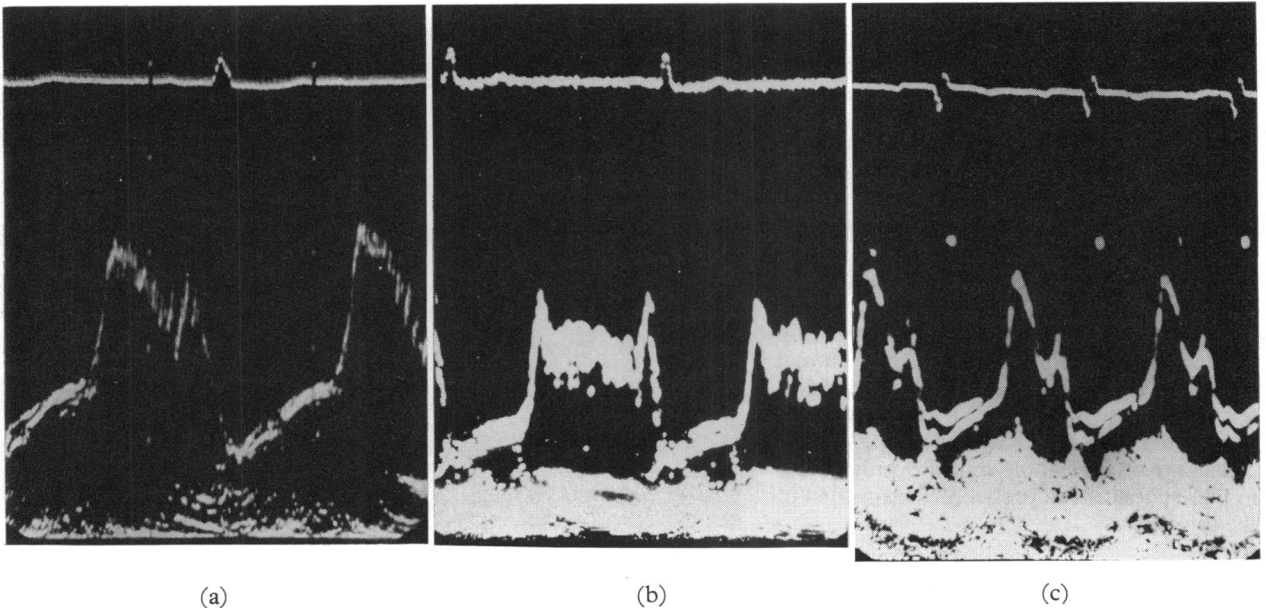


FIG. 3 Echocardiograms from patients with lone aortic regurgitation. (a) Chronic lone aortic regurgitation of rheumatic origin. Soft Austin Flint murmur. Left ventricular end-diastolic pressure 15 mm. Hg. The echocardiogram shows a diastolic closure rate of 60 mm./sec., a thin valve with fast oscillations and normal timing of mitral valve closure. All murmurs disappeared and the mitral echocardiogram became normal postoperatively. (b) Syphilitic aortic regurgitation. No heart failure. Austin Flint murmur. Mitral echocardiogram shows wide amplitude, fast oscillations. Normal reopening after atrial contraction and normal timing of systolic closure denotes a normal left ventricular end-diastolic pressure (confirmed in Fig. 6). (c) Chronic severe aortic regurgitation after repair of ventricular septal defect. There was no Austin Flint murmur. The left ventricular end-diastolic pressure was 17 mm. Hg. The mitral echocardiogram shows no diastolic oscillations, diastolic closure rate over 100 mm./sec., slightly premature mitral valve closure after normal reopening after atrial contraction associated with a prolonged PR interval (0.24 sec.).

TABLE Ultrasonic findings from the mitral valve in 75 patients with aortic regurgitation

	Total	Diastolic oscillations	Premature closure		Thickening	Diastolic closure rate (mm./sec.)			
			+	++		1-15	16-50	51-100	100+
No mid-diastolic murmur	36	4	14	2	3	0	0	10	24†
Mitral stenosis	20	0	2	0	20	9	11	0	0
Austin Flint*	19	9	5	6	1	0	0	0	11†
Total	75	13	21	8	24	9	11	10	35

* Austin Flint = Apical mid-diastolic murmur in the absence of mitral stenosis.
 † Ten patients, two without a mid-diastolic murmur and eight with an Austin Flint murmur, had heart rates so rapid that ventricular systole occurred before any diastolic closure of the valve had been recorded. All these patients had premature closure.
 Premature closure +: Mitral valve closure which occurred before the qRS but after the P wave. It was often associated with a long PR interval or a slow heart rate.
 Premature closure ++: Mitral valve closure which occurred before the P wave. It was found only in patients with aortic regurgitation of acute onset and it never coexisted with mitral stenosis.

the echo received from a normal valve in aortic regurgitation and the very considerable thickening or calcification seen in patients with organic mitral stenosis. Thickened stenotic mitral valve echoes are shown in Fig. 4 for comparison with the echoes from normal mitral valves in aortic regurgitation shown in Fig. 3. It is of interest that no patient in this group with aortic regurgitation had significant mitral stenosis without either valve thickening or restriction of movement, though in lone mitral valve disease 'pure stenosis' is not uncommonly seen without widening of the echo and with little diminution in the normal amplitude of excursion. This perhaps reflects the greater intensity of the rheumatic damage in patients with multivalve disease. The inconsistency of an audible mitral opening snap in these patients can probably be explained in the same way.

Premature mitral valve closure In 1886 Austin Flint had already deduced that premature closure of the mitral valve could occur in severe aortic regurgitation. It has since been demonstrated from pressure recordings which showed the left ventricular pressure rising to exceed the left atrial pressure during diastole (Rees *et al.*, 1964; Wright, Toscano-Barboza, and Brandenburg, 1956; Colvez *et al.*, 1959; Dodge, Sandler, and Evans, 1960; Kelly, Morrow, and Braunwald, 1960; Wigle and Labrosse, 1965). It is of interest to note that though Austin Flint realized that the mitral valve could close early in aortic regurgitation he described the apical diastolic murmur as presystolic. If the mitral valve closed in presystole the murmur would not occur later than mid-diastole, which is when it is usually heard in these patients.

Premature mitral valve closure was recognized on the echocardiogram when the systolic closure movement occurred before the Q wave of the electrocardiogram.

In 21 patients the mitral valve closed only slightly prematurely, up to 0.05 sec. before the Q wave and after the P wave in patients in sinus rhythm. In such patients atrial contraction had reopened the valve in the usual way, and premature closure occurred during atrial relaxation before the onset of ventricular systole. It was thus favoured by the presence of a long PR interval (Fig. 3c).

In eight patients the mitral valve closed very prematurely, up to 0.2 sec. before the Q wave (see Fig. 8a). All these eight patients had aortic regurgitation of acute onset. All were in sinus rhythm and none had mitral stenosis.

In chronic aortic regurgitation the leak from aorta to left ventricle is never 'free', though it

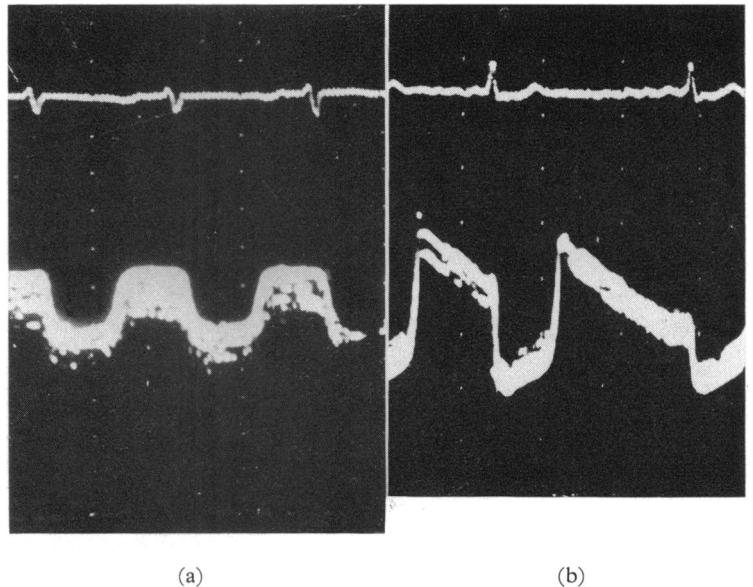
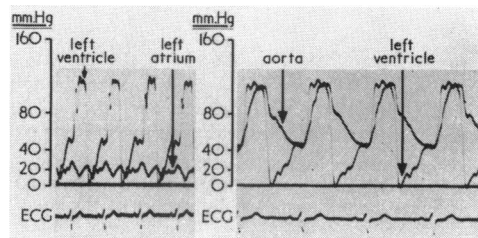


FIG. 4 *Mitral echocardiograms in severe chronic aortic regurgitation with mitral stenosis. (a) With severe calcific mitral stenosis and sinus rhythm. The mitral stenosis was clinically silent, but was recognized on the echocardiogram and confirmed on haemodynamic study and at operation. Diastolic closure rate zero; amplitude of excursion under 2 cm. Multiple echoes and delayed mitral closure. No oscillations. (b) With moderate mitral stenosis and atrial fibrillation. Diastolic closure rate 20 mm./sec., amplitude over 2 cm., normal timing of mitral valve closure. No oscillations.*

FIG. 5 *Taken from Wigle and Labrosse (1965)¹. Shows free aortic regurgitation of acute onset. The equilibration of aortic and left ventricular diastolic pressures at 45 mm. Hg can be compared with the usual preservation of a gradient in chronic subtotal regurgitation (Fig. 6). The left ventricular diastolic pressure quickly exceeds the left atrial pressure and ensures premature mitral valve closure which must occur before atrial contraction.*



¹ By kind permission of the authors and of the American Heart Association, Inc.

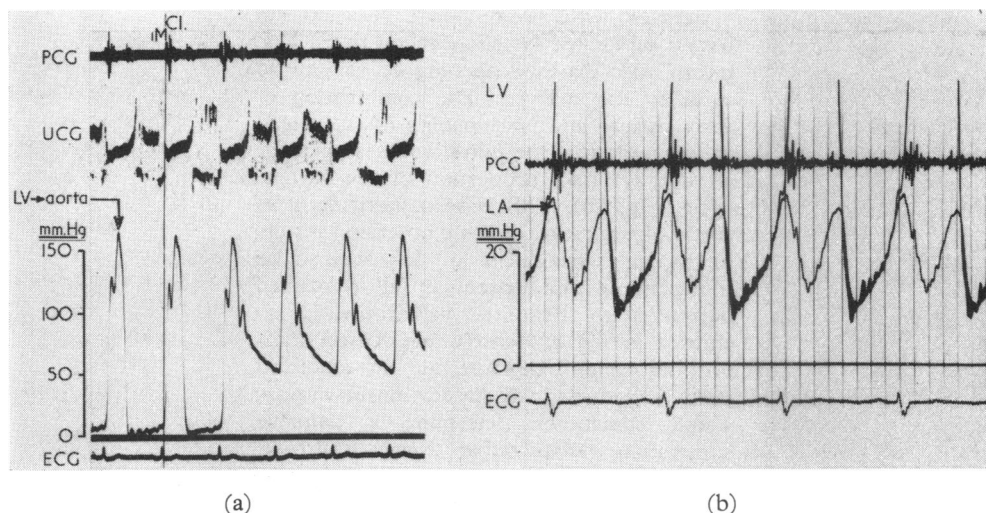


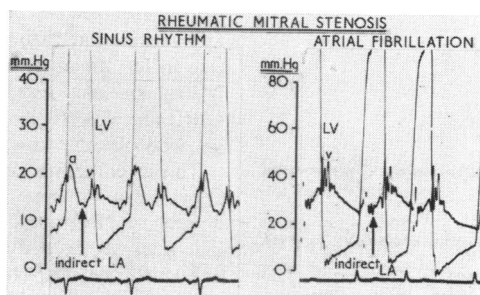
FIG. 6 (a) Phonocardiogram (PCG), mitral echocardiogram (UCG), and pressure record on withdrawal of catheter from left ventricle (LV) to aorta in the patients with severe chronic aortic regurgitation whose echocardiogram is shown in Fig. 3b. The timing of mitral valve closure was normal and a vertical line has been drawn through the left ventricular end-diastolic pressure, mitral closure (shown on the UCG), and mitral closure (shown on the PCG). (b) Simultaneous direct left atrial and left ventricular pressures from a patient with chronic aortic regurgitation and left ventricular failure. There was an Austin Flint murmur. The mitral echocardiogram showed diastolic oscillations and only slightly premature mitral valve closure following the P waves. The high left ventricular diastolic pressure is mirrored by an equally high left atrial pressure and the effect of left atrial contraction wave is clearly shown by the a wave in the left ventricular pressure pulse.

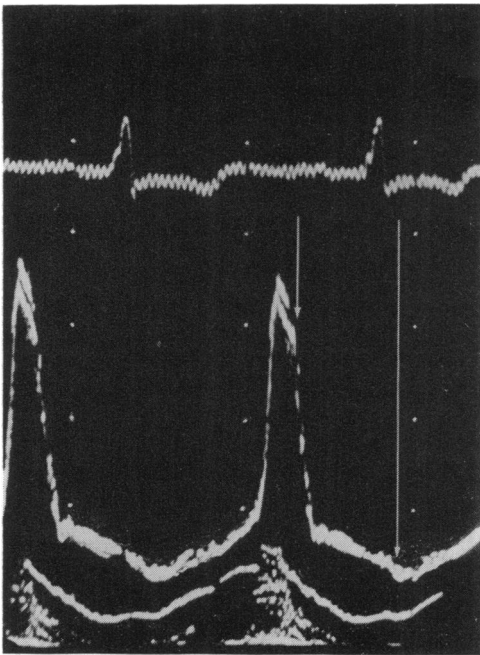
is often loosely described as such. This is clearly shown by the usual maintenance of a diastolic aortic/left ventricular gradient (Fig. 6). Slowing of the heart rate in such patients may permit equilibration of these pressures at end-diastole. A fast heart rate is therefore less likely to be associated with premature closure, which may appear when the heart rates slow down.

Distinction between acute aortic regurgitation and chronic aortic regurgitation is important. In acute aortic regurgitation as is seen after perforation of a cusp in infective endocarditis, or after sudden expansion of the aortic valve ring in dissection, the haemodynamic situation is quite different. Firstly the leak is often total with rapid equilibration of the aortic and left ventricular pressures. Even if the leak is less complete the left ventricle is small and its compliance early becomes exceeded as it rapidly distends after the onset of diastole. The steeply rising left ventricular pressure quickly exceeds the left atrial pressure and slams shut the mitral valve almost as soon as it has opened. Fig. 5, taken with permission from the paper by Wigle and Labrosse (1965), shows these pressure re-

lationships in a patient with aortic regurgitation of acute onset that was indeed 'free'. Under these haemodynamic circumstances premature closure of the mitral valve is inevitable and it can be gross (see Fig. 8a). The mitral valve may close in mid-diastole, and it is not reopened by atrial contraction which does not raise the left atrial pressure above that in the ventricle.

FIG. 7 Left ventricular and indirect left atrial pressures in tight mitral stenosis. Persistence of a gradient between left atrial and left ventricular pressures at the end of diastole will slightly delay mitral valve closure.

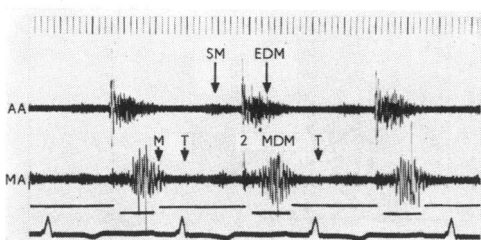




(a)

FIG. 8 *Severe aortic regurgitation of acute onset. (a) Mitral echocardiogram shows extremely premature mitral valve closure (first arrow). Note the extra kick imparted to the closed valve at the onset of ventricular systole (second arrow). Mitral valve opening is delayed owing to left ventricular failure. The gross curtailment of diastolic filling time is noteworthy. (b) Phonocardiogram from the same patient shows short loud early diastolic murmur (EDM) and short extremely loud mid-diastolic murmur (MDM) which terminates with a soft premature mitral closure sound (M). Tricuspid valve closure (T) is shown in the normal position of atrioventricular valve closure a full 0.16 sec. later. The broken horizontal lines indicate the periods when the mitral valve is closed (long line) and open (short line).*

(b)



Patients with severe aortic regurgitation have a prolonged systolic ejection time. This means that diastolic opening of the mitral valve is also delayed. The combination of early closure and late opening of the mitral valve means that the mitral valve is open for an unduly small proportion of the cardiac cycle (Fig. 8b). This is seen particularly in aortic regurgitation of acute onset and results in serious curtailment of left ventricular filling time with a consequent fall in forward output. With the mitral valve open for so short a period of diastole any Austin Flint murmur can only be short, and indeed a third heart sound and displaced mitral closure sound sometimes determine a palpable summation gallop rather than a murmur. Diastolic oscillations of the valve are not seen. The mid-diastolic murmur probably only occurs during antegrade left ventricular filling, and in cases like the one illustrated in Fig. 8 this period is so curtailed that the murmur provides less of a problem in differentiation from the murmur of organic mitral stenosis than it does in chronic regurgitation.

In severe aortic regurgitation associated with mitral stenosis, mitral valve closure was premature in only 2 of the 20 patients. The slightly premature closure of the mitral valve seen so commonly in lone chronic aortic regurgitation contrasts with the delayed closure which occurs in severe mitral stenosis when the mitral valve gradient persists until after the start of mechanical systole. This late closure in mitral stenosis can be recognized on the ultrasonic trace as well as phonocardiographically and from pressure recordings (Fig. 7). Four of our patients with aortic regurgitation and mitral stenosis showed delayed closure. The timing of mitral valve closure in the combined disease depends mainly on the severity of the mitral stenosis, but if the left ventricular pressure rises steeply in end-diastole then premature closure may still occur though at the expense of a reduction in forward output if mitral stenosis is severe. Clearly, acute aortic regurgitation is incompatible with life in the presence of severe mitral stenosis because of the curtailment of left ventricular filling time or the extravagant rise in left atrial pressure which would result. Mitral stenosis was absent in our 8 patients with acute aortic regurgitation, all of whom showed obvious premature closure.

In patients with chronic aortic regurgitation shortening of the diastolic filling time is absent or slight, so the murmur is long and can give rise to a diagnostic dilemma. Mitral echocardiograms from these patients may show diastolic oscillations (Fig. 9). Obvious

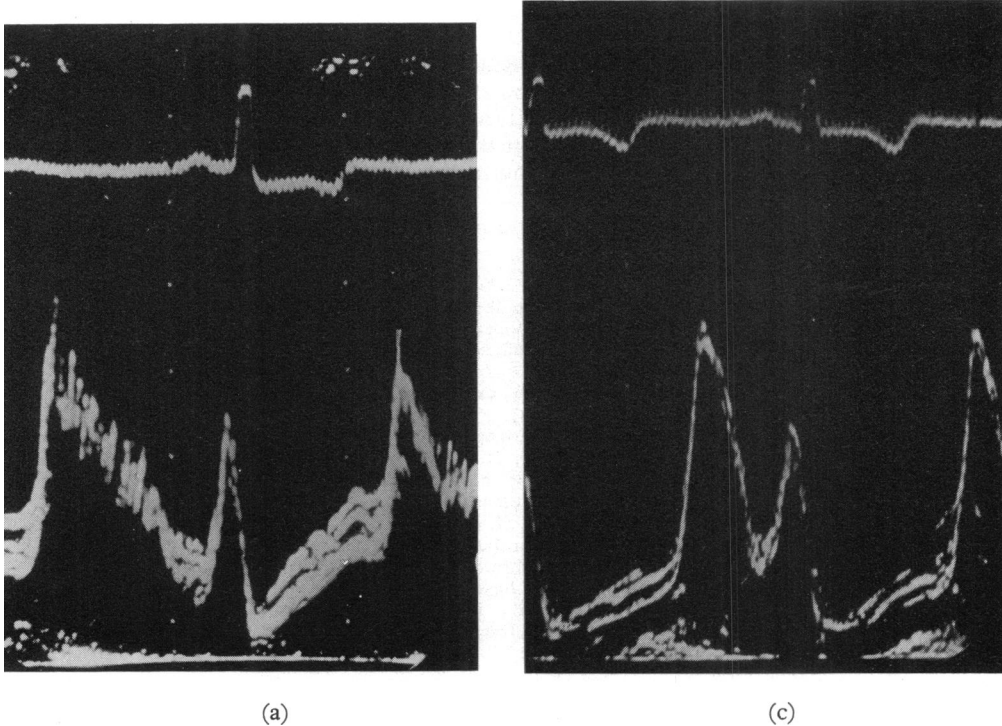
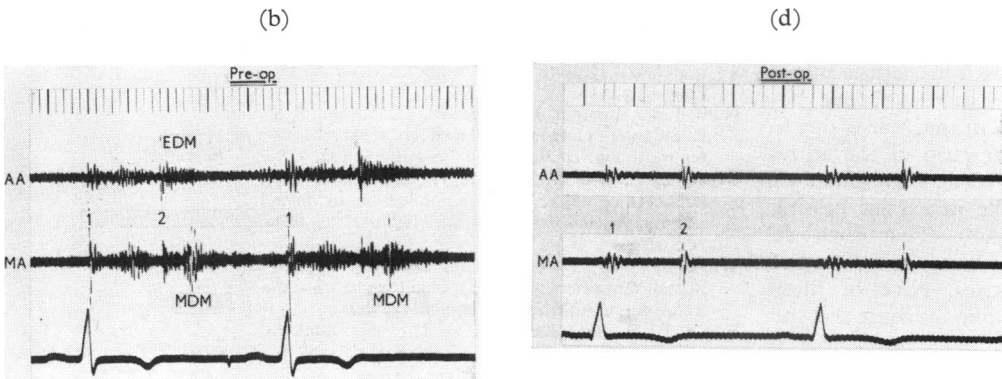


FIG. 9 Mitral echocardiogram with phonocardiogram from a patient with chronic rheumatic aortic regurgitation and an Austin Flint murmur before and after homograft replacement of the valve. (a) The mitral echocardiogram is normal apart from florid fast oscillations in diastole. (b) The phonocardiogram shows the Austin Flint murmur. (c and d) The mitral echocardiogram and phonocardiogram are normal after aortic valve replacement.



premature closure is not seen in such patients even in the presence of 'left ventricular failure' (Fig. 6b). In such patients pulmonary oedema or chronic venous congestion relates either to mitral valve disease, the onset of mitral regurgitation, or loss of left ventricular contractile force. The mitral echocardiogram does not distinguish such patients from those with chronic aortic regurgitation who have no evidence of left ventricular failure, except

possibly by a faster diastolic closure rate related to the high left atrial filling pressure on opening of the mitral valve. When heart failure results from acute aortic regurgitation the echocardiogram is entirely different. It is specific and it enables such patients to be recognized instantly and their failure distinguished from myocardial failure. Such patients need urgent aortic valve replacement (Wise *et al.*, 1970).

Diastolic oscillations of mitral valve in aortic regurgitation Rapid oscillations of the mitral valve in diastole were seen in 13 patients in this series (Fig. 9). All the patients with an Austin Flint murmur either showed this fluttering or had premature mitral valve closure. Oscillations were also seen in 4 patients without an Austin Flint murmur.

There was no correlation between the presence of the oscillations and the severity of the reflux. They have been noticed in a number of patients with moderate aortic regurgitation who were not included in this series and were very obvious in one patient with mild aortic regurgitation who had a very loud delayed mitral diastolic murmur. Organic mitral valve disease was subsequently excluded in this patient in whom an aortogram showed a fine jet of regurgitated blood directed posteriorly to strike and outline the anterior cusp of the mitral valve.

Diastolic oscillations were not seen in the presence of mitral stenosis. They were absent also in the patients with acute aortic regurgitation and premature mitral valve closure in whom the mitral valve was hardly open for long enough for oscillations to be visible (Fig. 8a).

It seems likely that diastolic fluttering of the mitral valve provides one cause but not the only cause of the Austin Flint murmur.

Austin Flint (1886) considered that the murmur he had described was due to atrial contraction while the mitral 'curtains' were closed. However, this has never been a fully acceptable hypothesis, and in any case would only apply to patients with premature mitral valve closure. Most cardiologists have believed that the Austin Flint murmur is due to fluttering of the anterior cusp of the mitral valve produced by the aortic regurgitant jet passing in front and the mitral jet passing behind (Da Costa, 1908). That such an oscillation may occur has been shown in 13 of the patients in this series. Nine of these patients had a mid-diastolic murmur and the echocardiogram of one is illustrated in Fig. 9 together with a phonocardiogram. Post-operatively the mitral valve oscillations disappeared and so did the mid-diastolic murmur. Other workers have considered (Lochaya, Igarashi, and Shaffer, 1967) that the Austin Flint murmur is due to diastolic mitral reflux which has been described during left ventricu-

lar angiography in patients with aortic regurgitation. Diastolic reflux was not recognized though carefully sought in our patients with Austin Flint murmurs. Though sometimes seen it was inconstant from diastole to diastole and bore no relation to the presence or absence of an Austin Flint murmur.

References

- Colvez, P., Alhomme, P., Samson, M., and Guedon, J. (1959). La pression de remplissage du ventricule gauche dans les grandes insuffisances aortiques. Ses relations avec l'allongement de la conduction auriculoventriculaire. *Archives des Maladies du Cœur et des Vaisseaux*, **52**, 1369.
- Da Costa, J. C. (1908). *Principles and Practice of Physical Diagnosis*, p. 354. Saunders, Philadelphia.
- Dodge, H. T., Sandler, H., and Evans, T. (1960). Observations on the hemodynamics of severe aortic insufficiency in man. *Circulation*, **22**, 741.
- Edler, I., and Hertz, C. H. (1954). The use of ultrasonic reflectoscope for the continuous recording of the movements of heart walls. *Kungliga Fysiografiska Sällskapet i Lund Förhandlingar*, **24**, 40.
- Effert, S., Bleifeld, W., Deupmann, F. J., and Karitsiotis, J. (1964). Diagnostic value of ultrasonic cardiography. *British Journal of Radiology*, **37**, 920.
- Flint, A. (1862). On cardiac murmurs. *American Journal of the Medical Sciences*, **44**, 29.
- (1886). The mitral cardiac murmurs. *American Journal of the Medical Sciences*, **91**, 27.
- Kelly, E. R., Morrow, A. G., and Braunwald, E. (1960). Catheterization of the left side of the heart. A key to the solution of some perplexing problems in cardiovascular diagnosis and management. *New England Journal of Medicine*, **262**, 162.
- Lochaya, S., Igarashi, M., and Shaffer, A. B. (1967). Late diastolic mitral regurgitation secondary to aortic regurgitation: its relationship to the Austin Flint murmur. *American Heart Journal*, **74**, 161.
- Pridie, R. B., and Turnbull, T. A. (1968). Diagnosis of pericardial effusion by ultrasound. *British Medical Journal*, **3**, 356.
- Rees, J. R., Epstein, E. J., Criley, J. M., and Ross, R. S. (1964). Haemodynamic effects of severe aortic regurgitation. *British Heart Journal*, **26**, 412.
- Segal, B. L., Likoff, W., and Kingsley, B. (1966). Echocardiography. Clinical application in mitral stenosis. *Journal of the American Medical Association*, **195**, 161.
- Wharton, C. F. P., and Lopez Bescos, L. (1970). Mitral movement: a study using an ultrasound technique. *British Heart Journal*, **32**, 344.
- Wigle, E. D., and Labrosse, C. J. (1965). Sudden, severe aortic insufficiency. *Circulation*, **32**, 708.
- Wise, J. R., Hallidie-Smith, K. A., Oakley, C. M., Bentall, H. H., and Goodwin, J. F. (1970). Urgent aortic valve replacement for acute aortic regurgitation in infective endocarditis. *Lancet*. In the press.
- Wright, J. L., Toscano-Barboza, E., and Brandenburg, R. O. (1956). Left ventricular and aortic pressure pulses in aortic valvular disease. *Proceedings of the Staff Meetings of the Mayo Clinic*, **31**, 120.