

Pacemaker therapy in sino-atrial block complicated by paroxysmal tachycardia

R. Rokseth, L. Hatle, D. Gedde-Dahl, and P. O. Foss

From Section of Cardiology, Medical Department, Central Hospital, Trondheim; Medical Department, Narvik Hospital, Narvik; and Medical Department, Innherred Hospital, Levanger, Norway

Pacemakers were implanted in 10 of 14 patients with dizziness and syncopal episodes of long duration, due to sino-atrial block. Paroxysmal supraventricular tachycardia, notably atrial fibrillation, had occurred in 6 patients. Medical treatment was unsatisfactory in 3 of these and pacemaker therapy was given. This abolished both syncope and paroxysmal tachycardia. Sino-atrial block and supraventricular tachycardia are probably not only different expressions of the same pathological process; a functional relation seems likely.

Sino-atrial block may, on rare occasions, cause syncopal episodes which can be prevented by pacemaker therapy. Another complication is paroxysmal, rapid, supraventricular rhythms, notably atrial fibrillation. Treatment is then difficult. Cardio-accelerator drugs, such as atropine or isoprenaline, may precipitate tachycardia, while antiarrhythmic agents, such as quinidine, digitalis, or propranolol, can accentuate bradycardia and cause syncope. A logical approach seems to be the combination of pacemaker to prevent bradycardia, and antiarrhythmic drugs in sufficient doses to prevent tachycardia. Successful use of the pacemaker was reported by Cohen, Kahn, and Donoso (1967) in a patient with chronic sinus and nodal bradycardia and paroxysmal atrial flutter.

The purpose of this paper is to show that sino-atrial block can quite often be associated with paroxysmal atrial fibrillation, and that pacemaker therapy may prevent both syncope and fibrillation.

Patients and methods

During the past 4 years sino-atrial block was the main diagnosis in 14 patients admitted to the Section of Cardiology, Medical Department, Central Hospital, Trondheim. Neither patients with recent myocardial infarction nor those whose symptomless sino-atrial block was discovered accidentally, were included. A summary of clinical data is shown in the Table. Ages varied from 47 to 76 years. One patient had a history

of moderate angina pectoris. Otherwise, none showed any underlying cause for the block such as hypertension, valvular, coronary, thyrotoxic, syphilitic, or pulmonary heart disease. It is noted, however, that 3 patients gave a history of rheumatic fever, and 2 of diphtheria.

Before symptoms appeared none of the patients had taken drugs, such as digitalis or quinidine, which might cause arrhythmia. Hyperkalaemia was not seen. The age at which symptoms began varied from 43 to 71 years and the duration of symptoms from 6 months to 17 years. Twelve patients had repeated attacks of dizziness and/or syncope. Six of these had, in addition, episodes of rapid, irregular heart beats lasting a few minutes to a few hours. A relation between syncope and tachycardia could only be established in one (Case 13). A few patients complained of moderate dyspnoea on exertion and one (Case 11) had ankle oedema. Otherwise, no signs of congestive heart failure were found, but cardiomegaly was sometimes shown on x-ray, all four chambers being equally enlarged.

Frequent electrocardiograms were made in all patients. Monitoring devices have been available since early 1967. In the Table, 'S-A block' indicates the appearance of a normal PQRS after a pause of about twice the normal length. 'Sinus arrest' arbitrarily indicates a somewhat longer pause, up to several seconds, with a nodal escape beat at the end. All patients had bradycardia, the basic heart rate being less than 60 a minute. Electrocardiograms taken in the 6 patients with paroxysmal tachycardia showed ventricular rates varying from 140 to 180 during paroxysms. One patient had possible nodal tachycardia, another had frequent supraventricular extrasystoles, and 4 had atrial fibrillation.

TABLE Clinical data in 14 patients with sino-atrial (S-A) block or sinus arrest

Case No.	Age and sex	Previous disease	Symptoms	Duration of symptoms (yr.)	Electrocardiogram	Heart x-ray (ml./m. ²)†	Attempted medical therapy	Pacemaker
1	73 F	Angina pectoris	Syncope; paroxysmal tachycardia	2	S-A block; atrial fibrillation	480		
2	65 F	Rheumatic fever	Paroxysmal tachycardia	½	S-A block; AV block; atrial extrasystoles	400	Digitalis	
3	67 F	Rheumatic fever	Syncope; paroxysmal tachycardia	2	S-A block; sinus arrest; atrial fibrillation	495	Isoprenaline	
4	50 F		Attacks of dizziness	3	Sinus arrest	380		
5	47 F	Diphtheria	Syncope	3	S-A block	350 (320)	Isoprenaline; ephedrine	5.7.64
6	79 F		Syncope; paroxysmal tachycardia	10	S-A block; sinus arrest	680 (620)	Isoprenaline	15.12.66
7	55 M		Syncope	24	S-A block	570 (520)	Isoprenaline	27.6.66
8*	53 M	Diphtheria	Syncope; paroxysmal tachycardia	1	S-A block; atrial fibrillation	440 (400)	Quinidine; isoprenaline	26.9.67
9	60 M		Syncope	½	S-A block; sinus arrest	435	Isoprenaline	16.1.68
10	59 F		Syncope	17	S-A block	480 (390)		11.3.68
11	60 F		Syncope; dyspnoea	7	Sinus arrest	625	Isoprenaline	22.4.68
12	34 M		Dyspnoea	1	S-A block	720 (720)		24.4.68
13*	61 M	Rheumatic fever	Dyspnoea; syncope; paroxysmal tachycardia	8	Sinus arrest; nodal tachycardia; AV block 1-2	620 (660)	Digitalis; quinidine; procainamide	6.5.68
14*	76 M		Syncope; paroxysmal tachycardia	7	Sinus arrest; atrial fibrillation	620 (520)	Atropine; ephedrine + digitoxin quinidine	23.8.68

* Cases 8, 13, and 14 are described in the text.

† Heart volumes after pacemaker implantation are given in parentheses.

A combination of extreme sinus bradycardia and AV block was found in one patient (Case 13 in Fig. 2).

Medical treatment included cardio-accelerator or antiarrhythmic drugs, or occasionally a combination of both. In Cases 1 and 4 symptoms were only rarely present and no specific therapy was given. The regular use of digitalis in Case 2 and of isoprenaline sublingually in Case 3 alleviated the symptoms. In the former, episodes of tachycardia became milder and less frequent, and in the latter the attacks of both syncope and tachycardia were practically abolished. In the remaining patients medical treatment, when attempted, either produced no improvement or caused a deterioration of symptoms. Paroxysmal tachycardia was not relieved, and syncopal episodes occurred more often after digitalis in Case 14 and after quinidine in Cases 8 and 13. The use of isoprenaline in Case 8 probably provoked paroxysmal atrial fibrillation (see Case report). Similarly a bout of atrial fibrillation occurred about 15 minutes after administration of 15 mg. of isoprenaline sublingually in one patient (Case 6) who had not had such attacks spontaneously.

Pacemaker therapy was given to 9 patients because of frequent syncopal episodes, sometimes associated with head injuries. A tenth patient was chosen because of tiredness and dyspnoea on exertion, gradual slowing of heart rate, and increasing cardiomegaly. Special problems were present in 3 of these patients because of the association of sino-atrial block with paroxysmal tachycardia, and case reports are given below.

Case reports

Case 8 A man of 53 had diphtheria when aged 31. He was admitted to hospital in November 1966. During the 5 to 6 weeks before entering hospital he had repeated syncope and also short episodes of rapid, irregular heart beats. Quinidine sulphate, 0.2 g. three times daily, was associated with increased tendency to syncope. Apart from a pulse rate of 48 and an electrocardiogram showing sino-atrial block or sinus arrest, clinical and laboratory findings were normal. Isoprenaline, 15 mg. sublingually five times daily, caused an increase of heart rate to 54-58. A week later, shortly after the morning dose, he complained of palpitations similar to

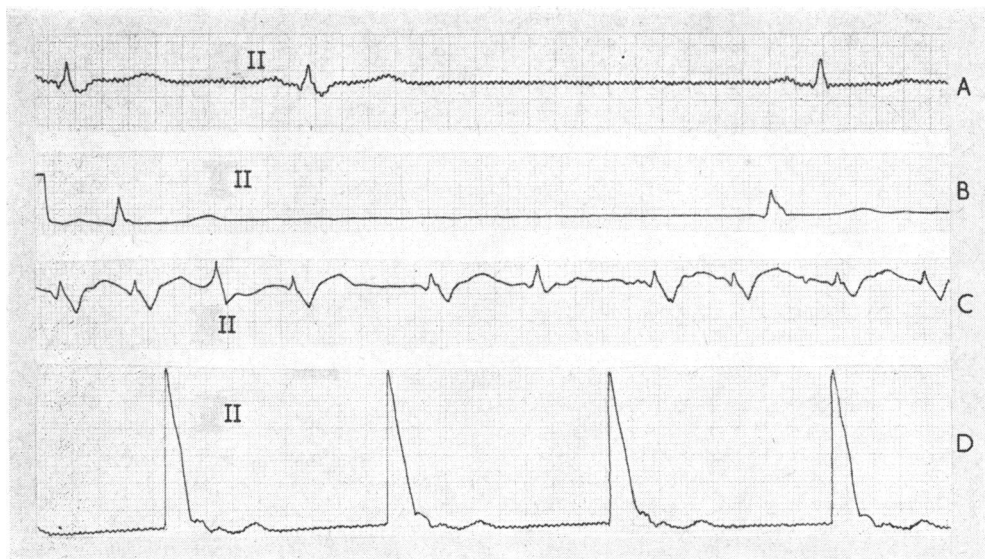


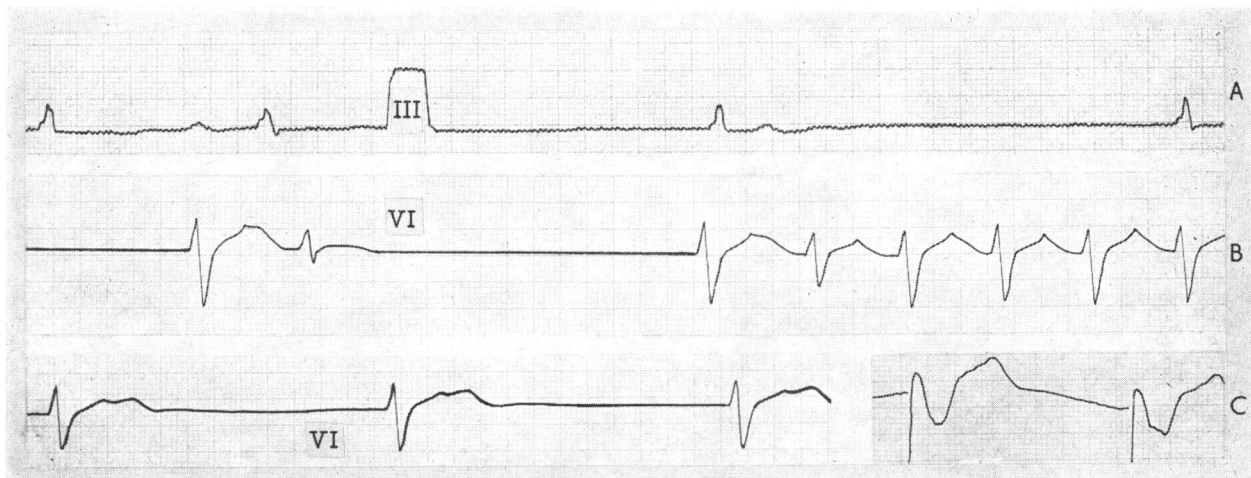
FIG. 1 Case 8. *Electrocardiogram shows sino-atrial block (A); sinus arrest with nodal escape beat (B); atrial fibrillation, ventricular rate 170 per min. (C); and pacemaker rhythm (D).*

previous attacks. An electrocardiogram showed atrial fibrillation (Fig. 1); reversal to sinus rhythm occurred spontaneously. He was discharged without medication and was fairly well apart from a few attacks of dizziness or palpitations. But in August 1967 his symptoms worsened. During one syncopal episode he suffered a head injury. He was readmitted to hospital and a 'fixed-rate'

pacemaker was implanted in September. For 19 months since then he has been working in a factory, has taken no drugs, and has had no episodes of dizziness, syncope, or palpitations.

Case 13 A man of 61 had rheumatic fever at the age of 20. During the past 7 years he had weekly to monthly attacks of supraventricular

FIG. 2 Case 13. *Electrocardiogram shows extreme sinus bradycardia, atrial rate 28 per min., AV block grade 2, and nodal escape (A); probable nodal beats and then supraventricular tachycardia which followed after sinus arrest for 6 seconds (B); nodal bradycardia, rate 46 per min. (C left); and pacemaker rhythm (C right).*



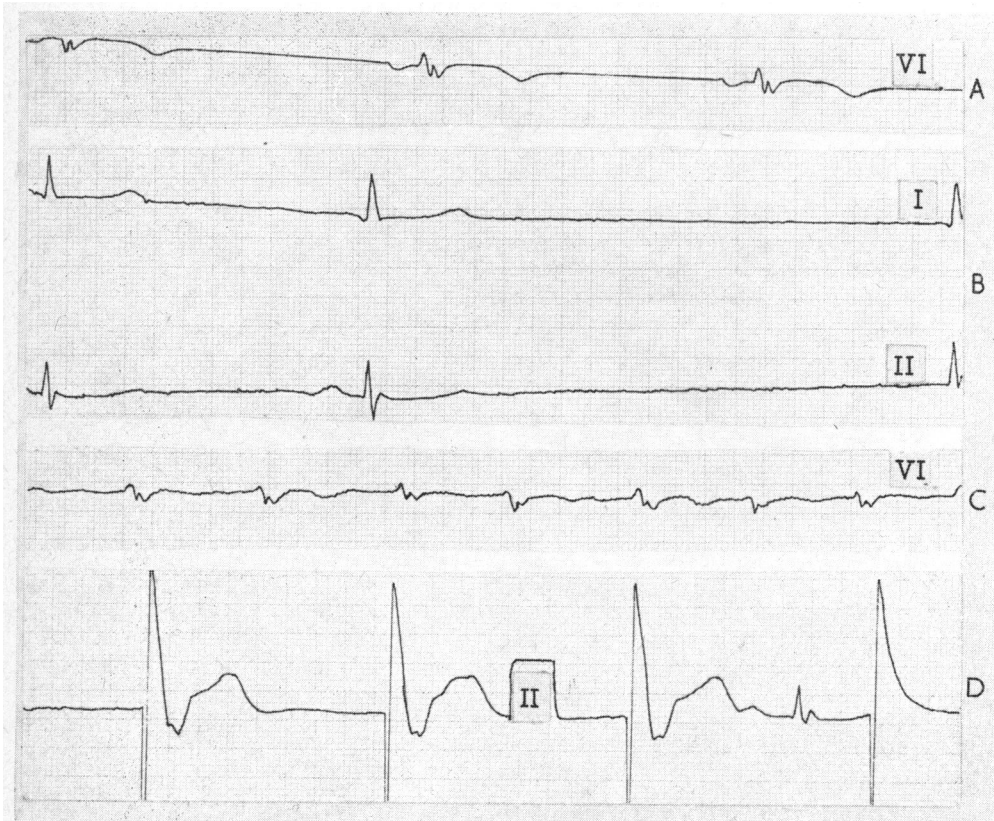
tachycardia. An electrocardiogram between attacks showed extreme sinus bradycardia with AV block grade 1 or 2, and sinus arrest with nodal escape or slow nodal rhythm. He experienced a tendency to syncope sometimes at the beginning, sometimes shortly after tachycardia, but most often syncope was unconnected with tachycardia. Quinidine sulphate, 0.2 g. 4 times, increased the tendency to syncope. Digitoxin, 0.1 mg. a day, combined with procainamide hydrochloride, 250 mg. 4 times, reduced the attacks of tachycardia, but bradycardia was accentuated and he became dyspnoeic on exertion.

He was admitted to the Section of Cardiology in August 1967. Fig. 2 shows some examples of his arrhythmia. Clinical and laboratory findings were otherwise normal except cardiomegaly on chest x-ray. A transvenous electrode was placed in the right ventricle and connected with an external 'fixed-rate' pacemaker but had to be removed after one hour because of repeated paroxysms of supraventricular tachycardia. He was readmitted in April 1968, and an 'on-demand' pacemaker was connected. The medication was digitoxin and procainamide as above. When the

pacemaker was connected, supraventricular tachycardia with a rate of 160 a minute reappeared. After lanatoside C, 0.4 mg., and procainamide hydrochloride, 600 mg., intravenously, a 'normal' pacemaker rhythm, 72 per minute, took over. After operation, he received procainamide hydrochloride, 500 mg. four times, and digitoxin, 0.1 mg. daily. The former drug was later gradually discontinued. His condition improved considerably, dyspnoea was reduced, and he had no dizziness, syncope, or tachycardia for 12 months after the second pacemaker was implanted.

Case 14 A man of 76 was admitted to the Section of Cardiology in August 1968. He had been healthy until seven years previously when syncope occurred with increasing frequency, up to 4 times a day. A year after his first syncope he had attacks of rapid, irregular heart beats which became gradually more frequent, up to several times a week, and lasted for many hours. There was no relation between tachycardia and syncope. Treatment with ephedrine hydrochloride, ephedrine plus digitalis, atropine, or quinidine, was without effect. Digitalization alone had no effect

FIG. 3 Case 14. *Electrocardiogram shows sinus bradycardia, rate 52 per min. (A); sinus arrest (B); atrial fibrillation, ventricular rate 140 per min. (C); and pacemaker rhythm with interference beat (D).*



on tachycardia, and syncope occurred more often even after low doses (0.05 mg. digitoxin a day). The electrocardiogram showed sinus bradycardia, sinus arrest, and paroxysmal atrial fibrillation (Fig. 3). Otherwise, clinical and laboratory findings were normal. A 'fixed-rate' pacemaker was implanted, and for the 8 months following implantation he has had no syncope or tachycardia. All drugs have been discontinued.

Technique of pacemaker therapy

In one patient (Case 5) epicardial electrodes were applied during thoracotomy and connected to an implanted Medtronic pulse generator, Model 5870 C. In the other 9 a catheter electrode was introduced through the external jugular vein to the apex of the right ventricle under fluoroscopic and electrocardiographic control. The pacemaker was implanted subcutaneously below the clavicle. The procedure took place under local anaesthesia in the cardiac catheterization laboratory. Unipolar Cordis electrodes were used in 8 patients and a bipolar Medtronic in one. The pacemakers were 'fixed-rate' Cordis Ventricle, Model I, C, in 7 patients, Cordis Ectocor 'on-demand', Model III, 129 E, in 1, and Medtronic Model 5870 C in the ninth.

A broad spectrum antibiotic was administered, usually for 3 or 4 days. No anticoagulants were given.

Complications

In 3 patients there was superficial post-operative wound infection which subsided after prolonged antibiotic therapy. The only serious complication occurred in Case 6; this patient was twice treated for staphylococcal septicaemia, 6 months and 1 year after pacemaker implantation. During the first episode she had an attack of rapid atrial fibrillation which subsided after lanatoside C intravenously. She had a superficial wound infection in the neck which ultimately healed, and for the past 18 months she has had no trouble.

Comments

Sino-atrial block or sinus arrest as an expression of 'sick sinus node' (Lown, 1966) was considered to be the basic rhythm disturbance in our patients. It is often impossible to differentiate between the two mechanisms, and they may coexist in the same patient. As regards the underlying cause it is noted that 5 patients had a history of rheumatic fever or diphtheria. Another 2 were mother and son (Table, Cases 10 and 12): a familial, myocardial, factor may have been present, especially as cardiomegaly in Case 12 persisted after correction of bradycardia. A son of Case 12 also had cardiomegaly, and further investigation of this family is in progress. One patient had moderate angina pectoris. The aetiology of sino-atrial block in the remaining 6 is uncertain. It is emphasized that no drugs had been taken before symptoms, and that none of the patients had a

history of or presented electrocardiographic signs of myocardial infarction.

Adams-Stokes attacks due to sino-atrial block are stated to be extremely rare (Müller and Finkelstein, 1966), but to occur more frequently if the patient is digitalized (Levine, 1916; Siddons and Sowton, 1967). Prevention of syncopal episodes by pacemaker has been reported (Müller and Finkelstein, 1966; Siddons and Sowton, 1967; Storstein, 1968). The 7 patients in our study with sino-atrial block uncomplicated by tachycardia were successfully treated and have been free of symptoms at follow-ups for 10-56 months after pacemaker implantation.

It is interesting to note that nearly half of the patients had paroxysmal tachycardia, notably atrial fibrillation. Stock (1969) noted that two of his patients with sino-atrial block developed chronic atrial fibrillation and then lost their dizziness and syncopal attacks. Such a course was not noted in any of our patients, despite a clinical history of up to 17 years. In myocardial infarction with occlusion of the sinus node artery, atrial fibrillation or sino-atrial block sometimes with slow nodal escape rhythm have been reported by many authors (James, 1961; Cancilla and Nicklaus, 1966; Lippestad and Marton, 1967). It appears from our study that paroxysmal, rapid, atrial rhythms are fairly frequent in patients with sino-atrial block and syncope over years, a fact that is little emphasized in textbooks on cardiology, though Levine as early as 1916, in a survey of 18 patients collected from published papers or studied personally, noted paroxysmal atrial fibrillation in 4 of them. Since then scattered case reports have appeared presenting sino-atrial block associated with paroxysms of atrial flutter (Jervell, 1945) or atrial tachycardia (Laake, 1946). Such patients present a difficult problem, as drugs, alone or in combination, are often unsuccessful or cause a deterioration of symptoms. The use of quinidine seemed to us especially harmful, and was associated with more frequent syncopal attacks despite the rather small doses of no more than 0.2 g. four times a day. Digitalis was occasionally used with some success, but was also sometimes associated with more frequent syncopal attacks. Isoprenaline was useful in one patient, but probably provoked paroxysmal atrial fibrillation in two others. The difficulties of medical treatment in sino-atrial block have also been mentioned by Greenwood and Finkelstein (1964).

As 3 of the 6 patients with the combination of bradycardia and tachycardia were severely incapacitated, pacemaker therapy seemed to

be the last resort. Today an 'on-demand' pacemaker, functioning only during bradycardia, seems to be the best approach instead of one with 'fixed rate' where interference phenomena in the case of paroxysmal tachycardia might give rise to problems. The former type was used only in one patient. In the other two a 'fixed-rate' pacemaker was applied, either because of limited experience with the 'on-demand' pacemaker, or because it was not available at the particular time. However, the therapy was successful also in these two patients. In one of them the pacemaker has completely taken over, and the other is unaware of the occasional interference with his own rhythm.

In patients with total atrioventricular block and Adams-Stokes syndrome due to paroxysmal ventricular tachycardia or fibrillation, the attacks of tachyarrhythmia have been abolished by increasing the basic heart rate either with drugs such as isoprenaline or ephinephrine (Linenthal and Zoll, 1963) or by pacemaker (Zoll, Linenthal, and Zarsky, 1960). It is interesting to note that a similar principle probably applies to paroxysmal supraventricular tachycardia/fibrillation occurring in sinus bradycardia with sino-atrial block. In one of our patients syncope and tachycardia have been controlled by pacemaker plus digitalis, while identical doses of digitalis prior to pacemaker implantation were unable to prevent paroxysmal tachycardia. In two others pacemaker therapy alone has abolished not only syncopal attacks, but also paroxysmal atrial fibrillation, as they had no such attacks after pacemaker implantation despite discontinuing antiarrhythmic drugs. A functional relation between sino-atrial block and atrial fibrillation in these two patients seems probable.

References

- Cancilla, P. A., and Nicklaus, T. M. (1966). Atrial fibrillation with occlusion of the sinus node artery. *Archives of Internal Medicine*, **117**, 422.
- Cohen, H. E., Kahn, M., and Donoso, E. (1967). Treatment of supraventricular tachycardias with catheter and permanent pacemakers. *American Journal of Cardiology*, **20**, 735.
- Greenwood, R. J., and Finkelstein, D. (1964). *Sino-atrial Heart Block*, p. 70. Charles C. Thomas, Springfield, Illinois.
- James, T. N. (1961). Myocardial infarction and atrial arrhythmias. *Circulation*, **24**, 761.
- Jervell, O. (1945). Sinus arrhythmia and defective sinoauricular conduction. (In Norwegian.) *Nordisk Medicin*, **26**, 815.
- Laake, H. (1946). A case of paroxysmal auricular tachycardia with sino-auricular and atrio-ventricular block. *Acta medica Scandinavica*, **124**, 52.
- Levine, S. A. (1916). Observations on sino-auricular heart block. *Archives of Internal Medicine*, **17**, 153.
- Linenthal, A. J., and Zoll, P. M. (1963). Prevention of ventricular tachycardia and fibrillation by intravenous isoproterenol and ephinephrine. *Circulation*, **27**, 5.
- Lippestad, C. T., and Marton, P. F. (1967). Sinus arrest in proximal right coronary artery occlusion. *American Heart Journal*, **74**, 551.
- Lown, B. (1966). Electrical reversion of atrial fibrillation. In *Mechanisms and Therapy of Cardiac Arrhythmias*, p. 182. Ed. by L. S. Dreifus, W. Likoff, and J. H. Moyer. Grune and Stratton, New York.
- Müller, O. F., and Finkelstein, D. (1966). Adams-Stokes syndrome due to sinoatrial block. *American Journal of Cardiology*, **17**, 433.
- Siddons, H., and Sowton, E. (1967). *Cardiac Pacemakers*, p. 18. Charles C. Thomas, Springfield, Illinois.
- Stock, J. P. P. (1969). *Diagnosis and Treatment of Cardiac Arrhythmias*, p. 187. Butterworths, London.
- Storstein, O. (1968). Treatment of heart block from a clinical viewpoint. *Acta Medica Scandinavica*, **183**, 559.
- Zoll, P. M., Linenthal, A. J., and Zarsky, L. R. N. (1960). Ventricular fibrillation. Treatment and prevention by external electric currents. *New England Journal of Medicine*, **262**, 105.