

Coronary Artery Fistula

R. J. BARNES, ANTHONY C. S. CHEUNG, AND RAYMOND W. Y. WU

From Queen Elizabeth Hospital, Hong Kong Government

The diagnosis of coronary artery fistula was difficult to confirm and assess until the advent of cardiac catheterization and selective angiography. The first description of this condition was in 1865 by Krause. Subsequent early reports include those by Cayla (1885), Abbott (1906), Trevor (1911), Blake-way (1918), Halpert (1930), and Harris (1937). From 1955 onwards there were increasing numbers of reports and by 1966, Dedichen, Skalleberg, and Cappelen collected 98 published cases. The importance of this anomaly lies in the fact that it must be considered in the differential diagnosis of continuous murmurs over the praecordium, and in the fact that surgical treatment is more generally available. This paper describes three patients with coronary artery fistula, and discusses the diagnosis and indications for operation.

CASE REPORTS

Case 1. A woman, aged 43, complained of dyspnoea and palpitations on exertion for 8 months in 1961. She did not have nocturnal dyspnoea, orthopnoea, or swelling of ankles. She had given birth to her seventh baby without complications 1 year previously. The past history and family history were not relevant. Physical examination revealed a well-nourished woman in good general condition. Blood pressure was 130/75 mm. Hg, radial pulse 82 a minute and regular. A loud harsh systolic murmur, maximal at the right parasternal border, was the only positive physical finding, though x-ray examination of the chest showed generalized enlargement of the heart. The electrocardiogram was within normal limits.

She was closely and regularly followed up, and in 1964 a diastolic murmur became audible maximally at the aortic area. The phonocardiogram (Fig. 1) depicts this finding. The murmur was transmitted along both sternal borders. There was no collapsing pulse or Corrigan's sign, and the blood pressure was unchanged.

In 1967, a systolic thrill was palpable over the aortic area, and the jugular venous pressure was noted to have risen to half way up the neck, with the patient at 45°.

Cardiac catheterization was performed, which showed a left-to-right shunt of 2.7 l./min. at atrial level. The right ventricular pressure was 33/5-9 mm. Hg and pulmonary artery pressure 33/15 mm. Hg. The cardiac output was 4.5 l./min., and the pulmonary vascular resistance 1.6 units. An aortic angiogram (Fig. 2) showed a large tortuous right coronary artery which drained into the right atrium. A Master two-step test did not show any evidence of myocardial ischaemia.

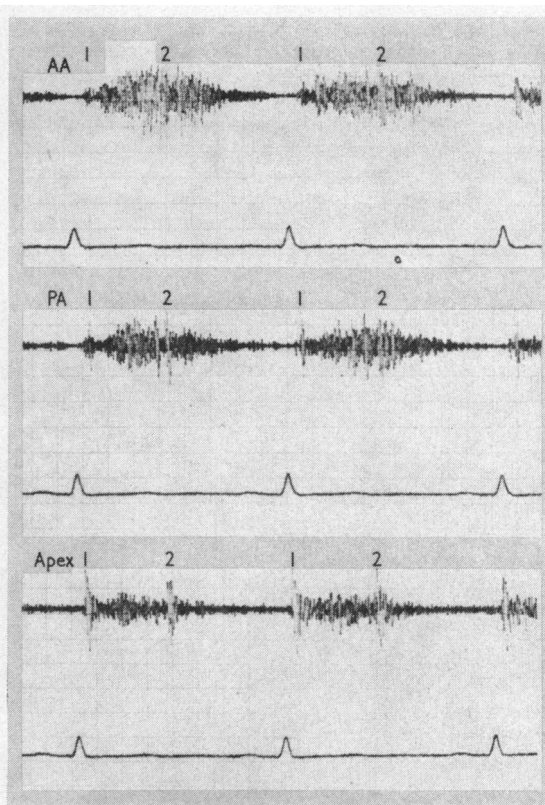


FIG. 1.—Phonocardiogram of Case 1. The diastolic murmur is diminuendo and not as loud as the systolic murmur.

Received July 30, 1968.

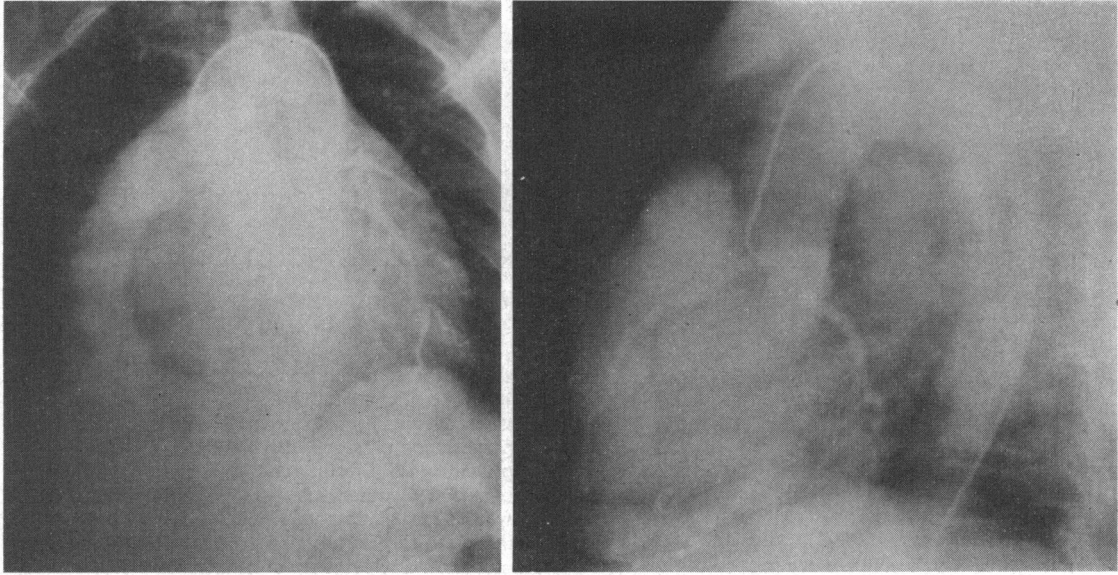


FIG. 2.—Aortogram of Case 1, showing the dilated right coronary artery.

Case 2. A woman, aged 28, was told by a doctor when she was 11 years of age that she had heart disease. There was never any history of chest pain, neither were there any symptoms suggestive of heart failure. She had 3 children, the youngest of whom was 1 year; there had been no complications during pregnancy. On physical examination the patient was found to have collapsing pulse and Corrigan's sign, though the blood pressure was 120/65 mm. Hg. The apex beat was situated at the 5th intercostal space on the mid-clavicular line. A sys-

tolic and diastolic thrill was easily palpable over the apex, but was maximal over the left sternal edge at the level of the 4th intercostal space. The murmur was maximal at the 4th left sternal border, and was continuous in character (Fig. 3). Other systems were normal. The resting electrocardiogram and the x-ray examination of the chest were within normal limits.

Cardiac catheterization revealed a left-to-right shunt of 4.0 l./min. at ventricular level. The pressures in the right ventricle and pulmonary artery were 30/3 and 25/5

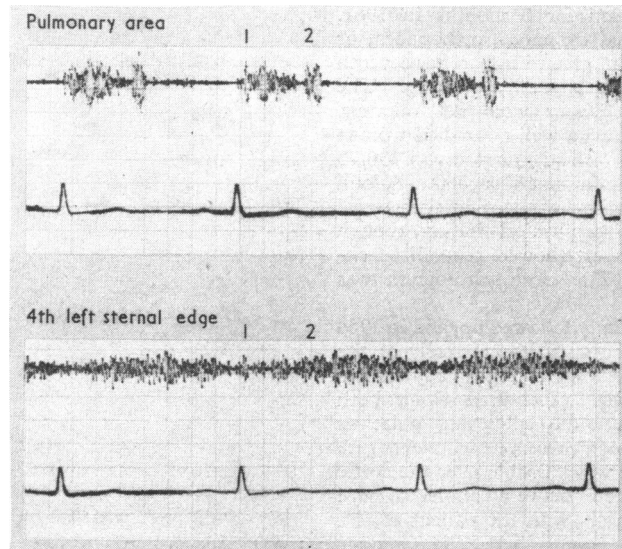


FIG. 3.—Phonocardiogram of Case 2. The continuous murmur is louder during diastole than during systole.

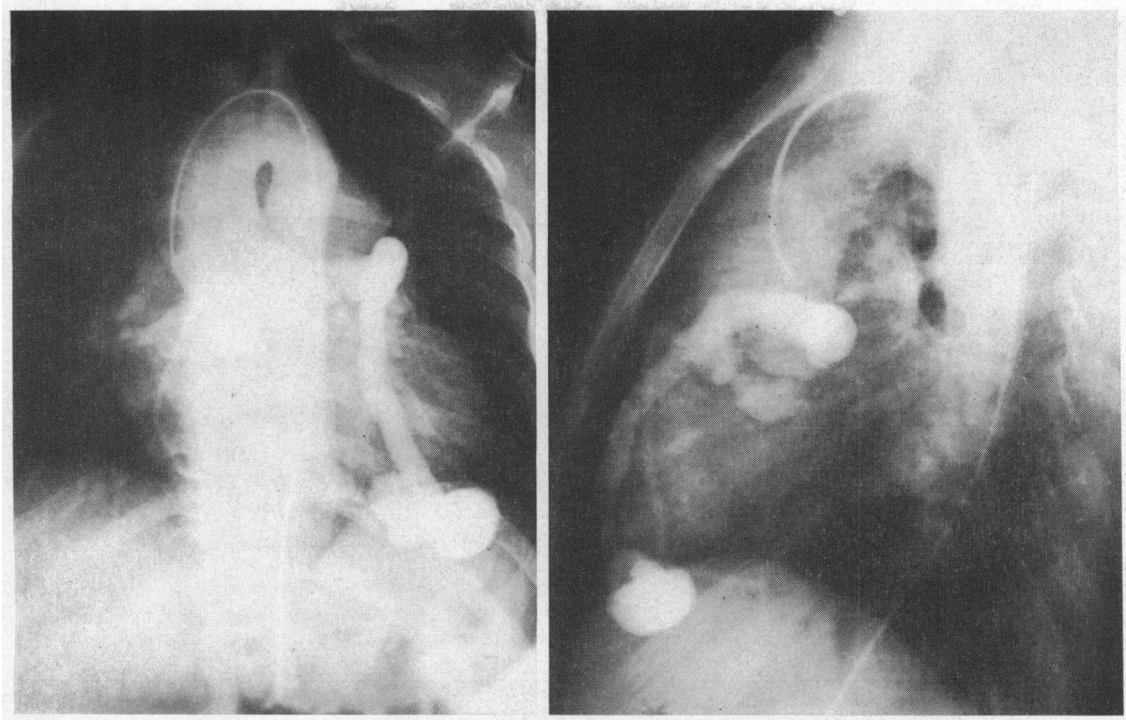


FIG. 4.—Aortogram of Case 2, showing the large anterior descending branch of the left coronary artery.

mm. Hg, respectively. Cardiac output was 4.6 l./min., and the pulmonary vascular resistance 0.8 units. Aortogram showed a large left coronary artery draining into the right ventricle (Fig. 4).

Case 3. A schoolboy, aged 12, was referred because of a murmur over the praecordium. His exercise tolerance was good, and there were no symptoms suggestive of cardiac decompensation. His past health and family history were not relevant. On physical examination, he was found to be of slight build, and in good general condition. The jugular venous pressure was not raised and Corrigan pulsation was absent. The radial pulse was of good volume but was not collapsing in character. There was no clubbing or cyanosis. The apex beat was at the 4th left intercostal space on the midclavicular line. A systolic and diastolic thrill was felt over the right sternal border at the 4th intercostal space. The murmur corresponding to the thrill was continuous in character (Fig. 5) and the heart sounds were not accentuated. The electrocardiogram showed qRs in V3R and RSR's' (0.07 sec.) in V1, with inverted T waves. X-ray examination of the chest showed normal cardiac shadow and lung fields.

Cardiac catheterization revealed a left-to-right shunt of 0.7 l./min. at ventricular level, and a pulmonary vascular resistance of 1.8 units. The right ventricular pressure was 25/0 mm. Hg, the pulmonary artery pressure 25/8 mm. Hg, and the cardiac output was 3.1 l./min.

An aortogram showed the presence of an abnormal right coronary artery (Fig. 6), but the left coronary artery was not visualized.

DISCUSSION

Many classifications of coronary artery fistulae have been proposed to aid the understanding of this condition from the embryological, anatomical, and functional points of view (Williams, Kent, and Edwards, 1951; Edwards, 1958; Edwards, Gladding, and Weir, 1958; Steinberg, Baldwin, and Dotter, 1958; Swan *et al.*, 1959; Muir, 1960; Upshaw, 1962; Dedichen *et al.*, 1966; Effler *et al.*, 1967). The classification based on haemodynamics, advocated by Dedichen *et al.* (1966), is utilized for the sake of simplicity. Two types of communication between a coronary artery and a cardiac chamber are recognized. The first type empties into the pulmonary vein or the left side of the heart, and cannot be detected by cardiac catheterization. In the second type, the coronary artery communicates with the pulmonary artery or the right side of the heart, and the flow can be calculated from right heart catheterization. The cases reported here are of the latter category.

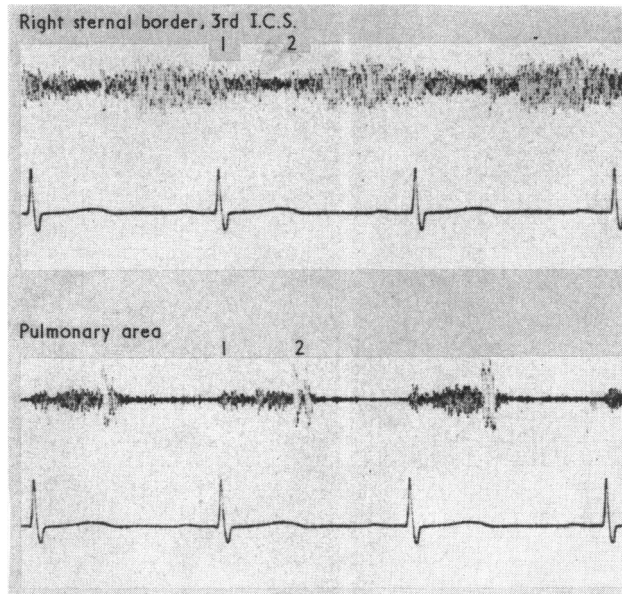


FIG. 5.—Phonocardiogram of Case 3. The continuous murmur is loudest during diastole.

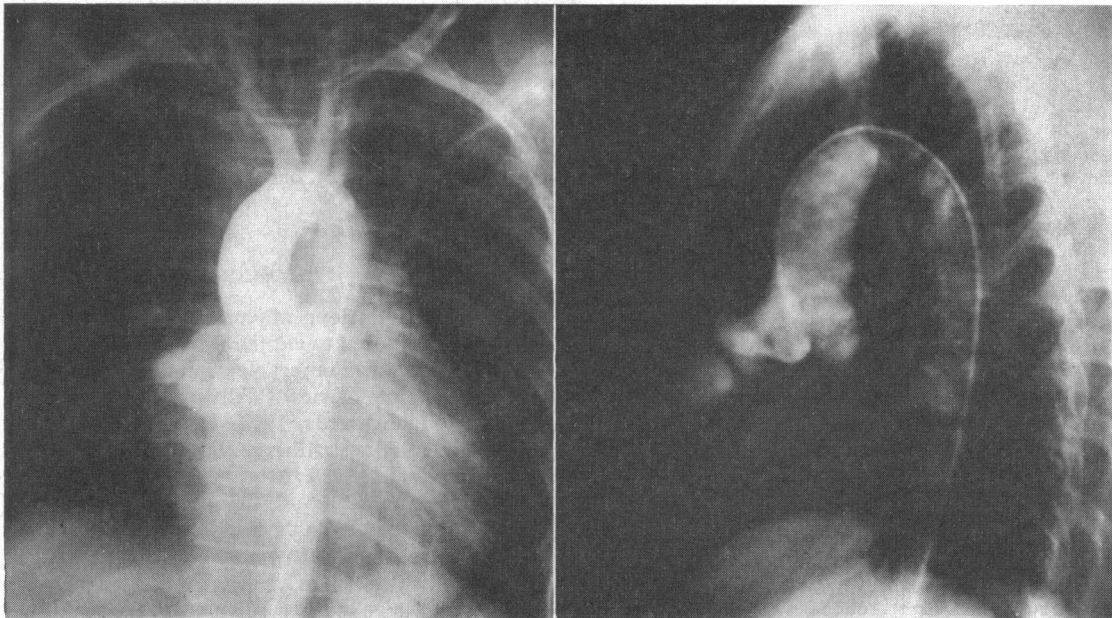


FIG. 6.—Aortogram of Case 3, showing the dilated right coronary artery.

Clinical Features. Many reported cases were symptomless, the patient presenting with a continuous murmur over the praecordium. The site of maximal intensity of the murmur depends on the chamber with which the fistula communicates (Neufeld *et al.*, 1961), and is commonly associated with

a thrill. Case 1 had a systolic thrill at the right sternal border, where the systolic and diastolic murmurs were heard maximally, and did, in fact, have a right coronary artery fistula draining into the right atrium.

Case 2 exhibited a thrill and continuous murmur

over the left sternal border at the level of the 4th left intercostal space, and was shown to have an abnormal anterior descending branch of the left coronary artery draining into the right ventricle. In Case 3, the thrill and continuous murmur were maximal at the right 3rd intercostal space near the sternum, and the communication was from the right coronary artery into the right ventricle. Gasul *et al.* (1960) observed that the diastolic component was louder than the systolic component in fistulae communicating into the right ventricle. This seems to be a useful point in the differential diagnosis of patent ductus arteriosus in which, typically, there is systolic accentuation of the murmur. This feature is seen in the phonocardiogram (Fig. 3 and 5) of Cases 2 and 3, and in one of the patients described by Sanger, Taylor, and Robicsek (1959). Case 1 appeared to have had only a systolic murmur when first seen in 1961. She had been examined repeatedly, but it was not until 1964 that a diastolic murmur was detected. Biörck and Crafoord (1947), Paul, Sweet, and White (1949), and Davison, McCracken, and McIlveen (1955) also described murmurs which changed in character, developing into a continuous murmur at a later date. No explanation is advanced for this phenomenon, as serial haemodynamic studies have not been performed in these patients.

In all suspected cases, the diagnosis should be confirmed by aortogram and cardiac catheterization. The aortogram usually shows a tortuous and dilated coronary artery which may be aneurysmal in size (Case 1); but there have been cases in which the coronary artery was not enlarged, or only minimally so (Biörck and Crafoord, 1947; Essenberg, 1950; Neufeld *et al.*, 1961). The left coronary artery in Case 3 failed to opacify in the aortogram, and selective coronary angiography is, therefore, required to demonstrate the presence or absence of the vessel. This should be performed just before operation.

Cardiac catheterization can often localize the level of the shunt, and provide information on the flow. In the majority of cases the shunt is moderate or small, as it was in Cases 1 and 3 in the present report (2.7 and 0.7 l./min., respectively), but severe shunts of 6.4 and 8.7 l./min./m.² have been reported by Gasul *et al.* (1960), and Neufeld *et al.* (1961), respectively. Case 2 had a shunt of 4.0 l./min.

The x-ray examination of the chest and the electrocardiogram may show various abnormalities depending mostly on the degree of the shunt and the consequent hypertrophy of the ventricle, but the findings are not specific for coronary artery fistula.

Complications. Though many reported cases were symptomless, this condition does not appear

to be as benign as some authors have suggested. The occurrence of congestive cardiac failure has been documented (Davison *et al.*, 1955; Steinberg *et al.*, 1958; Neufeld *et al.*, 1961; Honey, 1964; Berman *et al.*, 1965), and may even occur in infancy (Sanger *et al.*, 1959; Cooley and Ellis, 1962; Braudo *et al.*, 1962). One patient survived to the age of 80 before the onset of heart failure (Colbeck and Shaw, 1954). This shows the wide range of morbidity and mortality of coronary artery fistulae.

Angina pectoris might be expected to be a common symptom since there is a run-off of blood from the coronary artery and its branches, thus depriving the myocardium of part of its blood supply. But this has not been noted as frequently as might be expected. Four patients had electrocardiographic findings suggestive of ischaemic heart disease (Knoblich and Rawson, 1956; Valdivia, Rowe, and Angevine, 1957; Edwards *et al.*, 1958; Sabiston *et al.*, 1963), and 3 patients had angina pectoris (Abbott, Rivarola, and Logue, 1961; Neufeld *et al.*, 1961; Dedichen *et al.*, 1966). The Master two-step test was performed on the present patients and the results were negative. Subacute bacterial endocarditis has been reported by Jacobi and Heinrich (1933), Sanger *et al.* (1959), and Serratto and Kezdi (1965), and pulmonary hypertension by Davison *et al.* (1955), Neill and Mounsey (1958), and Boshier *et al.* (1959). Haemopericardium due to a coronary artery fistula complicated by rupture of the coronary sinus was reported by Habermann, Howard, and Johnson (1963).

Operative Treatment. There has been a relatively large number of patients who were subjected to surgical treatment (Sondergaard, 1955; Davis *et al.*, 1956; Mozen, 1956; Edwards *et al.*, 1958; Neill and Mounsey, 1958; Boshier *et al.*, 1959; Grob and Kolb, 1959; Kittle, 1959; Sanger *et al.*, 1959; Swan *et al.*, 1959; Gasul *et al.*, 1959; Zuhdi *et al.*, 1960; Carmichael and Davidson, 1961; Dubost, Chevrier, and Metianu, 1961; Engle *et al.*, 1961; McIntosh *et al.*, 1961; Neufeld *et al.*, 1961; Barcia *et al.*, 1962; Braudo *et al.*, 1962; Cooley and Ellis, 1962; Papaioannou *et al.*, 1962; Effler and Welti, 1963), and the results appear to be uniformly encouraging. Most operations were performed under conventional anaesthesia, the abnormal coronary artery being cut and/or ligated, after having been clamped for a few minutes while the effect of occlusion on the heart was observed. However, in cases of circoid aneurysm, it may be difficult or impossible to perform simple ligation and excision. Some patients were not ligated at operation for fear of jeopardizing the coronary circulation or because the shunt could not be obliterated by clamping, or by

pressure on the vessel (Paul *et al.*, 1949; Gross, 1949; Walther *et al.*, 1957; Dedichen *et al.*, 1966). Extracorporeal circulation should be employed for such patients, and the feasibility of operation can then be assessed more accurately.

CONCLUSION

From the above it appears that a significant number of complications may occur in patients with coronary artery fistulae, and though many may be symptomless at the time of examination, obliteration of the communication is desirable, particularly in view of the low operative mortality. In uncomplicated cases operation may be delayed. The availability of an extracorporeal circulation is highly desirable, particularly in the presence of aneurysmal coronary arteries.

SUMMARY

Three cases of coronary artery fistula are described, and the diagnostic features of the condition are discussed. Complications appear to be not as infrequent as was suggested by some authors, and this is discussed in the light of indications for operation. Cardiac bypass is recommended particularly in the presence of aneurysmal or cirroid coronary artery.

We wish to thank Dr. J. Han for the aortograms and Drs. R. B. Bernardo, H. J. Yew, and S. M. Kong for their part in the cardiac catheterization.

REFERENCES

- Abbott, M. E. (1906). Anomalies of the coronary arteries. In *Osler's Modern Medicine*, p. 420. Ed. by T. McCrae. Lea and Febiger, Philadelphia and New York.
- Abbott, O. A., Rivarola, C. H., and Logue, R. B. (1961). Surgical correction of coronary arteriovenous fistula. *J. thorac. Surg.*, **42**, 660.
- Barcia, A., Kincaid, O. W., Swan, H. J. C., Weidman, W. H., and Kirklin, J. W. (1962). Coronary artery-to-right ventricle communication: Report of two cases studied by selective angiocardiography. *Proc. Mayo Clin.*, **37**, 623.
- Berman, D. A., Alexander, C. S., Adicoff, A., and Sako, Y. (1965). Coronary arteriovenous fistula. *Amer. J. Cardiol.*, **15**, 853.
- Biörck, G., and Crafoord, G. (1947). Arteriovenous aneurysm on the pulmonary artery simulating patent ductus arteriosus Botalli. *Thorax*, **2**, 65.
- Blakeway, H. (1918). A hitherto undescribed malformation of the heart. *J. Anat. (Lond.)*, **52**, 354.
- Bosher, L. H., Vasli, S., McCue, C. M., and Belter, L. F. (1959). Congenital coronary arteriovenous fistula associated with large patent ductus. *Circulation*, **20**, 254.
- Braudo, J. L., Javett, S. N., Zion, M. M., and Adler, D. I. (1962). Congenital coronary arteriovenous fistula. *Brit. med. J.*, **1**, 601.
- Carmichael, D. B., and Davidson, D. G. (1961). Congenital coronary arteriovenous fistula. *Amer. J. Cardiol.*, **8**, 846.
- Cayla, A. (1885). Malformation congénitale du cœur.—Canal faisant communiquer l'extrémité du ventricule droit avec l'origine de l'aorte. *Progr. méd. (Paris)*, 2 ser., **2**, 121.
- Colbeck, J. C., and Shaw, J. M. (1954). Coronary aneurysm with arteriovenous fistula. *Amer. Heart J.*, **48**, 270.
- Cooley, D. A., and Ellis, P. R. (1962). Surgical considerations of coronary arterial fistula. *Amer. J. Cardiol.*, **10**, 467.
- Davis, C., Jr., Dillon, R. F., Fell, E. H., and Gasul, B. M. (1956). Anomalous coronary artery simulating patent ductus arteriosus. *J. Amer. med. Ass.*, **160**, 1047.
- Davison, P. H., McCracken, B. H., and McIlveen, D. J. S. (1955). Congenital coronary arterio-venous aneurysm. *Brit. Heart J.*, **17**, 569.
- Dedichen, H., Skalleberg, L., and Cappelen, Chr., Jr. (1966). Congenital coronary artery fistula. *Thorax*, **21**, 121.
- Dubost, C., Chevrier, J. L., and Metianu, C. (1961). Congenital communication between the right coronary artery and the right atrium. A case report of successful surgical repair. *J. cardiovasc. Surg. (Torino)*, **2**, 60.
- Edwards, J. E. (1958). Anomalous coronary arteries with special reference to arteriovenous-like communications. (Editorial.) *Circulation*, **17**, 1001.
- , Gladding, T. C., and Weir, A. B., Jr. (1958). Congenital communication between the right coronary artery and the right atrium. *J. thorac. Surg.*, **35**, 662.
- Effler, D. B., Sheldon, W. C., Turner, J. J., and Groves, L. K. (1967). Coronary arteriovenous fistulas: Diagnosis and surgical management. Report of 15 cases. *Surgery*, **61**, 41.
- , and Welti, H. (1963). A propos d'une fistule artérioveineuse entre artère coronaire gauche et ventricule droit. *Arch. Mal. Coeur*, **56**, 164.
- Engle, M. A., Goldsmith, E. I., Holswade, G. F., Goldberg, H. P., and Glenn, F. (1961). Congenital coronary arteriovenous fistula. *New Engl. J. Med.*, **264**, 856.
- Essenberg, J. M. (1950). An anomalous left coronary artery in a human fetus: Its passage through the left atrium and possible discharge into the right atrium. *Anat. Rec.*, **108**, 709.
- Gasul, B. M., Arcilla, R. A., Fell, E. H., Lynfield, J., Bicoff, J. P., and Luan, L. L. (1960). Congenital coronary arteriovenous fistula: Clinical, phonocardiographic, angiocardiographic and hemodynamic studies in five patients. *Pediatrics*, **25**, 531.
- , Fell, E. H., Moreano, M., and Weinberg, M., Jr. (1959). Congenital coronary arteriovenous aneurysm. Clinical, angiocardiographic, and physiologic findings on 3 patients with successful surgical correction. *Arch. Surg.*, **78**, 203.
- Grob, M., and Kolb, E. (1959). Congenital aneurysm of the coronary artery. *Arch. Dis. Childh.*, **34**, 8.
- Gross, R. E.: cited by Paul, O., Sweet, R. H., and White, P. D. (1949). Coronary arteriovenous fistula. Case report. *Amer. Heart J.*, **37**, 441.
- Habermann, J. H., Howard, M. L., and Johnson, E. S. (1963). Rupture of the coronary sinus with hemopericardium. A rare complication of coronary arteriovenous fistula. *Circulation*, **28**, 1143.
- Halpert, B. (1930). Arteriovenous communication between the right coronary artery and the coronary sinus. *Heart*, **15**, 129.
- Harris, P. N. (1937). Aneurysmal dilatation of the cardiac coronary arteries: Review of the literature and report of a case. *Amer. J. Path.*, **13**, 89.

- Honey, M. (1964). Coronary arterial fistula. *Brit. Heart J.*, **26**, 719.
- Jacobi, M., and Heinrich, A. (1933). Congenital aortico-ventricular fistula with engrafted acute suppurative endocarditis. *Amer. J. med. Sci.*, **186**, 364.
- Kittle, C. F. (1959). Discussion. *Arch. Surg.*, **78**, 204.
- Knoblich, R., and Rawson, A. J. (1956). Arteriovenous fistula of the heart. *Amer. Heart J.*, **52**, 474.
- Krause, W. (1865). Über den Ursprung einer akzessorischen A. coronaria aus der A. pulmonalis. *Z. rat. Med.*, **24**, 225.
- McIntosh, H. D., Sleeper, J. C., Thompson, H. K., Jr., Sealy, W. C., and Young, W. G., Jr. (1961). Preoperative evaluation of a continuous murmur in the chest. *Arch. Surg.*, **82**, 74.
- Mozen, H. E. (1956). Congenital cirroid aneurysm of a coronary artery with associated arterio-atrial fistula, treated by operation: A case report. *Ann. Surg.*, **144**, 215.
- Muir, C. S. (1960). Coronary arterio-cameral fistula. *Brit. Heart J.*, **22**, 374.
- Neill, C., and Mounsey, P. (1958). Auscultation in patent ductus arteriosus with a description of two fistulae simulating patent ductus. *Brit. Heart J.*, **20**, 61.
- Neufeld, H. N., Lester, R. G., Adams, P., Jr., Anderson, R. C., Lillehei, C. W., and Edwards, J. E. (1961). Congenital communication of a coronary artery with a cardiac chamber or the pulmonary trunk. ("Coronary artery fistula"). *Circulation*, **24**, 171.
- Papaioannou, A., Agorogiannis, S., Nihoyanopoulos, J., and Lazzaridis, D. (1962). Congenital coronary artery fistula. *Amer. J. Cardiol.*, **10**, 588.
- Paul, O., Sweet, R. H., and White, P. D. (1949). Coronary arteriovenous fistula: Case report. *Amer. Heart J.*, **37**, 441.
- Sabiston, D. C., Jr., Ross, R. S., Criley, J. M., Gaertner, R. A., Neill, C. A., and Taussig, H. B. (1963). Surgical management of congenital lesions of the coronary circulation. *Ann. Surg.*, **157**, 908.
- Sanger, P. W., Taylor, F. H., and Robicsek, F. (1959). The diagnosis and treatment of coronary arteriovenous fistula. *Surgery*, **45**, 344.
- Serratto, M., and Kezdi, P. (1965). Congenital coronary artery—right ventricular fistula corrected surgically. *Brit. Heart J.*, **27**, 781.
- Sondergaard, T. (1955). In *Henry Ford Hospital. International Symposium on Cardiovascular Surgery*, p. 492. Ed. by C. R. Lam. Saunders, Philadelphia.
- Steinberg, I., Baldwin, J. S., and Dotter, C. T. (1958). Coronary arteriovenous fistula. *Circulation*, **17**, 372.
- Swan, H., Wilson, J. N., Woodwark, G., and Blount, S. G. (1959). Surgical obliteration of a coronary artery fistula to right ventricle. *Arch. Surg.*, **79**, 820.
- Trevor, R. S. (1911). Aneurysm of the descending branch of the right coronary artery, situated in the wall of the right ventricle, and opening into the cavity of the ventricle, associated with great dilatation of the right coronary artery and non-valvular infective endocarditis. *Proc. roy. Soc. Med.*, **5**, Sect. Study Dis. Child., p. 20.
- Upshaw, C. B., Jr. (1962). Congenital coronary arteriovenous fistula. Report of a case with an analysis of 73 reported cases. *Amer. Heart J.*, **63**, 399.
- Valdivia, E., Rowe, G. G., and Angevine, D. M. (1957). Large congenital aneurysm of the right coronary artery. *Arch. Path.*, **63**, 168.
- Walther, R. J., Starkey, G. W. B., Zervopolus, E., and Gibbons, G. A. (1957). Coronary arteriovenous fistula: Clinical and physiologic report on two patients, with review of the literature. *Amer. J. Med.*, **22**, 213.
- Williams, R. R., Kent, G. B., Jr., and Edwards, J. E. (1951). Anomalous cardiac blood vessel communicating with the right ventricle: Observations in a case of pulmonary atresia with an intact ventricular septum. *Arch. Path.*, **52**, 480.
- Zuhdi, N., Kraft, D., Carey, J., and Greer, A. (1960). Coronary arteriovenous-like communications. *Arch. Surg.*, **80**, 178.