

## Mild Ebstein's Anomaly

W. A. POCOCK, R. B. K. TUCKER, AND J. B. BARLOW

*From the C.S.I.R. Cardio-Pulmonary Research Unit and the Cardio-Vascular Research Unit, Department of Medicine, The University of the Witwatersrand; and the Cardiac Clinic, General Hospital, Johannesburg, South Africa*

In 1866 Ebstein described the first case of the anomaly that now bears his name. Since then over 300 cases have been reported. The essential pathology consists of malformation and downward displacement of the tricuspid valve, as a result of which the functional right ventricular cavity is reduced in size. The degree of incapacity is extremely variable and is related to the severity of the tricuspid valve deformity and displacement. The diagnosis in a typical case should be readily made but this may be difficult in milder forms, especially where cyanosis is absent. The purpose of this paper is to describe the clinical features, with emphasis on the auscultatory signs, in 9 cases of mild Ebstein's anomaly.

### SUBJECTS AND METHODS

The patients (6 male, 3 female) ranged in age from 6 to 42 years (Table I). Phonocardiograms, using a New Electronic Products (N.E.P.) multichannel apparatus, chest x-ray films, and routine 12-lead electrocardiograms with lead V4R, were obtained in all patients. Eight (Cases 1, 2, 4-9) underwent cardiac catheterization, 1 of whom (Case 7) was catheterized elsewhere. In 3 patients (Cases 2, 4, and 6), an external phonocardiogram and simultaneous right ventricular pressures were recorded during cardiac catheterization.

### RESULTS

#### *Clinical Features*

Symptoms were generally mild (Table I), and 1 subject (Case 4) was symptom free. All were clinically acyanotic, with normal jugular venous pressure, peripheral pulses, and blood pressure. None had evidence of left or right ventricular hypertrophy, but in 3 a hyperactive impulse was palpable to the left of the sternum in the second and third intercostal spaces. A systolic thrill was felt at the lower left sternal border in 2 instances.

#### *Auscultatory Features*

*Systolic murmur.* A somewhat low-pitched crescendo-decrescendo systolic murmur, loudest at the third and fourth left intercostal spaces or at the apex, was present in all patients. The intensity ranged from grade 1 to 3, and the murmur became louder, and sometimes longer, on inspiration. In 5 the murmur was short, occupying half to two-thirds of systole, but in the remaining 4 it was virtually pansystolic.

*Diastolic Murmur.* In all 9 subjects there was a diastolic murmur (Fig. 1), occurring in mid-diastole or presystole, at the lower left sternal border and sometimes at the apex. It was very soft in 2 patients but was easily audible in the remainder and had a scratchy quality. The murmur increased in intensity with inspiration and on occasion was audible only during this phase of respiration.

*First Heart Sound.* Splitting of the first heart sound was detected on clinical auscultation in all patients, and in 2 of them 3 distinct sounds were heard. Phonocardiography revealed 3 components to the first heart sound (Fig. 1 and 2) in 7 patients (Table I). The last component was usually the loudest but the second component was greatest in intensity in 2 instances. Time intervals from Q of the simultaneous electrocardiogram to each of the three sounds were measured (Table II). In the 6 patients who had a "triple" first heart sound with right bundle-branch block pattern on the electrocardiogram (Table II), the first component (M1) was attributed to closure of the mitral valve and the later two (T1 and T2) were thought to arise at the tricuspid valve. In 2 of the 6 patients an external phonocardiogram was recorded simultaneously with the right ventricular pressure, and this showed that T1 coincided with the onset of the upstroke of the right ventricular pressure wave

TABLE I  
NINE CASES OF MILD EBSTEIN'S ANOMALY

| Case No. | Age (yr.) | Sex | Symptoms               | "Triple" first heart sound | Electrocardiogram   | Catheterization                      |   |  |
|----------|-----------|-----|------------------------|----------------------------|---|--------------------------------------|---|--|
|          |           |     |                        |                            |   | Arterial O <sub>2</sub> saturation % | Catheter through patent foramen ovale or atrial septal defect | Left-to-right shunt on hydrogen inhalation |
| 1        | 6         | M   | Fatigue                | Present                    | Right bundle-branch block, right atrial enlargement   | 90.5                                 | Yes   | Yes  |
| 2        | 6½        | M   | Palpitations           | Present                    | Type B ventricular pre-excitation, right atrial enlargement, paroxysmal supraventricular tachycardia              | 96                                   | No  | No   |
| 3        | 7         | F   | Dyspnoea               | Present                    | Incomplete right bundle-branch block, right atrial enlargement  |                                      | Not catheterized  |  |
| 4        | 15        | M   | None                   | Present                    | Right bundle-branch block, right atrial enlargement   | 91.5                                 | Yes   | No   |
| 5        | 20        | F   | Palpitations, dyspnoea | Present                    | Incomplete right bundle-branch block, type B ventricular pre-excitation, paroxysmal supra-ventricular tachycardia | 89                                   | Yes   | Yes  |
| 6        | 21        | M   | Palpitations, dyspnoea | Present                    | Right bundle-branch block, P-R 0.22 sec.  | 93.5                                 | Yes   | No   |
| 7        | 22        | F   | Palpitations, dyspnoea | Absent                     | Type B ventricular pre-excitation, paroxysmal supraventricular tachycardia  | 96                                   | No  | Not done                                   |
| 8        | 29        | M   | Palpitations           | Present                    | Right bundle-branch block   | 96                                   | Yes   | No   |
| 9        | 42        | M   | Palpitations, dyspnoea | Absent                     | Right bundle-branch block   | 94.5                                 | Yes   | Not done                                   |

(Fig. 3a). Comparison of the timing of this component of the first heart sound with the onset of the right ventricular pressure rise in the other 3 patients who were catheterized, but in whom simultaneous pressures and phonocardiograms were not obtained during catheterization, also showed a good

correlation. These findings suggest that T1 is related to tricuspid valve closure. The intervals from Q of the simultaneous electrocardiogram to T1 ranged from 0.08 to 0.17 sec. in these 6 patients, and there was a direct relation between the delay of the sound and the width of the QRS complex

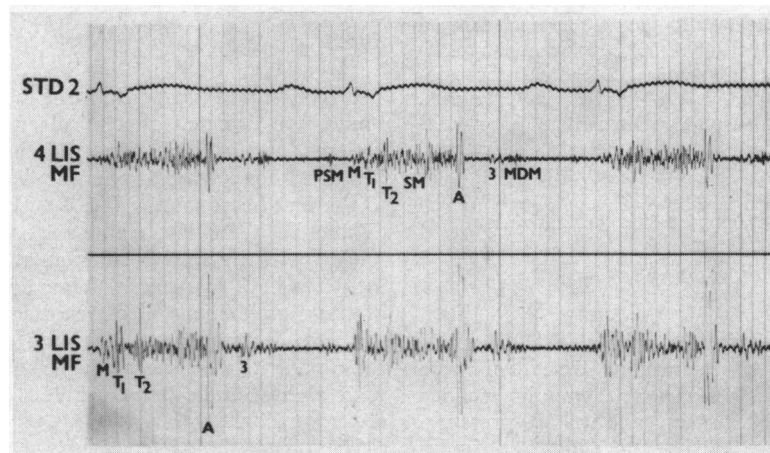


FIG. 1.—Phonocardiogram of a 21-year-old man (Case 6) recorded in expiration. A long systolic murmur extends to the aortic component of the second heart sound (A). A presystolic murmur (PSM) and short mid-diastolic murmur (MDM) are shown. The MDM is preceded by a third heart sound (3) 0.12 sec. after A. The three components of the first heart sound (M, T<sub>1</sub>, and T<sub>2</sub>) are shown.

Abbreviations for this and subsequent figures: LIS=left intercostal space; MF=medium frequency; M=mitral component of the first heart sound; T<sub>1</sub> and T<sub>2</sub>=tricuspid components of first heart sound.

The distance between the heavy vertical lines equals 0.20 sec.

TABLE II

TIME INTERVALS (SEC.) FROM Q OF SIMULTANEOUS ELECTROCARDIOGRAM TO COMPONENTS OF "TRIPLE FIRST SOUND"

| Case No. | Q-M <sub>1</sub> | Q-T <sub>1</sub> | Q-T <sub>2</sub> | Duration of QRS | Bundle-branch block pattern |
|----------|------------------|------------------|------------------|-----------------|-----------------------------|
| 5        | 0.05             | 0.09             | 0.14             | 0.09            | Right                       |
| 3        | 0.06             | 0.10             | 0.13             | 0.10            | Right                       |
| 6        | 0.04             | 0.08             | 0.14             | 0.12            | Right                       |
| 4        | 0.06             | 0.10             | 0.13             | 0.13            | Right                       |
| 1        | 0.04             | 0.10             | 0.15             | 0.13            | Right                       |
| 8        | 0.06             | 0.17             | 0.21             | 0.15            | Right                       |
| 2        | 0.06             | 0.04             | 0.10             | 0.12            | Left*                       |

\* Type B WPW syndrome.

(Table II). Analysis of the simultaneous right ventricular pressure and phonocardiogram in the remaining patient with a triple first heart sound, a six-year-old boy with the Wolff-Parkinson-White (WPW) syndrome and left bundle-branch block pattern, i.e. type B (Rosenbaum *et al.*, 1945; Sodi-Pallares and Calder, 1956), revealed that the onset of the upstroke coincided with the initial component of the first heart sound 0.04 sec. after the beginning of the QRS complex, which therefore indicated tricuspid valve closure (T<sub>1</sub>). Mitral valve closure (M<sub>1</sub>) was represented by a louder sound occurring 0.02 sec. later (Table II).

In the 7 patients with a "triple" first heart sound, the third component (T<sub>2</sub>) occurred from 0.10 to 0.21 sec. after Q (Table II). Six of the 7 patients

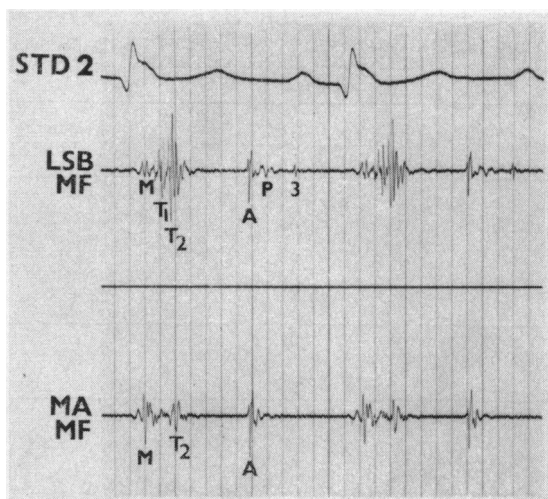


FIG. 2.—Phonocardiogram, recorded in expiration, of a 7-year-old girl (Case 3), showing the "triple" first heart sound. The third component (T<sub>2</sub>) is the loudest. A high frequency third heart sound occurs 0.12 sec. after aortic closure (A). P=pulmonary component of second heart sound; MA=mitral area; LSB=lower left sternal border.

were catheterized, and in 4 (Cases 1, 2, 6, and 8) the right ventricular upstroke showed an initial slow pressure rise followed by a more rapid one (Fig. 3b). Two (Cases 2 and 6) of the 4 had simultaneous external phonocardiograms and right ventricular pressures, and T<sub>2</sub> coincided with the

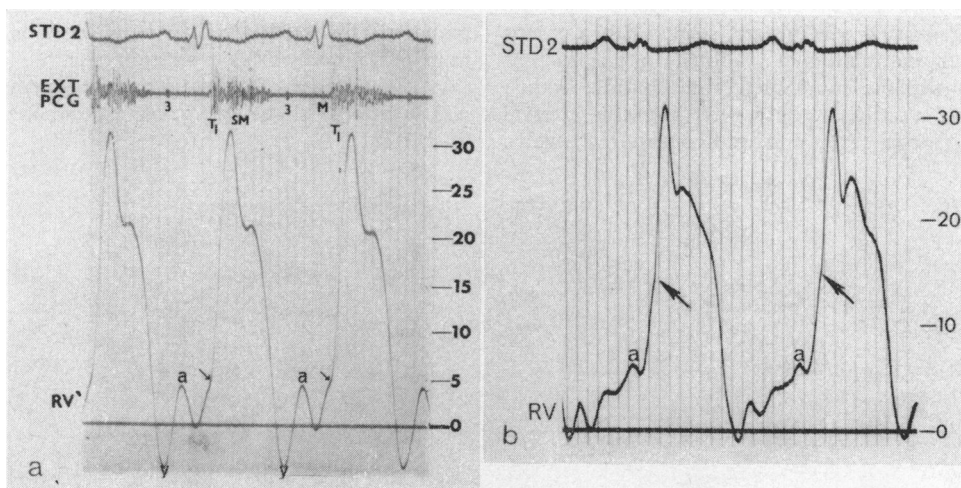


FIG. 3.—(a) Simultaneous right ventricular pressure (in mm. Hg) and external phonocardiogram of a 15-year-old boy (Case 4). The onset of the ventricular pressure rise (marked with an arrow) occurs at the same time as T<sub>1</sub>, which is believed to represent tricuspid valve closure. The third heart sound (3), coincides with the y point. (b) Right ventricular pressure (in mm. Hg) of Case 2, a 6½-year-old boy with type B ventricular pre-excitation. The arrow indicates the point at which the rate of pressure rise becomes steeper. The initial right ventricular pressure rise is early because of the premature ventricular depolarization (see text).

TABLE III  
CORRELATION OF SPLITTING OF SECOND HEART  
SOUND WITH TYPE AND EXTENT OF BUNDLE-BRANCH  
BLOCK PATTERN

| Case No. | A-P interval (sec.)         |             | Duration of QRS (sec.) | Bundle-branch block pattern |
|----------|-----------------------------|-------------|------------------------|-----------------------------|
|          | Expiration                  | Inspiration |                        |                             |
| 5        | 0.04                        | 0.03        | 0.11                   | Left*                       |
|          | 0.02                        | 0.04        | 0.09                   | Right                       |
| 3        | 0.04                        | 0.06        | 0.10                   | Right                       |
| 6        | 0.04                        |             | 0.12                   | Right                       |
| 1        | 0.04                        | 0.06        | 0.13                   | Right                       |
| 4        | 0.06                        | 0.07        | 0.13                   | Right                       |
| 8        | 0.07                        | 0.08        | 0.15                   | Right                       |
| 9        | 0.09                        | 0.10        | 0.16                   | Right                       |
| 2        | 0.04                        | 0.02        | 0.12                   | Left*                       |
| 7        | Pulmonary closure not shown |             | 0.12                   | Left*                       |

Note: Case 6 was recorded in expiration only.  
\* Type B WPW syndrome.

point at which the rate of rise altered. In the 2 (Cases 1 and 8) who did not have simultaneous pressures and external phonocardiograms, the sound also correlated well in timing with this point.

*Second Heart Sound.* The second heart sound could be assessed in all but 1 patient (Case 7), a 22-year-old woman with type B WPW syndrome, in whom pulmonary closure was neither audible nor demonstrable phonocardiographically. Splitting of the second sound was related to the type of conduction defect present (Table III); the 7 patients with a right bundle-branch block pattern had a widely split second heart sound, and the width of splitting was directly related to the extent of the conduction defect. Thus, in one patient (Case 5) with an incomplete right bundle-branch block and a QRS of only 0.09 sec. the interval between aortic (A2) and pulmonary (P2) valve

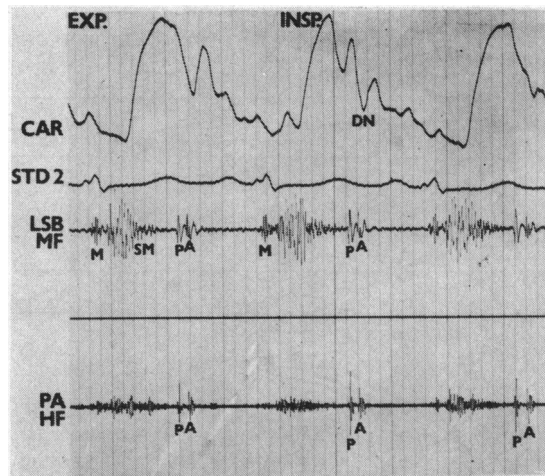


FIG. 5.—Phonocardiogram, recorded during normal respiration, of the 64-year-old boy (Case 2) with WPW syndrome. Reversed splitting of the second sound is shown. P precedes A by 0.04 sec. in expiration and 0.03 sec. in inspiration.

closure was 0.02 sec. in expiration, whereas in Case 9 who had a QRS measuring 0.16 sec. the interval was 0.09 sec. This woman (Case 5), with an incomplete right bundle-branch block, developed an intermittent WPW syndrome of type B pattern, at which time reversed splitting of the second sound was demonstrated (Table III and Fig. 4). In this patient and in the other one (Case 2) with type B ventricular pre-excitation and an audible P2, the paradoxically split second sound remained split in inspiration as well as expiration (Fig. 5). Alteration of the width of splitting caused by respiration was invariably slight and never exceeded 0.02 sec. (Table III).

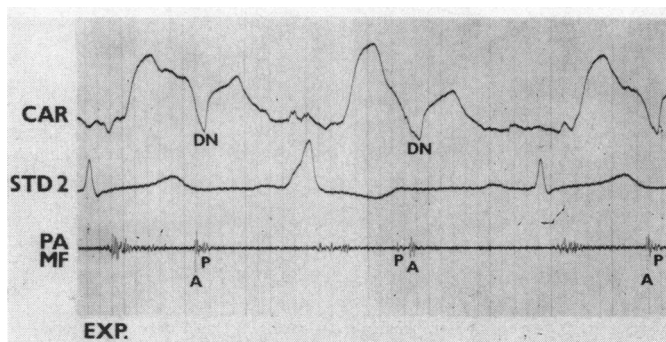


FIG. 4.—Phonocardiogram of Case 5 showing variable splitting of the second heart sound, dependent on the type of ventricular conduction. The first and third complexes show an incomplete right bundle-branch block pattern, at which time A precedes P by 0.03 sec. In the middle complex type B pre-excitation occurs, ventricular activation is premature, and P therefore precedes A. CAR=indirect carotid tracing; DN=dicrotic notch; PA=pulmonary area.

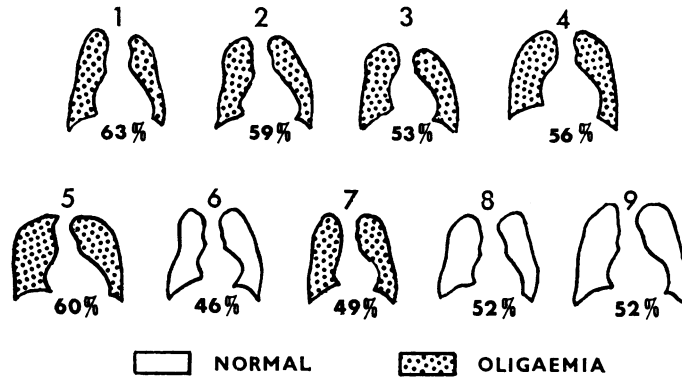


FIG. 6.—Diagrammatic representation of the radiological appearances of the patients in this series. The numbers 1-9 refer to the individual cases, and the cardiothoracic ratios are represented below each cardiac outline.

**Third Heart Sound.** An audible vibration in early diastole, compatible with a third heart sound, was recorded (Fig. 1 and 2) at the lower left sternal border in 6 patients (Cases 1, 3, 4, 6, 7, 8). Measured from P2 the interval to this sound ranged from 0.05 to 0.14 sec. (mean 0.085 sec.). The sound became louder and moved slightly earlier during inspiration, indicating a right-sided origin. It was often unusually high pitched for a third heart sound and in this respect resembled an opening snap. However, an external phonocardiogram recorded with a simultaneous right ventricular pressure tracing in 2 patients (Cases 4 and 6) showed that the sound coincided with the y point of the right ventricular pressure (Fig. 3a), a position characteristic of a third sound and too late for an opening snap.

#### Radiological Features

The cardiothoracic ratio ranged from 46 to 63 per cent (Fig. 6). All patients showed some prominence of the right atrium. Lung vascularity was normal in 3 and slightly reduced in 6.

#### Electrocardiographic Features (Fig. 7)

All were in sinus rhythm. The P-R interval was prolonged (0.22 sec.) in 1 patient (Case 6) and 4 showed enlargement of the right atrium (Table I). Five patients had complete and 2 incomplete right bundle-branch block. One of the latter had an intermittent type B WPW pattern (Fig. 8), and the remaining 2 patients also showed this pattern of pre-excitation. The voltage of the R or R1 wave in V1 and V4R was never more than 9 mm.

#### Cardiac Catheterization

Right ventricular systolic pressures never ex-

ceeded 30 mm. Hg. The onset of the right ventricular pressure rise ranged from 0.10 to 0.14 sec. after Q in the 6 patients with right bundle-branch block who were catheterized, and occurred 0.04 sec. after the beginning of the QRS complex in the 6½-year-old boy (Case 2) with type B WPW syndrome. In the other patient (Case 7) with this pattern who underwent catheterization, the onset of ventricular depolarization was not sufficiently well defined to enable measurements to be made. In all 8 patients the peak of the right ventricular pressure was delayed, and it was usually reached at least 0.03 sec. after that of the corresponding left ventricular pressure. Time intervals from the onset of the upstroke to the peak ranged from 0.08 to 0.14 sec., with a mean of 0.10 sec. The pulmonary artery was entered in 6 patients and in no case was a pressure difference of more than 4 mm. Hg recorded between the right ventricle and pulmonary artery.

No gradient was demonstrated across the tricuspid valve. Mean right atrial pressures were in the normal range and were equal to, or slightly lower than, those in the corresponding left atria. The "a" and "v" waves did not exceed 7 mm. Hg. In 6 patients (Cases 1, 4, 5, 6, 8, and 9) the atrial septum was crossed, confirming the presence of a patent foramen ovale or atrial septal defect, but in only 2 of 5 of these, in whom the sensitive hydrogen inhalation technique (Heimann and Barlow, 1965) was used, was a left-to-right shunt shown (Table I). These 2 patients (Cases 1 and 5, Table I) had no detectable shunt on oxygen studies, nor had Cases 7 and 9 (Table I) in whom hydrogen studies were not performed. In addition to Case 7, the left atrium was also not entered in Case 2, and in this patient hydrogen inhalation studies confirmed the

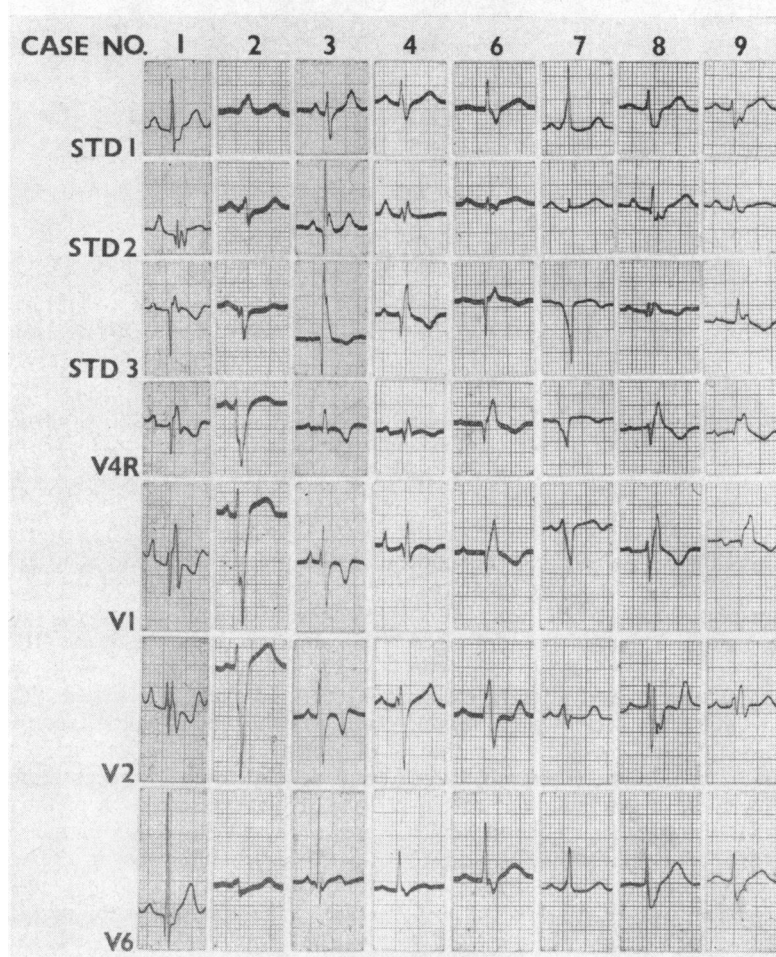


FIG. 7.—Representative complexes from the electrocardiograms of 8 patients. Complete right bundle-branch block is present in Cases 1, 4, 6, 8, and 9, incomplete right bundle-branch block in Case 3, and type B WPW syndrome in Cases 2 and 7.

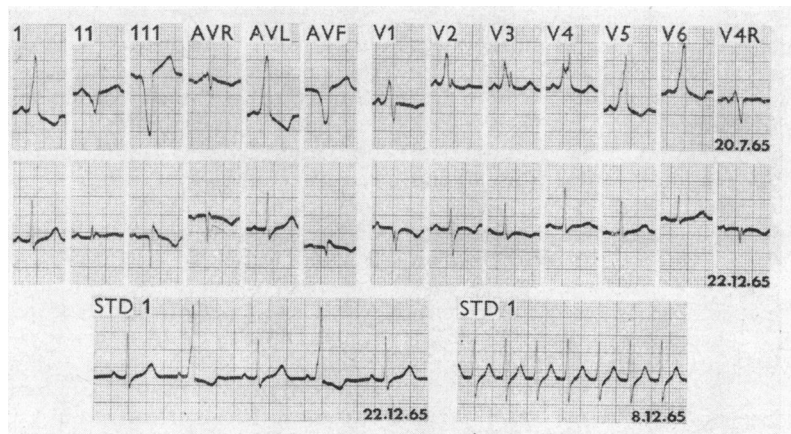


FIG. 8.—Electrocardiograms of Case 5, showing type B ventricular pre-excitation on 20.7.65, incomplete right bundle-branch block, and an alternating pattern on 22.12.65, and paroxysmal supraventricular tachycardia on 8.12.65.

absence of a left-to-right shunt. Arterial oxygen saturations ranged from 89–96 per cent. Cine-angiography showed a moderately enlarged right atrium and an enlarged mobile tricuspid leaflet, with displacement of the valve to the left. In 5 patients an intracardiac electrocardiogram was recorded with simultaneous pressures during withdrawal of the catheter from right ventricle to right atrium. Positive results for Ebstein's anomaly (Yim and Yu, 1958; Watson, 1966) were demonstrated in 3 patients (Cases 2, 5, and 6), but negative results (Moles, Jacoby, and McIntosh, 1964) were also obtained in these during some withdrawals. The remaining 2 patients (Cases 4 and 8) gave negative results, but the technique was employed only once in 1 subject and twice in the other.

Serious arrhythmias were not encountered during catheterization. The 2 patients with WPW syndrome had several short episodes of nodal tachycardia. The patient with intermittent ventricular pre-excitation had a bout of supraventricular tachycardia several hours after catheterization, and this responded to intravenous pressor agents.

#### DISCUSSION

A diagnosis of Ebstein's anomaly of the tricuspid valve should be suspected from the fairly characteristic clinical, electrocardiographic, and radiological features, and can be confirmed by catheterization and angiographic studies. It is important to appreciate the possibility of Ebstein's anomaly before catheterization, since the procedure may fail to reveal the diagnosis unless the condition is specifically sought (Blount, McCord, and Gelb, 1957). The diagnosis in a severe case should be readily apparent, and the presentation of a cyanosed subject with a "quiet" heart, tricuspid murmurs, a large globular cardiac shadow with pulmonary oligoemia on radiological examination, and a low voltage electrocardiogram with conduction defects, is now well recognized (Blount *et al.*, 1957; Mayer, Nadas, and Ongley, 1957; Vacca, Bussmann, and Mudd, 1958; Schiebler *et al.*, 1959; Sinha, Uricchio, and Goldberg, 1960). However, in milder forms of the malformation, often encountered in acyanotic adults, the diagnosis is less obvious (Blount *et al.*, 1957; Watson, 1966).

The severity of Ebstein's anomaly is largely determined by the extent of displacement and deformity of the tricuspid valve (Goodwin, Wynn, and Steiner, 1953; Kezdi and Wennemark, 1958). Part or all of the valve arises from the wall of the right ventricle, dividing this chamber into a proximal "atrialized" portion and a distal outflow portion which is the functional right ventricular chamber. There is

considerable variation in the structure of the valve (Engle *et al.*, 1950; Edwards, 1953; Brown, Heath, and Whitaker, 1956; Yim and Yu, 1958; Schiebler *et al.*, 1959; Genton and Blount, 1967), which may be functionally competent, incompetent, or stenosed. The anterior leaflet is frequently a large sail-like structure that retains part of its attachment to the true annulus. It may be the only functional portion of the valve since the posterior and septal cusps are often rudimentary structures, with vestigial chordae and papillary muscles, attached to the wall of the right ventricular cavity.

An interatrial communication is present in at least 75 per cent of cases (Mayer *et al.*, 1957; Vacca *et al.*, 1958). When the distal right ventricular chamber is very small, it is unable to function adequately. Once the right atrial pressure rises, a right-to-left shunt with resultant cyanosis may supervene. Where the atrial septum is intact, right-sided cardiac failure without central cyanosis would ensue. Though the reported average age at death in Ebstein's anomaly has been 24 (Engle *et al.*, 1950) and 23 years (Vacca *et al.*, 1958), the calculated average life expectancy at birth, based on 219 cases, is 37 years (Makous and Vander Veer, 1966). Longevity is well documented (Adams and Hudson, 1956; Makous and Vander Veer, 1966; Genton and Blount, 1967), and patients may live to their seventh or eighth decade. In these older patients the cardiac lesion may be mistaken for rheumatic valvular disease (Blount *et al.*, 1957).

Despite no anatomical confirmation of the diagnosis in our cases, clinical and other evidence is sufficiently strong for us to be confident that all have Ebstein's anomaly. Because the patients are acyanotic with minor symptoms and a good exercise tolerance, they probably have a mild form of the malformation. The possibility remains, however, that the children have a more severe lesion, and that they may deteriorate within the next few years.

Symptoms of palpitations, dyspnoea, and fatigue are well recognized (Mayer *et al.*, 1957; Schiebler *et al.*, 1959; Sinha *et al.*, 1960). The palpitations may be related to episodes of paroxysmal supra-ventricular tachycardia. The 3 patients in this series with such attacks had the WPW syndrome and this association is common (Schiebler *et al.*, 1959). A physical sign of Ebstein's anomaly that has been emphasized (Blount *et al.*, 1957; Mayer *et al.*, 1957) is the absence of prominent praecordial pulsations. The finding, in 3 of our cases, of a hyperactive systolic impulse in the second and third left intercostal spaces, has, to our knowledge, not been documented. We believe that this pulsation

is produced by the active distal portion of the right ventricle.

*Auscultatory Features.* The systolic murmur in our patients resembled that described in other series (Blount *et al.*, 1957; Mayer *et al.*, 1957; Schiebler *et al.*, 1959; Genton and Blount, 1967), and it has been suggested (Blount *et al.*, 1957; Mayer *et al.*, 1957) that this murmur denotes tricuspid incompetence. Other possibilities as to its origin, such as turbulence arising within the proximal "atrialized" chamber (Vacca *et al.*, 1958) or from an enlarged moderator band (Engle *et al.*, 1950), appear less likely. The jugular venous and right atrial pressures do not necessarily reflect the tricuspid incompetence, since the atrium is enlarged and the amount of regurgitation may be slight. The valve is sometimes fenestrated (Vacca *et al.*, 1958; Bahnson, Bauersfeld, and Smith, 1965), or, by reason of its deformity, may be unable to close the tricuspid orifice (Edwards, 1953). Because the valve is displaced to the patient's left, the systolic murmur is not uncommonly loudest at the apex where it may resemble that of mitral incompetence (Blount *et al.*, 1957).

Diastolic murmurs are a prominent auscultatory feature (Blount *et al.*, 1957; Mayer *et al.*, 1957; Schiebler *et al.*, 1959; Genton and Blount, 1967) and their scratchy, superficial quality is similar to that of other tricuspid murmurs. Tricuspid stenosis may occur but is unusual, and the murmur is probably caused by flow across the malformed valve (Blount *et al.*, 1957).

Though the first heart sound is not mentioned in many reported cases of Ebstein's anomaly, it has been variously described as soft or absent (Vacca *et al.*, 1958), of normal intensity (Mayer *et al.*, 1957; Moles *et al.*, 1964; Genton and Blount, 1967), loud (Blount *et al.*, 1957; Genton and Blount, 1967), and occasionally as split (Brown, Heath, and Whitaker, 1956; Schiebler *et al.*, 1959). In the 6-year-old boy reported by Medd, Matthews, and Thursfield (1954), Leatham described the phonocardiogram as showing a first sound with "several components", and he attributed the later ones to tricuspid valve closure. Several authors have observed a loud, high-frequency systolic sound which they have called an "ejection click" (Bahnson *et al.*, 1965; Genton and Blount, 1967), "mid-systolic" sound (Kjellberg *et al.*, 1955), or "protosystolic right atrial dilatation" sound (Furuta, Go, and Saigusa, 1964). In 7 of our patients phonocardiograms revealed 3 distinct components of the first heart sound. In the 6 with right bundle-branch block pattern, the first component (M1) was attributed to closure of the mitral valve, and

the later two (T1 and T2) were thought to arise at the tricuspid valve. The correlation of T1 with the onset of the upstroke of the right ventricular pressure wave supports our view that this vibration is due to tricuspid valve closure. Furthermore, we have confirmed the observation of other workers that this sound (Medd *et al.*, 1954; Schiebler *et al.*, 1959) and the onset of right ventricular contraction (Blount *et al.*, 1957; Kezdi and Wenne-mark, 1958) are delayed, and the delay appears to be related to the right bundle-branch block (Table II). The loud, third component (T2) of the first heart sound occurred from 0.03 to 0.06 sec. after T1 (Table II), and apparently coincided in timing with the point on the right ventricular upstroke at which the pressure rise became steeper. The abnormal right ventricular pressure curve has previously aroused comment from other workers. Van Lingen and co-workers (1952) noted that the early pressure rise was gradual but became more abrupt with "systolic ejection", whereas Blount and associates (1957) stated that the right ventricular pressure was broadened, late in onset, and had a delayed peak. The anterior leaflet of the tricuspid valve is a large sail-like structure in many patients with Ebstein's anomaly, and is frequently the only functioning portion of the valve. We postulate that both T1 and T2 are produced by this leaflet, the initial component coinciding with the onset of right ventricular contraction and the second component occurring as the leaflet billows, slightly later in systole. Once the "slack" has been taken up in this leaflet, the right ventricular pressure rise would be steeper.

The second sound has seldom been specifically studied, and has been described as soft and single (Van Lingen *et al.*, 1952; Brown *et al.*, 1956; Mayer *et al.*, 1957), normal (Genton and Blount, 1967), or widely split and fixed (Bahnson *et al.*, 1965). Leatham recorded a wide split in the case reported by Medd and associates (1954), which he attributed to the right bundle-branch block. We have found that the splitting of the second sound depended on the type of conduction defect present. Wide splitting was associated with right bundle-branch block, whereas reversed splitting was demonstrated with the WPW syndrome. Comparison of the relative durations of right and left ventricular systole in the patients with right bundle-branch block did not show a significant difference. The widely split second heart sound can therefore be accounted for by the bundle-branch block producing delay in the onset of right ventricular systole, relative to left-sided events, and this is supported by the finding of a direct relation between the Q-T1 and A-P intervals and the width of the QRS complex. The reverse situation exists in



the patients with type B pre-excitation pattern in whom the onset of right ventricular systole is premature (Sodi-Pallares and Calder, 1956), and this, in association with a normal sequence of left ventricular depolarization, results in the reversed split of the second heart sound. With one exception, P2, though soft, was easily audible in all patients in that series. However, this has not been our experience (W. A. Pocock, R. B. K. Tucker, and J. B. Barlow, unpublished data) in 7 patients with severe Ebstein's anomaly whom we have studied. In 5 of those P2 was not audible, and comparatively wide splitting of the second heart sound (0.06 and 0.08 sec. in expiration) was recorded in the remaining 2 patients, both of whom had an incomplete right bundle-branch block pattern with a QRS of 0.10 and 0.11 sec., respectively. The marked delay of P2 possibly resulted from poor right ventricular function, since in these patients the duration of right ventricular systole was delayed relative to that of the left ventricle, as measured phonocardiographically.

Diastolic sounds are a feature of the condition (Medd *et al.*, 1954; Mayer *et al.*, 1957; Vacca *et al.*, 1958; Schiebler *et al.*, 1959; Sinha *et al.*, 1960; Genton and Blount, 1967), and both third and fourth heart sounds have been observed. Fourth heart sounds are less common than are third sounds, and were not encountered in this series. A high-pitched sound in early diastole has also been recorded, which has sometimes been regarded (Medd *et al.*, 1954; Vacca *et al.*, 1958; Barnard and Schrire, 1963) as an opening snap of the tricuspid valve rather than a third heart sound. Of importance, however, is the fact that neither in this series nor in other reported cases have both sounds been recorded in the same patient. It is thus likely that these vibrations have the same mechanism of production and may be high pitched and clicking in quality, or may sometimes resemble a more typical low-frequency third heart sound. In 2 of our cases this early diastolic vibration coincided with the y point of the right ventricular pressure tracing, a timing which is too late for an opening snap of the tricuspid valve. If a right-sided third heart sound arises from tension in the chordae and leaflets of the tricuspid valve, as has been postulated (Nixon, 1961), and is the mechanism of production of a third sound on the left side of the heart, then its unusually high frequency may be related to the large sail-like leaflet or the abnormal chordae tendineae that are common in this anomaly. Because the functioning right ventricular cavity is small, the sound might occur earlier in diastole and in similar manner to the "early diastolic sound" (Mounsey, 1955) of constrictive pericarditis.

#### *Radiological, Electrocardiographic, and Catheterization Findings*

In severe Ebstein's anomaly the greatly enlarged right atrium gives the heart a globular shape that shows virtually no pulsation on screening, thus resembling a pericardial effusion (Blount *et al.*, 1957; Mayer *et al.*, 1957; Schiebler *et al.*, 1959). In addition, the lung fields appear oligemic. However, in mild cases with slight right atrial enlargement, the cardiac outline may be unremarkable and the pulmonary vasculature normal or only slightly reduced (Amplatz *et al.*, 1959).

The electrocardiograms of our patients were characteristic of Ebstein's anomaly, in which right bundle-branch block pattern is common and the QRS complexes are usually slurred and of low voltage (Van Lingen and Bauersfeld, 1955; Blount *et al.*, 1957; Schiebler *et al.*, 1959; Genton and Blount, 1967; Lowe *et al.*, 1968). The exact cause of the electrocardiographic appearances is disputed; Kezdi and Wennemark (1958) postulated an abnormal conduction pathway, whereas other workers (Van Lingen and Bauersfeld, 1955; Blount *et al.*, 1957) thought that the large, thin-walled atrialized portion of the right ventricle was responsible for the wide, low voltage QRS complex. The WPW syndrome with type B pattern occurs in about 10 per cent of cases (Genton and Blount, 1967). It is sometimes intermittent and, as occurred in one of our cases, may alternate with a right bundle-branch block pattern (Kezdi and Wennemark, 1958).

A typical feature, observed in all our cases, is the demonstration by angiocardiology of a large tricuspid leaflet dividing the right ventricle into a proximal thin-walled chamber and a small distal outflow portion. Though there was a patent foramen ovale or atrial septal defect in 6 of our 8 patients who were catheterized, the arterial oxygen saturations were never less than 89 per cent, which is slightly below the lower limit of normal for this altitude (Goldman and Becklake, 1959), and probably within the normal range for a patient under sedation during catheterization. It is therefore likely that any right-to-left shunt, if present, was minimal. A small left-to-right shunt was detected in at least 2 patients, in keeping with the normal right atrial and equal or slightly higher left atrial pressures. The electrode catheter is of value in the diagnosis of Ebstein's anomaly by continuing to record right ventricular potentials on the intracardiac electrocardiogram when the pressure tracing has changed to an atrial form. However, as emphasized by Watson (1966), a positive result should be regarded as confirmatory rather than diagnostic, since both false positive and false negative results may be obtained with this technique.

## SUMMARY

Cases of mild Ebstein's anomaly are not so easily recognized as those with a more severe form of the condition. The presenting features of 9 mild and clinically acyanotic cases have been analysed, with emphasis on the auscultatory signs. These auscultatory signs are sufficiently characteristic to enable a diagnosis to be made, or at least strongly suspected, before electrocardiography or radiography and certainly before cardiac catheterization.

Seven patients had three components to the first heart sound, and it is postulated that 2 of these arise at the malformed tricuspid valve.

There was a close correlation between the pattern of conduction defect present and the reduplication of the second heart sound. Wide splitting of the second sound was associated with a right bundle-branch block pattern, and paradoxical splitting occurred with type B ventricular pre-excitation.

A ventricular filling sound is common in Ebstein's anomaly, and is sometimes unusually high pitched and early. The possibility that these factors may be explained by the malformed and displaced tricuspid valve is briefly discussed.

The Cardiovascular Research Unit is partly supported by grants from the Wellcome Foundation and the Johannesburg City Council. We are grateful to Miss P. A. Palfrey and Miss C. Le May for their considerable technical and secretarial assistance. We thank Dr. H. van Wyk, superintendent of the Johannesburg General Hospital, for permission to publish.

## REFERENCES

- Adams, J. C. L., and Hudson, R. (1956). A case of Ebstein's anomaly surviving to the age of 79. *Brit. Heart J.*, **18**, 129.
- Amplatz, K., Lester, R. G., Schiebler, G. L., Adams, P., Jr., and Anderson, R. C. (1959). The roentgenologic features of Ebstein's anomaly of the tricuspid valve. *Amer. J. Roentgenol.*, **81**, 788.
- Bahnson, H. T., Bauersfeld, S. R., and Smith, J. W. (1965). Pathological anatomy and surgical correction of Ebstein's anomaly. *Circulation*, **31**, Suppl. 1, p. 3.
- Barnard, C. N., and Schrire, V. (1963). Surgical correction of Ebstein's malformation with prosthetic tricuspid valve. *Surgery*, **54**, 302.
- Blount, S. G., McCord, M. C., and Gelb, I. J. (1957). Ebstein's anomaly. *Circulation*, **15**, 210.
- Brown, J. W., Heath, D., and Whitaker, W. (1956). Ebstein's disease. *Amer. J. Med.*, **20**, 322.
- Ebstein, W. (1866). Ueber einen sehr seltenen Fall von Insufficienz der Valvula tricuspidalis, bedingt durch eine angeborene hochgradige Missbildung derselben. *Arch. Anat. Physiol. (Lpz)*, p. 238.
- Edwards, J. E. (1953). Pathologic features of Ebstein's malformation of the tricuspid valve. *Proc. Mayo Clin.*, **28**, 89.
- Engle, M. A., Payne, T. P. B., Bruins, C., and Taussig, H. B. (1950). Ebstein's anomaly of the tricuspid valve. Report of three cases and analysis of clinical syndrome. *Circulation*, **1**, 1246.
- Furuta, S., Go, T., and Saigusa, M. (1964). Direct epicardial phonocardiography. In *Proc. Third Asian-Pacific Congr. Cardiol., Kyoto*, Vol. 2, p. 984.
- Genton, E., and Blount, S. G., Jr. (1967). The spectrum of Ebstein's anomaly. *Amer. Heart J.*, **73**, 395.
- Goldman, H. I., and Becklake, M. R. (1959). Respiratory function tests. Normal values at median altitudes and the prediction of normal results. *Amer. Rev. Tuberc.*, **79**, 457.
- Goodwin, J. F., Wynn, A., and Steiner, R. E. (1953). Ebstein's anomaly of the tricuspid valve. *Amer. Heart J.*, **45**, 144.
- Heimann, K. W., and Barlow, J. B. (1965). The use of hydrogen inhalation in the detection of intracardiac shunts. *S. Afr. med. J.*, **39**, 952.
- Kezdi, P., and Wennemark, J. (1958). Ebstein's malformation: Clinical findings and hemodynamic alterations. *Amer. J. Cardiol.*, **2**, 200.
- Kjellberg, S. R., Mannheimer, E., Rudhe, U., and Jonsson, B. (1955). *Diagnosis of Congenital Heart Disease*. The Year Book Publishers, Chicago.
- Lowe, K. G., Emslie-Smith, D., Robertson, P. G. C., and Watson, H. (1968). Scalar, vector, and intracardiac electrocardiograms in Ebstein's anomaly. *Brit. Heart J.*, **30**, 617.
- Makous, N., and Vander Veer, J. B. (1966). Ebstein's anomaly and life expectancy: Report of a survival to over age 79. *Amer. J. Cardiol.*, **18**, 100.
- Mayer, F. E., Nadas, A. S., and Ongley, P. A. (1957). Ebstein's anomaly: Presentation of ten cases. *Circulation*, **16**, 1057.
- Medd, W. E., Matthews, M. B., and Thursfield, W. R. R. (1954). Ebstein's disease. *Thorax*, **9**, 14.
- Moles, S. S., Jacoby, W. J., and McIntosh, H. D. (1964). Ebstein's malformation. Discordant intracavitary electrocardiographic and pressure relationship. *Amer. J. Cardiol.*, **14**, 720.
- Mounsey, P. (1955). The early diastolic sound of constrictive pericarditis. *Brit. Heart J.*, **17**, 143.
- Nixon, P. G. F. (1961). The third heart sound in mitral regurgitation. *Brit. Heart J.*, **23**, 677.
- Rosenbaum, F. F., Hecht, H. H., Wilson, F. N., and Johnston, F. D. (1945). The potential variations of the thorax and the esophagus in anomalous atrioventricular excitation (Wolff-Parkinson-White syndrome). *Amer. Heart J.*, **29**, 281.
- Schiebler, G. L., Adams, P., Jr., Anderson, R. C., Amplatz, K., and Lester, R. G. (1959). Clinical study of twenty-three cases of Ebstein's anomaly of the tricuspid valve. *Circulation*, **19**, 165.
- Sinha, K. P., Uricchio, J. F., and Goldberg, H. (1960). Ebstein's syndrome. *Brit. Heart J.*, **22**, 94.
- Sodi-Pallares, D., and Calder, R. M. (1956). *New Bases of Electrocardiography*. Henry Kimpton, London.
- Vacca, J. B., Bussmann, D. W., and Mudd, J. G. (1958). Ebstein's anomaly. Complete review of 108 cases. *Amer. J. Cardiol.*, **2**, 210.
- Van Lingen, B., and Bauersfeld, S. R. (1955). The electrocardiogram in Ebstein's anomaly of the tricuspid valve. *Amer. Heart J.*, **50**, 13.
- , McGregor, M., Kaye, J., Meyer, M. J., Jacobs, H. D., Braudo, J. L., Bothwell, T. H., and Elliott, G. A. (1952). Clinical and cardiac catheterization findings compatible with Ebstein's anomaly of the tricuspid valve: A report of two cases. *Amer. Heart J.*, **43**, 77.
- Watson, H. (1966). Electrode catheters and the diagnosis of Ebstein's anomaly of the tricuspid valve. *Brit. Heart J.*, **28**, 161.
- Yim, B. J. B., and Yu, P. N. (1958). Value of an electrode catheter in diagnosis of Ebstein's disease. *Circulation*, **17**, 543.