

## Scalar, Vector, and Intracardiac Electrocardiograms in Ebstein's Anomaly

K. G. LOWE, D. EMSLIE-SMITH, P. G. C. ROBERTSON, AND HAMISH WATSON

*From the Department of Medicine in the University of Dundee, and the Cardiac Department, Royal Infirmary, Dundee*

The severity of Ebstein's anomaly varies greatly. Its diagnosis is relatively easy in patients with characteristic clinical and radiological features, but is often so difficult that it may only be established at necropsy. Genton and Blount (1967) have recently stressed that the scalar electrocardiogram has contributed more to diagnosis in Ebstein's anomaly than in most other congenital cardiac lesions, and there is no doubt that an increasing number of both typical and atypical cases are being recognized and confirmed as its electrocardiographic features become more widely known. The purpose of this paper is to review the peculiar spectrum of *scalar*, *vector*, and *intracardiac* electrocardiograms associated with this malformation and to illustrate them from our experience of 11 carefully studied cases.

### SCALAR ELECTROCARDIOGRAPHY

Engle and her colleagues (1950) emphasized the prolonged P-R interval and right bundle-branch block found in their cases (Fig. 1), and Van Lingen and Bauersfeld (1955) drew attention to the frequency of supraventricular tachycardia, tall and prolonged P waves, long P-R interval, and complete right bundle-branch block with low voltage r, s, and r' deflections in the right praecordial leads. These characteristic and often bizarre features of the scalar electrocardiogram played a large part in increasing the frequency of clinical diagnosis of what had hitherto been considered a rarity usually discovered at necropsy.

By 1958, Vacca, Bussmann, and Mudd were able to analyse the electrocardiographic features of 86 patients, most of whom had been previously reported. Seventeen had frequent ventricular premature beats and 18 had paroxysmal supraventricular tachycardia. Fifty-two had enlarged P waves and 14 had

prolonged P-R intervals. Right bundle-branch block was reported in 61 and was probably present in another 5 patients; left bundle-branch block was present in one. Ventricular pre-excitation occurred in 6 patients (Fig. 2). It is of interest that the first published electrocardiogram from a patient with Ebstein's anomaly showed pre-excitation (Yater and Shapiro, 1937).

In the following year, Frau and Agostoni (1959) found that 90 per cent of 126 previously reported cases had characteristic electrocardiograms with such features as (1) tall (often enormous), positive, rather wide, and pointed P waves in the limb and praecordial leads; (2) prolongation of P-R interval to as much as 300 msec.; (3) partial or complete right bundle-branch block, atypical because of the low voltage, complex polyphasic configuration (rsr's, qrsr', etc.) or broad, deep Q waves over the right praecordium; (4) extreme variability, either spontaneous or provoked, of the P-R interval and of atrial and ventricular excitation; (5) myocardial hyperexcitability as manifested by the Wolff-Parkinson-White syndrome (8.8%), atrial flutter or fibrillation (2.5%), ectopic beats (20%), coronary sinus rhythm, and wandering pacemaker (1.6%), and paroxysmal tachycardia (6%). Complete heart block has also been reported (Danaraj and LaBrooy, 1960). Such features might appear exceptionally in other congenital and acquired heart disease, but when present in varying combinations they provided strong evidence in favour of Ebstein's anomaly even though none was regarded as pathognomonic.

Ebstein's anomaly usually affects the right heart chambers and, as might be expected from a study of the pathological anatomy, their activation is adversely affected; hence the frequency of right bundle-branch block and right ventricular (type B) pre-excitation. Frau and Agostoni (1959) attribute the bizarre, low voltage, polyphasic ventricular

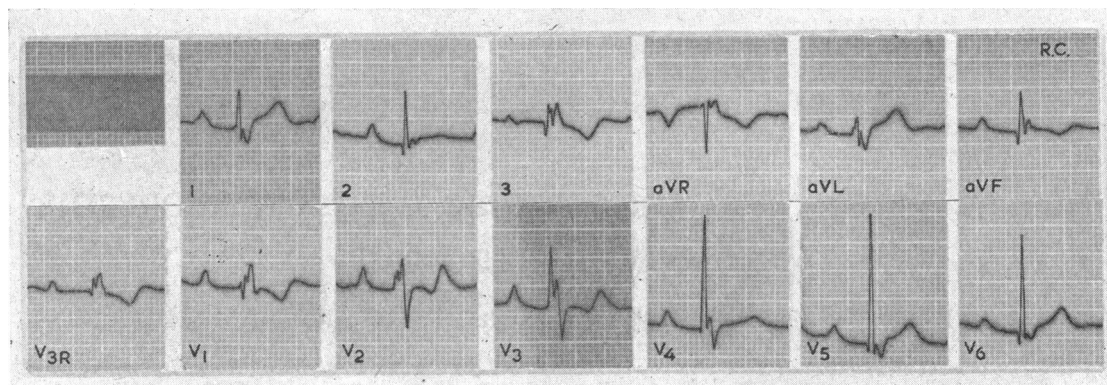


FIG. 1.—Case 9 (22 years). Scalar electrocardiogram showing large P waves, long P-R interval and bizarre complete right bundle-branch block with low voltage QRS complex in V3R and V1.

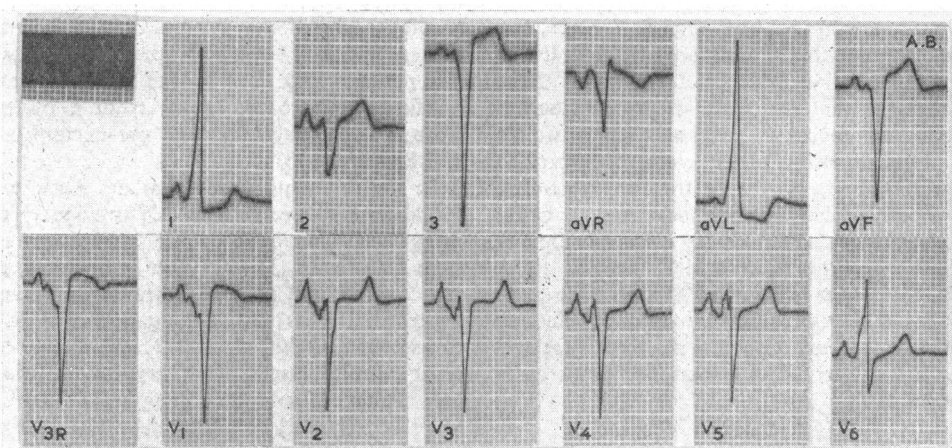


FIG. 2.—Case 7 (12 years). Scalar electrocardiogram showing large P waves and type B ventricular pre-excitation.

complexes in the right precordial leads to the extreme thinness and stretching of the right ventricular wall; Q waves when present in the right precordium were explained by clockwise rotation of the heart resulting from gross right atrial enlargement.

The ventricular pre-excitation in Ebstein's anomaly belongs to type B, in which the delta wave is negative in the right precordial leads (Rosenbaum *et al.*, 1945) (Fig. 2). The area of pre-excitation is thought to be in the right anterior aspect of the septum or free wall of the right ventricle (Tranchesi *et al.*, 1959; Watson and Lowe, 1967). Sodi-Pallares and Marsico (1955) studied 3 cases with this abnormality of conduction and emphasized that type B pre-excitation occurring in a patient with suspected congenital heart disease should always suggest the possibility of Ebstein's disease. It can,

of course, occur in association with other types of congenital heart disease, but much more rarely (Schiebler, Adams, and Anderson, 1959a). Its frequency in Ebstein's anomaly is probably due to maldevelopment of the tricuspid valve being associated either with muscular continuity between the right atrium and the right ventricle or with accessory conducting tissue (Edwards, 1953; Lev, Gibson, and Miller, 1955). As might be expected when pre-excitation complicates Ebstein's anomaly, the QRS complex is usually normal apart from the delta wave, because *premature* excitation of the right ventricle should theoretically prevent *delayed* excitation of the right bundle-branch block type (Gamboa *et al.*, 1962). In some cases alternation between pre-excitation without right bundle-branch block and normal A-V conduction with right bundle-branch block has been reported (Kezdi and Wenne-

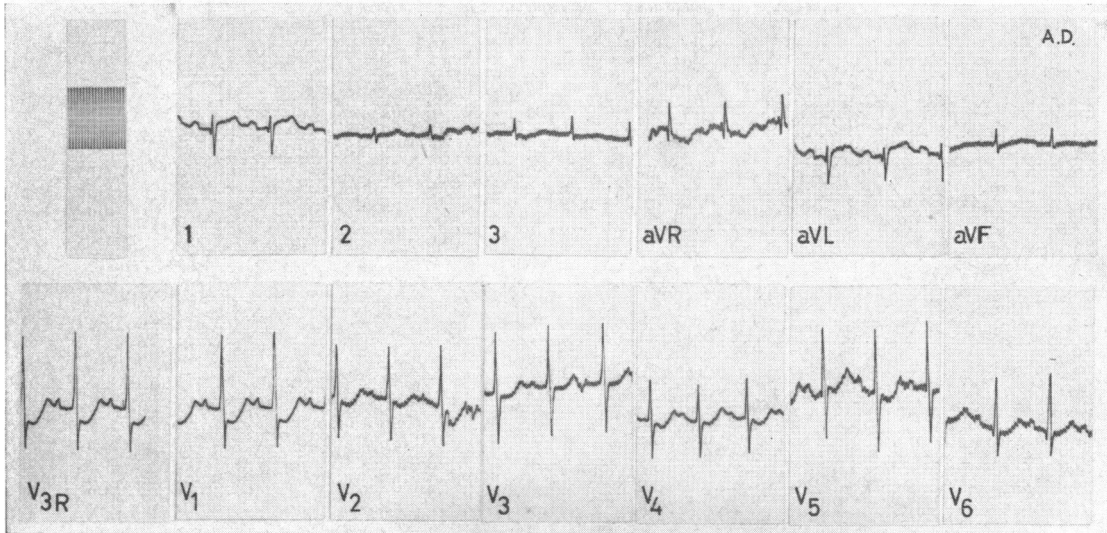


Fig. 3.—Case 11 (10 days). Scalar electrocardiogram within normal limits for a newborn child apart from changes in the S-T segment caused by digitalis.

mark, 1958; Cabrera, Feldman, and Olinto, 1959) and, rarely, type B pre-excitation and right bundle-branch block may co-exist in Ebstein's anomaly (Robertson *et al.*, 1963) or possibly in other forms of heart disease (Zakopoulos, Tsatas, and Liokis, 1964).

The electrocardiogram may be normal at birth (Fig. 3) and progress through incomplete to complete right bundle-branch block, the right praecordial QRS complexes showing progressive decrease in voltage and increased notching and slurring with advancing age (Schiebler *et al.*, 1959b). On the other hand, right bundle-branch block may be present from the start (Fig. 4). While 75 to 80 per cent of patients have complete right bundle-branch block, a small number have QRS of normal duration but a general configuration similar to those with

complete right bundle-branch block (Genton and Blount, 1967) (Fig. 5). A few have right ventricular hypertrophy or combined right bundle-branch block and right ventricular hypertrophy (Brown, Heath, and Whitaker, 1956; Mayer, Nadas, and Ongley, 1957; Genton and Blount, 1967).

We have reviewed the scalar electrocardiographic data of 11 patients with Ebstein's anomaly (Table I). Nine of them showed some features that contributed to the diagnosis. One patient had type B ventricular pre-excitation (Fig. 2). Another had the rare combination of type B ventricular pre-excitation and right bundle-branch block. Of our 3 infants, 1 had a normal tracing (Fig. 3); one had large P waves and the pattern of so-called incomplete right bundle-branch block (Fig. 6); and one had large P waves and right bundle-branch block (Fig. 4).

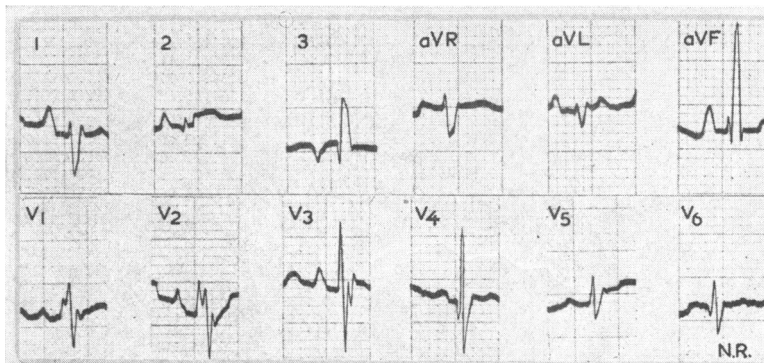


Fig. 4.—Case 8 (3 days). Scalar electrocardiogram showing large P waves and the pattern of right bundle-branch block (QRS=90 msec.) (Lowe and Watson, 1968).

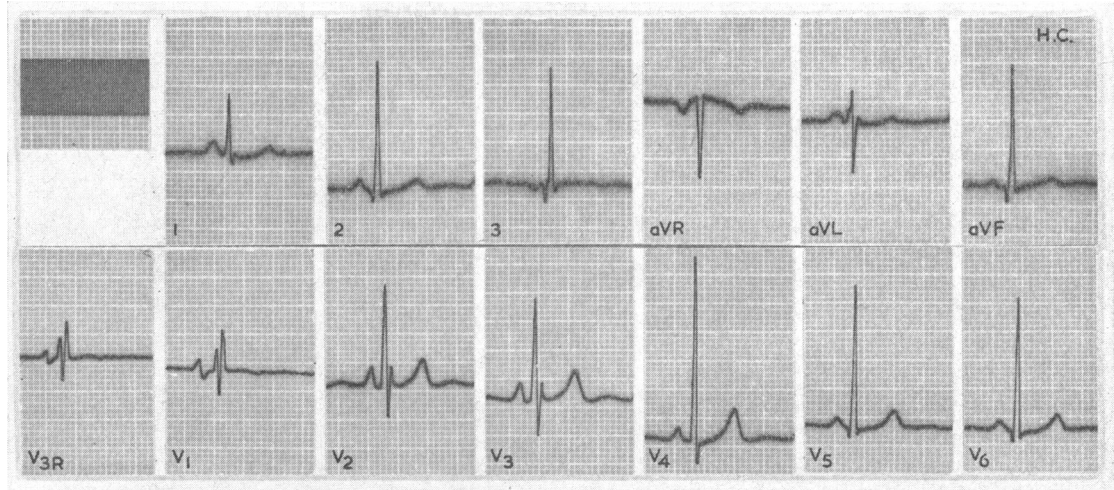


FIG. 5.—Case 6 (29 years). Scalar electrocardiogram showing large P waves, short P-R interval, and in-complete right bundle-branch block. The vectorcardiogram, illustrated in Fig. 11, shows no evidence of ventricular pre-excitation.

Two adults (Cases 5 and 6) had prominent P waves and incomplete right bundle-branch block (Fig. 5). Three patients (Cases 3, 4, and 9) had gross bizarre right bundle-branch block and, contrary to the experience of Van Lingen and Bauersfeld, two of them had tall R' waves in the right praecordial leads (Fig. 7). Case 1 had a normal electrocardiogram, showing only a notched R in the right praecordial leads (Fig. 8) despite an enormous heart. Five patients had dysrhythmia (Table I).

#### VECTORCARDIOGRAPHY

Vectorcardiography has been used chiefly in the diagnosis of right bundle-branch block and ventricular pre-excitation. Gardiner and Kay (1956) described 6 patients with Ebstein's anomaly and complete right bundle-branch block. Spatial vectorcardiograms were recorded in 4 of them and though differing in general contour they all showed a slow "secondary loop" directed to the right and forward, characteristic of right bundle-branch block.

TABLE I  
ANALYSIS OF SCALAR ELECTROCARDIOGRAMS IN 11 PATIENTS WITH EBSTEIN'S ANOMALY OF TRICUSPID VALVE

Case No.	Sex	Age (yr.)	"P" wave		P-R interval (msec.)	Maximal QRS duration (msec.)	Voltage QRS (mm.)		Pattern in right praecordial leads	Comment
			Maximum height (mm.)	Duration (msec.)			V3R	V1		
1	M	28	1	80	240	80	4.5	4.5	qrs	Developed permanent supraventric. tachy. with AV block that varied with posture; notched R in V2; otherwise normal
2	M	6	2	90	90	180	13.5	17.5	Rr's or qRr's	Type B pre-excitation + RBBB; paroxysm. supraventric. tachy.
3	M	16	4.5	120	240	180	12	14	rsR	Intermittent AV dissociation; gross RBBB
4	F	14	1.5	80	180	180	13.5	10	qrsR'	Intermittent AV nodal rhythm; gross RBBB
5	F	14	5	80	200	110	4	6	rSr's'r''	Rt. atr. P waves from V3R to V4
6	F	29	4	100	120	90	11	11.5	rsR	Short P-R interval without pre-excitation
7	M	12	4	100	100	120	23.5	25	S or qS	Type B pre-excitation
8	M	3 dy.	2	60	120	90	—	7.5	rsR's'	Sinus tachy.; tall P in lead I and aVF splintered
9	F	22	3.5	100	260	140	4	6.5	rsr'r''	Long P-R interval; rt. atr. P; bizarre RBBB
10	F	10 mth.	3	80	130	90	5	6	rsr's'	Sinus tachy.; incomplete RBBB
11	F	10 dy.	3	80	120	60	20	19	RS	No evidence of BBB

RBBB = right bundle-branch block.

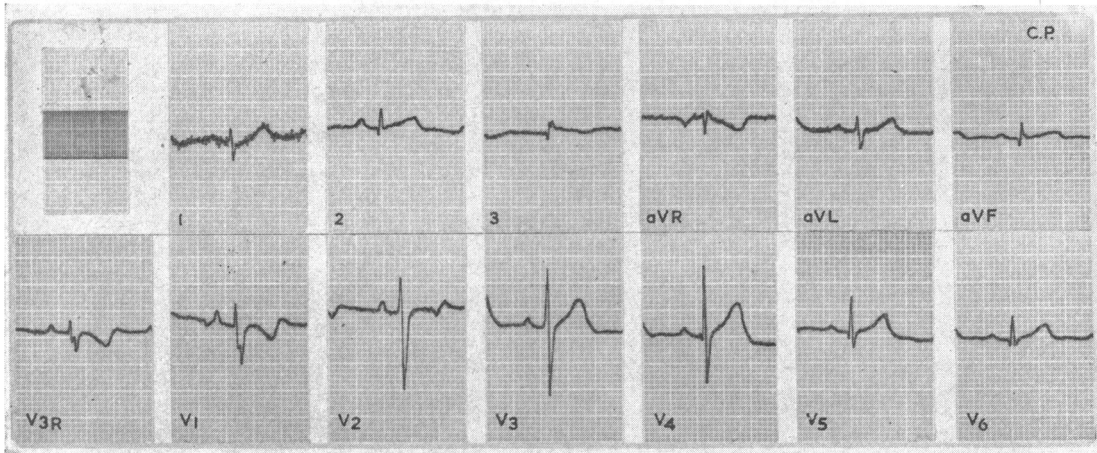


FIG. 6.—Case 10 (10 months). Scalar electrocardiogram showing large P waves in V1 and the pattern of so-called incomplete right bundle-branch block.

Cabrera and Gaxiola (1960) studied 11 patients. In the frontal projection, the inscription of the QRS loop was clockwise in 8, anticlockwise in 2, and had a figure-of-eight configuration in 1. In the horizontal plane it was clockwise in 3, anticlockwise in 6, and figure-of-eight in 2. The initial crochet was reduced in 5 and absent in 6 cases. Initial slurring of the QRS loop occurred in 9 cases and the first part was abnormally directed upward and to the left in 8 of them. Two patients had ventricular pre-

excitation and in 7 the vectorcardiogram had a "terminal appendage", which was directed anteriorly and to the right, as in right bundle-branch block. They concluded that features suggesting Ebstein's anomaly in young patients with electrocardiographic signs of mild or moderate right ventricular overload were abnormal slurring of the initial part of the QRS loop that was directed upward and to the left, and terminal slurring suggestive of incomplete right bundle-branch block.

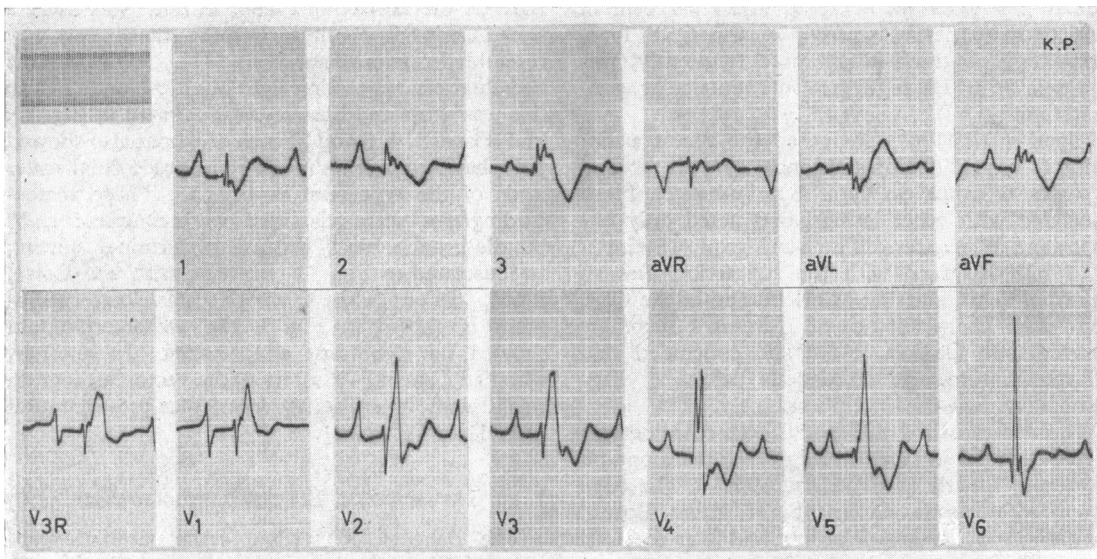


FIG. 7.—Case 3 (16 years). Scalar electrocardiogram showing huge P waves, long P-R interval (240 msec.), bizarre complete right bundle-branch block with tall broad R' in right praecordial leads. Compare with vectorcardiogram in Fig. 10.

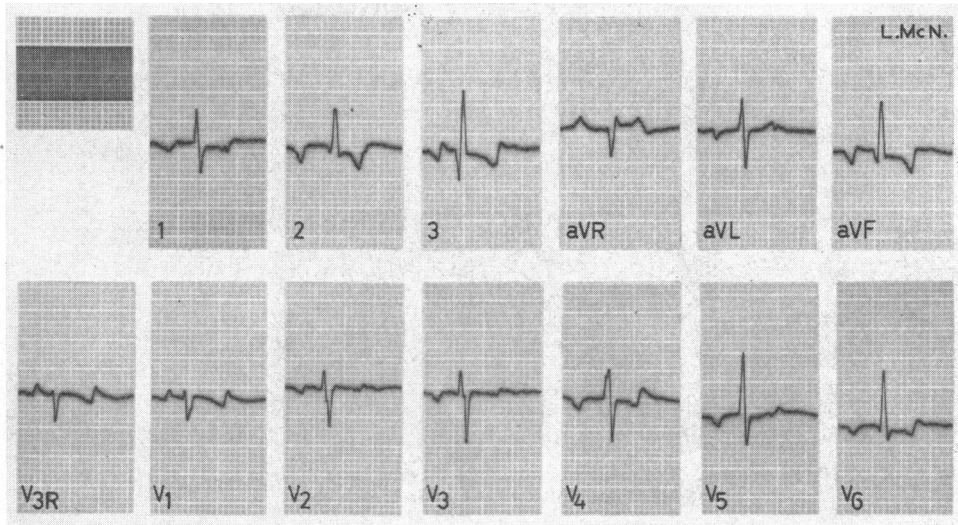


FIG. 8.—Case 1 (28 years). Scalar electrocardiogram showing no significant abnormality apart from atrial flutter with 2:1 A-V block.

In a later communication (Cabrera *et al.*, 1962) they reported 15 cases and again emphasized that the initial crochet was absent in 9, very reduced in 4, and of normal voltage in only 2. The first part of the QRS loop was slurred in 7 patients, all of whom had paroxysmal tachycardia. Eight patients had complete right bundle-branch block, 4 had incomplete right bundle-branch block, and 3 had type B ventricular pre-excitation. Although typical ventricular pre-excitation occurred in 20 per cent of their patients, initial slurring of the QRS loop, which they observed much more frequently, was regarded as a lesser degree of ventricular pre-excitation.

Bilger *et al.* (1961) compared the vectorcardiograms of 6 cases of Ebstein's anomaly with those of 47 cases of complete right bundle-branch block associated with other lesions, and noted only unimportant differences. The same group (Stein *et al.*, 1962) disagreed with the suggestion that an abnormal initial slurring or orientation of the QRS loop was characteristic of Ebstein's anomaly (Cabrera and Gaxiola, 1960) and concluded that the vectorcardiogram afforded no particular diagnostic advantage in Ebstein's anomaly.

We have recorded the spatial vectorcardiograms in 10 patients using a Cambridge vectorcardiograph (Cameron, Lawrie, and Wright, 1959). The cube system of electrode placement (Grishman, Borun, and Jaffe, 1951) was used at first and later replaced by the Frank system (Frank, 1956). Because ventricular pre-excitation and right bundle-branch block seemed the most important electrocardio-

graphic features of Ebstein's anomaly, particular attention was paid to the early and late activation forces. Two patients (Cases 2 and 7) had classical type B ventricular pre-excitation, with delta vectors directed to the left in the horizontal plane (Fig. 9a and b), and one of these (Case 2) showed, in addition, the pattern of right bundle-branch block (Robertson *et al.*, 1963) (Fig. 9b). In 7 of the other 8 patients the first part of the QRS loop was directed to the right in the horizontal plane; in none was there a slow inscription of the early forces that in any way resembled a delta vector (Table II). Eight patients had a pattern suggesting right bundle-branch block; this was gross and bizarre, as illustrated in Fig. 10, in 4 (Cases 3, 4, 6 and 2) each of whom also showed polyphasic complexes in the right praecordial scalar leads of the type seen in Fig. 7. Three vectorcardiograms were classified as incomplete right bundle-branch block because of terminal slowing as illustrated in Fig. 11 (Emslie-Smith and Lowe, 1968). In one (Case 1) whose scalar electrocardiogram is shown in Fig. 8 the vectorcardiogram showed no significant abnormality. In another, who had a short P-R interval, the vectorcardiogram was of value in excluding ventricular pre-excitation (Fig. 11).

#### INTRACARDIAC ELECTROCARDIOGRAPHY

The dangers of cardiac catheterization—paroxysmal dysrhythmias and cardiac arrest—are now well known and may have been overstressed in the past. We believe that patients with Ebstein's

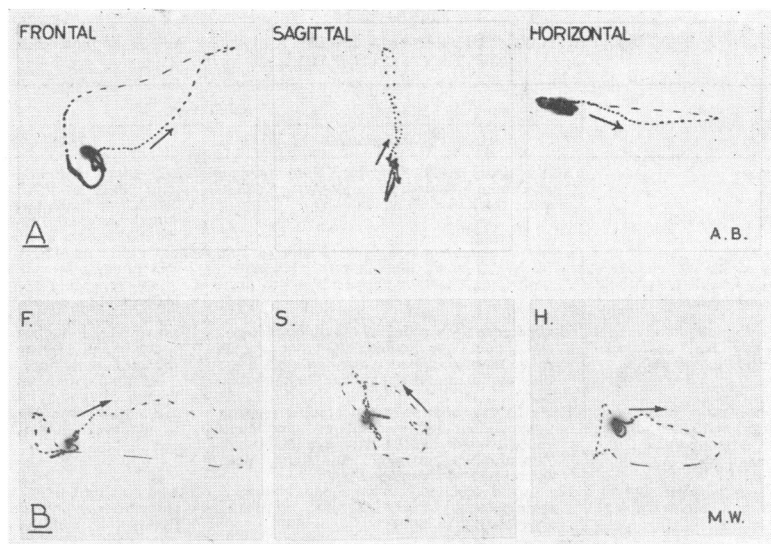


FIG. 9.—A. Case 7 (12 years). The vectorcardiogram shows the very slow inscription of the initial part of the QRS loop (delta vector) directed to the left (type B pre-excitation). The appearance of a slow run-in from the right in the frontal plane is the result of a J deflection corresponding to the S-T deflection in leads I and aVL (see Fig. 2).

B. M.W. (6 years). The vectorcardiogram shows type B pre-excitation and also a slow inscription of the "terminal appendage" of the QRS loop with a "run-in" from the right, characteristic of right bundle-branch block.

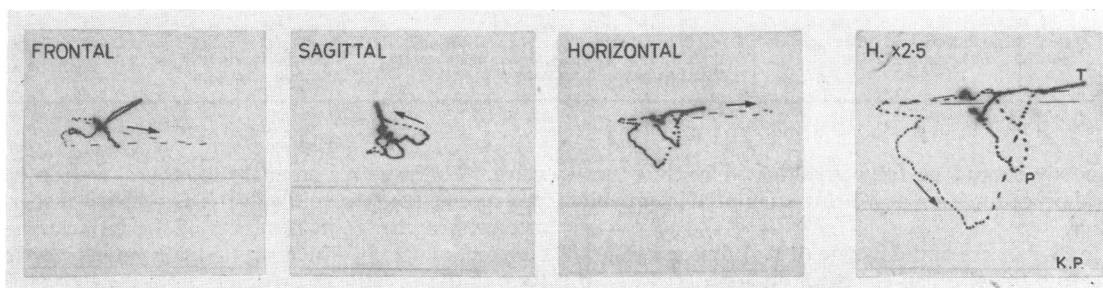


FIG. 10.—Case 3 (16 years). The vectorcardiogram shows the very slow inscription and bizarre path of the terminal part of the QRS loop corresponding to the polyphasic scalar complexes shown in Fig. 7.

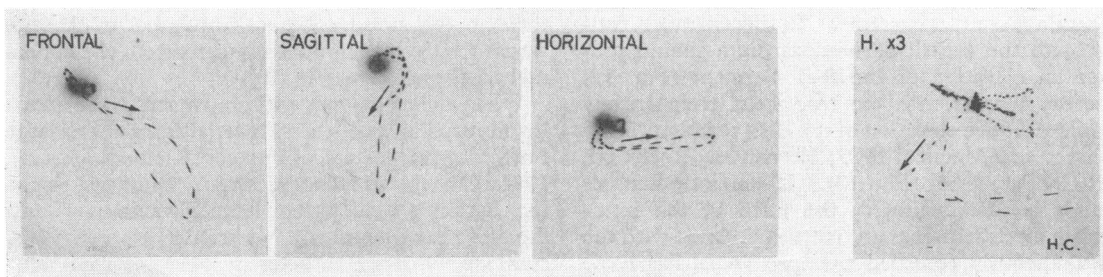


FIG. 11.—Case 6 (29 years). The vectorcardiogram shows a normal speed of inscription of the initial part of the QRS loop. The absence of a delta vector excludes pre-excitation suggested by the short P-R interval seen in Fig. 5.

TABLE II  
ANALYSIS OF SPATIAL VECTORCARDIOGRAMS IN 10 PATIENTS WITH EBSTEIN'S ANOMALY  
OF TRICUSPID VALVE

Case No.	P loop	QRS loop	
		Frontal plane	Horizontal plane
1	Atr. flutter	Early forces directed upward then rotating clockwise leftward, main loop inscribed in wide clockwise direction	Early forces directed forward and to right and then passing anticlockwise to left, main loop having figure-of-8 configuration; small terminal crochet directed to right; normal speeds of inscription
2	Loop passing anteriorly and downward initially and passing clockwise in frontal and horizontal planes	Delta vector inscribed upward and to left, leading to main loop inscribed clockwise with large "terminal appendage" to right	Delta vector passing to left along 0° axis, leading to main loop inscribed clockwise with large "terminal appendage" pointing forward and to right with slow run-in from right
3	Loop passing anteriorly and downward and anticlockwise in horizontal plane	Early forces show as initial crochet passing to right, then inscribed anticlockwise to form main loop inscribed clockwise with large bizarre "terminal appendage" directed to right	Narrow initial crochet directed to right, then main loop passing leftward in clockwise direction with large bizarre slowly inscribed "terminal appendage" orientated anteriorly and to right with anticlockwise rotation
4	Loop passing anteriorly, downward, then anticlockwise in horizontal and frontal planes	Early forces show as initial crochet passing upward then clockwise leftward, main loop being inscribed anticlockwise, with bizarre "terminal appendage" to right, with figure-of-8 configuration	Main loop anticlockwise with large "terminal appendage" directed to right and anteriorly
5	Narrow loop passing slightly upward and backward but mainly to left	No initial crochet; narrow loop inscribed anticlockwise; slowly inscribed "terminal appendage" to right	Initial crochet passing to right and anteriorly, inscribed anticlockwise; main loop has figure-of-8 configuration with "terminal appendage" to right with slow run-in from right
6	Loop clockwise in horizontal plane	Initial crochet passing upward and to right and inscribed anticlockwise; main loop has figure-of-8 configuration	Initial crochet passing to right and inscribed anticlockwise; clockwise rotation of main loop, with slow run-in from right
7	Small P loop inscribed anticlockwise and inferiorly in frontal plane	Delta vector passing to left, main loop inscribed anticlockwise	Delta vector passing to left along 0° axis; anticlockwise rotation of main loop
9	Inscribed anticlockwise in frontal and horizontal planes	Initial crochet passing upward and inscribed anticlockwise; main loop has figure-of-8 configuration, with complex slowly inscribed "terminal appendage" to right	Initial crochet passing to right and inscribed anticlockwise; main loop inscribed anticlockwise with slowly inscribed "terminal appendage" directed to right and anteriorly
10	Tiny figure-of-8 loop	Early forces directed upward and to right then rotating anticlockwise; main loop shows figure-of-8 configuration with terminal slow run-in from right	Early forces show as initial crochet passing forward and to right leading to main loop inscribed anticlockwise with slow run-in from right and posteriorly
11	Small loop inscribed clockwise in horizontal plane	Early forces directed to right and superiorly then turning abruptly downward and further to right to form narrow main loop	Early forces directed forward and to right, then continuing forward to form main loop inscribed clockwise

anomaly should be fully investigated because surgical procedures are now being attempted in suitable cases.

Sodi-Pallares and Marsico (1955) first suggested that the intracardiac electrocardiogram could help in diagnosis. At cardiac catheterization or surgical exploration the tip of an electrode catheter can be pressed against the endocardial wall of the "atrialized" right ventricular chamber at different levels to produce contact currents. In this chamber, contact with the ventricular endocardium should produce an elevation of the S-T segment (Fig. 12) whereas contact with the true atrial endocardium should produce elevation of the P-Q segment (Sodi-Pallares and Marsico, 1955; Hernandez, Rochkind, and Cooper, 1958) (Fig. 13). If contact potentials cannot be demonstrated, the form of the intracardiac electrocardiogram, when correlated with the simultaneously recorded pressure pulse, has some diagnostic value. In the normal heart the P waves become larger and the QRS complexes smaller as the electrode is withdrawn through the tricuspid

valve. In Ebstein's anomaly, however, a drop in pressure at the tricuspid valve is not always associated with a change in the form of the intracardiac electrocardiogram, which may remain ventricular in form until the catheter tip passes from the atrialized ventricle into the true atrium (Yim and Yu, 1958; Hernandez *et al.*, 1958; Sterz *et al.*, 1960). The intracardiac electrocardiogram may, therefore, signal the passage of the electrode at the catheter tip through the annulus fibrosus proximal to the site where the pressure pulse changes across the abnormal tricuspid valve (Fig. 13).

When the catheter is withdrawn across the annulus fibrosus in patients with atrial fibrillation, large f waves appear instead of P waves (Kleinerman *et al.*, 1961; Gandhi and Datey, 1963). Similarly, when the rhythm is atrial flutter, large F waves may mark the site of the annulus. Ventricular ectopic beats, common when the catheter tip is in the right ventricle, are less frequent during catheterization of the right atrium. Their presence during the recording of an atrial pressure in the atrialized portion of the



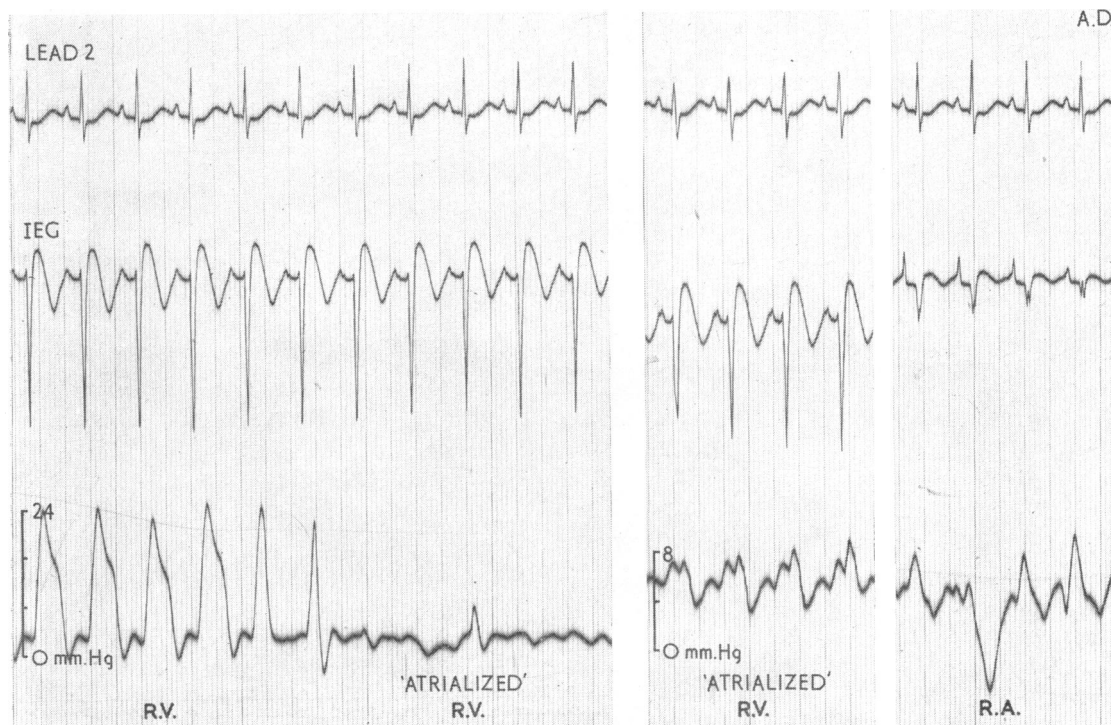


FIG. 12.—Case 11 (10 days). Records obtained at cardiac catheterization showing the paradoxical association of a right ventricular electrocardiogram with an atrial pressure pulse. The intracardiac electrocardiogram (IEG) also shows ventricular contact potentials (S-T elevations) in the atrialized portion of the right ventricle.

right ventricle has been said to be characteristic of Ebstein's anomaly (Kossmann, 1958; Gandhi and Datey, 1963), but we have not found this a helpful sign even when deliberate attempts were made to elicit it.

Withdrawal tracings suggestive of Ebstein's anomaly may also be obtained in patients who do not have it—"false positives" (Gandhi and Datey, 1963); and normal intracardiac electrocardiographic withdrawal patterns can be obtained in patients who do—"false negatives" (Moles, Jacoby, and McIntosh, 1964). Watson (1966) has shown how such "false positive" and "false negative" patterns can be obtained and that they are related to the speed and care with which the electrode catheter is withdrawn either through the atrialized portion of the ventricle in Ebstein's anomaly or through the normal tricuspid valve.

Nine of our patients have been investigated by cardiac catheterization. The information gained was helpful in supporting the clinical diagnosis in typical cases or in establishing the diagnosis in atypical ones. Particular attention was paid to the intracardiac electrocardiogram in the region of the

atrialized portion of the right ventricle, where the paradoxical association of a right ventricular complex with a right atrial pressure pulse might help to confirm the diagnosis, especially if it occurs to the left of the sternal edge. In 7 cases many withdrawals from the right ventricle into the right atrium were studied on the oscilloscope, and 35 representative tracings were recorded from them. Of these withdrawals, 30 were compatible with a diagnosis of Ebstein's anomaly and 5 were false negatives. But in each of the 7 patients some of the withdrawals were helpful in confirming the diagnosis.

Despite repeated attempts, we were only able to produce S-T elevation in the atrialized portion of the right ventricle in a single patient (Fig. 12).

In some of the intracardiac electrocardiograms there were additional features of interest. In one (Case 5) we demonstrated the electrogram of the bundle of His—a small diphasic wave just preceding the QRS complex, recorded in the atrialized ventricle (Watson, Emslie-Smith, and Lowe, 1967). In another (Case 7) the intracardiac electrocardiogram was recorded from all 4 heart chambers for the first

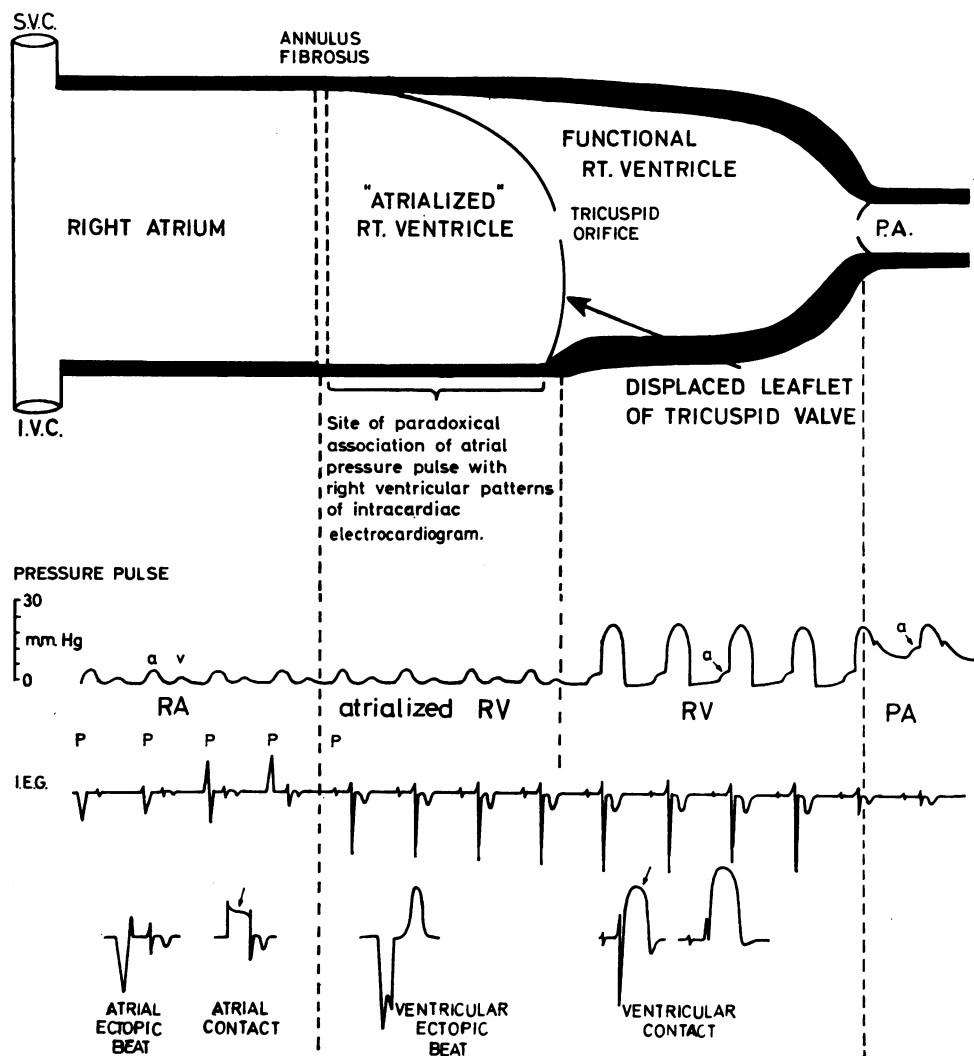


FIG. 13.—Diagram showing the features of the intracardiac electrocardiogram in Ebstein's anomaly and their correlation with the disordered anatomy and pressure pulses.

time in a patient with type B ventricular pre-excitation (Watson and Lowe, 1967). Unusually tall P waves were recorded in the right atrium in some patients. In the patients with complete right bundle-branch block, polyphasic QRS complexes of the type described by Dickens and Goldberg (1958) were recorded in the right ventricle.

#### DISCUSSION

Although the *scalar electrocardiogram* contributes considerably to the diagnosis of Ebstein's anomaly, bizarre right bundle-branch block occurred in only 4 of our 11 cases and the low voltage pattern in the

right praecordial leads (Van Lingen and Bauersfeld, 1955) was present in only 1 of them. Many cases will have only incomplete right bundle-branch block, possibly with prominent P waves or a prolonged P-R interval. The right praecordial QR pattern described by Sodi-Pallares (1956), and rare in the experience of others (Genton and Blount, 1967), was not seen in our series. Type B ventricular pre-excitation may be a clue in diagnosis, and the association of ventricular pre-excitation and right bundle-branch block is almost pathognomonic.

The *vectorcardiogram* is less useful in diagnosis but the horizontal plane is of value in demonstrating

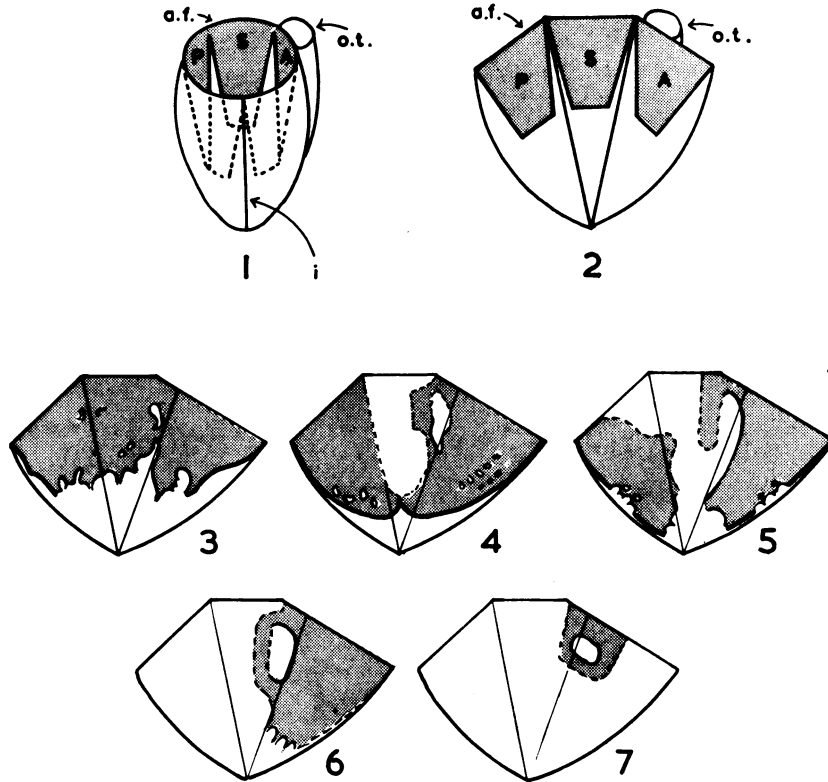


FIG. 14.—Anatomical varieties of the tricuspid valve in Ebstein's anomaly (after Pechstein, 1957).

- (1) Diagrammatic representation of the right ventricle, showing normal arrangements of posterior, septal and anterior cusps of the tricuspid valve (P, S, A), the annulus fibrosus (a.f.), the outflow tract (o.t.) and the line of incision (i.).
- (2) The right ventricle is incised along the line i and laid open to show the normal valve cusps and the endocardium.
- (3-7) Various representative types of Ebstein's anomaly (4 represents Ebstein's original case).

the delta vector of ventricular pre-excitation, which is invariably of type B in Ebstein's anomaly. It is inscribed to the left within the limits set by Bleifer *et al.* (1959) and Tranchesi *et al.* (1959). Cabrera and his colleagues (1962) have emphasized that cases without frank pre-excitation often have an initial slurring of the QRS loop and they have implied that this is an incomplete or partial form of ventricular pre-excitation. We have been unable to confirm this finding.

The vectorcardiogram is also helpful in complementing the scalar lead diagnosis of complete or incomplete right bundle-branch block by demonstrating terminal slowing of the QRS loop from a point anterior and to the right of the origin. This is of particular value when right bundle-branch block is associated with ventricular pre-excitation (Cabrera *et al.*, 1959; Robertson *et al.*, 1963).

We agree with Bilger *et al.* (1961) that there are no specific features in the right bundle-branch block pattern of Ebstein's anomaly.

The *intracardiac electrocardiogram* was useful in confirming the clinical diagnosis, and, in 1 of our patients, first suggested it. However, as Watson (1966) has emphasized, records made with electrode catheters during cardiac catheterization should be considered only along with the other clinical, electrocardiographic, and radiological features of the case, and should not be relied upon as the definitive method of diagnosis of Ebstein's anomaly.

In our series we found that careful exploration of the atrialized ventricle was necessary to demonstrate the ventricular pattern of the intracardiac electrocardiogram. Despite repeated attempts, we were only able to induce ventricular contact currents in the atrialized ventricle in 1 out of 8 cases, and we

found ventricular ectopic beats equally hard to provoke in the same situation. We think, therefore, that these features are not very helpful in the diagnosis of Ebstein's anomaly. Indeed, there are good anatomical reasons for expecting them not to be so.

The important review by Pechstein (1957) of the detailed anatomy of Ebstein's anomaly has not received the attention it deserves. In his description of the tricuspid valve in a large number of cases, the amount of the right ventricular endocardium unprotected by the abnormal valve cusps varied greatly (Fig. 14). In many hearts very little of the endocardium is accessible (examples 3 and 4 in Fig. 14), and in those hearts ventricular S-T elevations could hardly be expected. In some, however, much of the endocardium of the atrialized ventricle is unprotected by valve cusps and is, therefore, accessible to the exploring electrode (examples 6 and 7 in Fig. 14).

#### SUMMARY

The *scalar electrocardiogram* is of considerable diagnostic value in Ebstein's anomaly though it may be normal. There is no stereotyped pattern, but common findings are prominent P waves, a prolonged P-R interval, incomplete or bizarre complete right bundle-branch block, type B ventricular pre-excitation, and dysrhythmias.

Of our 11 patients, only 4 had bizarre right bundle-branch block and only one had the low voltage complexes in right praecordial leads stressed by other authors. Two had normal electrocardiograms.

The *vectorcardiogram*, recorded in 10 cases, was useful in demonstrating the delta wave in cases of ventricular pre-excitation and in confirming the presence of right bundle-branch block, particularly when it was associated with pre-excitation. We have found no evidence of the initial slurring of the QRS loop interpreted by other writers as incomplete ventricular pre-excitation.

The *intracardiac electrocardiogram*, recorded in 8 cases, is not the definitive method of diagnosis, but may give useful confirmatory information. Contrary to a widely held belief, we think that it is extremely uncommon to obtain ventricular contact potentials (S-T elevations) or ventricular ectopic beats from the atrialized portion of the right ventricle, and there are good theoretical reasons why this should be so.

In most cases it is possible to demonstrate the paradoxical association of a right ventricular electrocardiogram with an atrial pressure pulse, but the correct elicitation and interpretation of this important sign demands a full understanding of the limiting factors.

#### REFERENCES

- Bilger, R., So, C. S., Emmrich, J., Steim, H., and Reindell, H. (1961). Über das Elektrokardiogramm und Vektorkardiogramm des Ebstein-Syndroms. *Arch. Kreisf.-Forsch.*, **35**, 238.
- Bleifer, S., Kahn, M., Grishman, A., and Donoso, E. (1959). Wolff-Parkinson-White syndrome. A vectorcardiographic, electrocardiographic and clinical study. *Amer. J. Cardiol.*, **4**, 321.
- Brown, J. W., Heath, D., and Whitaker, W. (1956). Ebstein's disease. *Amer. J. Med.*, **20**, 322.
- Cabrera, E., Feldman, J., and Olinto, F. C. (1959). Estudio electro y vectocardiografico en un caso de Wolff-Parkinson-White con bloqueo de rama derecha. *Arch. Inst. Cardiol. Méx.*, **29**, 404.
- , and Gaxiola, A. (1960). Diagnostic contribution of the vectorcardiogram in hemodynamic overloading of the heart. *Amer. Heart J.*, **60**, 296.
- , —, Ferrer, G., and Costa Rocha, J. (1962). El vectocardiograma en la enfermedad de Ebstein. *Arch. Inst. Cardiol. Méx.*, **32**, 702.
- Cameron, A. J. V., Lawrie, T. D. V., and Wright, J. H. (1959). A twin osciloscopic vectorcardiograph. *Brit. Heart J.*, **21**, 505.
- Danaraj, T. J., and LaBrooy, E. B. (1960). Ebstein's malformation of the tricuspid valve: a report of six cases. *Singapore med. J.*, **1**, 16.
- Dickens, J., and Goldberg, H. (1958). The endocardial lead in complete right bundle-branch block. *Amer. Heart J.*, **56**, 372.
- Edwards, J. E. (1953). Pathologic features of Ebstein's malformation of the tricuspid valve. *Proc. Mayo Clin.*, **28**, 89.
- Emslie-Smith, D., and Lowe, K. G. (1968). The spatial vectorcardiogram in diagnosis. *Postgrad. med. J.*, **44**, 39.
- Engle, M. A., Payne, T. P. B., Bruins, C., and Taussig, H. B. (1950). Ebstein's anomaly of the tricuspid valve. Report of three cases and analysis of clinical syndrome. *Circulation*, **1**, 1246.
- Frank, E. (1956). An accurate, clinically practical system for spatial vectorcardiography. *Circulation*, **13**, 737.
- Frau, G., and Agostoni, A. (1959). L'elettrocardiogramma nella malattia di Ebstein. Morfologia, genesi ed importanza diagnostica. Descrizione di 2 nuovi casi e rassegna di altri 124 casi riportati nella letteratura. *Folia cardiol. (Milano)*, **18**, 223.
- Gamboa, R., Peñaloza, D., Sime, F., and Banchero, N. (1962). The role of the right and left ventricles in the ventricular pre-excitation (WPW) syndrome. An experimental study in man. *Amer. J. Cardiol.*, **10**, 650.
- Gandhi, M. J., and Datey, K. K. (1963). The value of electrophysiologic changes at the tricuspid valve in the diagnosis of Ebstein's anomaly. *Amer. J. Cardiol.*, **12**, 169.
- Gardiner, J. M., and Kay, H. B. (1956). Ebstein's disease. *Alfred Hosp. clin. Rep. (Melbourne)*, **6**, 111.
- Genton, E., and Blount, S. G. (1967). The spectrum of Ebstein's anomaly. *Amer. Heart J.*, **73**, 395.
- Grishman, A., Borun, E. R., and Jaffe, H. L. (1951). Spatial vectorcardiography: Technique for the simultaneous recording of the frontal, sagittal and horizontal projections. *Amer. Heart J.*, **42**, 483.
- Hernandez, F. A., Rochkind, R., and Cooper, H. R. (1958). The intracavitary electrocardiogram in the diagnosis of Ebstein's anomaly. *Amer. J. Cardiol.*, **1**, 181.
- Kezdi, P., and Wennemark, J. (1958). Ebstein's malformation. Clinical findings and hemodynamic alterations. *Amer. J. Cardiol.*, **2**, 200.

- Klienerman, L., Ghită, M., Stefanescu, T., Iliescu, M., Bandu, I., and Gută, G. (1961). L'importance de l'électrocardiographie intracavitaire pour le diagnostic de l'anomalie d'Ebstein, compliquée d'une fibrillation auriculaire. *Cor et vasa (Praga)*, **3**, 231.
- Kossmann, C. E. (1958). *Advances in Electrocardiography*. Grune and Stratton, New York and London.
- Lev, M., Gibson, S., and Miller, R. A. (1955). Ebstein's disease with Wolff-Parkinson-White syndrome: report of a case with a histopathologic study of possible conduction pathways. *Amer. Heart J.*, **49**, 724.
- Lowe, K. G., and Watson, H. (1968). In *Paediatric Cardiology*, p. 441. Ed. by Hamish Watson. Lloyd-Luke, London.
- Mayer, F. E., Nadas, A. S., and Ongley, P. A. (1957). Ebstein's anomaly. Presentation of 10 cases. *Circulation*, **16**, 1057.
- Moles, S. S., Jacoby, W. J., Jr., and McIntosh, H. D. (1964). Ebstein's malformation. Discordant intracavitary electrocardiographic and pressure relationship. *Amer. J. Cardiol.*, **14**, 720.
- Pechstein, J. (1957). Beitrag zur Ebsteinschen Anomalie der Valvula tricuspidalis. *Arch. Kreis.-Forsch.*, **26**, 282.
- Robertson, P. G. C., Emslie-Smith, D., Lowe, K. G., and Watson, H. (1963). The association of type B ventricular pre-excitation and right bundle-branch block. *Brit. Heart J.*, **25**, 755.
- Rosenbaum, F. F., Hecht, H. H., Wilson, F. N., and Johnston, F. D. (1945). The potential variations of the thorax and the esophagus in anomalous atrioventricular excitation (Wolff-Parkinson-White syndrome). *Amer. Heart J.*, **29**, 281.
- Schiebler, G. L., Adams, P., Jr., and Anderson, R. C. (1959a). The Wolff-Parkinson-White syndrome in infants and children. A review and a report of 28 cases. *Pediatrics*, **24**, 585.
- , ———, ———, Amplatz, K., and Lester, R. G. (1959b). Clinical study of twenty-three cases of Ebstein's anomaly of the tricuspid valve. *Circulation*, **19**, 165.
- Sodi-Pallares, D. (1956). *New Bases of Electrocardiography*, p. 272. Mosby, St. Louis.
- , and Marsico, F. (1955). The importance of electrocardiographic patterns in congenital heart disease. *Amer. Heart J.*, **49**, 202.
- Steim, H., So, C. S., Emmrich, J., and Bilger, R. (1962). Das Ebstein-Syndrom. *Ergebn. inn. Med. Kinderheilk.*, n.s. **17**, 58.
- Sterz, H., Schreiner, B., Hübl, W., Hinrichs, R., and Rosanelli, K. (1960). Diagnostische Schwierigkeiten bei der Ebsteinschen Anomalie. *Z. Kreis.-Forsch.*, **49**, 67.
- Tranchesi, J., Guimarães, A. C., Teixeira, V., and Pileggi, F. (1959). Vectorial interpretation of the ventricular complex in Wolff-Parkinson-White syndrome. *Amer. J. Cardiol.*, **44**, 334.
- Vacca, J. B., Bussmann, D. W., and Mudd, J. G. (1958). Ebstein's anomaly. Complete review of 108 cases. *Amer. J. Cardiol.*, **2**, 210.
- Van Lingen, B., and Bauersfeld, S. R. (1955). The electrocardiogram in Ebstein's anomaly of the tricuspid valve. *Amer. Heart J.*, **50**, 13.
- Watson, H. (1966). Electrode catheters and the diagnosis of Ebstein's anomaly of the tricuspid valve. *Brit. Heart J.*, **28**, 161.
- , Emslie-Smith, D., and Lowe, K. G. (1967). The intracardiac electrocardiogram of human atrioventricular conducting tissue. *Amer. Heart J.*, **74**, 66.
- , and Lowe, K. G. (1967). Intracavitary potentials in type B ventricular pre-excitation. *Brit. Heart J.*, **29**, 505.
- Yater, W. M., and Shapiro, M. J. (1937). Congenital displacement of the tricuspid valve (Ebstein's disease): review and report of a case with electrocardiographic abnormalities and detailed histologic study of the conduction system. *Ann. intern. Med.*, **11**, 1043.
- Yim, B. J. B., and Yu, P. N. (1958). Value of an electrode catheter in diagnosis of Ebstein's disease. *Circulation*, **17**, 543.
- Zakopoulos, K. S., Tsatas, A. T., and Liokis, T. E. (1964). Type B Wolff-Parkinson-White syndrome associated with right bundle-branch block. *Dis. Chest*, **46**, 346.