

## Pacemaker 'Heart Sound'

ALAN HARRIS

*From the Cardiac Department, St. George's Hospital, Hyde Park Corner, London S.W.1*

Artificial pacing of the heart may alter the order of closure of the mitral and tricuspid valves and pulmonary and aortic valves depending on the site of the myocardial electrode (Haber and Leatham, 1965). In some patients on artificial pacemakers we have also noticed an extra sound, always earlier, and sometimes louder, than the usual heart sounds, and it has been found to occur with both epicardial and endocardial systems (Nager *et al.*, 1965). This extra sound can be heard, and more often recorded, 6 m.sec. after the pacemaker impulse is recorded on the electrocardiogram. In addition, an early outward systolic movement can be recorded in the apex cardiogram coinciding with the extra sound. Nager *et al.* (1965) concluded that the extra sound was possibly of intracardiac origin related to premature contraction of the heart muscle underlying the electrode. This implies that heart muscle could behave in an abnormal way in respect to its known electromechanical interval which is 21 m.sec. for conducted beats (Tafur, Cohen, and Levine, 1964) and contravenes the "all or none law" (Bowditch, 1871). In view of the physiological importance of these findings, the pacemaker heart sound has been further investigated.

### SUBJECTS AND METHODS

In 6 patients with chronic heart block on artificial pacemakers a four-channel photographic oscilloscope\* was used to record the extra sound, together with a second phonocardiogram, external carotid pulse, respiration, and electrocardiogram at a paper speed of 100 m.sec./cm. The apex cardiogram was recorded in the left lateral decubitus position, with the breath held at the end of expiration. One patient was also studied by intracardiac phonocardiography and pressure recordings. In order to measure the interval between the pacemaker

impulse and extra sound with greater accuracy, high-speed phonocardiograms were also recorded on a measuring oscilloscope at a speed of 5 m.sec./cm. and 10 m.sec./cm.

Five of the patients were being paced with a C.50 No. 5 unipolar electrode† positioned in the apex of the right ventricle: in four of them the pacemaker and positive electrode were buried in the axilla and in the fifth patient the C.50 No. 5 unipolar electrode was exteriorized in the left mammary region and attached to an external pacemaker unit, and the positive electrode was implanted in the subcutaneous tissue overlying the left pectoral muscle. The sixth patient was paced with an electrode placed on the epicardium of the left ventricle at thoracotomy and attached to an implanted abdominal pacemaker unit. The units were of the constant voltage type, the no-load voltage being 5 volts, and powered by 3 or 4 mercury batteries giving a square wave impulse of 0.7 to 1 m.sec. at a fixed rate of 75 a minute.

### RESULTS

A typical recording of the extra sound (X) is shown in Fig. 1. The extra sound may be louder than any of the other heart sounds, and on inspiration it tends to diminish in intensity and is best heard in the mitral and tricuspid areas. Occasionally on auscultation the first sound may be quite soft and almost inaudible, so that the extra sound may be mistaken for the first heart sound, giving the impression of an abnormally long interval between the first and second heart sounds (Fig. 2). The apex cardiogram usually shows an early systolic outward movement, the onset of which coincides with the extra sound (Fig. 2), and less commonly is the only recorded movement (Fig. 3). High-speed phonocardiograms were recorded and the interval between the pacemaker stimulus and the onset of the extra sound was found to be 6 m.sec. (Fig. 4).

Received November 30, 1966.

\* Cambridge Instrument Company of England.

† U.S. Catheter Corporation.

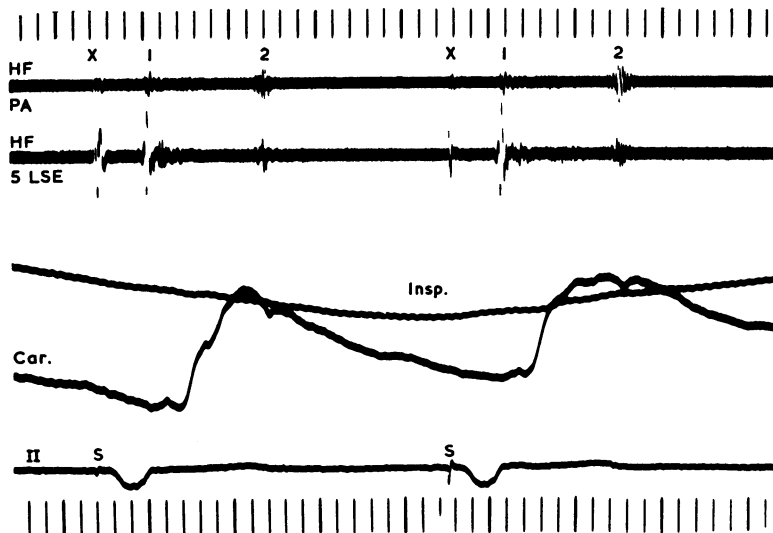


FIG. 1.—Endocardial pacing from the right ventricular cavity with an implanted axillary pacemaker, demonstrating the extra sound (X) which decreases in intensity on inspiration. The time intervals in this and subsequent records, unless otherwise stated, are 0.20 and 0.04 sec. External phonocardiograms: PA, pulmonary area; LSE, left sternal edge; 1, first heart sound; 2, second heart sound; Insp., inspiration; II, lead II of electrocardiogram; S, pacemaker stimulus; HF, high frequency; Car., external carotid pulse.

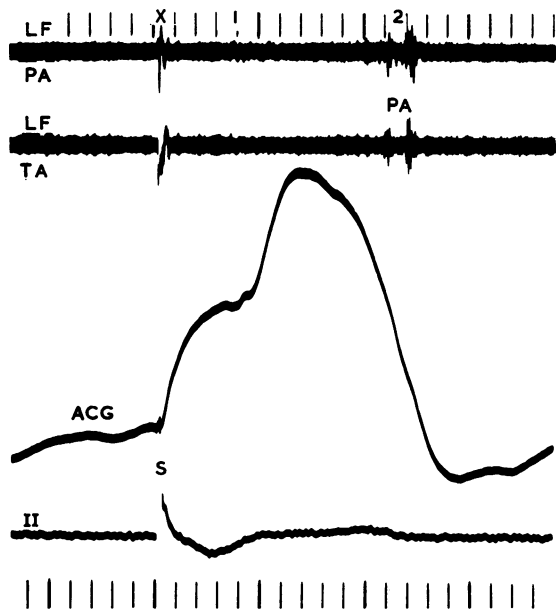


FIG. 2.—An early outward movement of the apex cardiogram (ACG) coincides with the extra sound (X) which is relatively loud compared with the first heart sound. LF, low frequency; TA, tricuspid area.

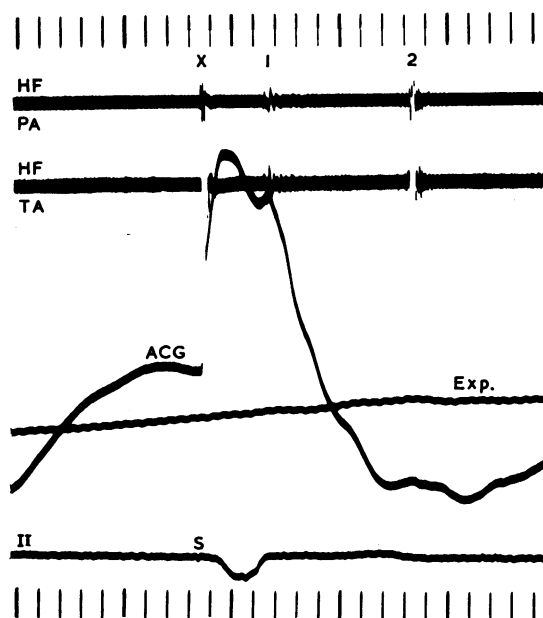


FIG. 3.—The outward movement of the apex cardiogram is the only movement recorded. Exp., expiration.

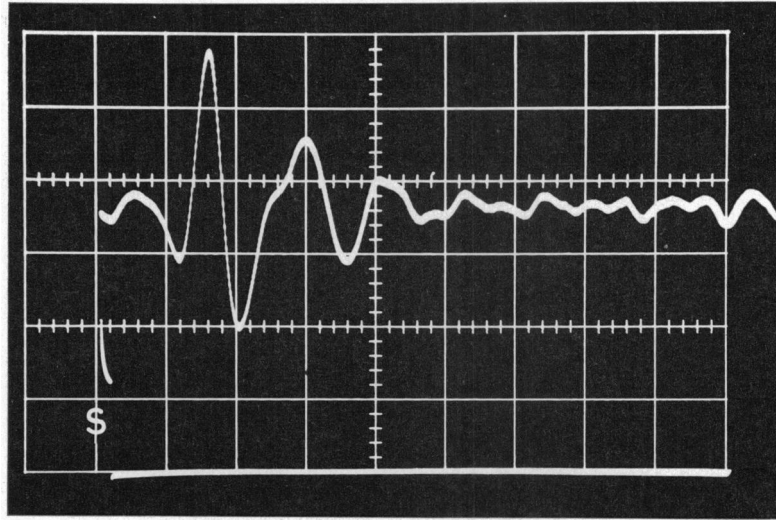


FIG. 4.—High-speed phonocardiogram recorded on a measuring oscilloscope showing the time interval between the pacemaker stimulus and the onset of the extra sound to be 6 m.sec. Time intervals are 5 and 1 m.sec.

An electro-mechanical interval of 6 m.sec. is of the same order as that of skeletal muscle and the possibility that diaphragmatic contraction was the source of the extra sound was considered. However, x-ray screening of the patients did not reveal any abnormal diaphragmatic contraction, and this was also the finding of Nager *et al.* (1965). It was possible to reproduce the extra sound and early apical movement in one patient by implanting the positive electrode of the pacing system in the left pectoral muscle overlying the apex of the heart.

This patient had visible and palpable contractions of the pectoral muscle with every pacemaker stimulus, and recordings were obtained with (Fig. 5A) and without (Fig. 5B) pectoral muscle stimulation. Pectoral muscle stimulation resulted in an extra sound and early systolic movement (Fig. 5, 6, and 7), which were similar in timing (8 m.sec.) to the extra sound and apical movement recorded in the other 5 patients. Phonocardiograms were recorded over the implanted pacemaker units and positive electrodes in these 5 patients to see if local muscle con-

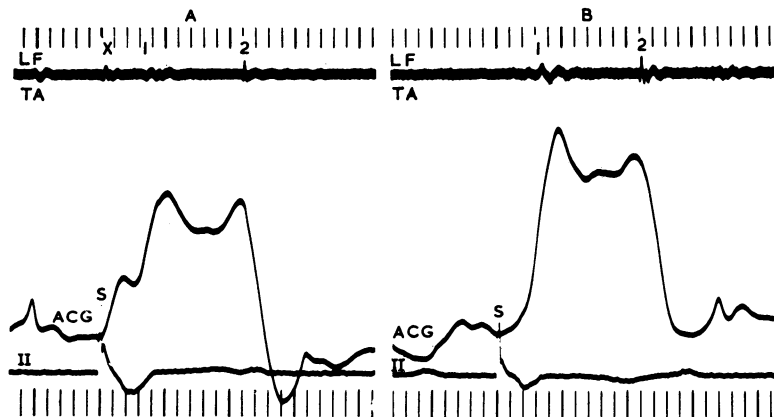


FIG. 5(A).—Unipolar endocardial pacing with a positive electrode implanted in the left pectoral muscle. The extra sound (X) is produced by pectoral muscle contraction and coincides with an early outward movement of the apex cardiogram.

FIG. 5(B).—Bipolar endocardial pacing abolished the extra sound and early movement of the apex cardiogram.

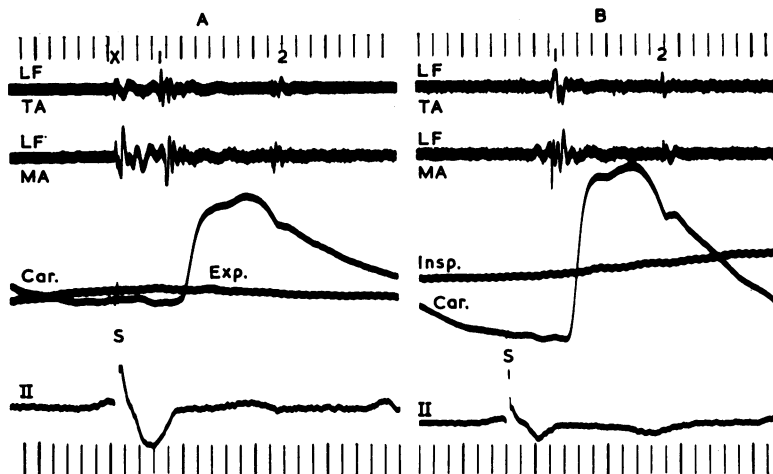


FIG. 6(A).—Unipolar endocardial pacing with a positive electrode implanted in the left pectoral muscle. The extra sound (X) is produced by pectoral muscle contraction.  
 FIG. 6(B).—Bipolar endocardial pacing abolished the extra sound. MA, mitral area.

traction was causing the extra sound, but no sound was present (Fig. 8).

Since the extra sound coincided with an early outward systolic movement of the apex cardiogram it would presumably be associated with an early rise in ventricular pressure if arising from the ventricle. During the routine change of an implanted axillary pacemaker the opportunity was taken to obtain intracardiac phonocardiograms and pressure recordings in one patient with an obvious extra sound, and it was found that the right ventricular pressure trace

did not show any evidence of an early rise in pressure (Fig. 9), nor was the extra sound recorded within the cavity of the right ventricle. The external carotid pulse recording was also normal, excluding the possibility that the left ventricle was producing an early rise in pressure. In the refractory phase of ectopic beats the extra sound still followed the pacemaker impulse, despite the absence of a right ventricular pressure pulse (Fig. 10). Hence it seemed almost certain that the extra sound was not cardiac in origin and must be related to pacemaker-induced

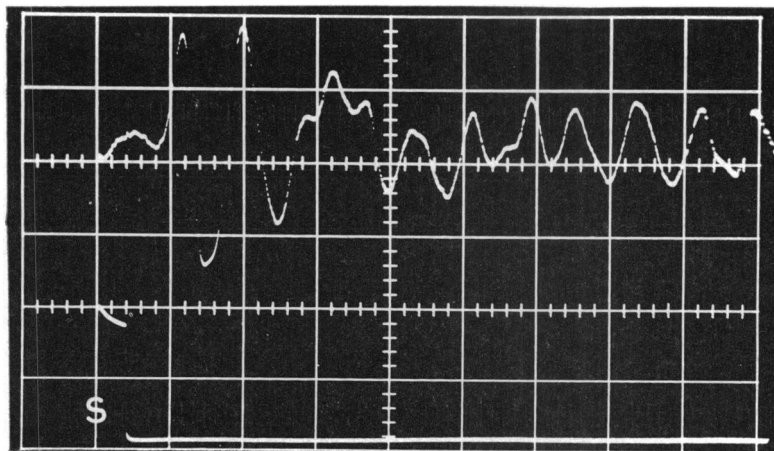


FIG. 7.—High-speed phonocardiogram recorded on a measuring oscilloscope, showing the time interval between the pacemaker stimulus and the onset of the sound produced by pectoral muscle contraction to be 8 m.sec. Time intervals 10 and 2 m.sec.

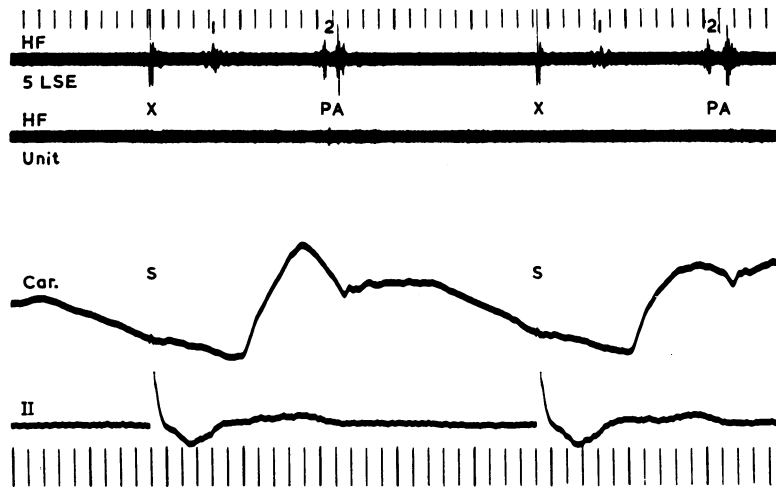


FIG. 8.—Phonocardiogram recorded over the implanted axillary pacemaker unit and positive electrode, showing absence of any sound, though present at the fifth left intercostal space.

contraction of skeletal muscle overlying the myocardial electrode. Thus, during the course of the general anaesthetic, the patient was given a neuromuscular blocking agent (suxamethonium chloride), and this was found to abolish the extra sound (Fig. 9).

It also seemed likely that the position of the electrode tip might be critical, since current was presumably spreading to the adjacent intercostal nerves. In one patient the position of the endocardial electrode could be altered without loss of right ventricular stimulation, as indicated by the heart sounds (Fig. 11), and yet the extra sound could be abolished.

#### DISCUSSION

The results of this investigation show that the extra sound produced by electrical pacing of the heart is due to spread of current to the nearby intercostal nerves producing intercostal muscle contraction. Nager *et al.* (1965) considered that the abolition of the extra sound, when the pacemaker impulse fell in the refractory period of a normal conducted beat and therefore failed to stimulate the heart, must indicate that the sound was due to premature heart contraction, but this was not confirmed in this present study (Fig. 10). One possible explanation for this difference in findings is the interpreta-

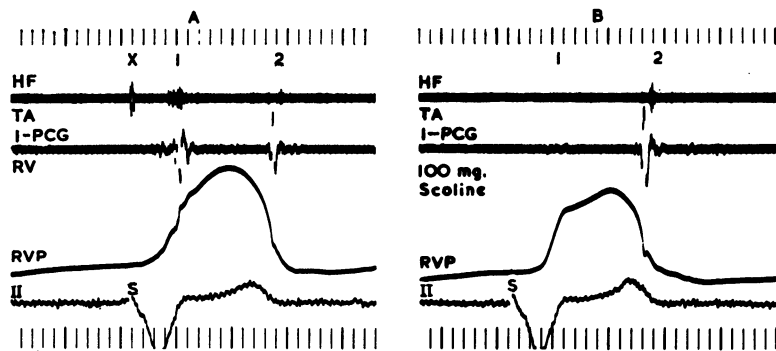


FIG. 9.—Intracardiac phonocardiogram (I-PCG) recorded in the right ventricle (RV) simultaneously with the right ventricular pressure (RVP) failed to record the extra sound which was shown on the external phonocardiogram. The extra sound shown on the external phonocardiogram in (A) is abolished by intravenous suxamethonium chloride (B).

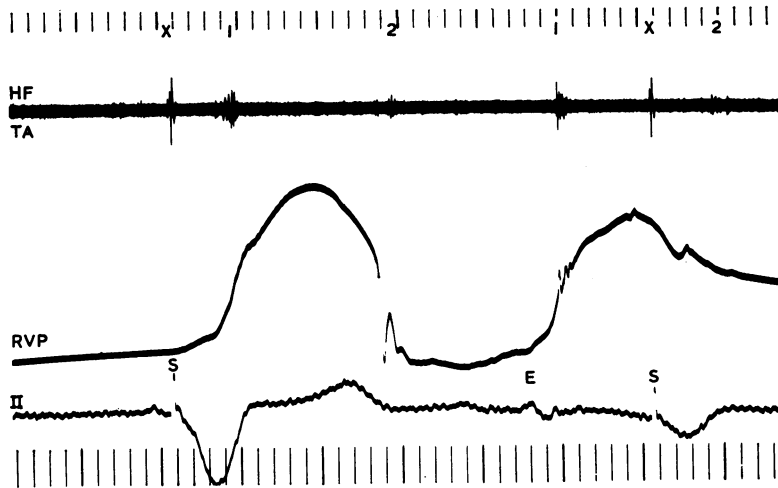


FIG. 10.—The external phonocardiogram shows the extra sound coinciding with a pacemaker impulse during the second cycle which is due to a ventricular ectopic beat (E). The first cycle is a normal paced beat.

tion of the phonocardiograms which Nager *et al.* (1965) used to illustrate this point. It is possible that the extra sound was coinciding with the first heart sound in the section showing competition between sinus rhythm and pacemaker rhythm. In another patient, Nager *et al.* (1965) were unable

satisfactorily to explain, on the basis of the premature heart contraction, the continuation of the extra sound when pacing was intermittent. The probable explanation of their findings in this patient was that the threshold for pacing had risen, resulting in intermittent pacing of the heart, but the threshold for

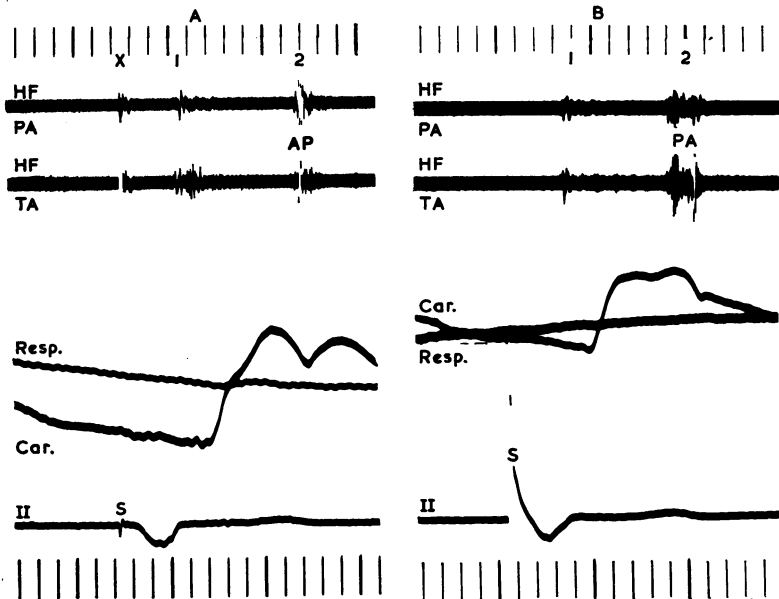


FIG. 11.—External phonocardiograms before (A) and after (B) repositioning the right ventricular endocardial unipolar electrode, showing abolition of the extra sound. In (A), pacing is causing physiological closure of the second sound indicating that the left ventricle is being stimulated before the right. In (B), closure of the second sound is reversed, which is the normal sequence of events in right ventricular endocardial pacing. A, aortic component; P, pulmonary component.

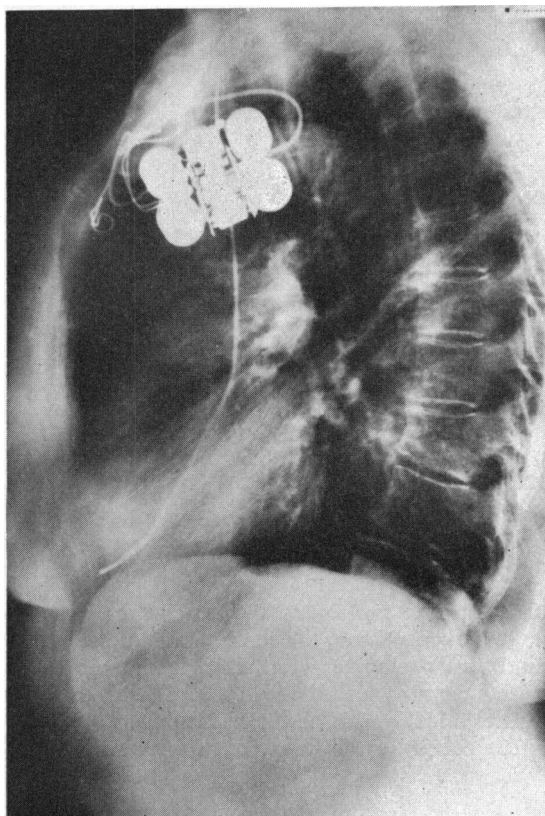


FIG. 12.—Lateral chest x-ray film showing the proximity of the endocardial electrode tip to the anterior chest wall.

stimulation of the intercostal nerves adjacent to the myocardial electrode may not have altered and thus the extra sound continued to be recorded.

Nager *et al.* (1965) considered the possibility that skeletal muscle stimulation might be responsible for the extra sound and that the diaphragm would be its likely source. Abnormal diaphragmatic contraction was not observed on x-ray screening, which was confirmed in this present study, and they concluded that skeletal muscle was unlikely to be the source of the extra sound. Intercostal muscle contraction causing the extra sound is in fact too localized to be apparent on x-ray screening. From time to time, however, endocardial pacing does result in diaphragmatic stimulation (Harris *et al.*, 1965), and patients are always aware of this, and it is of interest that none of the patients with extra sound studied were aware of the localized intercostal muscle contraction.

The position of the myocardial electrode is presumably fairly critical for stimulation of the intercostal nerves, since by repositioning the endocardial electrode the extra sound could be abolished (Fig. 11). Lateral chest x-ray films of two patients, one

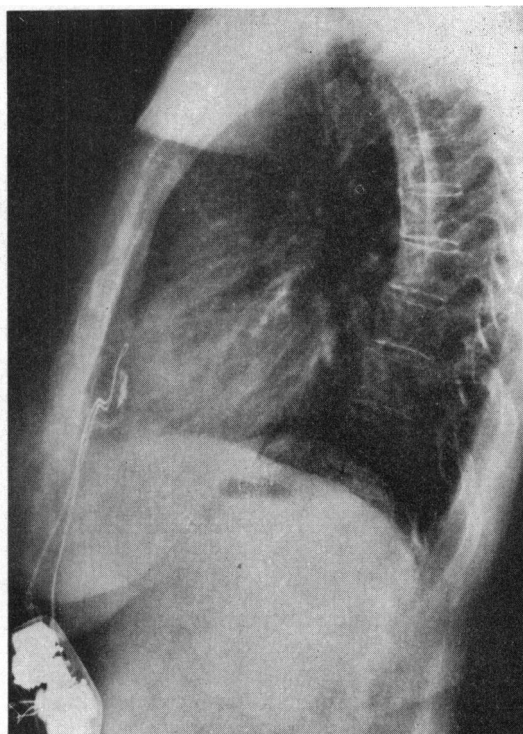


FIG. 13.—Lateral chest x-ray film showing the proximity of the epicardial electrode to the anterior chest wall.

with an endocardial electrode and the other with an epicardial electrode, are shown in Fig. 12 and 13 and demonstrate the proximity of the electrode to the chest wall. Chest wall movement during inspiration away from the electrode could account for the decrease in intensity of the extra sound, since under these circumstances spread of current would be expected to stimulate fewer intercostal nerve fibres owing to the greater separation of the electrode from the chest wall. Respiratory variation in the intensity of the extra sound should only occur with low power units, and the more powerful units would be expected to produce an extra sound of constant intensity during inspiration. The early systolic movement of the apex cardiogram is localized over the apex beat of the heart, which is the region where the endocardial and epicardial electrodes are usually positioned. The localized intercostal muscle contraction gives a false impression of an early outward movement of the heart.

The failure to record any premature rise in ventricular pressure or intracardiac sound coinciding with the extra sound, and the abolition of the extra sound by a neuromuscular blocking agent, forms conclusive evidence of an extracardiac source for this sound and of its origin from contraction of skeletal muscle.

## SUMMARY

Many patients on artificial pacemakers have an extra heart sound which is always earlier, and often louder, than the usual heart sounds. Five patients with this extra sound have been studied by external phonocardiograms and apex cardiograms, and one by intracardiac phonocardiography and pressure recordings.

The extra sound occurred 6 m.sec. after the pacemaker impulse was recorded on the phonocardiogram, and was accompanied by an early outward movement of the apex cardiogram, but was not associated with premature ventricular pressure rise, nor could it be recorded within the right ventricle during right ventricular endocardial pacing.

The extra sound continued to occur when the pacemaker impulse fell in the refractory period of ventricular ectopic beats, and could be abolished by a neuromuscular blocking agent or by repositioning the endocardial electrode. It was concluded that the extra sound was due to stimulation of intercostal nerves adjacent to the epicardial or endocardial

electrode and was not due to premature contraction of cardiac muscle.

I wish to thank Dr. Aubrey Leatham for his helpful advice in the preparation of this paper.

## REFERENCES

- Bowditch, H. P. (1871). Über die Eigenthümlichkeiten der Reizbarkeit, welche die Muskelfasern des Herzens zeigen. *Ber. sächs. Ges. Wiss. (Math.-phys. classe)*, **23**, 652.
- Haber, E., and Leatham, A. (1965). Splitting of heart sounds from ventricular asynchrony in bundle-branch block, ventricular ectopic beats, and artificial pacing. *Brit. Heart J.*, **27**, 691.
- Harris, A., Bluestone, R., Busby, E., Davies, G., Leatham, A., Siddons, H., and Sowton, E. (1965). The management of heart block. *Brit. Heart J.*, **27**, 469.
- Nager, F., Bühlmann, A., Schaub, F., Schwarz, H., and Senning, A. (1965). Auskultatorische und kardiographische Befunde bei Patienten mit implantiertem elektrischem Schrittmacher. *Klin. Wschr.*, **43**, 1232.
- Tafur, E., Cohen, L. S., and Levine, H. D. (1964). The normal apex cardiogram. Its temporal relationship to electrical, acoustic, and mechanical cardiac events. *Circulation*, **30**, 381.