

## CASE REPORTS

# Duplication of the Tricuspid Valve

A. SÁNCHEZ CASCOS, P. RÁBAGO, AND M. SOKOLOWSKI

*From the Cardiac Department, Fundación Jiménez Díaz, Madrid, Spain*

Duplication of an atrio-ventricular valve is a rare anomaly. In most instances the double, or even triple, atrio-ventricular orifice is on the left side—the so-called “double mitral valve” (Hartmann, 1937; Wimsatt and Lewis, 1948; Schraft and Lisa, 1950; Prior, 1953; Wigle, 1957; Pachaly and Schultz, 1962; Edwards *et al.*, 1965). Only exceptional cases of “double tricuspid valve” have been described (Sinapius, 1954; Pachaly and Schultz, 1962; Neufeld *et al.*, 1960; Edwards *et al.*, 1965). Another is reported here and a second is briefly reported.

### *Case Reports*

*Case 1.* This 11-month-old boy had been deeply cyanosed from birth and was subject to frequent cyanotic attacks. On examination he was an underdeveloped child with central cyanosis and slight clubbing. A coarse systolic thrill was felt over the præcordium, associated with a grade 5/6 pansystolic murmur, with its maximum intensity in the mitral and tricuspid areas. There was also an early diastolic triple rhythm; the second sound was single.

The electrocardiogram showed gross right atrial and ventricular hypertrophy patterns, with right axis deviation. The chest *x*-ray film showed an extremely large, globular heart with ischæmic lung fields. The blood count showed no polycythæmia or other abnormality.

The electrocardiographic picture was thought to exclude tricuspid atresia or Ebstein's disease. Pulmonary atresia, with an intact ventricular septum and tricuspid incompetence, seemed the most likely diagnosis. The patient's condition was very poor, with daily cyanotic attacks, and the possibility of surgical relief was considered. Angiocardiography was, therefore, performed. The catheter entered the right atrium which was shown to be enormously dilated, occupying more than half the cardiac silhouette, and then passed to the left atrium and ventricle; it could not be manipulated into the right ventricle. An injection of opaque medium into the left ventricle showed an intact ventricular septum, mild

mitral incompetence (probably produced by the presence of the catheter), and a small atrial septal defect, possibly a foramen ovale.

A Brock procedure for pulmonary valve dilatation was performed (G. Rábago) and an atretic or near atretic valve was opened to give an outlet to the right ventricular outflow tract. The immediate result was good, with relief of cyanosis, but the child died suddenly 24 hours later with cardiac arrest.

Necropsy was limited to the heart. It weighed 110 g. Externally there was a very large right atrium but the ventricles and great vessels appeared normal. The right atrial wall was hypertrophied, and there was a small ostium secundum septal defect. The tricuspid valve, from its atrial aspect (Figure A) presented two orifices, one anterior and the other lateral, with its medial half occupied by a rigid diaphragmatic septal cusp. Between the two orifices there was a fibrous band from the middle of the septal cusp to the lateral border of the fibrous annulus. The anterior orifice was roughly triangular, about 1.5 cm. across; its anterior edge had a normal anterior valve cusp whose chordæ arose from a normal Lancisi's muscle. The lateral orifice was much smaller (less than 5 mm. across), and was guarded by two rudimentary cusps attached to chordæ arising from two small accessory papillary muscles. Attached by a delicate fibrous network to the atrial aspect of the septal cusp was a small (5 mm.) white nodule (Figure B). Histological examination of the nodule revealed a hyaline constitution and the network seemed to be an atypically placed rest of the Chiari network.

The right ventricle was of normal size but its wall was hypertrophied; the septum was intact. The pulmonary valve had been opened to produce a 5 mm. orifice, but the cusps were fused. The left atrium and ventricle were normal, but the lateral cusp of the mitral valve had short chordæ attached directly to the ventricular wall, resulting in mild incompetence of the valve. The aorta and pulmonary artery were normal and the ductus arteriosus had closed.

*Case 2.* This 17-year-old boy is only briefly mentioned here, as he was an example of Ebstein's disease,

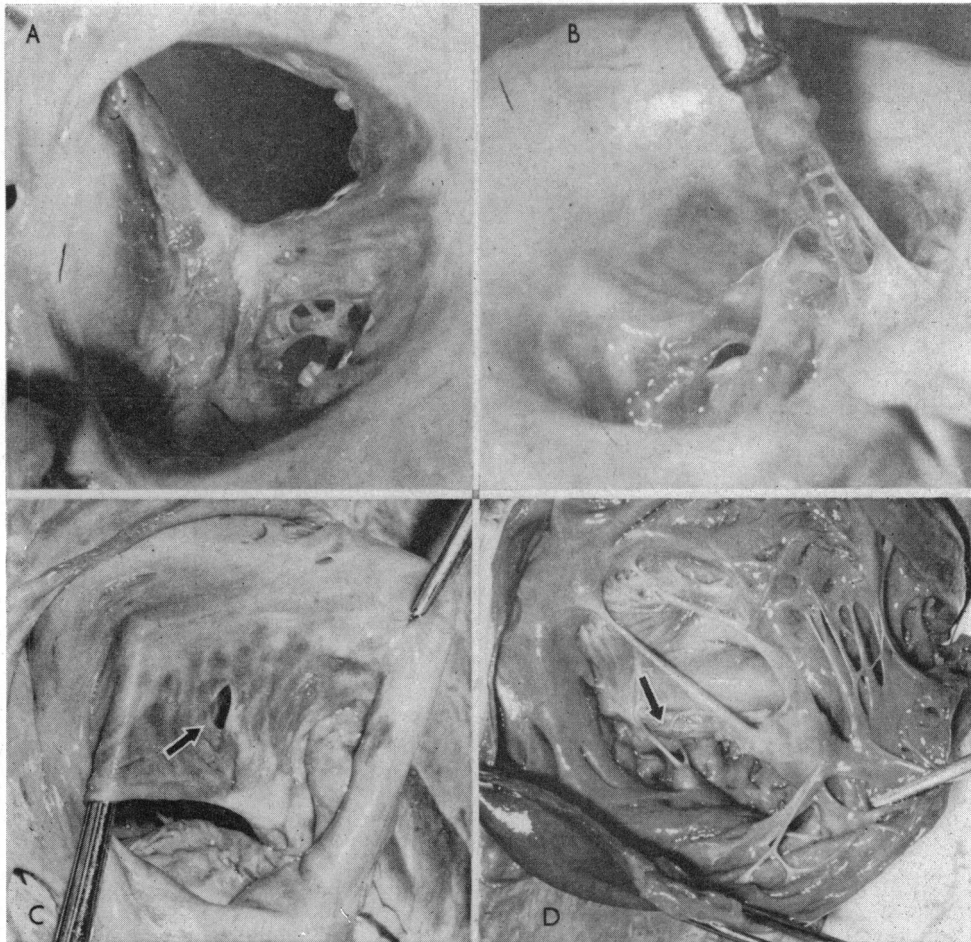


FIG.—A.—*Case 1*: tricuspid valve, right atrial view, showing bigger anterior orifice, and smaller lateral one. B.—*Case 1*: rudimentary atrial network and hyaline tubercle on the tricuspid valve. C.—*Case 2*: tricuspid valve, atrial view. The arrow points to the hole on the anterior leaflet. D.—*Case 2*: tricuspid valve, ventricular view. The arrow marks the site of the hole, under which a rudimentary papillary muscle and two small chordæ are seen.

and will be reported as such elsewhere. He presented with slight dyspnoea on exertion and præcordial pain. On auscultation a triple rhythm and a pansystolic murmur were heard. The electrocardiogram showed large P waves with right bundle-branch block and a Q wave from V1-4. The cardiac outline on the chest x-ray film was globular and the lung fields were oligæmic. Cardiac catheterization was attempted, but the patient developed ventricular fibrillation which resisted correction.

Necropsy of the heart revealed a large right atrium with a typical Ebstein's anomaly of the tricuspid valve which had a normal attachment of the anterior cusp, while the septal cusp was attached 2-5 cm. below the annulus fibrosus; the posterior cusp was rudimentary. The anterior cusp had a 4 mm. hole in its medial part

(Figure C); two small chordæ arising from a rudimentary papillary muscle were attached to the ventricular aspect of this hole (Figure D).

#### Discussion

Hartmann (1937) was the first to attempt a classification of the varieties of double atrio-ventricular valve. He distinguished three types: (1) Type L ("Loch"), in which the secondary orifice is defined by a constriction in the anterior commissure. This orifice has two cusps attached to chordæ tendineæ arising from the anterior papillary muscle. (2) Type B ("Brucke"), in which the two orifices are separated by a fibrous band; each is associated

with one papillary muscle. (3) Type S ("Sonderstellung"), in which the separation of the orifices is more complete and each has an independent set of chordæ and a papillary muscle.

In this classification Type L is distinct from the other two, but the latter are less well separated. There is another variety which has not been included, so that a better classification would be as follows.

(A) *Commissural type* (Hartmann's type L) in which the accessory orifice is at the end of a valve commissure and its subvalvar apparatus (chordæ and papillary muscle) is the normal one for that commissure, though sometimes accessory papillary muscles may be present.

(B) *Central type* (Hartmann's types B and S). A fibrous band divides the atrio-ventricular orifice into either equal or unequal parts.

(C) *Hole type*. In this variety the accessory orifice is a hole in a cusp. This form of double valve orifice is to be distinguished from a simple fenestration or cleft which has no subvalvar apparatus. It is essential for the identification of duplication of a valve that both orifices should be provided with a subvalvar apparatus, though this may be rudimentary for one of them.

On the basis of this classification, Case 1 is an example of the *central type* and Case 2 of the *hole type*.

The syndrome of pulmonary atresia or extreme stenosis with intact ventricular septum is well known. Greenwold *et al.* (1956) and more recently Davignon *et al.* (1961) have emphasized the occurrence of two anatomical types, depending upon the status of the tricuspid valve. In the commoner type I, both right ventricle and tricuspid valve are minute; these hearts typically present anomalous connexions between the coronary arteries and the right ventricular cavity through persistent coronary sinusoids.

The rarer type II has a right ventricle which is normal or enlarged, with a tricuspid valve which is deformed and incompetent. The deformity often resembles that of the Ebstein's anomaly (Davignon *et al.*, 1961; Elliott, Adams, and Edwards, 1963; Caddell and Whittemore, 1963). In other cases there is a less specific abnormality or an absence of tricuspid valve tissue which produces valvar incompetence (Davignon *et al.*, 1961; Benton *et al.*, 1962; Elliott *et al.*, 1963; De Rábago *et al.*, 1964; Kanjuh *et al.*, 1964). To our knowledge, duplication of the tricuspid valve has not hitherto been reported in this condition.

Fenestration of the tricuspid valve in Ebstein's

anomaly has been described (Baker, Brinton, and Channell, 1950), but here the distinction between a simple fenestration without any subvalvar apparatus and duplication of the orifice with such apparatus, as in Case 2, has to be made.

### Summary

An example of a double tricuspid valve occurring in association with pulmonary atresia and an intact ventricular septum is reported. A second case in association with Ebstein's anomaly of the valve is briefly mentioned.

A classification of the different varieties of duplication of an atrio-ventricular valve orifice is proposed.

We are indebted to Dr. Dennis Deuchar, of the Cardiac Department, Guy's Hospital, London, who kindly revised the text and gave us valuable suggestions.

### References

- Baker, C., Brinton, W. D., and Channell, G. D. (1950). Ebstein's disease. *Guy's Hosp. Rep.*, **99**, 247.
- Benton, J. W., Elliott, L. P., Adams, P., Anderson, R. C., Hong, C. Y., and Lester, R. G. (1962). Pulmonary atresia and stenosis with intact ventricular septum. *Amer. J. Dis. Child.*, **104**, 161.
- Caddell, J. L. and Whittemore, R. (1963). Pulmonary atresia with dilated right ventricle. A case with congenital atrial flutter. *Amer. J. Cardiol.*, **12**, 254.
- Davignon, A. L., Greenwold, W. E., DuShane, J. W., and Edwards, J. E. (1961). Congenital pulmonary atresia with intact ventricular septum. Clinicopathologic correlation of two anatomic types. *Amer. Heart J.*, **62**, 591.
- De Rábago, P., Sokolowski, M., Sánchez Cascos, A., and Varela de Seijas, J. R. (1964). El síndrome de atresia o estenosis extrema de arteria pulmonar con tabique interventricular normal. *Rev. esp. Cardiol.*, **17**, 352.
- Edwards, J. E., Carey, L. S., Neufeld, H. N., and Lester, R. G. (1965). *Congenital Heart Disease. Correlation of Pathologic Anatomy and Angiocardiography*. Saunders, Philadelphia and London.
- Elliott, L. P., Adams, P., Jr., and Edwards, J. E. (1963). Pulmonary atresia with intact ventricular septum. *Brit. Heart J.*, **25**, 489.
- Greenwold, W. E., DuShane, J. W., Burchell, H. B., Bruwer, A., and Edwards, J. E. (1956). Congenital pulmonary atresia with intact ventricular septum: two anatomic types. Proc. 29th Sci. Sess., Amer. Heart Ass., page 51. (Abstract in *Circulation*, **14**, 945 (1956).)
- Hartmann, B. (1937). Zur Lehre der Verdoppelung des linken Atrioventrikularostiums. *Arch. Kreis.-Forsch.*, **1**, 286.
- Kanjuh, V. I., Stevenson, J. E., Amplatz, K., and Edwards, J. E. (1964). Congenitally unguarded tricuspid orifice with coexistent pulmonary atresia. *Circulation*, **30**, 911.
- Neufeld, H. N., McGoon, D. C., DuShane, J. W., and Edwards, J. E. (1960). Tetralogy of Fallot with anomalous tricuspid valve simulating pulmonary stenosis with intact septum. *Circulation*, **22**, 1083.

- Pachaly, L., and Schultz, H. (1962). Zur formalen Genese der angeborenen Lückenbildungen der Atrioventrikularklappen des Herzens. *Frankfurt Z. Path.*, **71**, 531.
- Prior, J. T. (1953). Congenital anomalies of the mitral valve. Two cases associated with long survival. *Amer. Heart J.*, **46**, 649.
- Schraft, W. C., and Lisa, J. R. (1950). Duplication of the mitral valve. Case report and review of the literature. *Amer. Heart J.*, **39**, 136.
- Sinapius, D. (1954). Angeborene Tricuspidalinsuffizienz infolge eines Defektes im vorderen Klappensegel. *Frankfurt. Z. Path.*, **65**, 459.
- Wigle, E. D. (1957). Duplication of the mitral valve. *Brit. Heart J.*, **19**, 296.
- Wimsatt, W. A., and Lewis, F. T. (1948). Duplication of the mitral valve and a rare apical interventricular foramen in the heart of a yak calf. *Amer. J. Anat.*, **83**, 67.