

SHORT REPORT

MRI in cerebral toxocaral disease

Petra Rüttinger, Hussein Hadidi

Abstract

Toxocara canis, the common round-worm in the dog, can cause "visceral larva migrans" syndrome in humans, which may include generalised illness, eosinophilia, and symptoms arising from larval invasion of different organs. Of these, the clinically most important are liver, lungs, eyes and CNS. Involvement of the different parts of the CNS in human toxocaral disease has been described, but not the CT or MRI appearances of the cerebral lesions. In one case with a single focal epileptic fit, CT was described as normal. In the *Toxocara canis* case described, the cerebral lesions on MRI, before and after therapy, are shown.

Case report

A 26 year old woman, presenting with a single generalised epileptic seizure, was admitted to our hospital on 18 July 1989. Plain CT scan showed irregular spots of high density (230-280 HU) behind the fourth ventricle, without oedema or space-occupying effect, suggesting a calcification. In addition, there were two isodense lesions about 10 mm in diameter, surrounded by a hypodense area which might represent a perifocal oedema. One was in the left upper parietal and one in the left occipitoparietal region.

The patient lived in a rural region in close contact with cats and dogs. There was no history of overseas travel. Neurological examination was completely normal. Laboratory investigations showed an eosinophilia of 6% in 9100 white blood cells. Gamma-GT was elevated at 48 U/l. All other routine blood tests were normal. An EEG showed a regular alpha-activity of 10 per second with an intermittent slight focal slowing in the right temporo-parietal region.

Cranial MRI on 28 July (Siemens, 1.0 Tesla) showed approximately 25 lesions situated mainly cortically or subcortically, which had a hyperintense, cloudy irregular appearance on proton density and T₂-weighted images and were 1-2 cm in diameter. None of the lesions could be seen in the T₁-weighted sequences without gadolinium. After intravenous gadolinium-DTPA (20 ml = 0.2 mmol/kg bw) all lesions showed intense contrast-enhancement in their centres (fig 1A). The size of the area of enhancement was smaller than the lesions in the T₂-weighted

images suggesting the presence of a perifocal oedema. An additional lesion, situated behind the fourth ventricle, had a hypointense portion on proton density, T₁- and T₂-weighted

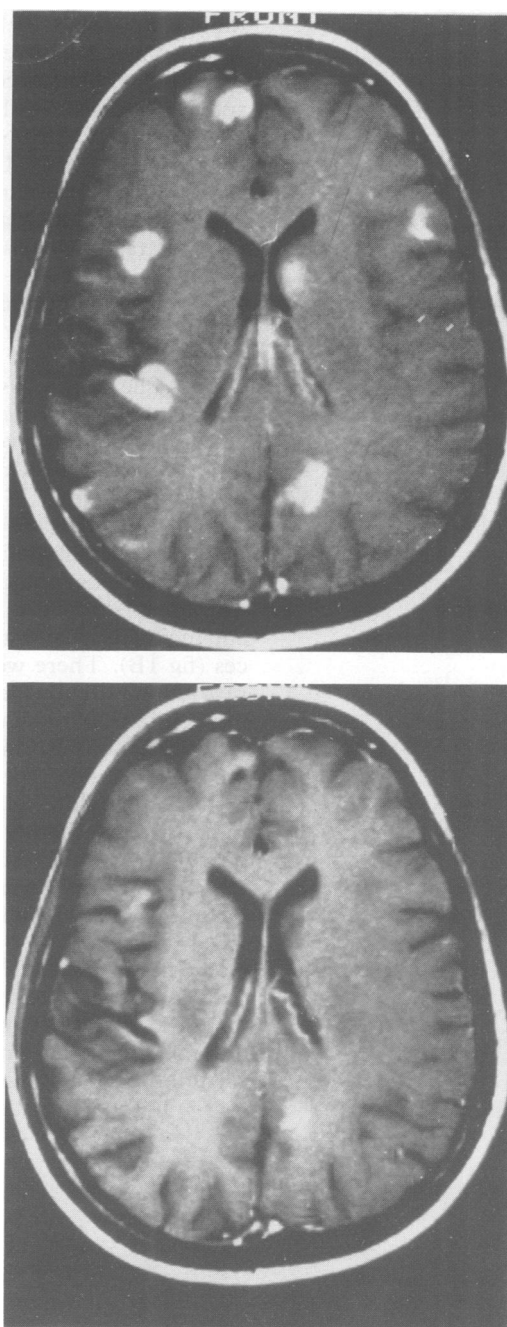


Figure Cranial MRI, gadolinium-enhanced T₁-weighted sequences TE 600 ms, TR 15 ms; A) Before therapy and B) after therapy.

University of
Saarland, Homburg/
Saar, Germany
Department of
Neurology
P Rüttinger

Department of
Neuroradiology
H Hadidi

Correspondence to:
Dr Rüttinger,
Universitäts-Nervenlinik-
Neurologie, D-6650
Homburg/Saar, Germany

Received 27 April 1990
and in revised form
13 August 1990.

Accepted 30 August 1990

images suggesting the presence of a perifocal oedema. An additional lesion, situated behind the fourth ventricle, had a hypointense portion on proton density, T₁- and T₂-weighted images, which may resemble the calcified structure on the CT scan. This lesion also showed a small area of gadolinium-enhancement. An MRI of the liver, abdominal ultrasound, chest radiograph and an ophthalmological examination were normal.

A lumbar puncture on 2 August yielded 19 white cells per mm³, which were only mononuclear cells, a protein level of 47 mg per 100 ml and normal glucose. The blood-CSF-barrier was slightly disturbed (CSF albumin × 1000/serum albumin = 6.8) there was no evidence of locally synthesised IgG. Identical gammaglobulin bands could be detected in the CSF and serum. Spinal fluid microscopy for bacteria, tubercle bacilli and fungi was negative. Serological examination revealed negative titres for toxoplasmosis, cysticercosis, echinococcosis and schistosomiasis and Lyme disease. The antibody-titre against *Toxocara canis* was positive in serum, negative in CSF (ELISA 12 U, IHA 1:40, Bernhard-Nocht-Institute, Hamburg. Titres of this level indicate either past or current mild infection). Paragonomiasis-titre was positive 1:10 as a crossreaction. HIV-1- and HIV-2-antibodies and HIV-antigen were negative.

The patient was treated with diethylcarbamazine (Hetrazan[®]) for a period of four weeks. The dose was slowly increased from 75 mg/day up to 250 mg/day. Side effects were nausea, occasional vomiting and headache. The only additional medication administered were antiepileptics. She received no steroids. A follow up MRI on 11 September showed a marked reduction mainly in size of the lesions on proton density and T₂-weighted images as well as a reduction in number and size of the enhancing lesions on the T₁-weighted sequences (fig 1B). There were no new lesions. The involution of the lesions was even more marked in the follow up study on 25 October. An analysis of CSF immediately after therapy on 9 September revealed no change. On 27 October the white cells were reduced to 4 per mm³, while all other CSF parameters were nearly unchanged. An analysis of serum and CSF antibody-titre for *Toxocara canis* on 27 October showed no change.

Conclusion

This is the first report of MRI in cerebral toxocaral disease. Our diagnosis is based on the positive *Toxocara* titre in ELISA and IHA and on the marked reduction of number

and activity (contrast-enhancement) of the lesions on MRI as well as on the improvement of CSF parameters under antihelminthic therapy. We believe this striking recovery is quite unlikely to be the spontaneous course of the disease.

Prevalence of *Toxocara* infestation of dogs and the resulting contamination of the ground is relatively high in many countries all over the world. Reported data range from three to 81% for dog infestation and 0.3 to 87% for soil contamination. The results of sensitive and specific serological tests suggest that about 7% of the clinically healthy human population of the United States, 5% of the population in Canada and 4% of that of the United Kingdom are infected with the parasite. Recent data are not available for Western Germany.⁴

How often the CNS is involved in human toxocaral disease is not clear. Case reports on clinically overt brain invasion by the larvae in the form of acute meningitis, encephalitis, myelitis etc are rare.¹⁻³ On the other hand, the percentage of cases in which granulomatous lesions lead to subacute symptoms such as headaches or occasional epileptic fits is a matter for debate. Eosinophilia and *Toxocara* titre are of limited help for diagnosis and in measuring the success of treatment, because they are often negative or borderline in pure cerebral infestation and can remain positive for months and years after the symptoms subside.³

What kind of drug should be used and what effect can be expected is still a controversial point.^{1,5} MRI may be the best way to assess the success of treatment and to follow the course of the disease, which is otherwise very difficult or impossible, especially in patients with occasional seizures. Gadolinium-enhanced MRI can even help to decide about the necessity of treatment, as a disturbed blood-brain-barrier points to an active inflammation.

We thank Professors Büttner and Mannweiler (Bernhard-Nocht-Institute, Hamburg, Germany) for their help and for carrying out the parasitological tests.

- 1 Brain R, Allan B. Encephalitis due to infection with *Toxocara canis*. *Lancet* 1964;i:1355-7.
- 2 Huismans H. Larva migrans visceralis (*Toxocara canis*) und Zentrales Nervensystem (ZNS). *Nervenarzt* 1980;51: 718-24.
- 3 Müller-Jensen A, Schall J, Weisner B, Lamina J. Eosinophile Meningo-enzephalo-myelitis und viszerales Syndrom durch Askaridenlarven beim Erwachsenen. *Dtsch med Wschr* 1973;98:1175-7.
- 4 Barriga OO. A critical look at the importance, prevalence and control of toxocarosis and the possibilities of immunological control. *Vet Parasitol* 1988;29:195-234.
- 5 Taylor MRH, Keane CT, O'Connor P. The expanded spectrum of toxocaral disease. *Lancet* 1988;i(8587):692-5.