

Pure akinesia: an atypical manifestation of progressive supranuclear palsy

Hidenori Matsuo, Hidetoshi Takashima, Masao Kishikawa, Ikuo Kinoshita, Masataka Mori, Mitsuhiro Tsujihata, Shigenobu Nagataki

Abstract

Two patients with "pure akinesia" who showed the characteristic changes of progressive supranuclear palsy (PSP) at necropsy are described. They had akinesia but no rigidity or tremor, and ophthalmoplegia was not observed during the course of illness. The symptoms of "pure akinesia" was not improved by levodopa therapy but was considerably improved by L-threo-3,4-dihydroxyphenylserine. At necropsy, pathological findings were not different from those reported for PSP. It is suggested that "pure akinesia" is an atypical manifestation of PSP, and that norepinephrinergic neurons may be involved in some types of PSP.

"Pure akinesia" is a rare syndrome characterised by the freezing of gait and pulsion symptoms without rigidity or tremor, and by lack of response to levodopa therapy.^{1,2} Several reports have shown L-threo-3,4-dihydroxyphenylserine (L-DOPS), a synthetic precursor of norepinephrine (NE), to be dramatically effective in treating this condition.^{3,4} This suggests that the norepinephrinergic neurons of the central nervous system (CNS) may be part of the neurochemical background of the disease. "Pure akinesia" therefore has been seen as a new condition or specific form of Parkinsonism.^{1,4,5} As there have been few anatomical studies, the classification of this syndrome is still not clear.

We report the cases of two patients who showed "pure akinesia" and who had good responses to L-DOPS as a clinical manifestation, but who on postmortem examination were found to have had progressive supranuclear palsy (PSP).

Case reports

Patient 1

A 72 year old man developed gait disturbance and started to have frequent falls due to difficulty in initiating movement. He also showed micrographia and festinating speech. A neurological examination showed a lack of facial expression but no associated tremor or rigidity. His eye movements were full, and his tendon reflexes and planter responses were normal, but he had frozen gait which disappeared when he was asked to step forward over the blocks on the floor and to go up or down the staircase (Kinésie paradoxale), and pulsion symptoms. There was no evidence of

dementia. A CT scan revealed mild cerebral atrophy and dilatation of the third ventricle. Levodopa was given for several months without benefit. During the next year there was further deterioration in his gait, with episodes of freezing during the initiation of gait and on turning. The freezing phenomenon dramatically improved when he underwent L-DOPS therapy (600 mg/day); the time of initial hesitation in walking decreased considerably and micrographia improved. Two years after the onset of his illness, he died of oesophageal cancer.

Patient 2

A 62 year old man with no history of neurological disease noticed an increasingly frequent inability to open his eyes. Over the next two years, he developed frozen gait and had frequent falls. His eye symptom and gait disturbance persisted despite treatment with carbidopa-levodopa and with trihexyphenidyl. At a neurological examination two years before his death, he showed a mask-like face and apraxia on opening his eyelids. No restriction of eye movement or ptosis was observed. His speech was low pitched and monotonous, and often festinating. There was no evidence of dementia, rigidity or tremor. His gait was considerably disturbed, freezing occurring on the initiation of movement and on turning. Pulsion symptoms were observed in each direction. An examination of his cerebrospinal fluid and an electroencephalogram showed no abnormality. A CT scan disclosed mild cerebral atrophy. After treatment with L-DOPS (600 mg/day), the time required to open his eyelid decreased from more than four minutes to less than 30 seconds, and his frozen gait improved slightly. One year later, he showed mild dementia and marked bradykinesia. Magnetic resonance imaging revealed no further abnormality except minimal atrophy of the tegmentum of the midbrain (fig 1). Six months before his death he developed a persistent cough; a chest radiograph disclosed lung cancer. A neurological examination two weeks before his death revealed no abnormality in his oculomotor function, and no axial rigidity or tremor.

Neuropathological findings

The brains of the two patients weighed 1125 and 1180 gm. Gross examinations of both brains showed no external abnormalities, apart from a degree of atrophy that was mainly in the frontal lobe. The sections

Nagasaki University,
School of Medicine,
Nagasaki
First Department of
Internal Medicine

H Matsuo
H Takashima
I Kinoshita

S Nagataki
Department of
Pathology, Scientific
Data Centre for the
Atomic Bomb
Disaster

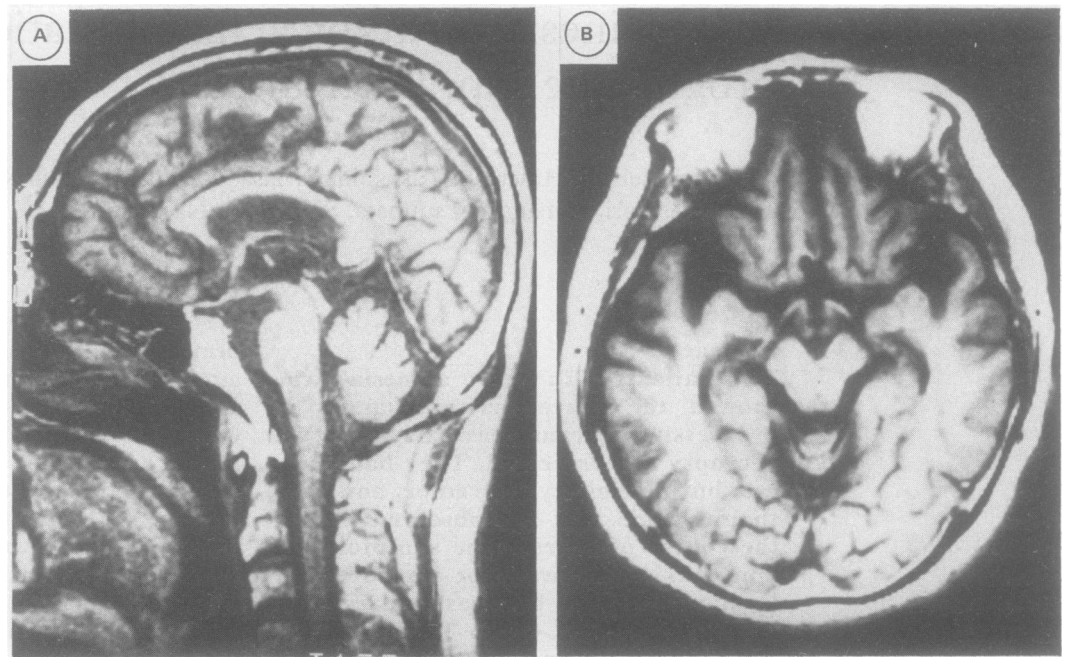
I Kishikawa*
The School of Allied
Medical Sciences
M Tsujihata

National Nagasaki—
Chuo Hospital, Omura
Department of
Neurology
M Mori

Isahaya Insurance
General Hospital,
Isahaya, Japan
Department of
Internal Medicine*

Correspondence to: Dr
Nagataki, First Department
of Internal Medicine,
Nagasaki University School
of Medicine, 7-1 Sakamoto-
machi, Nagasaki 852, Japan.
Received 24 July 1990.
Accepted 20 September
1990.

Figure 1 MRI of the brain (Patient 2). No specific lesion is present, only minimal atrophy of the tegmentum of midbrain and slight dilatation of the ventricles. (a) sagittal T1-weighted image, TR = 500, TE = 30; b) axial proton density image, TR = 2000, TE = 20).



showed that the ventricular system in each brain was slightly to moderately dilated. Both brains showed a slightly brownish colour change of the globus pallidum, the subthalamic nucleus, and marked depigmentation of the substantia nigra. There was mild atrophy in the pontine tegmentum in patient 2, but no colour change in the locus ceruleus.

Several tissue blocks were taken from the cerebral cortex, basal ganglia, thalamus with subthalamic nucleus, hippocampus, nucleus basalis of Meynert and cerebellum with dentate nucleus of both brains. The brainstem was sampled at several levels. Sections 8 μ m thick were cut and stained with Hematoxylin and eosin (H and E), Nissl, Bielschowsky-Hirano's silver, Bodian, Glial fibrillary acidic protein (GFAP), Holzer, Mallory's phosphotungstic acid hematoxylin (PTAH), Luxol fast blue, S-100 protein, Congo red or periodic acid-Schiff (PAS) stain. To identify senile plaques or neurofibrillary tangles (NFTs), paraffin sections were immunostained with anti- β protein or anti-tau.⁶⁻⁸

Selected structures were evaluated semiquantitatively (table).

In both cases microscopic examinations revealed the characteristic changes associated with PSP: cell loss, gliosis and neurofibrillary degeneration in a typical distribution (table). The cerebral cortex showed only mild cell loss with few senile plaques and no NFTs. In contrast, severe degeneration associated with cell loss, gliosis and NFTs had taken place in the globus pallidum, subthalamic nucleus, substantia nigra and pontine tegmentum (fig 2). In addition, many neuropil threads were present in the substantia nigra in both brains (fig 3). There was no apparent cell loss in the locus ceruleus, but many intracellular NFTs showed up on anti-tau immunostaining. Vacuolar degeneration was seen in the oculomotor nucleus and abducent nucleus in patient 2. There were no Lewy bodies in either brain.

Discussion

The freezing phenomenon as the predominant

Table Neuropathological findings

	Patient 1			Patient 2			
	Brain weight (gm)	Cell loss	Gliosis	NFTs	Cell loss	Gliosis	NFTs
Brain weight (gm)	1,125			1,180			
Cerebral cortex	\pm	-	-	\pm	-	-	
Putamen	+	+	+	+	+	+	+
Globus pallidum	++	++	++	++	++	++	+++
Nucleus basalis of Meynert	+	++	+	+	++	++	++
Thalamus	+	+	+	+	+	+	+
Paraventricular nucleus	\pm	+	\pm	\pm	+	+	+
Subthalamic nucleus	++	++	+	++	++	+	+
Hippocampus	-	-	+	-	-	-	+
Substantia nigra	+++	+++	+++	+++	+++	+++	+++
Oculomotor nucleus	+	+	+	+	+	+	++
Interstitial nucleus of Cajal	ND	ND	ND	\pm	+	+	+
Periaqueductal matter	+	+	++	+	++	++	++
Pontine tegmentum	+	++	++	+	++	+++	+++
Locus ceruleus	\pm	+	++	-	+	++	++
Pontine nucleus	-	\pm	+	-	\pm	+	+
Dentate nucleus	+	++	+	+	++	+	+

NFTs = neurofibrillary tangles; - = negative or none; \pm = fair or rare; + = mild or occasional; ++ = moderate or considerable; +++ = severe or frequent; ND = not done.

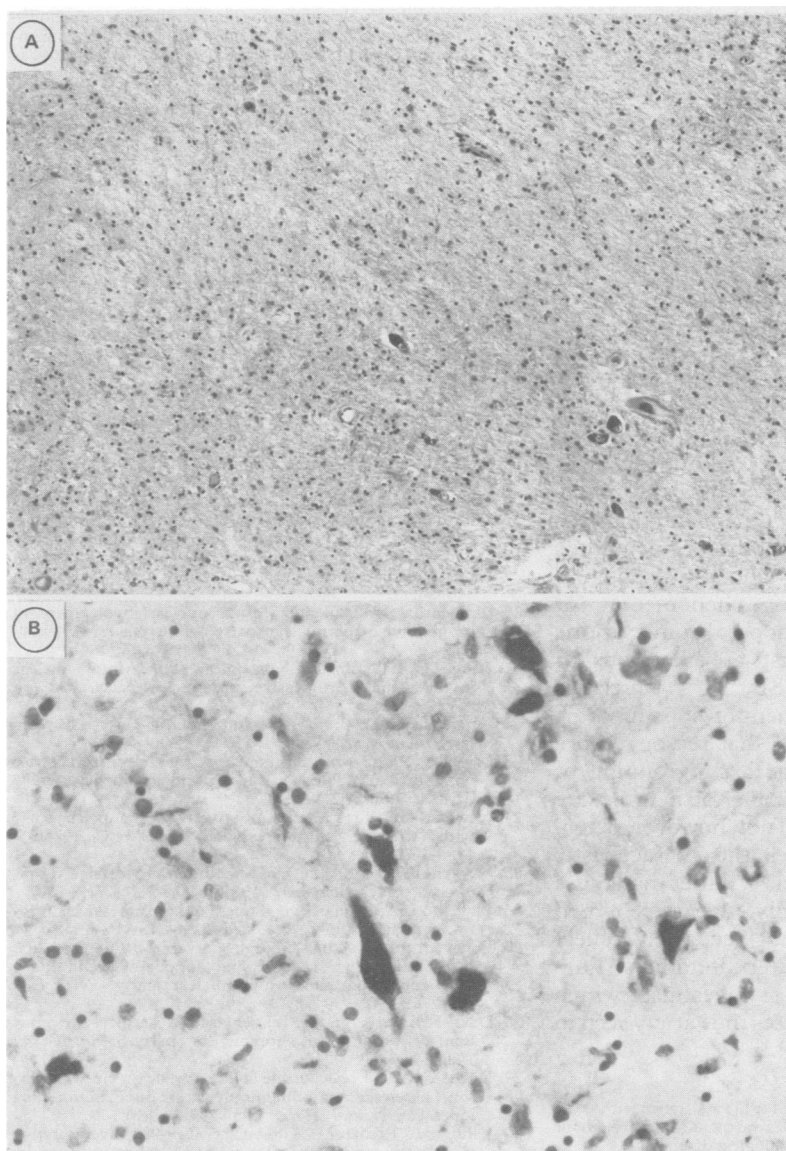


Figure 2 a) Patient 2. Marked cell loss and gliosis in the substantia nigra (H&E $\times 95$). b) Patient 1. Neurofibrillary tangles in the pontine tegmentum (Anti-tau stain, demelanisation, $\times 380$).

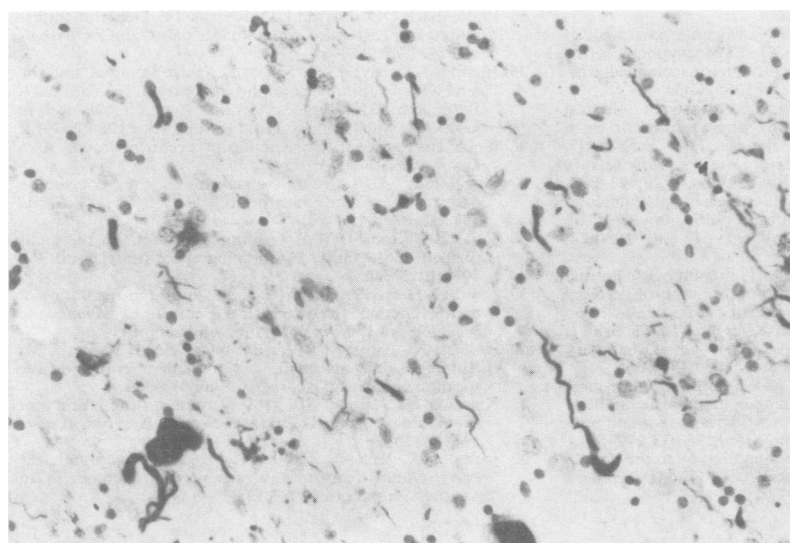


Figure 3 A large number of neuropil threads and neurofibrillary tangles in the substantia nigra. Patient 2. (Anti-tau, demelanisation, $\times 380$).

feature of akinesia is usually associated with the following conditions: 1) an almost pure akinetic syndrome without rigidity or tremor (as reported by Barbeau⁹), for which levodopa is effective and which suggests a deficiency of dopamine in the striatum; 2) pure akinesia characterised by the freezing phenomenon with no rigidity or tremor (as reported by Narabayashi *et al*¹), in which the lack of response to levodopa treatment suggests that it is unlikely that a deficiency in dopamine is the cause; 3) long-standing Parkinsonism treated chronically with levodopa;¹⁰⁻¹² and 4) the freezing phenomenon related to bradykinesia, itself. In our cases, no symptoms indicative of Parkinsonism other than akinesia were observed, nor did the freezing phenomenon improve when levodopa therapy was given. This corresponds to the "pure akinesia" reported by Narabayashi *et al*.

Only one or two pathological studies of this condition have been reported. Honma *et al* reported the necropsy examination of a patient with PSP who manifested initially "pure akinesia", but later also showed supranuclear ophthalmoplegia.¹³ They also reported that two other patients with "pure akinesia" developed dementia, supranuclear ophthalmoplegia, pseudobulbar palsy and nuchal rigidity during their illnesses which lasted for more than 10 years, and emphasised that PSP may be an underlying disease of pure akinesia.¹⁴ Quinn *et al* recently reported a case of pure akinesia produced by Lewy body Parkinson's disease,¹⁵ which responded to levodopa but not to L-DOPS, which indicated that it differed from the "pure akinesia" described by Narabayashi *et al*.¹ The pathological findings of our cases resemble those of Honma *et al* and are consistent with previous reports of PSP,^{9 16-22} even though no clinical signs indicative of PSP were found.

PSP has been described as a distinct clinicopathological entity,¹⁶ but several unusual symptoms have been reported that include torticollis, blepharospasm, dysfluency, apraxia of eyelid opening and the freezing phenomenon.²³⁻²⁸ Several pathology reports have also described PSP with no eye movement disorder during the patient's life²⁸⁻³² and cases in which there was a delay in ophthalmoplegia of up to 12 years.³²⁻³⁴ Furthermore, features similar to those of "pure akinesia" have been present in cases described by Steel *et al*,¹⁶ and by Davis *et al*.²⁸ In a small number of patients with PSP, "pure akinesia" may be the only symptom in the early stage of the illness. Most of the reported cases of "pure akinesia" are atypical presentations of PSP. In fact, neuro-otological examinations of three patients with "pure akinesia" have disclosed supranuclear ophthalmoplegia that suggests cerebellar and midbrain tegmental involvement.³⁵

L-DOPS treatment had a beneficial effect on each of our patients. The frozen gait and micrographia of patient 1 improved, and the apraxia of eyelid opening (which seems to be a freezing phenomenon because of the difficulty in initiating the act of opening the eyelid³⁶) and the frozen gait of patient 2 improved. The

efficacy of L-DOPS suggests that the norepinephrinergic neurons are involved in this condition. Norepinephrinergic neurons are distributed widely throughout the CNS: in the cerebral cortex, hypothalamus, limbic system, globus pallidum, cerebellum, spinal cord and the locus ceruleus.^{37,38} Some are assumed to affect movement by regulating the drive components of motility, posture and locomotion.³⁹ Because the highest NE concentration is in the CNS, the lesion of the locus ceruleus may be responsible for "pure akinesia,"³⁸ whereas we found only mild involvement with NFTs. Recently Koller *et al* transplanted autologous adrenal medullary cells to the caudate nuclei of three patients with PSP.⁴⁰ It is worth noting that one patient showed marked improvement of his postural instability, but the pharmacological basis of this transplantation was not documented. Norepinephrinergic neurons may be involved in PSP and cause postural instability or the freezing phenomenon (or "pure akinesia"). Levodopa, bromocriptine and other dopamine agonists are efficacious for some symptoms of PSP,^{22,41-42} which is indicative of the involvement of dopaminergic neurons or receptors. For that reason, "pure akinesia" may actually be a subgrouping of PSP, in which norepinephrinergic neurons are deeply involved. We could not, however, determine which lesion causes the characteristic symptoms of "pure akinesia", rather than those of typical PSP. Probably the stereotyped pathological lesions do not accurately reflect underlying neurotransmitter alterations. Further studies are planned to investigate which transmitter deficiency causes the variety seen in the clinical picture of PSP.

We thank Dr Hiromasa Kuratsune for his assistance with these investigations, and Drs Yoshihisa Kawase and Masahiro Ito for their helpful comments on the pathological diagnosis.

- 1 Narabayashi H, Imai H, Yokochi M, *et al*. Cases of pure akinesia without rigidity and tremor and with no effect by L-Dopa therapy. In: Birkmayer W, Hornykiewicz O, eds. *Advances in parkinsonism*. Basel: Roche, 1976:335-42.
- 2 Narabayashi H. Clinical analysis of akinesia. *J Neural Transm* 1980;suppl 16:334-42.
- 3 Yamamoto M, Ujike H, Ogawa N. Effective treatment of pure akinesia with L-threo-3,4-dihydroxyphenylserine (DOPS): Report of a case, with pharmacological considerations. *Clin Neuropharmacol* 1985;8:334-42.
- 4 Narabayashi H, Kondo T, Yokochi F, Nagatsu T. Clinical effects of L-threo-3,4-dihydroxyphenylserine in cases of parkinsonism and pure akinesia. In: Yahr MD, Bergmann KJ, eds. *Parkinson's disease (Advances in neurology, vol 45)*. New York: Raven Press, 1986:593-602.
- 5 Imai H. Syndrome of pure akinesia or freezing phenomenon without rigidity and tremor and with no effect by L-DOPA therapy. *Adv Neurol Sci (Tokyo)* 1980;24:838-48.
- 6 Kitamoto T, Ogomori K, Tateishi J, Prusiner SB. Formic acid pretreatment enhances immunostaining of cerebral and systemic amyloidosis. *Lab Invest* 1987;57:230-7.
- 7 Ryong-Woon Shin, Ogomori K, Kitamoto T, Tateishi J. Increased tau accumulation in senile plaques as a hallmark in Alzheimer's disease. *Am J Pathol* 1989;134:1365-71.
- 8 Yen S-H, Horopian DS, Terry RD. Immunocytochemical comparison of neurofibrillary tangles in senile dementia of Alzheimer type, progressive supranuclear palsy, and postencephalic parkinsonism. *Ann Neurol* 1983;13:172-5.
- 9 Barbeau A. Contribution of levodopa therapy to the neuropharmacology of akinesia. In: Siegfried J, ed. *Parkinson's disease*. Bern: Hans Huber, 1972:157-74.
- 10 Narabayashi H, Nakamura R. The freezing phenomenon—problems in long-term L-dopa treatment for parkinsonism. In: Rose FC, Capildeo R, eds. *Research progress in Parkinson's disease*. Tunbridge Wells, Kent: Pitman Medical, 1981:1057-63.
- 11 Ambani LM, Van Woert HM. Start hesitation—a side effect of long-term levodopa therapy. *N Engl J Med* 1973;288:1113-5.
- 12 Barbeau A. Six years of high-level levodopa therapy in severely akinetic parkinsonian patients. *Arch Neurol* 1976;33:333-8.
- 13 Honma Y, Takahashi H, Takeda S, Ikuta F. An autopsy case of progressive supranuclear palsy showing "pure akinesia without rigidity and tremor and with no effect by L-DOPA therapy (Imai)". *Brain Nerve (Tokyo)* 1987;39:183-7.
- 14 Yuasa T, Honma Y, Takahashi H, *et al*. Progressive supranuclear palsy with pure akinesia as an initial symptom. *Neurological Medicine (Tokyo)* 1987;26:460-7.
- 15 Quinn NP, Luthert P, Honavar M, Marsden CD. Pure akinesia due to Lewy body Parkinson's disease: a case with pathology. *Mov Disord* 1989;4:85-9.
- 16 Steele JC, Richardson JC, Olszewski J. Progressive supranuclear palsy. *Arch Neurol* 1964;10:333-59.
- 17 Steel JC. Progressive supranuclear palsy. *Brain* 1972;95:693-704.
- 18 Tagliavini F, Pilleri G, Gemignani F, Lechi A. Neuronal loss in the basal nucleus of Meynert in progressive supranuclear palsy. *Acta Neuropathol (Berl)* 1983;61:157-60.
- 19 David NJ, Mackey EA, Smith JL. Further observations in progressive supranuclear palsy. *Neurology* 1968;18:349-56.
- 20 Blumenthal H, Miller C. Motor nuclear involvement in progressive supranuclear palsy. *Arch Neurol* 1969;20:362-7.
- 21 Ishino H, Higashi H, Kuroda S, *et al*. Motor nuclear involvement in progressive supranuclear palsy. *J Neurol Sci* 1974;22:235-44.
- 22 Kristensen MO. Progressive supranuclear palsy—20 years later. *Acta Neurol Scand* 1985;71:177-89.
- 23 Janati A. Progressive supranuclear palsy: report of a case with torticollis, blepharospasm, and dysfluency. *Am J Med Sci* 1986;292:391-2.
- 24 Newman GC. Treatment of progressive supranuclear palsy with tricyclic antidepressants. *Neurology* 1985;35:1189-93.
- 25 Dehaene I. Apraxia of eyelid opening in progressive supranuclear palsy. *Ann Neurol* 1984;15:115.
- 26 Jankovic J. Apraxia of eyelid opening in progressive supranuclear palsy. Reply. *Ann Neurol* 1984;15:115-6.
- 27 Bonaventura I, Matias-Guiu J, Cervera C, Puiggras AC. Neuroacanthocytosis syndrome, apraxia of eyelid opening, and progressive supranuclear palsy. *Neurology* 1986;36:1276.
- 28 Davis PH, Bergeron C, McLachlan DR. Atypical presentation of progressive supranuclear palsy. *Ann Neurol* 1985;17:337-43.
- 29 Dubas F, Gray F, Escourolle R. Maladie de Steele-Richardson-Olszewski sans ophtalmoplégia: six cas anatomo-cliniques. *Rev Neurol (Paris)* 1983;139:407-16.
- 30 Jellinger K, Riederer P, Tomonaga M. Progressive supranuclear palsy: clinico-pathological and biochemical studies. *J Neural Transm* 1980;suppl 16:111-28.
- 31 Probst A. Dégénérescence neurofibrillaire sous-corticale sénile avec présence de tubules contournés et de filaments droits: form atypique de la paralysie supranucléaire progressive. *Rev Neurol (Paris)* 1977;133:417-28.
- 32 Perkin GD, Lees AJ, Stern GM, Kocek RS. Problems in the diagnosis of progressive supranuclear palsy. *Can J Neurol Sci* 1978;5:167-73.
- 33 Nuwer R. Progressive supranuclear palsy despite normal eye movements. *Arch Neurol* 1981;38:784.
- 34 Pfaffenbach DD, Layton DD, Kearns TP. Ocular manifestations in progressive supranuclear palsy. *Am J Ophthalmol* 1972;74:1179-84.
- 35 Imai H, Narabayashi H, Sakata E. "Pure akinesia" and the later added supranuclear ophthalmoplegia. In: Yahr MD, Bergmann KJ, eds. *Parkinson's disease (Advances in neurology, vol. 45)*. New York: Raven Press, 1986:207-12.
- 36 Goldstein J, Cogan D. Apraxia of eyelid opening. *Arch Ophthalmol* 1965;73:155-9.
- 37 Ungerstedt U. Stereotaxic mapping of the monoamine pathways in the rat brain. *Acta Physiol Scand* 1971;suppl:1-48.
- 38 Jones BE, Moore RY. Ascending projections of the locus ceruleus in the rat. II. Autoradiographic study. *Brain Res* 1977;127:23-53.
- 39 Lloid G, Hornykiewicz O. Catecholamines in regulating of motor function. In: Friedhoff AJ, ed. *Catecholamines and behavior*, vol 1. New York: Plenum Press, 1975:41.
- 40 Koller WC, Morantz R, Vetere-Overfield B, Waxman M. Autologous adrenal medullary transplant in progressive supranuclear palsy. *Neurology* 1989;39:1066-8.
- 41 Klawans HL, Ringel SP. Observations on the efficacy of l-dopa in progressive supranuclear palsy. *Eur Neurol* 1971;5:115-29.
- 42 Jackson JA, Jankovic J, Ford J. Progressive supranuclear palsy: clinical features and response to treatment in 16 patients. *Ann Neurol* 1983;13:273-8.