

Demographic and Clinical Findings in Children Undergoing Bronchoscopy for Foreign Body Aspiration

Mojgan Safari, MD,¹ Mohammad Reza Hashemi Manesh, MD²

¹Department of Pediatrics, Immunology and Allergy Ward, Besat Hospital, Hamadan University of Medical Sciences, Hamadan, Iran

²Department of Cardiology, Tehran University of Medical Sciences, Tehran, Iran

Background: Foreign body aspiration (FBA) is a significant cause of airway distress, mortality, and morbidity in children. Diagnosis of FBA can be challenging and is sometimes delayed for weeks or even months. If not diagnosed and treated promptly, FBA can result in serious consequences.

Methods: For this retrospective study, we investigated the medical records of 89 children who underwent bronchoscopy for suspected FBA and recorded relevant demographic, clinical, and treatment data.

Results: Of the 89 patients identified for this study, 51 had a definitive diagnosis of FBA. Among these patients, choking, chronic cough and wheezing, cyanosis, and dyspnea were the most frequent symptoms of FBA. The foreign bodies were located in the left bronchus (45.1%), the right bronchus (35.3%), the trachea (15.7%), and in both the right and left bronchi (3.9%). Seeds were the most prevalent foreign body, found in 39.2% of the patients.

Conclusion: Lack of complete medical history in patients with suspected FBA is one of the main causes of delayed FBA diagnosis. Bronchoscopy is considered the definitive diagnostic method for FBA and should be conducted in all patients with suspected FBA because of the low risk of complications and reduced probability that FBA diagnosis and treatment will be delayed.

Keywords: Airway obstruction, bronchoscopy, foreign bodies, pediatrics, respiratory aspiration, respiratory sounds

Address correspondence to Mojgan Safari, MD, Department of Pediatrics, Immunology and Allergy Ward, Besat Hospital, Hamadan University of Medical Sciences, Hamadan, Iran. Tel: (+98) 813-826-8866. Email: mo_sfr@yahoo.com

INTRODUCTION

Foreign body aspiration (FBA) occurs most frequently in children <2 years and is a significant cause of airway distress, mortality, and morbidity among young children.¹ The prevalence in young children could be because of their lack of molar teeth; poor swallowing of food; their tendency to put objects in the mouth; playing with objects in the mouth; talking, crying, or moving while eating; having weak protective laryngeal reflexes; and having the desire to explore the world.^{2,3}

In most cases, the aspirated foreign bodies lodge in the bronchi, less commonly in the trachea and larynx.⁴ Inflammation and irritation are major complications caused by an impacted object's obstruction of the bronchi, trachea, and larynx and can lead to bronchitis, tracheitis, atelectasis, and pneumonia.^{5,6} Prompt recognition and early treatment of FBA are paramount to minimize these severe consequences. Symptoms such as cough, choking, wheezing, diminished breath sounds, unilateral crackles, and pathologic chest x-ray are among the main diagnostic factors for tracheobronchial FBA.⁷

Diagnosis of FBA can be challenging and is sometimes delayed for weeks or even months, especially if the patient

is not choking at presentation or an aspiration event has not been confirmed. Delayed diagnosis can lead to deterioration of the patient's condition and result in serious consequences.^{6,8}

The most common reasons for delayed FBA diagnosis are the similarity of FBA symptoms to the symptoms of asthma and croup, parents' inattention to a choking event, nondisclosure of an aspiration, and failure to recognize a foreign body via standard radiographic examinations.

According to one study, lack of reported choking and normal radiographic results are the most significant factors associated with delayed diagnosis of FBA.² Approximately 43% of patients with FBA are wrongly diagnosed with other respiratory disorders.² Acute and chronic coughs are also associated with delayed FBA diagnosis,² and this finding was confirmed in a study by Chik et al.⁴ Severe symptoms of FBA such as acute cough and fever may not occur immediately after choking, causing parents to ignore the severity of choking. Another cause of delayed FBA diagnosis is the similarity between the common symptoms of this condition and other respiratory disorders such as asthma.⁴

During the 20th century, techniques such as bronchoscopy were introduced as standard procedures for the diagnosis and removal of FBA and have resulted in decreased mortality and morbidity.⁹ Radiography and high-resolution computed tomography can also be used to diagnose FBA.

Nevertheless, the life-threatening risks of FBA remain, as death because of choking is the fifth cause of mortality in the United States; every year, about 3,000 people die because of FBA, and the majority of these deaths occur before hospital evaluations and treatments.⁸

Obtaining a detailed medical history, performing a proper physical examination, and evaluating special imaging studies for patients with suspected FBA are of paramount importance for an accurate and timely diagnosis. Furthermore, patients with symptoms such as acute cough, dyspnea, and wheezing need to be monitored by specialists for the possible risk of FBA.² Bronchoscopy is an efficient diagnostic measure for patients with suspected FBA because it is associated with low complications and reduced risks of delayed FBA diagnosis and treatment.^{10,11} Early bronchoscopy is recommended for children who present with suspected FBA.^{4,12}

METHODS

This study aimed to determine the demographic and clinical findings in children who underwent bronchoscopy for possible FBA. We wanted to find the relationship between these factors and the presence of foreign bodies in airways. For this retrospective study, we examined the medical records (n=89) of children who were hospitalized with suspected FBA at Besat Hospital in Hamadan, Iran, and underwent bronchoscopy during 2005-2009. The samples were selected by the census method, and all data were collected from the medical records of patients undergoing bronchoscopy because of respiratory disorders.

Patients undergoing bronchoscopy for conditions other than respiratory disorders, those with incomplete medical records, and children >8 years of age were excluded from this study. Of 89 patients identified for this study, 51 had a definitive diagnosis of FBA. The other 38 patients with suspected FBA were not diagnosed with FBA.

The retrospective medical record review was conducted at Besat Hospital by a medical student investigator. After reviewing the patients' medical histories, the investigator completed researcher-made questionnaires to gather data on age, sex, and the following clinical symptoms: chronic cough, wheezing, stridor, hoarseness, cyanosis, dyspnea, respiratory arrest, and choking. The results of physical examinations were also obtained from the patients' medical records. The locations and types of foreign bodies were determined based on the descriptions by the surgeon (ear, nose, and throat specialist) and recorded.

History of previous admission was recorded for any patients who had been hospitalized because of respiratory disorders such as pneumonia and asthma. The time intervals between patients' hospitalization for a suspected diagnosis of FBA and bronchoscopy and the time intervals between the occurrence of aspiration and

bronchoscopy were also captured and recorded. Data analysis was performed in SPSS v.20 (IBM) to determine the normal distribution of data, and $P \leq 0.05$ was considered significant. In addition, we used the chi-square test to analyze qualitative variables and the relationship between the presence and absence of symptoms in patients with FBA.

RESULTS

In our study population, the youngest patient was 3 months old, and the oldest patient was 84 months old (7 years) (mean age=23.2 months, SD=20.6). Of the patients, 74.5% were male, and 25.5% were female. The frequencies of clinical symptoms in patients with and without FBA are shown in the Table.

We examined the difference between the two study groups (FBA vs non-FBA) for each symptom. No significant relationship was observed between the presence of a foreign body in the airways and the presence of chronic cough ($\chi^2=1.86$, $P=0.24$). In addition, we found there was no significant relationship between the presence of a

Table. Clinical Symptoms in Patients With and Without a Diagnosis of Foreign Body Aspiration

Clinical Symptom	Foreign Body Aspiration Diagnosis		χ^2	P Value
	Yes (n=51)	No (n=38)		
Chronic cough, n (%)				
Yes	32 (62.7)	29 (76.3)	1.86	0.24
No	19 (37.3)	9 (23.7)		
Wheezing, n (%)				
Yes	32 (62.7)	16 (42.1)	3.7	0.08
No	19 (37.3)	22 (57.9)		
Stridor, n (%)				
Yes	2 (3.9)	2 (5.3)	0.09	0.7
No	49 (96.1)	36 (94.7)		
Hoarseness, n (%)				
Yes	4 (7.8)	4 (10.5)	0.19	0.6
No	47 (92.2)	34 (89.5)		
Cyanosis, n (%)				
Yes	18 (35.3)	15 (39.5)	0.16	0.68
No	33 (64.7)	23 (60.5)		
Dyspnea, n (%)				
Yes	10 (19.6)	18 (47.4)	7.7	<0.0005
No	41 (80.4)	20 (52.6)		
Respiratory arrest, n (%)				
Yes	2 (3.9)	0	1.5	0.21
No	49 (96.1)	38 (100)		
Choking, n (%)				
Yes	36 (70.6)	15 (39.5)	8.6	0.003
No	15 (29.4)	23 (60.5)		

foreign body and wheezing ($\chi^2=3.7$, $P=0.08$), stridor ($\chi^2=0.09$, $P=0.7$), hoarseness ($\chi^2=0.19$, $P=0.6$), or cyanosis ($\chi^2=0.16$, $P=0.68$). Similarly, we observed no significant relationship between the presence of a foreign body and respiratory arrest ($\chi^2=1.5$, $P=0.21$). However, we found a significant relationship between the presence of a foreign body and dyspnea ($\chi^2=7.7$, $P<0.0005$) and choking ($\chi^2=8.6$, $P=0.003$).

The time interval between the hospitalization and bronchoscopy for patients with suspected FBA was <1 day in 94.1% of patients and >1 day in 5.9% of patients. The time intervals between the occurrence of FBA and bronchoscopy are shown in the Figure.

For the majority of patients (52.8%), bronchoscopy was done within 9 days of aspiration. However, almost one-fifth of the patients (19.1%) did not have a bronchoscopy until 60 or more days after the aspiration. Of 89 patients, 62 had not been hospitalized previously, and 27 were hospitalized because of other diagnoses such as pneumonia and asthma.

Foreign bodies were located in the left bronchus of 23 (45.1%) patients, the right bronchus of 18 (35.3%) patients, the trachea of 8 (15.7%) patients, and both the right and left bronchi of 2 (3.9%) patients. Regarding the types of foreign bodies, seeds were observed in 20 (39.2%) patients with FBA, and other nuts such as walnuts, almonds, peanuts, and pistachios as well as raisins were observed in 10 (19.6%) patients. Bread and food crumbs, fruit pyrene, and toy parts were observed in 5 (9.8%), 3 (5.9%), and 2 (3.9%) patients, respectively. Chewing gum, beads, and parts of a pen were each observed in 1 (2%) patient. Unknown objects were responsible for FBA in 8 (15.7%) patients.

DISCUSSION

In our study, the majority of children undergoing bronchoscopy were male, and the mean age of the patients was 2 years, demographics that are similar to the results of previous studies.^{7,12,13} Consistent with our

findings, previous studies evaluating bronchoscopy for suspected FBA have indicated the prevalence of this condition to be higher among male infants compared to female infants.¹⁴⁻¹⁶

We compared the results between the FBA group and non-FBA group. Choking was observed in more than two-thirds of patients with a definitive diagnosis of FBA. Furthermore, a significant relationship was seen between choking and dyspnea and the presence or absence of foreign bodies. On the other hand, no significant association was observed between other symptoms of FBA and the presence or absence of foreign bodies. In a study by Chiu et al, coughing and choking were reported to be the most frequent symptoms of FBA.² In the study by Halwai et al, coughing and respiratory arrest were the most frequent symptoms in patients with a history of FBA.¹²

Chronic cough and wheezing were the second most common symptoms among our patients with FBA. More than half the patients in the FBA group presented with chronic cough and wheezing, while other symptoms, such as stridor and respiratory arrest, were less common. The lower incidence of these symptoms could be because of the lower prevalence of upper airway obstruction (15.5% of our patients had foreign bodies lodged in their tracheas) compared to lower airway obstruction (84.5% of our patients had foreign bodies lodged in their bronchi), as stridor and respiratory arrest most frequently occur because of upper airway obstruction. Dyspnea was the fourth most common symptom of FBA, present in 19.6% of patients in the FBA group.

According to Chiu et al, parents often ignore choking, and a significant association exists between acute cough, choking, and early diagnosis of FBA.² Delayed diagnosis of FBA often occurs because coughing in children is neglected; therefore, obtaining a complete medical history of patients with suspected FBA is necessary for accurate diagnosis.² In fact, medical history is considered the most important factor in the

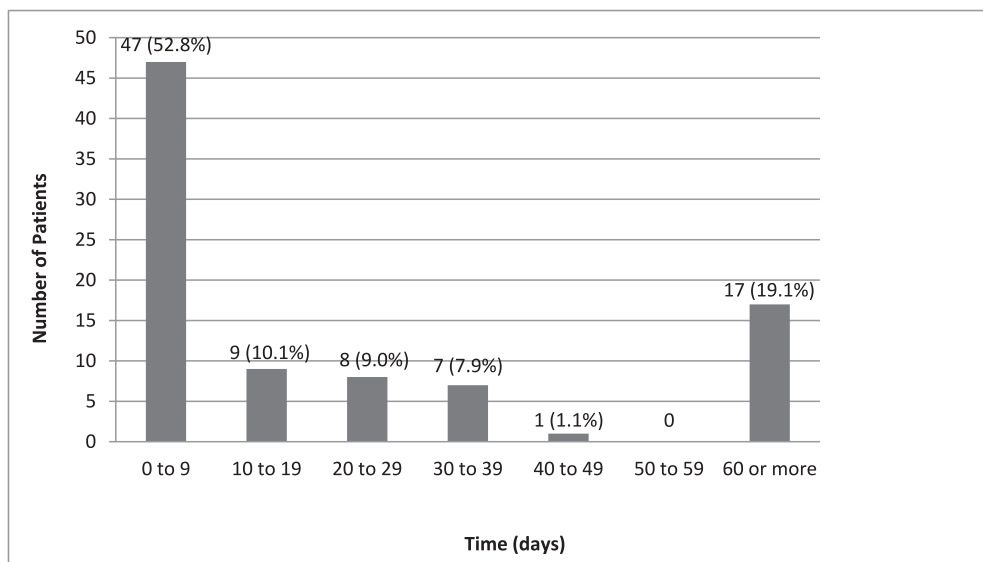


Figure. Time intervals between the occurrence of foreign body aspiration and bronchoscopy.

accurate diagnosis of FBA. Training programs for parents need to be developed to make them aware of signs and symptoms of FBA such as choking, coughing, and wheezing.

In our study, the majority of the foreign bodies were detected in the left bronchus, in line with the findings of Ahmed and Shuiabu¹⁷ and inconsistent with the findings of Halwai et al in which most objects lodged in the right bronchus.¹² On the other hand, Albirmawy and Elsheikh claimed that foreign bodies could be lodged in different spots of the bronchioles, and the location of the foreign body principally depends on the age and physical activity of children at the time of swallowing.¹⁵ In a study by Cataneo et al, the majority of foreign bodies were detected in the right bronchi of children.¹⁰ In other research, foreign bodies were equally distributed between the left and right bronchi of children.¹⁸ Regarding the location of foreign bodies, some researchers have claimed that FBA is more prevalent in the left bronchus.¹⁸

Tahir et al evaluated the location of foreign bodies in different age groups. According to their findings, age and sex had no significant correlations with the location of FBA.¹⁹

The type of foreign body depends on the age, sex, lifestyle, and dietary habits of patients. In developed countries, the majority of aspirated foreign bodies are organic materials, while plastic toys account for a large proportion of impacted objects.¹⁵

In our study, seeds were the most frequent foreign bodies in patients with FBA, consistent with the results obtained by Moghadam et al.¹³ In a study performed in China, food crumbs were the most frequent foreign bodies detected in patients with FBA.² Halwai et al reports that the majority of foreign bodies were organic (eg, peanuts),¹² consistent with the results of Ahmed and Shuiabu¹⁷ and Sumanth et al.⁷

In a 2008 study, Fraga et al reported the mean length of hospital stay in FBA patients to be 2.1 days.²⁰ According to Gregori et al, the rate of hospitalization was 77.6%, and complications occurred in 12.7% of these cases. The majority of patients were discharged after a short time; however, 1 patient died as a result of FBA.¹

In our study, 30% of patients were previously admitted to the hospital once or more with wrong diagnoses such as asthma or pneumonia. Therefore, the possibility of FBA must be considered for children admitted to the hospital with respiratory symptoms.

CONCLUSION

One of the principal causes of delayed FBA diagnosis is lack of access to the complete medical history of patients; therefore, a thorough review of the medical history of patients with suspected FBA is necessary for an accurate diagnosis. In addition, training programs about choking in children need to be developed to raise parents' awareness of the common symptoms of FBA and the potential serious consequences. Bronchoscopy is an efficient diagnostic measure for patients with suspected FBA because it is associated with low complications and reduced risks of delayed FBA diagnosis and treatment.

ACKNOWLEDGMENTS

The authors have no financial or proprietary interest in the subject matter of this article.

REFERENCES

- Gregori D, Salerni L, Scarinzi C, et al; ESFBI Study Group. Foreign bodies in the upper airways causing complications and requiring hospitalization in children aged 0-14 years: results from the ESFBI study. *Eur Arch Otorhinolaryngol*. 2008 Aug; 265(8):971-978. doi: 10.1007/s00405-007-0566-8.
- Chiu CY, Wong KS, Lai SH, Hsia SH, Wu CT. Factors predicting early diagnosis of foreign body aspiration in children. *Pediatr Emerg Care*. 2005 Mar;21(3):161-164.
- DeRowe A, Massick D, Beste DJ. Clinical characteristics of aerodigestive foreign bodies in neurologically impaired children. *Int J Pediatr Otorhinolaryngol*. 2002 Feb 25;62(3):243-248.
- Chik KK, Miu TY, Chan CW. Foreign body aspiration in Hong Kong Chinese children. *Hong Kong Med J*. 2009 Feb;15(1):6-11.
- Adramerina A, Xatzigeorgiou S, Spanou C, Tzanetis F, Neocleous C. How parents' lack of awareness could be associated with foreign body aspiration in children. *Pediatr Emerg Care*. 2015 Apr 7. [Epub ahead of print].
- Zur KB, Litman RS. Pediatric airway foreign body retrieval: surgical and anesthetic perspectives. *Paediatr Anaesth*. 2009 Jul;19 Suppl 1:109-117. doi: 10.1111/j.1460-9592.2009.03006.x.
- Sumanth TJ, Bokare BD, Mahore DM, Ekhar VR, Sakhare PT, Gawarle SH. Management of tracheobronchial foreign bodies: a retrospective and prospective study. *Indian J Otolaryngol Head Neck Surg*. 2014 Jan;66(Suppl 1):60-64. doi: 10.1007/s12070-011-0302-y.
- Rodríguez H, Cuestas G, Botto H, et al. Complications in children from foreign bodies in the airway. *Acta Otorrinolaringol Esp*. 2015 Apr 6. pii: S0001-6519(15)00031-X. doi: 10.1016/j.otorri.2015.01.003.
- Kramer TA, Riding KH, Salkeld LJ. Tracheobronchial and esophageal foreign bodies in the pediatric population. *J Otolaryngol*. 1986 Dec;15(6):355-358.
- Cataneo AJ, Cataneo DC, Ruiz RL Jr. Management of tracheobronchial foreign body in children. *Pediatr Surg Int*. 2008 Feb;24(2):151-156.
- Dehghani N, Ludemann P. Aspirated foreign bodies in children: BC Children's Hospital emergency room protocol. *BCM J*. 2008 Jun;50(5):252-256.
- Halwai O, Bihani A, Sharma A, Dabholkar J. A study of clinical presentations and complications of foreign body in the bronchus—own experience. *Otolaryngol Pol*. 2015;69(1):22-28. doi: 10.5604/00306657.1131145.
- Moghadam HM, Jafarzadeh M, Meimaneh A. Foreign body aspiration in children. *Iran J Pediatr*. 2007;17(Suppl 2):s281-s284.
- Ciftci AO, Bingöl-Koloğlu M, Senocak ME, Tanyel FC, Büyükpamukçu N. Bronchoscopy for evaluation of foreign body aspiration in children. *J Pediatr Surg*. 2003 Aug;38(8):1170-1176.
- Albirmawy OA, Elsheikh MN. Foreign body aspiration, a continuously growing challenge: Tanta University experience in Egypt. *Auris Nasus Larynx*. 2011 Feb;38(1):88-94. doi: 10.1016/j.anl.2010.05.010.
- Paşaoğlu I, Doğan R, Demircin M, Hatipoğlu A, Bozer AY. Bronchoscopic removal of foreign bodies in children: retrospective analysis of 822 cases. *Thorac Cardiovasc Surg*. 1991 Apr;39(2):95-98.
- Ahmed AO, Shuiabu IY. Inhaled foreign bodies in a paediatric population at AKTH Kano-Nigeria. *Niger Med J*. 2014 Jan;55(1):77-82. doi: 10.4103/0300-1652.128178.
- Cohen SR, Herbert WI, Lewis GB Jr, Geller KA. Foreign bodies in the airway. Five-year retrospective study with special reference to management. *Ann Otol Rhinol Laryngol*. 1980 Sep-Oct;89(5 Pt 1):437-442.

19. Tahir N, Ramsden WH, Stringer MD. Tracheobronchial anatomy and the distribution of inhaled foreign bodies in children. *Eur J Pediatr*. 2009 Mar;168(3):289-295. doi: 10.1007/s00431-008-0751-9.
20. Fraga Ade M, Reis MC, Zambon MP, Toro IC, Ribeiro JD, Baracat EC. Foreign body aspiration in children: clinical aspects, radiological aspects and bronchoscopic treatment. *J Bras Pneumol*. 2008 Feb;34(2):74-82.

This article meets the Accreditation Council for Graduate Medical Education and the American Board of Medical Specialties Maintenance of Certification competencies for Patient Care and Medical Knowledge.