

Scapho-capitate Syndrome Variant: 180-Degree Rotation of the Proximal Capitate Fragment without Identifiable Scaphoid Fracture

Matthew M. Robbins, M.D., Ajay B. Nemade, B.S., Timothy B. Chen, M.D. and Robert E. Epstein, M.D.

Scapho-capitate fractures, also known as Fenton's Syndrome, occur very rarely. We report a case of a variant capitate fracture with a 180 degree rotation of the proximal fragment and no identifiable scaphoid fracture. Prompt identification of this fracture is necessary to minimize complications such as avascular necrosis.

Introduction

Fractures of the capitate are rare due to its anatomic position; it is centrally located between other carpal bones. The cuboidal shape of the capitate provides strength to the bone and therefore is less prone to fracture [1]. The incidence of capitate fractures is reported 0.2% to 1.3% of all carpal bone fractures [2, 3, 4]. An isolated fracture of the capitate can be clinically occult

Citation: Robbins MM, Nemade AB, Chen TB, Epstein RE. Scapho-capitate syndrome variant: 180-degree rotation of the proximal capitate fragment without identifiable scaphoid fracture. *Radiology Case Reports*. [Online] 2008;3:193.

Copyright: © 2008 The Authors. This is an open-access article distributed under the terms of the Creative Commons Attribution-NonCommercial-NoDerivs 2.5 License, which permits reproduction and distribution, provided the original work is properly cited. Commercial use and derivative works are not permitted.

Abbreviations: CT, computed tomography

Matthew M. Robbins, M.D. (Email: m2robbins@gmail.com), Timothy B. Chen, M.D., and Robert E. Epstein, M.D., are in the Department of Radiology, University of Medicine and Dentistry of New Jersey, New Brunswick, NJ, USA.

Ajay B. Nemade, B.S., is at the University of Medicine and Dentistry of New Jersey, Robert Wood Johnson Medical School, Piscataway, NJ, USA.

Published: August 22, 2008

DOI: 10.2484/rcr.v3i3.193

initially because it may produce few specific symptoms. Furthermore, a capitate fracture is often non-displaced due to stability offered by the intercarpal ligaments. This contributes to the difficulty in radiographically detecting these fractures [5]. Scapho-capitate fractures are characterized by combined fractures of the scaphoid and capitate with rotation of the proximal fragment of the capitate through 90 or 180 degrees [6]. Consequences of delayed treatment of scapho-capitate fracture include posttraumatic arthritis, avascular necrosis of the capitate head, and nonunion [7].

Case Report

The patient was a 24-year-old female with no significant past medical history. She presented to Emergency Department after falling while attempting to enter her home through a second-story bathroom window in February 2007. She landed on her feet and subsequently fell on her wrists. The patient's injuries included multiple wrist injuries and bilateral distal tibial fractures. Physical

Scapho-capitate Syndrome Variant

examination revealed a left wrist deformity. Wrist pain was elicited bilaterally during wrist flexion and extension maneuvers. Initial radiographs demonstrated a fracture of the right capitate bone. Further evaluation was obtained with unenhanced computed tomography of the wrist, which showed 180 degree rotation of the proximal capitate fragment. Additional injuries from the

fall included an L1 superior end plate compression fracture, a left distal radius fracture, a right pilon fracture, and a left ankle fracture. The patient was admitted to the orthopedic service for further management. She underwent two separate procedures: Open reduction and internal fixations of the right capitate, and of the ankle fracture. The patient did well postoperatively and was subsequently discharged and followed by the orthopedic service.

Discussion

The mechanism of scapho-capitate fracture is controversial. The most frequent mechanism of scapho-capitate fracture is a fall on the palm with the wrist extended [7, 8, 9, 10]. This movement causes scaphoid fracture due to compression forces. Due to hyperextension of the wrist, contact between the posterior margin of the radius and the neck of the capitate occurs leading to capitate fracture. The continuation of this motion leads to a two-step rotation of the proximal pole of the capitate. Direct trauma over the dorsum of the wrist is also reported as a cause of capitate fractures [11]. Fractures of the capitate are serious and treatment to obtain satisfactory clinical

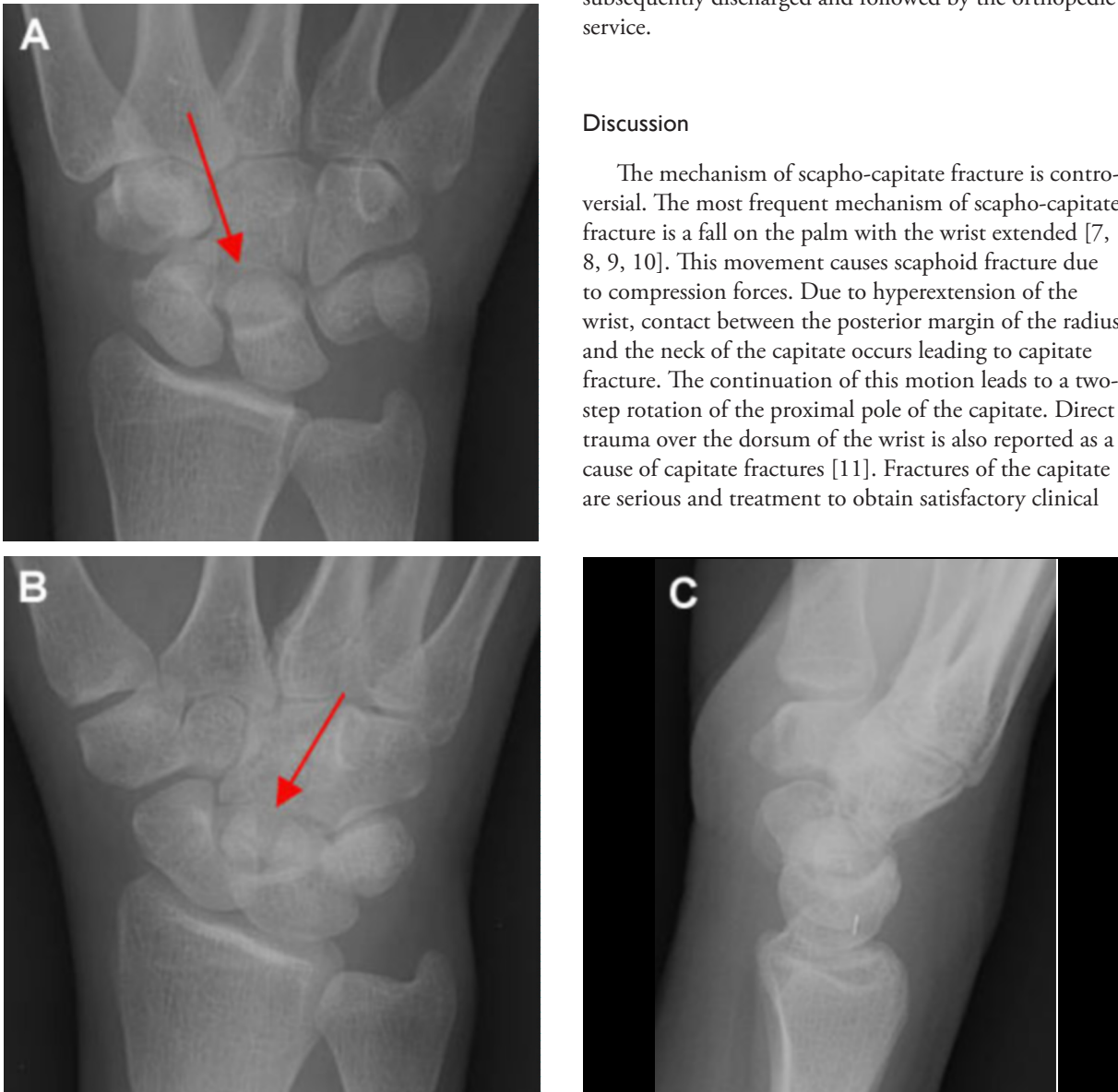

Figure 1A-C. Frontal (A) and oblique (B) right wrist radiographs demonstrate a fracture of the capitate (arrows) with no other injuries identified. On the lateral radiograph (C), the capitate fracture fragment is hard to discern.

Scapho-capitate Syndrome Variant

results is difficult. Moreover, literature has focused little attention on injuries of the capitate [12].

Capitate fractures are rare and may be underdiagnosed. Adler and Shaftan (1962) reported 12 cases of capitate fractures and categorized these into 3 types: 1)

Isolated fractures, transverse across the waist of the capitate, or oblique fractures involving the distal dorsal rim, 2) Scapho-capitate fracture syndrome, with proximal transverse fracture of the capitate and 90 to 180 degrees rotation of the proximal fragment, and 3) Capitate frac-

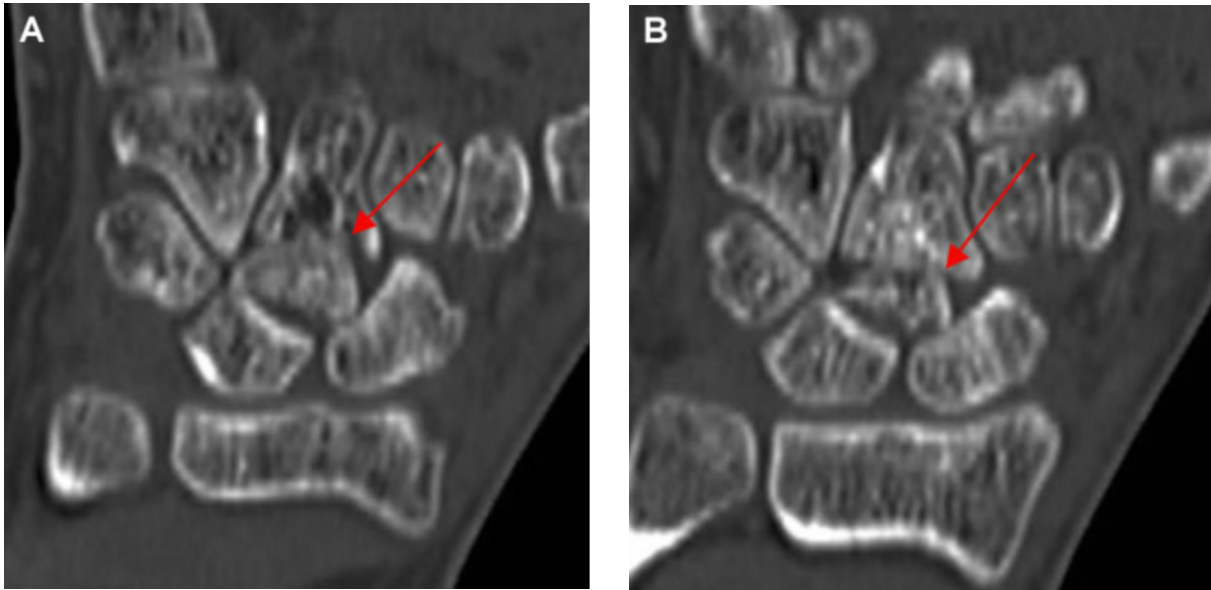


Figure 2A-B. Coronal CT images of the right wrist show the capitate fracture. The proximal fracture fragment (arrow) rotated 180 degrees.

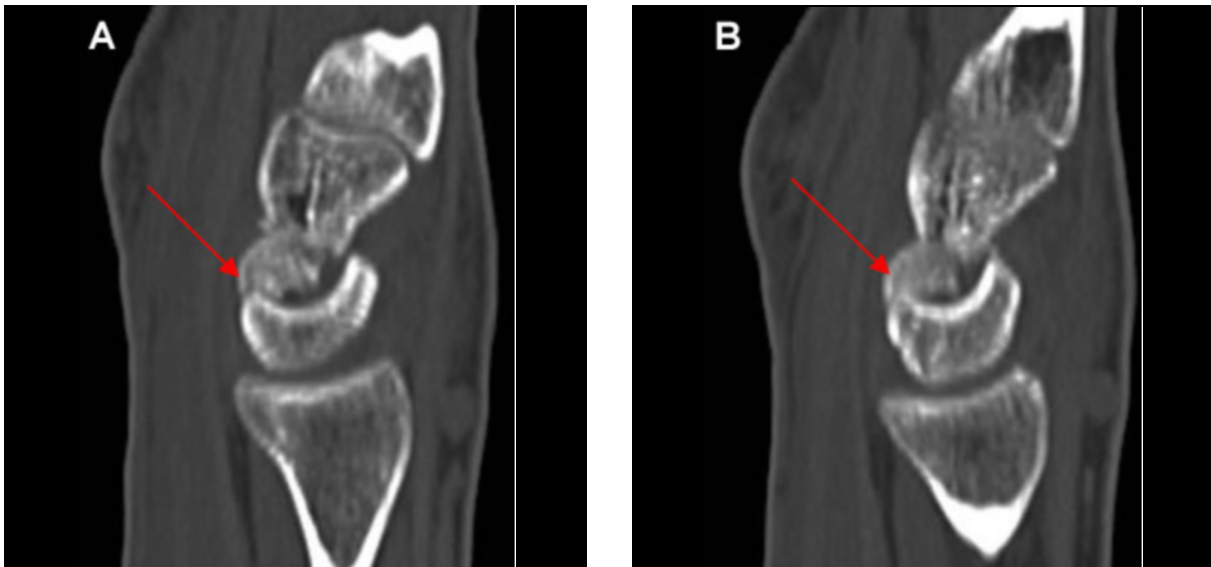


Figure 3A-B. Sagittal CT images demonstrate the capitate fracture (arrows).

Scapho-capitate Syndrome Variant

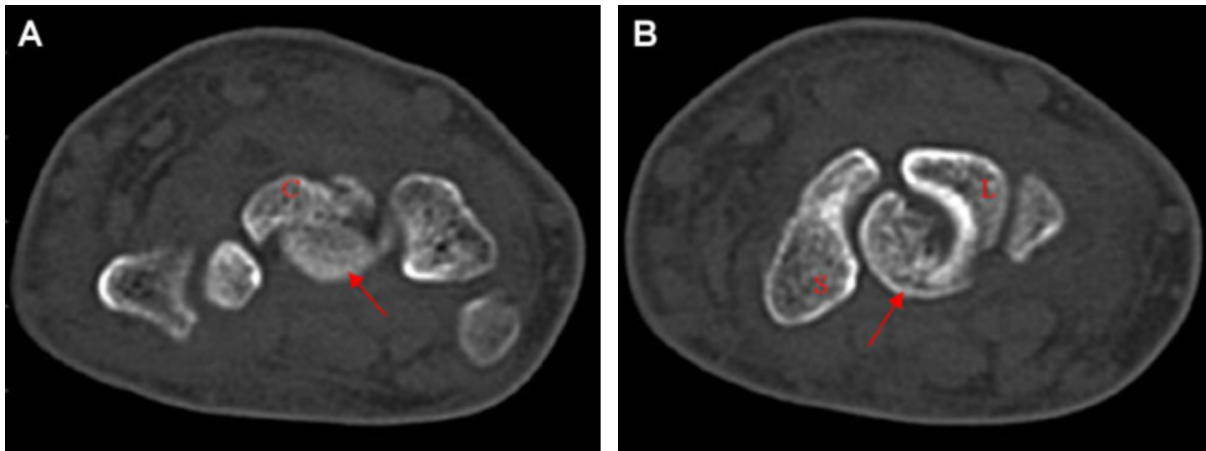


Figure 4A-B. Axial CT images demonstrate the proximal capitate fracture (arrows). S = scaphoid. L = Lunate. C = distal capitate fragment.

ture in association with other carpal injury.

This patient suffered fracture of the capitate bone with an inversion of the proximal fracture fragment after a 2 story fall. Despite the lack of injury to the other carpal bones, the rotation of the proximal fragment indicates injuries to the intercarpal ligaments. Therefore, we believe this case represents a variant of the scapho-capitate syndrome, rather than a simple isolated carpal fracture.

References

1. Fenton RL. The naviculo-capitate fracture syndrome. *J Bone Joint Surg* 1956;38-A: 681-4. [PubMed]
2. Snodgrass LE. Fractures of the carpal bones. *Amer J Surg* 1937;38: 539-48.
3. Rand JA, Linscheid RL, Dobyns JH. Capitate fractures: a long-term follow-up. *Clin Orthop* 1982;165: 209-16. DOI:10.1016/S0363-5023(05)80272-2.
4. Kuderna H. Frakturen und Luxationsfrakturen der Handwurzel. *Orthopädie* 1986;15: 95-108. DOI: 10.1055/s-2003-43112.
5. Calandruccio JH, Duncan SFM. Isolated nondisplaced capitate waist fracture diagnosed by magnetic resonance imaging. *J Hand Surg Am* 1999;24(4): 856-9. [PubMed]
6. Steffens K, Luce S, Koob E. Unusual course of scapho-capitate syndrome. *Handchir Mikrochir Plast Chir* 1994;26(1): 12-4. [PubMed]
7. Boisgard S, Bremont JL, Guyonnet G, et al. Scapho-capitate fracture. Apropos of a case, review of the literature. *Ann Chir Main Memb Super* 1996;15(3): 181-8. [PubMed]
8. Adler JB, Shaftan GW. Fractures of the capitate. *J Bone Joint Surg Am.* 1962;44-A: 1537-47. [PubMed]
9. Ameziane L, Marzouki A, Souhail SM, et al. Fentons syndrome or scapho-capitate fracture (a case report). *Chir Main* 2003;22(6): 318-20. [PubMed]
10. Strohm PC, Laier P, Müller CA, et al. Scapho-capitate fracture syndrome of both hands—first description of a bilateral occurrence of a rare carpal injury. *Unfallchirurg* 2003;106(4): 339-42. [PubMed]
11. Stein F, Siegel MW. Naviculocapitate fracture syndrome. A case report: new thoughts on the mechanism of injury. *J Bone Joint Surg Am* 1969;51(2): 391-5. [PubMed]

Scapho-capitate Syndrome Variant

12. Yoshihara M, Sakai A, Toba N, et al. Nonunion of the isolated capitate waist fracture. *J Orthop Sci* 2002;7(5): 578-80. [PubMed]