



Craniocerebral Gunshot Injuries; A Review of the Current Literature

Hernando Raphael Alvis-Miranda¹, Andres M. Rubiano², Amit Agrawal³, Alejandro Rojas⁴, Luis Rafael Moscote-Salazar⁵, Guru Dutta Satyarthee⁶, Willem Guillermo Calderon-Miranda⁷, Nidia Escobar Hernandez⁸, Nasly Zabaleta-Churio⁹

¹Department of Neurosurgery, University of Cartagena, Cartagena de Indias, Colombia

²Department of Neurosurgery and Neuroscience, University of El Bosque, RED LATINO-Latin American Trauma & Intensive Neuro-Care Organization, Bogota, Colombia

³Department of Neurosurgery, MM Institute of Medical Sciences & Research, Maharishi Markandeshwar University, Mullana, Ambala, Haryana, India

⁴Department of Neurosurgery, Fundacion Universitaria de Ciencias de la Salud, Bogota, Colombia

⁵Department of Neurosurgery, RED LATINO-Latin American Trauma & Intensive Neuro-Care Organization, Bogota, Colombia

⁶Department of Neurosurgery All India Institute of Medical Sciences, New Delhi, India

⁷Resident of Radiology, Universidad Nacional Autonoma de Mexico, Mexico D.F, Mexico

⁸Chief of Radiology, Hospital General Dr. Manuel Gea Gonzalez, Mexico D.F, Mexico

⁹Universidad Popular del Cesar, Valledupar, Colombia

***Corresponding author:** Luis Rafael Moscote-Salazar

Address: Department of Neurosurgery, RED LATINO-Latin American Trauma & Intensive Neuro-Care Organization, Bogota, Colombia.

e-mail:mineurocirujano@aol.com

Received: October 15, 2015

Revised: December 10, 2015

Accepted: December 29, 2015

▶ ABSTRACT

Craniocerebral gunshot injuries (CGI) are increasingly encountered by neurosurgeons in civilian and urban settings. Unfortunately, more prevalent condition in developing countries, with major armed conflicts which is still persisting, since the main trigger is violence at the national or state level. Management goals of CGI should focus on aggressive resuscitation and correction of coagulopathy; those with stable vital signs should undergo CT scan head at the earliest possible opportunity. Neuroimaging is vital for planning of surgical management, especially to determine the type of surgery, routes of the approach to the surgical target area and extraction of the impacted foreign bodies, however, surgical management is not always indicated. Although subset of such cases may be managed even with non-surgical management. The treatment comprises of immediate life salvaging resuscitative measures including control of the persistent bleeding, care of associated injury, management of raised intracranial pressure, prevention of cerebrospinal fistula formation by primary watertight dural repair and prevention of infection, through extensive debridement of contaminated, macerated or ischemic tissues; preservation of nervous tissue and restoration of anatomic structures through the hermetic sealing of dural and scalp defect. Recently, only few studies of craniocerebral penetrating injuries are published that too involving smaller patients sample sizes; although classic studies in the military and civil situation noticed associated relatively very high mortality and morbidity and psychological as well as economic impact on the affected individual, the family and the health system in providing ongoing care to the sufferers and society at large. Currently various measures are advocated with aim to reduce the incidence of CGI especially in civilian populations. It is highly necessary and immensely urgent to promote research in a neurocritical care of CGI to provide positive impact on improvement of the quality of life and further providing better care and reduction of overall health care cost.

Keywords: Craniocerebral gunshot injuries; Penetrating head injury; Neurotrauma; Management; Prognosis; Outcome.

Please cite this paper as:

Alvis-Miranda HR, Rubiano AM, Agrawal A, Rojas A, Moscote-Salazar LR, Satyarthee GD, Calderon-Miranda WG, Hernandez NE, Zabaleta-Churio N. Craniocerebral Gunshot Injuries; A Review of the Current Literature. *Bull Emerg Trauma*. 2016;4(2):65-74.

Introduction

Cranio-cerebral gunshot injuries (CGI), in the past usually described and managed in military settings, are currently increasingly encountered by neurosurgeons in civilian and urban settings, which is on the rise especially in developing countries. Although less prevalent than closed head trauma, penetrating brain injury carries a worse prognosis [1]. CGI are the most lethal of all firearm injuries, with reported survival rates of only 7% to 15% [2].

About 90% the victims die before prior to reaching at the hospital care, and for those who survive and make it to the hospital, further about 50% die in the emergency room [3,4]. Peak mortality from CGI usually happens either at the site of injury or within first three hours of injury [4,5]. So, management of gunshot (missile) wounds (injuries) of head (cranio-cerebral) due to bullets, shotguns, blasts, explosion of grenades and mines are routine experience at Neurosurgical centre in any countries with civil armed conflict. Since patient epidemiology is a multifactorial phenomenon and being influenced by socioeconomic, psychological, as well as cultural factors, the characteristics of CGI patients might be fundamentally different among the different countries.

There are many lessons to be learnt. Current review considers modern ballistic aspects, pathophysiology of injury, diagnosis and management.

Ballistics and Pathophysiology

Projectiles may be pellets fired from a shotgun, bullets from rifles, machine-guns, automatic guns and carbines, shrapnel's and splinters by exploding bombs, grenades and mines. A missile is a projectile having either a high velocity (muzzle velocity less than 600m/sec) or a low velocity (muzzle velocity below 300m/sec) [6].

Ballistics

As majority of the penetrating brain injuries are caused by missiles or projectiles, an understanding of ballistics (i.e., the study of the dynamics of projectiles) is imperative [1].

Firearms can be classified in many ways; the simplest is based on speed:

1. Low velocity: usually fires at less than 1000 feet per second (<300 m/sec). e.g. handguns or hand sizes 22, 38 and 9mm.
2. Medium velocity: maximum speed range is 1000 to 2000 feet per second (300 to 600 m / sec e.g. submachine guns.
3. High velocity: More than 2000 feet per second (600 to 1000 m/sec) as the AK-47, G-3 or Galil. These possessing properties i.e. Oscillation, rotation, and fragmentation making much more lethal.

Physiopathology

The ability of any penetrating object to penetrate the brain and causing primary brain injury is dependent on the ballistic properties i.e. kinetic energy, mass of projectile, velocity, shape, angle of approach, the characteristics of intervening tissues, etc and any secondary projectiles formation such as fragments of bone or metals [1,7].

It is important to consider the total energy being delivered and areas of the brain to which affected. The kinetic or wounding energy is defined by the relationship: $E = 1/2mv^2$, velocity can be represented as $E = 1/2 m (V_i^2 - V_r^2)$ where m is the mass of the projectile, V_i is the impact velocity and V_r is the residual velocity in the case of perforating wound [8,9]. This implies velocity of the projectile has a greater influence than the mass alone, meaning that the bullet of an AK-47 assault rifle, which weighs 7.9 g and has an initial velocity of 720 m/s, has a kinetic energy of 2635 ft/lb (1.77 m/g). Projectile velocity from firearms in handguns is less than that of rifles, varying usually from 180 m/s to 450 m/s.

When the velocity exceeds 700 m/s, the wounding capacity of the projectile is significantly increased, leading to more severe brain damage, more bone fragmentation of calvarium, and associated enhanced secondary brain cavitations [10,11]. Higher velocity projectiles will also cause additional temporary cavitation effect in their trail, [7] which is a velocity-related phenomenon, a high-pressure sonic wave, lasting for few microseconds radiates outwards from the point of primary missile impact [6,12]. Expanding (Dumdum) and devastator bullets transmit most kinetic energy preferentially at the impact site [13]. The missile deposits its kinetic energy on the skull, causing fragmentation and fracture of the bone, generating secondary missiles of small bone pieces entering into brain parenchyma causing further damage. Adjacent and distant to track, is a low pressure, long lasting wave which displaces and crushes the brain tissue radially due to moving missile in the brain, thus rapidly compressing it tangentially from the primary track, leading to temporary cavitations effect which in turn causes suction of air, skin, hairs and debris into brain parenchyma. Such a phenomenon leads to a large exit wound with a perforating injury [14].

Posteriorly, this temporary cavity collapses upon itself only to re-expand in progressively smaller undulating wave-like patterns. Every cycle of temporary expansion and collapse creates significant surrounding brain tissue injury, which result in shear-like injury of the neurons or can result in formation of epidural hematomas, subdural hematomas, or parenchymal contusions [15]. However, a bullet does not need to penetrate the skull to cause intracranial damage; the mechanism of injury in these are either a blunt force or secondary bone fragments entering into the brain [16]. The velocity of the missile is

important in tangential wounds, having the ability to release sufficient energy to cause intracranial damage without skull bone damage [17].

A projectile, while travelling through the air loses kinetic energy rapidly due to resistance [15], which causes reduction in projectile velocity which also depends on the shape of the projectile. Bullets can be blunt-nosed, fully or half jacketed and hollow tipped to increase deformity, to ensure more damage to target. The sharper the nose of a bullet, the lesser the decrease in velocity by air resistance. Matson classified craniocerebral gunshot wounds.

Classification

Craniocerebral missile wounds were first classified by Cushing, based in his experience on World War I [18]. Matson modified craniocerebral injury classification in 1948 which is the most currently used [19]. According to Matson classification wound is divided into four classes. Class I wound comprise of scalp wound with unassociated skull fracture, second being skull fracture without dural penetration, third being compound skull fracture with dural and associated brain parenchymal penetration and finally class IV being class iii wounds with following complicating factors: i ventricular penetration, ii fracture of the orbit or sinus, iii injury to the dural sinus and iv intracerebral hematoma. However, class III wounds were further divided into Subtypes of Class III: a. gutter type with no retained missile, b. penetrating variety with retained missile in the brain parenchyma and c. Perforating type with no retained missile.

Missile wounds are tangential, penetrating and perforating [19,20]. Penetrating injury is described as gunshot penetrating skull and dura without any exit wound, whereas in perforating type missile enters the skull and dura and then exits by creating exit wounds. Tangential wounds occurs when a missile grazes the skull at an oblique angle, only lacerating the scalp or stays under scalp causing depressed or elevated fractures and in driven bone fragments into brain parenchyma may cause dural breaches, extradural or subdural hematomas or cortical contusions.

The preponderance of low muzzle velocity weapons seen in clinical practice and the availability of computed tomographic (CT) scan head evaluation within minutes after presentation has altered the range of prognostic indicators available to the neurosurgeon and the amount of relative importance placed on each factor [3] Raimondi and Samuelson [21] in 1970 noted this difference in wound ballistics and offered a classification scheme based on initial neurologic assessment.

Neuroimaging

The diverse neuroimaging modalities are used in patients with CGI to plan out treatment decision and

for prognostic implications. Neuroimaging is vital for surgical planning and approaches, especially for evaluating the type and nature of surgery, size of incision and placement of incision, route of extraction of the foreign body. Basic radiological findings that evaluated in determination in CGI wound victims are exit and entry sites. intracranial fragments, missile trajectory and its relationship to important vessels and nerves and air-containing skull base sinuses; presence of intracranial air; transventricular injury; missile track crossing the midline; multilobar injury; effacement of basal cistern; brain parenchymal injury and associated mass effect with transtentorial herniation, presence of obstructive hydrocephalus or pneumocephalus [22]. In case of survival, computed tomography (CT) scan and magnetic resonance imaging (MRI) can be used to monitor progress and pick up possible vascular infarct or infectious complications. [23].

Plain Films

The availability of CT-scan precludes the use of plain radiography, but still it is used in remote places [24,25]. However, post-mortem radiography is routine and invaluable, particularly when death has occurred prior to the instigation of any emergent medical management and imaging. It is invaluable in forensic investigation of gunshot wounds to locate the bullet, identify the type of ammunition used, document the path of the bullet, and assist in retrieval [22].

Computed Tomography Scan of Brain

Brain CT-scan is widely used to evaluate cases with penetrating head trauma, in addition to the standard axial view with bone window and brain parenchyma, coronal cuts may be helpful to evaluate lesions of the skull-base and convexity. CT-scan is useful and has increased capacity to identifying missile and bone fragments, characterization of the projectile trajectory, extent of brain injury evaluation, and detection of existing intracranial hematomas (Figure 1). All patients with CGI should be undergo none contrast CT scan head irrespective of evidence of penetration of skull on clinical evaluation [22]. Volume acquisition protocol on current multi-detector helical systems is highly useful as scanning time is very short and the acquired volume dataset allows retro-formatting of images to the variable section thickness specially useful for skull-base assessment as well as three-dimensional surface-rendered depiction for fracture evaluation [22]. CT findings of multi lobar injury and associated intraventricular hemorrhage correlate with poor outcome, [26,27].

Magnetic Resonance Imaging

In the acute setting of CGI, MRI is usually not

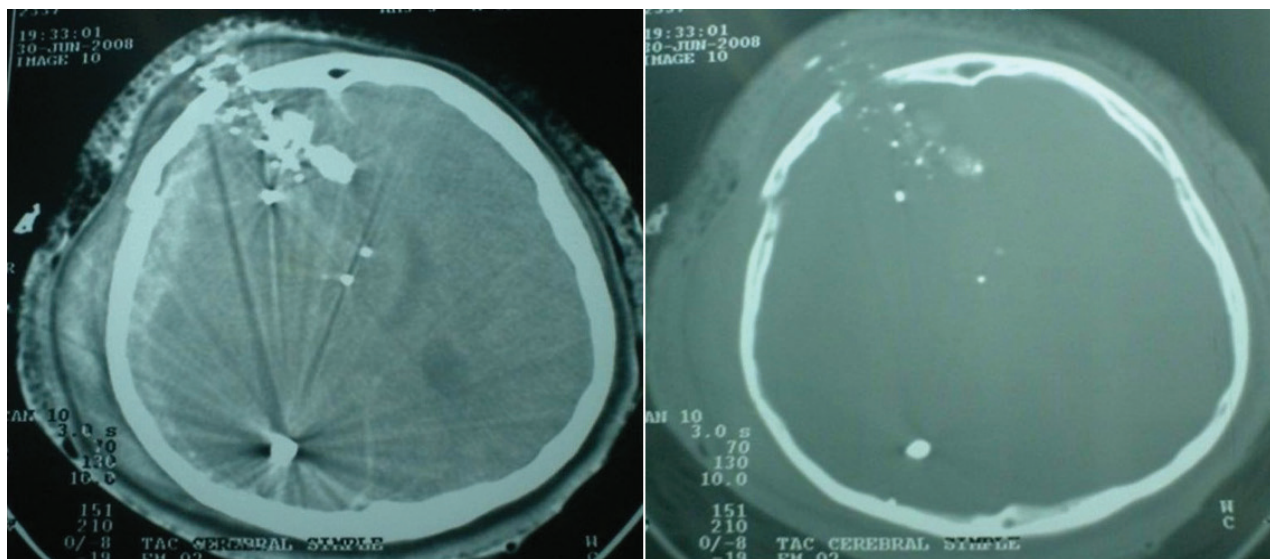


Fig. 1. Simple brain CT scan in a case of CGI **A.** multiple shrapnel from the left region to the right parieto-occipital region, accompanied by subdural hematoma, cerebral edema and ventricular collapse. **B.** CT bone window, right frontal fracture, accompanied by multiple intracranial shrapnel.

recommended, as time consuming process and carries the potential danger if retained ferromagnetic objects may lead to possible movement in response to the magnetic torque, [7] and further majority of military and paramilitary ammunition contains ferromagnetic materials, usually in the jacket covering the lead or antimony core. It has been suggested bullets showing less deformation on CT or plain X-ray imaging is more likely to carry a hard steel ferromagnetic component compared with the more easily deforming non-ferromagnetic bullets [28]. Nevertheless, owing to the uncertainty of bullet construct in the vast majority of civilian shootings, the use of MRI would seem imprudent, and CT scan still continue to be the primary imaging mode [22].

Cerebral Angiography

Angiography is required in case with increased risk of vascular injury, including wound trajectory is through or near the Sylvian fissure and, therefore, M1 and M2 segments of the middle cerebral artery, peripheral branches of the anterior cerebral artery, the supraclinoid carotid artery, the vertebra-basilar vessels, the cavernous sinus region or the major dural venous sinuses [29,30].

Angiography can play a significant role to in delayed vascular complications developing following CGI, most notably traumatic aneurysm formation. CT angiography (CTA) has many advantages over conventional Digital subtraction angiography (DSA). CTA is a rapid, non-invasive, and relatively inexpensive modality; also reveals the trajectory of the wound track and non-vascular injuries. However, some limitations of CTA are streak artifact from shoulders, retained metallic fragments, and dental fillings, which can prevent adequate visualization of the intracranial vessels. Also, suboptimal timing of contrast or failed intravenous injection may lead to

decreased or non-optimal opacification of vessels, which can miss the presence of vascular injury [31].

Treatment

General Considerations

Management goals should focus on early aggressive, vigorous resuscitation and correction of coagulopathy; those with stable vital signs, should undergo brain CT scan [32].

If aggressive therapy stands a high chance of severe disability in survivors or persistent vegetative state with only a very small chance of a good outcome; most neurosurgeons would be discouraged for aggressively treating the Glasgow Coma Scale (GCS) 3–5 group [24]. Graham *et al.*, [33] recommend in patients (with GCS of 3-5) after resuscitation should not be treated unless there was an associated operable haematoma, the economic and psychosocial burden of caring for these disabled survivors is immensely expensive [24]. Patients with a GCS of ≥ 8 should be treated aggressively [33]. To consider, organ donation after fatal CGI is a legitimate goal.

The treatment can be summarized in four steps:

1. Immediate resuscitation to salvage life, through control of persistent bleeding and control of raised intracranial pressure.
2. Prevention of infection, through extensive debridement of all contaminated, macerated or ischemic tissues.
3. Preservation of nervous tissue, through preventing meningocerebral scars.
4. Restoration of anatomic structures through the hermetic seal of the dura and scalp layers.

Intracranial Hypertension (ICH)

ICH is the leading cause of death in traumatic brain injury (TBI) and contributes to secondary brain

injury if not properly handled. According to Monroe-Kelly doctrine suggests the rigid skull is occupied by three volumes: blood, brain and cerebrospinal fluid, at least any additional volume, such as hematomas, cerebral edema or hydrocephalus result in increased intracranial pressure (ICP) when compensatory movements of the primary volumes have been exceeded. It has been shown in clinical studies that TBI patients with ICP greater than 20 mmHg, particularly when refractory to treatment, have a worse prognosis and are more likely to have cerebral herniation syndromes. Cerebral perfusion pressure below 60-70 mmHg is also associated with decreased cerebral parenchymal oxygenation causing altered cerebral metabolism and poor prognosis. The goal of neuromonitoring and treatment is at least maintaining cerebral perfusion, oxygenation and metabolism suitable, but also to limit the progression of elevated intracranial pressure and any episode of desaturation events.

ICP monitoring is well documented to be an important predictor of prognosis in severe non penetrating TBI as ICH is clearly associated with worse recovery and optimum control of elevated ICP leads to a better outcome. The available data suggest a higher frequency of raised ICP in CGI patients, and raised ICP is documented to be a predictor of worse prognosis [25]. In cases, where ICP is monitored and ICH is detected, immediate measure to control these should be applied. The treatment measures are the same, which are used in non-penetrating TBI, i.e. hyperventilation, mannitol, CSF drainage, high-dose barbiturates, and more recently, decompressive

craniectomy [34,35].

Surgical Management

Surgical management of these patients is controversial. Some neurosurgeons favor a surgical approach consisting of minimal local debridement while preserving as much cerebral tissue as possible. While other neurosurgeons are more aggressive and try to remove all bone and any metallic fragments that are reasonably accessible [36]. In theory, intracranial bone and metallic fragments that are not removed might be associated with a higher rate of infection, however in a small group of 13 patients, there was no correlation between the presence of retained fragments and the subsequent development of intracranial infection or epilepsy [27]., the neurosurgeon must take into account the type of weapon used and the distance from which it was fired, the patient's age and clinical condition and the CT scan findings while making a management decision. It is reasonable for the neurosurgeon to decide against active therapy for the patients in poor condition with multiple poor prognostic variables [24].

Tsuei *et al.*, [37] suggested an algorithm for penetrating gunshot injuries of the brain, according to GCS and pupillary reactivity, the decision to perform or not surgery is planned. Patients with a GCS 3-5 following resuscitation, who have responsive pupils and are not hypotensive should have a CT scan;(24) but those with GCS ≥ 3 and/or reactive pupils can undergo to head CT-scan, and based on findings, is decided to perform surgery or not. (Figure 2).

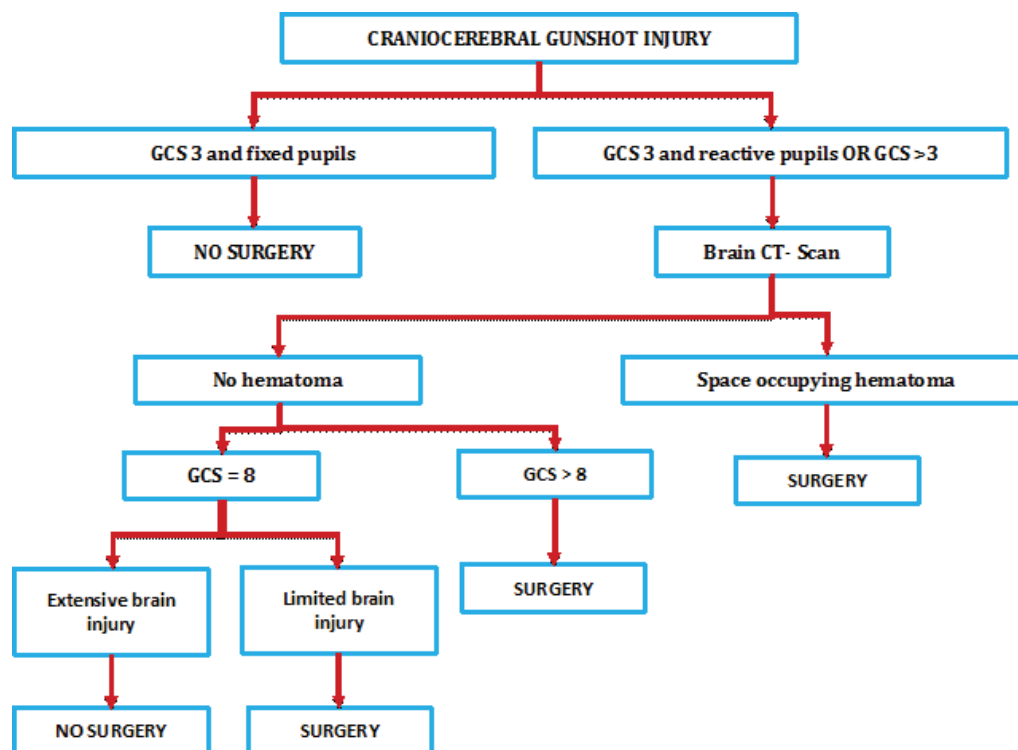


Fig. 2. Management guideline for craniocerebral gunshot injury (Adopted from Tsuei YS, Sun MH, Lee HD, Chiang MZ, Leu CH, Cheng WY, et al. Civilian gunshot wounds to the brain. J Chin Med Assoc. 2005 Mar;68(3):126-30).

What to Do on Surgery?

Surgical procedures include irrigation, debridement of devitalized tissues, and removal of space-occupying hematomas, in-driven bone, and accessible bullet fragments. For the treatment of CGI with small inlets the recommendation is local wound care and closure in patients without devitalized scalp and without significant intracranial pathologic findings. The term “significant” has not a clear definition, however, the volume and location of the hematoma, evidence of mass effect with greater than 5mm shift or effacement of the basal cisterns by edema or hematoma and the clinical condition of the patient, all belong to the term “significant”.

The treatment of most extensive wounds with nonviable scalp or bone (significant fragmentation of the skull) is a large debridement with craniectomy or craniotomy before primary closure. In the presence of significant mass effect, debridement of necrotic tissue and secure access to the bone fragments is the recommended, also hematoma evacuation (Figure 3). In the absence of significant mass effect, surgical debridement of projectile trajectory is not recommended on the basis of evidence Class III [1]. Repairing of open sinuses with dural sealing is recommended, the clinical circumstances may dictate the time of repair. The dural graft technique and the material used for closure are discretionary to the practicing neurosurgeon.

Regarding surgical management techniques are

variable whether civil literature and military literature were separately analyzed, due to following reasons:

1. The majority of injuries by gun fire in skull on the battlefield are produced by high-speed projectiles unlike most penetrating civilian’s brain injuries.

2. Wounds are much more contaminated in the battlefield.

3. Early surgical treatment in the military is limited in comparison with the treatment facilities of civilians.

4. The technical difficulties for adequate brain and cardiopulmonary resuscitation on the battlefield compared to the civilian situation.

Until the end of Vietnam War, surgical recommended was complete removal of metal and bone fragments, along with vigorous debridement and performing many surgeries as necessary to prevent complications i.e. infections, epilepsy and cerebral edema, but was demonstrated in prospective studies during wartime, that repeated craniotomies to remove retained fragments and vigorous exploration in the initial surgery exponentially increased the morbidity and mortality of these patients and their ineffectiveness in preventing seizures or infections, so the current trend led to the realization of a less aggressive debridement approach.

The management of CSF fistulas should be early to prevent infections; regarding the choice of closure techniques and the material used is familiarity and experience of the treating neurosurgeon, although preferably autologous fascia lata graft or pericardial

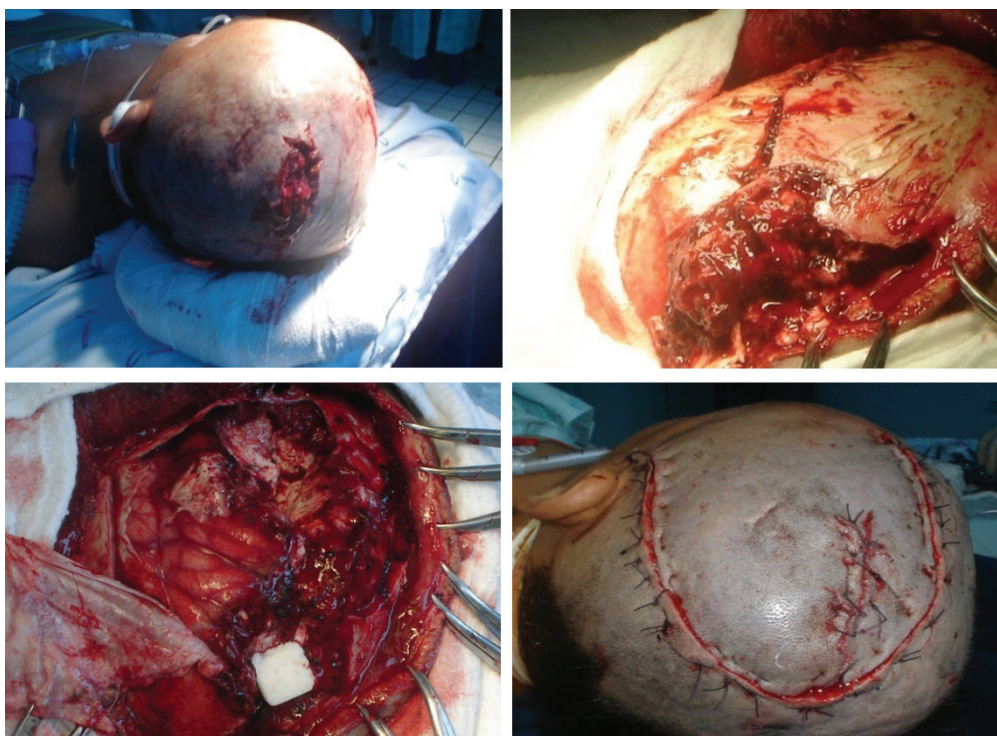


Fig. 3. Adult male victim of CGI during assault; patient received prompt transfer to our emergency service, receiving vigorous resuscitation despite GCS of 5 (E1V2M2) and emergent damage control neurosurgery. **A.** Image showing the inlet hole of CGI in left parietal region with perilesional tissue devitalization. **B.** comminuted left skull associated to dural tear, brain laceration and output of macerated brain parenchyma. **C.** Postoperative image of subtotal left fronto-parietal lobectomy with drain of left intraparenchymal hemorrhage; also evidence a blunt and congestive hemisphere. **D.** Incisional raffia with Corachan points.

graft can be recommended.

Regarding to craniotomy or craniectomy in patients with military injuries, Rish *et al.*, [38,39] recommendation is the most important, the standard protocol includes exposure of the surgical field from the skull defect by craniectomy to the periphery, removing devitalized tissue, however, in this study there was no difference among the two groups in terms of morbidity including postoperative infection and mortality, in addition there was no ability to control the factors which initially led to the decision to perform craniotomy before craniectomy.

In terms of timing to perform cranioplasty in military wounds the most representative study is Hammon and Kemp, [40] the findings of the study were:

1. The incidence of post-cranioplasty complications was 56%, who had complications during the initial care i.e. CSF fistula or infection.

2. Cranioplasty after 1 year following injury is recommended. (Post-cranioplasty complication was 4 % after 1 year versus 20 % within 1 year.

3. In patients without baseline complications there is no difference in the infection rate or time of cranioplasty.

Management of Complications

Vascular Complications of CGI

The angiography may be considered to identify traumatic intracranial aneurysms (TICA) and arteriovenous fistulas in patients with SHW in orbito-facial or pterional region or cavernous sinus region. About 0.4% and 0.7% of all aneurysms are caused by trauma and approximately 20% of traumatic aneurysms are due to penetrating head traumas. The branches of the middle cerebral artery and the anterior cerebral artery are the most vulnerable to penetrating trauma, followed by the internal carotid artery. TICA should be suspected in patients with CGI, presenting with secondary neurological deterioration; [41] are rare occurrences [42]. TICA may appear as early within first two hours of the injury, but also appear in a delayed fashion. TICA may regress, resolve, or grow with time; and can be associated with intracranial hemorrhage in 80% of cases and subdural hematomas in 26% of cases; whenever possible, TICAs should be trapped and excised [42]. The evolution of diagnostic neuroangiographic techniques provides an optimal opportunities for noninvasive endovascular therapy of traumatic vascular lesions of the head and neck, attractive options in selected cases [43].

Management of CSF Fistulas

During primary surgery all efforts should be directed to primary repair of the dura to prevent CSF fistulas. Surgical correction is recommended for CSF fistulas, if do not close spontaneously or refractory to medical management. The management of fistulas in the inlet

and outlet of the projectile require the meticulous closure of the dura mater, fascia and skin. Infection is the most common complication of penetrating brain injuries and is directly associated with increased morbidity and mortality, [44] so prevention is essential to optimize their prognosis regardless of the initial management of the injury.

Factors determinants of infection include: [44-46]

1. Presence of retained fragments of bone or metal
2. Timing of surgery.
3. Use of antibiotics.
4. Presence of CSF fistulas.

In the study of Meirowsky *et al.*, [47] only 50% of the fistulas were at the site of entry or exit of the projectile, 72% occurred within the first 2 weeks of trauma while about 44% closed spontaneously. The early treatment of CSF fistulas reduces is the risk of infective complications and associated morbidity and mortality.

Antibiotic Prophylaxis in CGI

The use of broad spectrum antibiotics is recommended in patients with penetrating brain trauma [48]. The risk of intracranial infection in penetrating brain trauma is high due to the presence of foreign bodies, bone fragments, contaminated skin and hair in the path of the projectile.

The infection rate in the pre-antibiotic era during World War I as reported by Whitaker [49] was 58.8% in the Second World War in the Post-Antibiotic Era in Slemont study compared the use of Sulfa Local and / or parenteral sulfonamide with an infection rate of 21% to 31%, but when added penicillin the infection rate dropped from 5.7% to 13% [50].

Regard bacteriological cultures, Carey in Vietnam reported 45% of the fragments removed mainly had positive cultures for gram-positive bacteria; [51] in the study of Hagan in the Vietnam War, Staphylococcus epidermidis was isolated; [52] Aarabi in a study during the Iran-Iraq War 1983-1984, observed positive cultures in approximately 20% of cases, isolates included staphylococcus, streptococcus and Acinetobacter, and positive cultures in brain tissue removed for staph, Acinetobacter, Escherichia coli, Klebsiella and Enterobacter [11].

Risk factors for infection in CGI, according to Arendall, [53] are 29% for sinuses wound and 49% according to Meirowsky [47] for CSF fistulas. Regarding selection of the of antimicrobial agents as prophylaxis for penetrating brain trauma, there is considerable variability, in a survey about Neurosurgical practice in the U.S. Kaufman *et al.*, [54] reported that 87% of respondents neurosurgeons used cephalosporin, 24% used chloramphenicol, 16% penicillin, 12% aminoglycosides and 6% vancomycin, less frequently used agents were erythromycin, miconazole and tetracyclines.

In patients who underwent surgery for removal of bullet fragments, wound debridement, and watertight

dural closure, administration of prophylactic antibiotics was not associated with the incidence of intracranial infection secondary to PCGWs. Projectile trajectory through potentially contaminating cavities, persistence of intraparenchymal osseous or metallic fragments after surgery, and prolonged hospital stay were independent risk factors for; postoperative intracranial infection [55].

Anticonvulsive Prophylaxis in CGI

Between 30 and 50% of patients with penetrating brain trauma develop seizures, about 4 to 10% of them had first seizure within the first week and 80 % during the first two years, however, the risk decreases with time. Anticonvulsant medications in the first week after penetrating brain trauma are recommended to prevent early posttraumatic seizures (phenytoin, carbamazepine, valproic acid, and phenobarbital). Prophylactic treatment with anticonvulsants beyond the first week after penetrating brain trauma has not proven to prevent the development of new seizures and is not recommended. The results of previous studies have not shown any significant correlation between retained fragments and posttraumatic epilepsy [1,56].

Mortality and Prognosis

With regard to mortality, CGI, can have a mortality rate after penetrating craniocerebral injury varying from 23% to 92%, with higher mortality rates, approximately 87% to 100% in patients with poor neurologic status on presentation [11,33,54,57,58]. After surgical interventions mortality rates of CGI has been reported to be about 20% [59] in earlier studies and 7.4% [60] to 18.7% [61] in recent studies. Murano *et al.* observed the following variables as predictors of death: respiratory arrest on admission, hypotension on admission, trans hemispheric and transventricular CGI [62].

As mentioned previously, one of the first challenges in managing patients with CGI is determining whether any intervention will result in an outcome that is acceptable to the patient, family, and society, [63] in this regard, the post resuscitation GCS is the

most reliable and significant clinical predictor of outcome [5,61,64-66]. The series reported by Khan *et al.* confirmed the strong correlation between post-resuscitation GCS score and outcome [67]. Interestingly, however, authors found no difference in outcome between penetrating and perforating wounds. However, Joseph *et al.* found that survival rate increased incrementally over time to a rate of 46% with early aggressive resuscitation of all patients with gunshot wounds to the brain regardless of their presenting clinical presentation, [68] recommending that notion of low GCS should not deter the use of resources to treat and manage these patients [68]. Other clinical prognostic factors include dilated nonreactive pupils, hypotension, hypoxia, coagulopathy, suicide attempt, advanced age, and presence of the perforating wounds [1,11,25,64,66].

Summary

There have been few recent studies involving penetrating craniocerebral injuries, and most studies were restricted to small numbers of patients, which failed to plan about definitive management protocol to prediction of mortality. However, classic studies in military and civil environment; CGI is identified as a highly lethal or devastating violent condition, able to produce marked consequences to the affected individual, the family and the health system itself. Unfortunately it is highly prevalent in the developing countries, with major armed conflicts, since the main trigger is violence at the national or state level. Various measures aimed to lower the incidence of CGI, especially in civilians. It is important to recognize the role of vigorous and intense resuscitation but should always be evaluated together with predictors of mortality, to provide an individualized treatment approach, especially because injuries as each projectile are different and unique. It is heightened urgency to continue promoting research in a neurocritical care such as CGI, for producing positive impact on the quality of life of CGI survivors.

Conflict of Interest: None declared.

References

1. Part I: Guidelines for the management of penetrating brain injury. Introduction and methodology. *J Trauma*. 2001;**51**(2 Suppl):S3-6.
2. Selden BS, Goodman JM, Cordell W, Rodman GH, Jr., Schnitzer PG. Outcome of self-inflicted gunshot wounds of the brain. *Ann Emerg Med*. 1988;**17**(3):247-53.
3. Shaffrey ME, Polin RS, Phillips CD, Germanson T, Shaffrey CI, Jane JA. Classification of civilian craniocerebral gunshot wounds: a multivariate analysis predictive of mortality. *J Neurotrauma*. 1992;**9** Suppl 1:S279-85.
4. Cavaliere R, Cavenago L, Siccardi D, Viale G. Gunshot wounds of the brain in civilians. *Acta Neurochir (Wien)*. 1988;**94**(3-4):133-6.
5. Levy ML, Masri LS, Lavine S, Apuzzo ML. Outcome prediction after penetrating craniocerebral injury in a civilian population: aggressive surgical management in patients with admission Glasgow Coma Scale scores of 3, 4, or 5. *Neurosurg*. 1994;**35**(1):77-85.
6. Barach E, Tomlanovich M, Nowak R. Ballistics: a pathophysiologic examination of the wounding mechanisms of firearms: Part I. *J Trauma*. 1986; **26** (3):225-35.
7. Esposito DP, Walker JB. Contemporary management of penetrating brain injury. *Neurosurgery Quarterly*. 2009;**19**(4):249-54.
8. Liker M, Aarabi B, Levy ML. Missile wounds to the head: ballistics and

- forensics. *Missile wounds of head and neck*. 1999;1:35-55.
9. Harvey EN, McMillen JH. An experimental study of shock waves resulting from the impact of high velocity missiles on animal tissues. *J Exp Med*. 1947;85(3):321-8
 10. Clark WC, Muhlbauer MS, Watridge CB, Ray MW. Analysis of 76 civilian craniocerebral gunshot wounds. *J Neurosurg*. 1986;65(1):9-14.
 11. Aarabi B. Surgical outcome in 435 patients who sustained missile head wounds during the Iran-Iraq War. *Neurosurgery*. 1990;27(5):692-5
 12. Carey ME. Experimental missile wounding of the brain. *Neurosurg Clin N Am*. 1995;6(4):629-42.
 13. Satyarthee GD, Mahapatra AK. Unusual presentation of retained bullet. *Panarab J Neurosurg* 2003;7(2): 205-208.
 14. Fackler ML, Malinowski JA. The wound profile: a visual method for quantifying gunshot wound components. *J Trauma*. 1985;25(6):522-9.
 15. Ordog GJ, Wasserberger J, Balasubramanium S. Wound ballistics: theory and practice. *Ann Emerg Med*. 1984;13(12):1113-22.
 16. Robles LA. High-velocity gunshot to the head presenting as initial minor head injury: things are not what they seem. *Am J Emerg Med*. 2012;30(9):2089 e5-7.
 17. Hadas N, Schiffer J, Rogev M, Shperber Y. Tangential low-velocity missile wound of the head with acute subdural hematoma: case report. *J Trauma*. 1990;30(3):358-9.
 18. Cushing H. Notes on penetrating wounds of the brain. *Br Med J*. 1918;1(2982):221-6.
 19. Matson DD. The treatment of acute craniocerebral injuries due to missiles. Charles C Thomas. 1948.
 20. Bakay L. Missile injuries of brain. *New York state journal of medicine*. 1982;82(3):313-9.
 21. Raimondi AJ, Samuelson GH. Craniocerebral gunshot wounds in civilian practice. *J Neurosurg*. 1970;32(6):647-53.
 22. Offiah C, Twigg S. Imaging assessment of penetrating craniocerebral and spinal trauma. *Clin Radiol*. 2009;64(12):1146-57.
 23. Gervaise A, Foscolo S, Rivierre A, Derelle A, Schmitt E, Braun M, et al. Imaging of cranial gunshot traumas. *Journal de radiologie*. 2010;91(11 Pt 1):1113-20.
 24. Rosenfeld JV. Gunshot injury to the head and spine. *J cli Neurosci* 2002;9(1):9-16.
 25. Kazim SF, Shamim MS, Tahir MZ, Enam SA, Waheed S. Management of penetrating brain injury. *J Emerg Trauma Shock*. 2011;4(3):395
 26. Hofbauer M, Kdolsky R, Figl M, Grunauer J, Aldrian S, Ostermann RC, et al. Predictive factors influencing the outcome after gunshot injuries to the head-a retrospective cohort study. *J Trauma*. 2010;69(4):770-5.
 27. Kim TW, Lee JK, Moon KS, Kwak HJ, Joo SP, Kim JH, et al. Penetrating gunshot injuries to the brain. *J Trauma*. 2007;62(6):1446-51.
 28. Hollerman JJ, Fackler ML, Coldwell DM, Ben-Menachem Y. Gunshot wounds: 2. Radiology. *AJR Am J Roentgenol*. 1990;155(4):691-702.
 29. Neuroimaging in the management of penetrating brain injury. *J Trauma*. 2001;51(2 Suppl):S7-11.
 30. Vascular complications of penetrating brain injury. *J Trauma*. 2001;51(2 Suppl):S26-8.
 31. Saito N, Hito R, Burke PA, Sakai O. Imaging of penetrating injuries of the head and neck:current practice at a level I trauma center in the United States. *Keio J Med*. 2014;63(2):23-33.
 32. Joseph B, Aziz H, Sadoun M, Kulvatunyou N, Pandit V, Tang A, et al. Fatal gunshot wound to the head: the impact of aggressive management. *Am J Surg*. 2014;207(1):89-94.
 33. Grahm TW, Williams FC, Jr., Harrington T, Spetzler RF. Civilian gunshot wounds to the head: a prospective study. *Neurosurgery*. 1990;27(5):696-700.
 34. Alvis-Miranda H, Castellar-Leones S, Moscote-Salazar L. Decompressive Craniectomy and Traumatic Brain Injury: A Review. *Bull Emerg Trauma*. 2013;1(2):60-8.
 35. Moscote-Salazar L, Alvis-Miranda H, Palencia C, Rubiano A. Emergent Decompressive Craniectomy in Patients with Fixed Dilated Pupils; A Single Center Experience. *Bull Emerg Trauma*. 2013;1(4):175-8.
 36. Kubal WS. Updated imaging of traumatic brain injury. *Radiol Clin North Am*. 2012;50(1):15-41.
 37. Tsuei Y-S, Sun M-H, Lee H-D, Chiang M-Z, Cheng W-Y, Shen C-C, et al. Civilian gunshot wounds to the brain. *J Chin Med Assoc*. 2005;68(3):126-30.
 38. Rish BL, Dillon JD, Caveness WF, Mohr JP, Kistler JP, Weiss GH. Evolution of craniotomy as a debridement technique for penetrating craniocerebral injuries. *J Neurosurg*. 1980;53(6):772-5.
 39. Rish BL, Dillon JD, Meierowsky AM, Caveness WF, Mohr JP, Kistler JP, et al. Cranioplasty: a review of 1030 cases of penetrating head injury. *Neurosurgery*. 1979;4(5):381-5.
 40. Hammon WM, Kempe LG. Methyl methacrylate cranioplasty. 13 years experience with 417 patients. *Acta Neurochir (Wien)*. 1971;25(1):69-77.
 41. Hachemi M, Jourdan C, Di Roio C, Turjman F, Ricci-Franchi A, Mottolese C, et al. Delayed rupture of traumatic aneurysm after civilian craniocerebral gunshot injury in children. *Childs Nerv Syst*. 2007;23(3):283-7.
 42. Horowitz MB, Kopitnik TA, Landreneau F, Ramnani DM, Rushing EJ, George E, et al. Multidisciplinary approach to traumatic intracranial aneurysms secondary to shotgun and handgun wounds. *Surg Neurol*. 1999;51(1):31-42.
 43. Diaz-Daza O, Arraiza FJ, Barkley JM, Whigham CJ. Endovascular therapy of traumatic vascular lesions of the head and neck. *Cardiovasc Intervent Radiol*. 2003;26(3):213-21.
 44. Gonul E, Baysefer A, Kahraman S, Ciklatekerlioglu O, Gezen F, Yayla O, et al. Causes of infections and management results in penetrating craniocerebral injuries. *Neurosurg Rev*. 1997;20(3):177-81.
 45. Cosar A, Gonul E, Kurt E, Gonul M, Tasar M, Yetiser S. Craniocerebral gunshot wounds: results of less aggressive surgery and complications. *Minim Invasive Neurosurg*. 2005;48(2):113-8.
 46. Satyarthee G D, Dawar P, Borkar S A., Sharma BS. Trans-orbital penetrating head injury (TOPHI): Short series of two cases with review of literature. *Ind J Neurotrauma* 2014; 11: 49–52.
 47. Meierowsky AM, Caveness WF, Dillon JD, Rish BL, Mohr JP, Kistler JP, et al. Cerebrospinal fluid fistulas complicating missile wounds of the brain. *J Neurosurg*. 1981;54(1):44-8.
 48. Bayston R, De Louvois J, Brown E, Johnston R, Lees P, Pople I. Use of antibiotics in penetrating craniocerebral injuries. *The Lancet*. 2000;355(9217):1813-7.
 49. Whitaker R. Gun shot wounds of the cranium: with special reference to those of the brain. *Br J Surg*. 1916; 3: 708–735.
 50. Slemmon H. Forward neurosurgery in Italy. *J Neurosurg*. 1945;2(4):332-9.
 51. Carey ME, Young H, Mathis JL, Forsythe J. A bacteriological study of craniocerebral missile wounds from Vietnam. *J Neurosurg*. 1971;34(2 Pt 1):145-54.
 52. Hagan RE. Early complications following penetrating wounds of the brain. *J Neurosurg*. 1971;34(2 Pt 1):132-41.
 53. Arendall RE, Meierowsky AM. Air sinus wounds: an analysis of 163 consecutive cases incurred

- in the Korean War, 1950-1952. *Neurosurgery*. 1983;**13**(4):377-80.
54. Kaufman HH. Civilian gunshot wounds to the head. *Neurosurgery*. 1993;**32**(6):962-4.
 55. Jimenez CM, Polo J, Espana JA. Risk factors for intracranial infection secondary to penetrating craniocerebral gunshot wounds in civilian practice. *World Neurosurg*. 2013;**79**(5-6):749-55.
 56. George ED, Dagi TF. Military penetrating craniocerebral injuries. Applications to civilian triage and management. *Neurosurg Clin N Am*. 1995;**6**(4):753-9.
 57. Nagib MG, Rockswold GL, Sherman RS, Lagaard MW. Civilian gunshot wounds to the brain: prognosis and management. *Neurosurgery*. 1986;**18**(5):533-7.
 58. Part 2: Prognosis in penetrating brain injury. *J Trauma*. 2001;**51**(2 Suppl):S44-86
 59. Becker DP, Miller JD, Ward JD, Greenberg RP, Young HF, Sakalas R. The outcome from severe head injury with early diagnosis and intensive management. *J Neurosurg*. 1977;**47**(4):491-502.
 60. Liebenberg WA, Demetriades AK, Hankins M, Hardwidge C, Hartzenberg BH. Penetrating civilian craniocerebral gunshot wounds: a protocol of delayed surgery. *Neurosurgery*. 2005;**57**(2):293-9; discussion -9.
 61. Ozkan U, Kemaloglu S, Ozates M, Aydin MD. Analysis of 107 civilian craniocerebral gunshot wounds. *Neurosurg Rev*. 2002;**25**(4):231-6.
 62. Murano T, Mohr AM, Lavery RF, Lynch C, Homnick AT, Livingston DH. Civilian craniocerebral gunshot wounds: an update in predicting outcomes. *Am Surg*. 2005;**71**(12):1009-14.
 63. Ecklund JM, Sioutos P. Prognosis for gunshot wounds to the head. *World Neurosurg*. 2014;**82**(1-2):27-9.
 64. Ambrosi PB, Valenca MM, Azevedo-Filho H. Prognostic factors in civilian gunshot wounds to the head: a series of 110 surgical patients and brief literature review. *Neurosurg Rev*. 2012;**35**(3):429-35; discussion 35-6.
 65. Hofbauer M, Kdolsky R, Figl M, Grunauer J, Aldrian S, Ostermann RC, et al. Predictive factors influencing the outcome after gunshot injuries to the head-a retrospective cohort study. *J Trauma*. 2010;**69**(4):770-5.
 66. Rish BL, Caveness WF, Dillon JD, Kistler JP, Mohr JP, Weiss GH. Analysis of brain abscess after penetrating craniocerebral injuries in Vietnam. *Neurosurgery*. 1981;**9**(5):535-41.
 67. Khan MB, Kumar R, Irfan FB, Irfan AB, Bari ME. Civilian craniocerebral gunshot injuries in a developing country: presentation, injury characteristics, prognostic indicators, and complications. *World Neurosurg*. 2014;**82**(1-2):14-9
 68. Joseph B, Aziz H, Pandit V, Kulvatunyou N, O'Keeffe T, Wynne J, et al. Improving survival rates after civilian gunshot wounds to the brain. *J Am Coll Surg*. 2014;**218**(1):58-65.