

## Subsegmental pulmonary embolus as a precipitating factor for takotsubo cardiomyopathy

Victor Y. Yu, MD, MSE; David A. Leitman, DO; Troy B. Graybeal, MD; and Christian W. Cox, MD

Known commonly as “broken heart syndrome,” takotsubo cardiomyopathy is a poorly understood heart condition that results in acute decompensation of cardiac function. We report a case of a 68-year-old female who developed acute shortness of breath status after chemotherapy and radiation treatment for Stage IV squamous-cell carcinoma. Computed tomography pulmonary angiogram (CTPA) revealed a single subsegmental pulmonary embolism, pulmonary edema, and left ventricular dilatation. Further evaluation revealed evidence of reversible cardiomyopathy with left ventricular apical ballooning, consistent with takotsubo cardiomyopathy. In reviewing the case, we cover the Mayo clinic criteria for diagnosis of takotsubo cardiomyopathy, and we consider pulmonary embolism as a precipitating factor.

### Introduction

Takotsubo cardiomyopathy, a condition found predominantly in postmenopausal women, features signs and symptoms of an acute myocardial infarction without evidence of obstructive coronary artery disease (1). In 1991, Sato et al first described takotsubo cardiomyopathy in a five-case series with a Japanese population. Named after the shape of the octopus trap (tako tsubo), the heart appears narrowed at the base with ballooning of the apex. Hypercontractility of the basal segments accounts for the narrowed base (2). This disorder has several alternative names, including stress cardiomyopathy, transient left ventricular apical ballooning syndrome, and “broken heart” syndrome. The pathogenesis of takotsubo cardiomyopathy is not well understood. Postulated mechanisms include catecholamine excess, coronary artery vasospasm, and estrogen deficiency (3, 4). Takotsubo cardiomyopathy is marked by rapid improvement of symp-

toms and systolic function within one to three weeks. This condition has an excellent prognosis with a morbidity of 1% and a recurrence rate of less than 10% (2).

### Case report

A 68-year-old female presented to the emergency department after noting right lower extremity pain and mild dyspnea during a gastroenterology exam. Past medical history was significant for Stage IV squamous-cell carcinoma of the lung with bone metastasis. Computed tomography pulmonary angiogram (CTPA) at that time showed no evidence of a pulmonary embolus (PE). A lower-extremity computed tomography venogram (CTV) demonstrated a deep venous thrombosis in the right popliteal fossa, for which the patient was placed on therapeutic Lovenox (enoxaparin sodium).

During subsequent admission for dysphagia, dyspnea, and right-lower-extremity pain, the patient became acutely dyspneic. Repeat CTPA demonstrated a subsegmental right middle lobe pulmonary embolus (Fig. 1) in addition to pulmonary edema (Fig. 2) and left ventricular dilatation (Fig. 3).

During the CTPA, the patient’s respiratory status worsened, and she required intubation. An electrocardiogram (ECG) demonstrated poor R-wave progression with no evidence of ST elevation in the precordial leads. She had a mildly elevated troponin I of 0.95. An echocardiogram demonstrated global hypokinesis and apical ballooning with an ejection fraction (EF) of 20% (Fig. 4A).

---

**Citation:** Yu VY, Leitman DA, Graybeal TB, Cox CW. Subsegmental pulmonary embolus as a precipitating factor for takotsubo cardiomyopathy. *Radiology Case Reports*. (Online) 2011;6:531.

**Copyright:** © 2011 The Authors. This is an open-access article distributed under the terms of the Creative Commons Attribution-NonCommercial-NoDerivs 2.5 License, which permits reproduction and distribution, provided the original work is properly cited. Commercial use and derivative works are not permitted.

The authors are all affiliated with the Madigan Healthcare System, Tacoma WA. Contact Dr. Yu at [Victor.Yu@us.army.mil](mailto:Victor.Yu@us.army.mil).

**Competing Interests:** The authors have declared that no competing interests exist.

**DOI:** 10.2484/rcr.v6i3.531

## Subsegmental pulmonary embolus as a precipitating factor for takotsubo cardiomyopathy

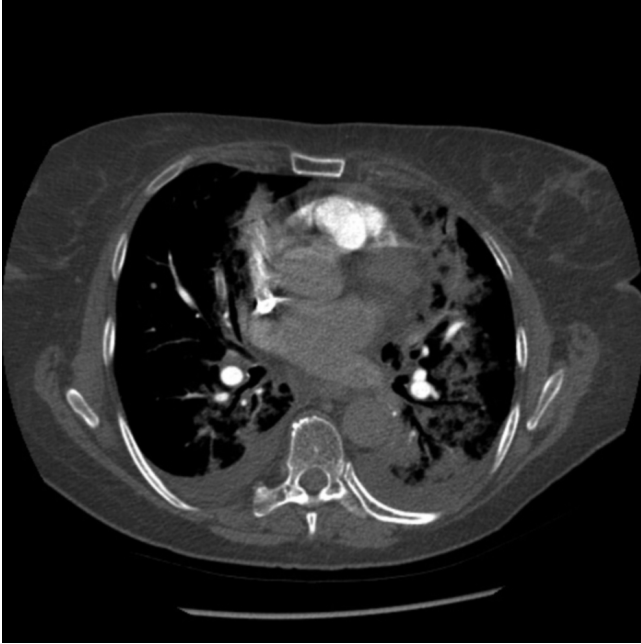

Figure 1. 68-year-old female with takotsubo cardiomyopathy. CTPA demonstrating right middle lobe subsegmental pulmonary embolus discovered at the time of the hypoxic event.

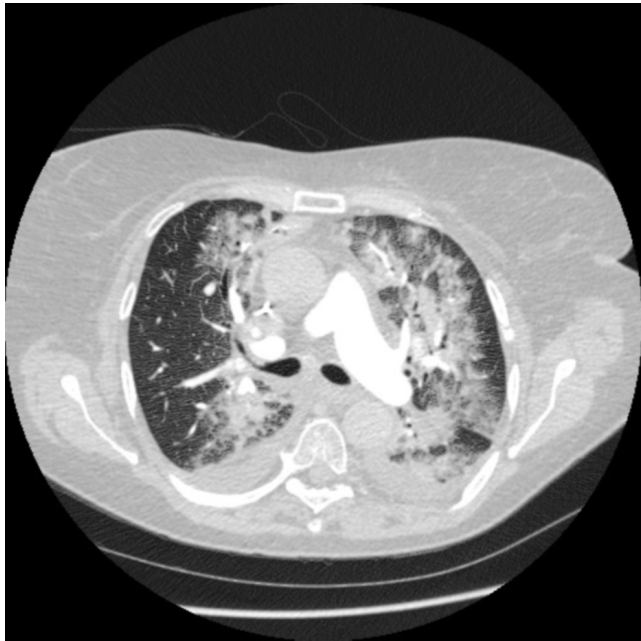


Figure 2. 68-year-old female with takotsubo cardiomyopathy. CTPA of patient during acute hypoxic event demonstrating diffuse bilateral, perihilar, acinar opacity, consistent with pulmonary edema.

An emergent coronary angiogram demonstrated normal anatomy, with with no flow-limiting lesions observed (Fig. 5), consistent with presumed takotsubo cardiomyopathy.

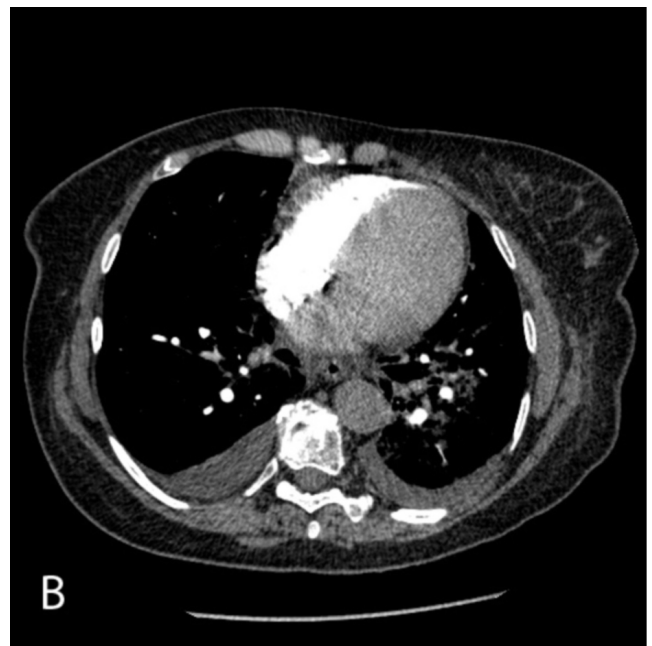
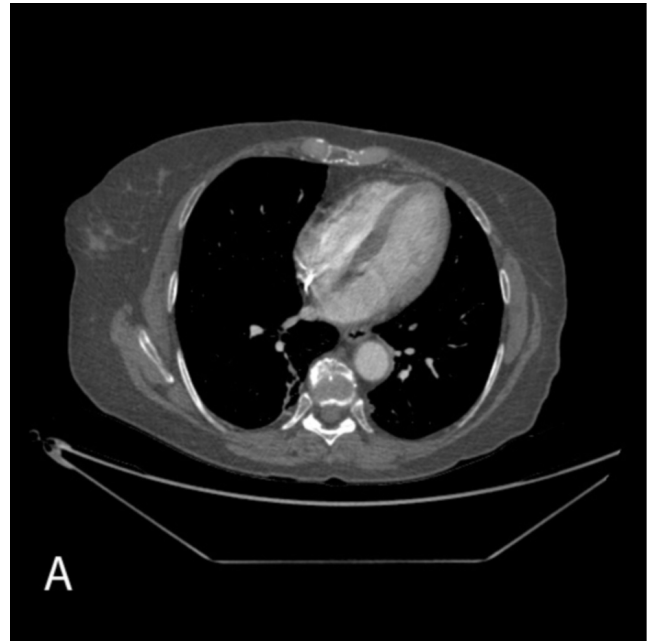


Figure 3. 68-year-old female with takotsubo cardiomyopathy. A) Axial CT of patient three days before acute hypoxic decompensation. The image demonstrates normal left ventricular size. B) Axial CT of patient obtained during the hypoxic event. The image demonstrates left ventricular apical ballooning.

## Subsegmental pulmonary embolus as a precipitating factor for takotsubo cardiomyopathy

The patient received standard treatment including a diuretic, an angiotensin-converting enzyme (ACE) inhibitor, and a beta blocker. Repeat echocardiogram on hospital day nine demonstrated improved cardiac contractility, an appropriately moving cardiac apex, and an EF of 50% (Fig. 4B). The patient was discharged two days later with cardiology followup scheduled.

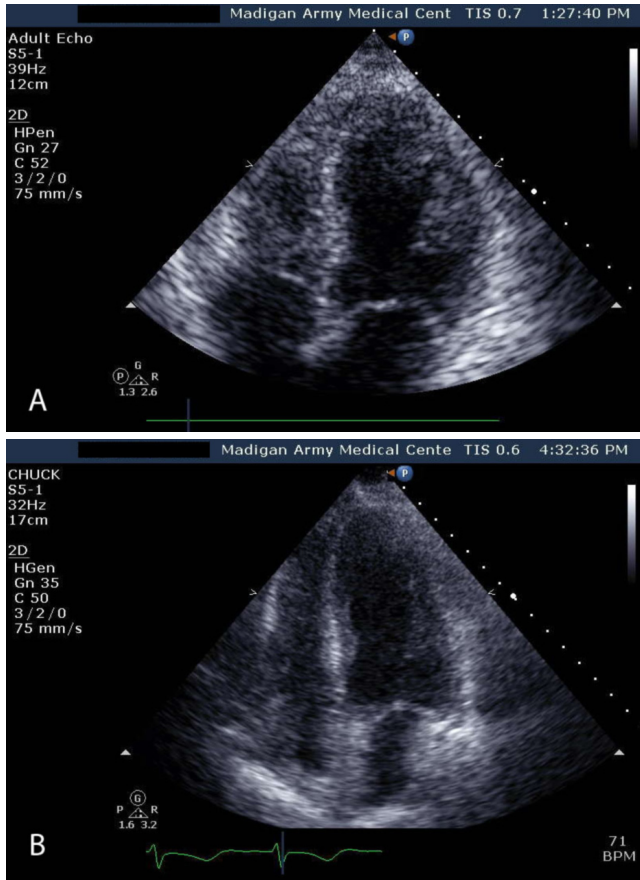


Figure 4. 68-year-old female with takotsubo cardiomyopathy. A) Bedside echocardiogram of patient during acute hypoxic event demonstrating left ventricular apical ballooning and severe LV dysfunction (EF of 20%). B) Bedside echocardiogram four days later demonstrating resolution of cardiomyopathy (EF of 50%).

### Discussion

The incidence of stress-induced cardiomyopathy has increased over the last few years, most likely from better characterization of this syndrome. In 2004, the Mayo Clinic defined takotsubo cardiomyopathy as (4):

1. Transient akinesis or dyskinesis of the left ventricular apical and mid-ventricular segments with regional wall-motion abnormalities extending beyond a single epicardial vascular distribution

2. Absence of obstructive coronary disease or angiographic evidence of acute plaque rupture
3. New electrocardiographic abnormalities (either ST-segment elevation or T-wave inversion) or modest elevation in cardiac troponin
4. Absence of recent significant head trauma, intracranial bleeding, pheochromocytoma, myocarditis, and hypertrophic cardiomyopathy (1)

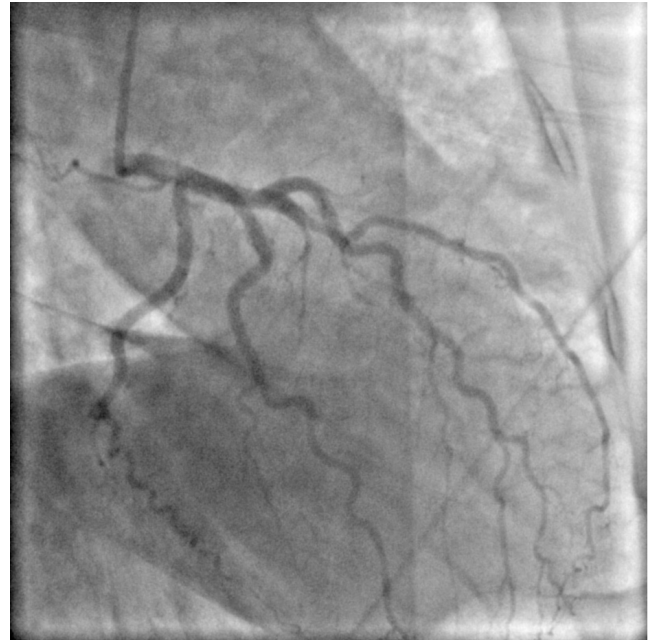


Figure 5. 68-year-old female with takotsubo cardiomyopathy. Coronary angiogram obtained at time of acute decompensation demonstrating normal anatomy with no flow-limiting lesions observed.

All four of these criteria must be met in order to diagnose takotsubo cardiomyopathy.

Patients with takotsubo cardiomyopathy typically present with symptoms and signs similar to that of a patient with acute coronary syndrome (5). A systematic review of 286 patients with takotsubo cardiomyopathy revealed the following key features (2):

- Postmenopausal females represent more than 80% of cases.
- Chest pain (68.8%) and dyspnea (17.8%) are the most common presenting complaints.
- A physical stressor preceded takotsubo cardiomyopathy in 37.8% of patients.
- An emotional stressor preceded takotsubo cardiomyopathy in 26.8% of patients.
- No physical or emotional stressor was identified in 34.3% of patients.
- ST segment elevation (81.6%), T wave abnormalities (64.3%), and Q waves (31.8%) are commonly seen.

## Subsegmental pulmonary embolus as a precipitating factor for takotsubo cardiomyopathy

- Troponin elevation is demonstrated in 86.2% of patients.
- Coronary artery catheterization demonstrates normal coronary arteries in 80.6% of cases and mild nonobstructive disease in 19.4% of cases.

Our patient demonstrated a classic presentation of takotsubo cardiomyopathy. She had underlying emotional and physical stressors, with a recent diagnosis of Stage IV squamous-cell carcinoma and recent completion of radiation and chemotherapy treatments. More acutely identifiable stressors included upper gastrointestinal endoscopy performed the day before developing cardiac dysfunction, as well as development of deep venous thrombosis with ensuing subsegmental PE. Our patient became acutely dyspneic, which is the second most common presentation for patients with takotsubo cardiomyopathy. She initially had an elevated troponin, decreased EF, and negative cardiac catheterization. As expected, troponin levels normalized within 24 hours, and left ventricular EF improved to 50% after four days. The subsegmental PE was the likely inciting event that precipitated her “broken heart” syndrome, given that she developed takotsubo cardiomyopathy-like symptoms, lab abnormalities, and echocardiogram changes at the same time that she was diagnosed with the subsegmental PE.

Acknowledgements/disclaimer: The views expressed are those of the author(s) and do not reflect the official policy of the Department of the Army, the Department of Defense, or the U.S. Government.

## References

1. Akashi YJ, Goldstein DS, Barbaro G, et al. Takotsubo cardiomyopathy: a new form of acute, reversible heart failure. *Circulation* 2008; 118:2754-2762. [\[PubMed\]](#)
2. Gianni M, Dentali F, Grandi AM, et al. Apical ballooning syndrome or takotsubo cardiomyopathy: a systematic review. *European Heart Journal* 2006; 27: 1523-1529. [\[PubMed\]](#)
3. Prasad A, Lerman A, Rihal CS. Apical ballooning syndrome (Tako-Tsubo or stress cardiomyopathy): a mimic of acute myocardial infarction. *Am Heart J*. 2008 Mar;155(3):408-17. [\[PubMed\]](#)
4. Bybee KA, Kara T, Prasad A, Lerman A, Barsness GW, Wright RS, Rihal CS. Systematic review: transient left ventricular apical ballooning: a syndrome that mimics ST-segment elevation myocardial infarction. *Annals of Internal Medicine* 2004; 141:858-865. [\[PubMed\]](#)
5. Kurowski V, Kaiser A, Von Hof K, et al. Apical and midventricular transient left ventricular dysfunction syndrome (tako-tsubo cardiomyopathy) frequency, mechanisms, and prognosis. *Chest* 2007; 132:809-16. [\[PubMed\]](#)