

Right-sided Aorta*

Part I: Occurrence of Right Aortic Arch in Various Types of Congenital Heart Disease

ALOIS R. HASTREITER, IVAN A. D'CRUZ, AND TALAT CANTEZ

Part II: Right Aortic Arch, Right Descending Aorta, and Associated Anomalies

IVAN A. D'CRUZ, TALAT CANTEZ, ERNESTO P. NAMIN,
RICHARD LICATA, AND ALOIS R. HASTREITER

From the Department of Pediatric Cardiology, Cook County Children's Hospital, Hektoen Institute for Medical Research, and The University of Illinois College of Medicine, Chicago, Illinois, U.S.A.

Part I

A right-sided aortic arch was first described two centuries ago by Fioratti and Aglietti (1763). Fifty-five years later, Corvisart (1818) reported its occurrence in a case of tetralogy of Fallot. A right-sided arch of the aorta has since been shown to occur with various other types of congenital heart lesions.

PRESENT STUDY

The present report deals with the findings from a total of 116 children or young adults with a right aortic arch. In all these cases the aortic arch was specifically studied at necropsy or could be located from angiocardiology. The diagnosis of the associated congenital cardiovascular lesions was established by cardiac catheterization, angiocardiology, operation, or post-mortem examination. This study reviews the occurrence of a right-sided aortic arch in various congenital cardiac malformations (Tables I and II) and its significance in the differential diagnosis of these lesions.

The frequency of occurrence of a right-sided

aortic arch among adults is approximately 0.1 per cent. The largest series of consecutive necropsies reporting its incidence is that of Biedermann (1931) who found 8 cases among about 20,000 post-mortem examinations (0.04%). More recent data, dealing with a smaller number of necropsies but perhaps a more accurate analysis, report the incidence of 0.1 per cent. Thus, Liechty, Shields, and Anson (1957) and Anson (1961) each found one instance of a right-sided aortic arch among 1000 cadavers examined independently for aortic arch anomalies in their anatomy departments.

Following the recognition that the side of the aortic arch could be determined from a conventional postero-anterior radiograph of the chest, several instances of right aortic arch occurring in otherwise normal persons were described by radiologists (Spencer and Dresser, 1936; Bedford and Parkinson, 1936; Eisen, 1944).

Figures reporting the incidence of a right aortic arch from the examination of large series of consecutive chest radiographs range from 0.1 per cent (Nozaki and Sekiya, 1948; Nozaki and Maki, 1950) to 0.14 per cent (Biedermann, 1931), based on an analysis of 15,000 and 5000 cases, respectively. In the present series, there were only four children with a right-sided aortic arch unassociated with congenital cardiovascular anomalies (Fig. 1 on p. 726).

A right aortic arch is seldom, if ever, found in

Received November 22, 1965.

* Supported in part by Research Grant HE 03518-07 from the National Heart Institute, National Institutes of Health, United States Public Health Service.

TABLE I
FREQUENCY OF OCCURRENCE OF RIGHT AORTIC ARCH IN LARGE SERIES OF PATIENTS WITH
CONGENITAL CARDIOVASCULAR LESIONS

Author	Year	No. of cases	No. with right arch	Per cent	Congenital heart lesion	Remarks
Anson	1961	1000	1	0.1	Normal cadavers	14 cases had normal hearts, 21 had associated cardiac defects
Liechty <i>et al.</i>	1957	1000	1	0.1	Normal cadavers	
Abbott	1936	1000	35	3.5	All congenital heart	
Blalock and Bahnson	1948	610		23.6	Cyanotic heart disease with subclavian pulmonary anastomosis	
Baker <i>et al.</i>	1949	50		28.0	Cyanotic heart disease with subclavian pulmonary anastomosis	
Dammann <i>et al.</i>	1949	108		26.0	Tetralogy	
Brinton and Campbell	1953	25		24.0	Tetralogy	
Lowe	1953	47		12.8	Tetralogy	
Edwards	1960	56		18.0	Tetralogy	
Keith <i>et al.</i>	1958	329		30.0	Tetralogy	
Wood	1956	160		17.0	Tetralogy	
Our series	1965	167	59	34.0	Tetralogy	
Keith <i>et al.</i>	1958	49	4	8.8	Tricuspid atresia	
Our series	1965	26	2	7.7	Tricuspid atresia	
Collett and Edwards	1949	76	11	15.0	Truncus	
Tandon, Hauck, and Nadas	1963	15	5	33.3	Truncus	
Keith <i>et al.</i>	1958	9		60.0	Truncus	
Our series	1965	22	8	36.0	Truncus	
Elliott <i>et al.</i>	1963	61	3	4.9	Transposition	All 3 had VSD and PS
Keith <i>et al.</i>	1958	108	4	3.7	Transposition	
Our series	1965	60	4	6.7	Transposition	All 4 had VSD, 3 had PS
Brotmacher and Campbell	1958	175	4	2.3	Ventricular septal defect	
Our series	1965	310	8	2.6	Ventricular septal defect	

TABLE II
INCIDENCE OF RIGHT AORTIC ARCH*

Cardiac diagnosis	No. of patients*	Right aortic arch		Incidence of right aortic arch (%)
		Right descending aorta	Left descending aorta	
Normal	—	3	1	—
Pulmonary stenosis with intact ventricular septum	92	2	0	2.2
Ventricular septal defect	310	7	1	2.6
Tetralogy	167	56	3	34.0
Truncus	22	6	2	36.0
Transposition	60	4	0	6.7
Double outlet right ventricle	8	2	0	25.0
Taussig-Bing	16	0	0	—
Tricuspid atresia	26	2	0	7.7
Atrio-ventricular canal	—	1	1	—
Corrected transposition	—	0	1	—
Lævocardia—with partial or complete situs inversus	30	12	0	40.0
Dextrocardia—with complete situs inversus	17	16	0	94.0
Dextrocardia—with right-sided venous atrium	14	7	0	14.0

* Only those patients in whom the side of the aortic arch was definitely stated in the necropsy report, or visualized by angiocardiography were included.

association with isolated atrial septal defect, isolated anomalies of pulmonary venous drainage, and some left-sided heart lesions such as congenital mitral stenosis, mitral insufficiency, or aortic stenosis. It is not present in our cases, nor has right aortic arch been mentioned as an associated finding in many large series of patients with these anomalies. Isolated instances of a right aortic arch associated with coarctation of the aorta and patent ductus

arteriosus have been described (Stewart, Kincaid, and Edwards, 1964; Felson and Palayew, 1963).

Pulmonary stenosis with intact ventricular septum is almost invariably associated with a left aortic arch. Hence the presence of a right aortic arch in a patient clinically suspected of having pulmonary stenosis suggests an associated ventricular septal defect. To our knowledge, only two instances of the association of right aortic arch with isolated pulmonary stenosis

have been reported (Campbell, 1954; Bressie, 1964). We found one additional case among our 92 patients with isolated pulmonary stenosis (see Fig. 8). One other patient had isolated supravalvular stenosis of the pulmonary trunk and a right aortic arch.

Brotmacher and Campbell (1958) found a right aortic arch in 4 of 175 patients with isolated ventricular septal defect (2.3%). Wood (1958) noted that 16 per cent of his patients with ventricular septal defect and pulmonary hypertension at systemic level had a right aortic arch, and mentioned this as a diagnostic clue helpful in distinguishing this group from those with pulmonary hypertension and communications at atrial or ductal levels. Espinova and Mata (1956) described four cases of Eisenmenger's complex, of which one *definitely* and another *probably* had a right aortic arch. They commented that "a right aortic arch is very often indicative of the co-existence of a bulbo-septal malformation". However, in a review of 35 reported cases of Eisenmenger's complex, Selzer and Laqueur (1951) found only one with a right aortic arch. We found 8 with right aortic arch among 310 patients with isolated ventricular septal defect in whom the side of the aortic arch was definitely known (2.6%). In these 8, the cardiac lesions varied in severity, from small ventricular septal defects with normal pulmonary artery pressures, to large defects with systemic pulmonary artery pressures.

The association of a right aortic arch with tetralogy of Fallot (Corvisart's disease) is well known. It varies from 13 to 34 per cent in different series (Dammann, Gibson, and Potts, 1949; Brinton and Campbell, 1953; Lowe, 1953; Edwards, 1960; Keith, Rowe, and Vlad, 1958; Wood, 1956). It occurred in 34 per cent of our 167 patients with this anomaly. The diagnostic importance of a right aortic arch accompanying a tetralogy of Fallot complex is of special significance in the so-called acyanotic variety. Nadas (1963) stated that 25 per cent of children with this lesion have a right aortic arch. Some may have a large left-to-right shunt early in life, and later develop progressive pulmonary infundibular stenosis and cyanosis. Of 15 reported cases of tetralogy of Fallot with absent pulmonary valve, in which the side of the aortic arch was stated, 5 had a right aortic arch. Other aspects of aortic arch anomalies found in association with tetralogy of Fallot are alluded to in succeeding sections of this paper.

As many as 60 per cent of Keith's cases of persistent truncus arteriosus and 36 per cent of the present series had the aortic arch on the right side (Keith *et al.*, 1958). However, of 76 reported cases collected by Collett and Edwards (1949), in which the side of the arch was specifically stated, it

was right-sided in only 11 (14.5%). They did not find any striking association between right aortic arch and any of their four anatomical types of persistent truncus arteriosus.

A right aortic arch is found in about 8 per cent of the cases with tricuspid atresia complexes. Certain subtypes of tricuspid atresia lesions appear to have a higher incidence of a right aortic arch than the group as a whole. Thus, Keith *et al.* (1958) noted that when a right aortic arch occurred with tricuspid atresia, it was usually in their subtype 1b (with pulmonary artery hypoplasia, subpulmonary stenosis, and small ventricular septal defect). One of our two patients with tricuspid atresia and a right aortic arch was of this type; the other differed only in that pulmonary atresia rather than stenosis was present. Similar cases have been reported by others (Wittenborg, Neuhauser, and Sprunt, 1951; Sommers and Johnson, 1951; Marder, Seaman, and Scott, 1953).

In complete transposition of the great vessels the incidence of a right aortic arch is relatively low. It was approximately 4 to 5 per cent in two series (Keith *et al.*, 1958; Elliott *et al.*, 1963). The occurrence of a right aortic arch appears to be higher in those cases of transposition associated with a ventricular septal defect and pulmonary stenosis. This was true of our series, in which all cases of complete transposition of the great vessels with a right aortic arch had a ventricular septal defect and pulmonary stenosis (Elliott *et al.*, 1963). Lev, Alcalde, and Baffes (1961) did not mention right aortic arch as an associated anomaly in 51 instances of transposition without associated defects and in 54 instances of transposition with a ventricular septal defect. A right-sided aortic arch was present, however, in much smaller groups of transposition with a ventricular septal defect and pulmonary stenosis, transposition with tricuspid atresia or stenosis, and transposition with mitral stenosis or atresia and pulmonary stenosis. Two of our patients who presented a complete transposition of the great vessels, ventricular septal defect, and pulmonary stenosis associated with mirror-image dextrocardia and complete situs inversus and had a left aortic arch (mirror image of a right aortic arch with situs solitus) were not included in the series.

In the uncomplicated cases of mirror-image dextrocardia associated with situs inversus of the viscera, the aortic arch is right-sided, and the great vessels occupy a position symmetrically opposite of normal in the frontal plane. This was observed in our 8 cases. When mirror-image dextrocardia is associated with congenital cardiac lesions, a left aortic arch is present in only 1 of our 9 cases (12%), and in about 20 per cent of other series (Keith *et al.*, 1958; Arcilla and Gasul, 1961). In dextrocardia

with situs solitus of the viscera, the venous atrium is usually located on the right side, and the aortic arch is, as a rule, situated on the left, e.g. opposite the cardiac apex. In our series this occurred in 15 of 17 cases (88%). In a previous report by Arcilla and Gasul (1961) the aortic arch was on the right side in 20 per cent of the cases. According to Keith *et al.* (1958), in isolated dextrocardia a right-sided aortic arch occurs predominantly in those cases in which the right ventricle is posterior to the left ventricle, and the aorta placed anteriorly and to the left of the pulmonary artery. This was observed in our 2 patients. Of the 4 patients with a common atrium only one had a right aortic arch. In so-called dextroposition of the heart (heart shifted to the right of the chest, but apex pointing towards the left side), either isolated or associated with extracardiac factors, the aortic arch maintains its normal left-sided position.

In the present series of 30 patients with *lævo*-cardia and complete or partial inversion of the viscera, 40 per cent had a right aortic arch. In *lævocardia* with atrial inversion, the aortic arch is usually right-sided (Shaher and Johnson, 1963). In one series this occurred in 8 of 11 cases (Keith *et al.*, 1958). A left-sided aortic arch may be present, however, particularly in those cases associated with transposition of the great vessels, ventricular septal defect, and pulmonary stenosis. In the present group, 7 of the 30 patients with *lævocardia* had separate and inverted atria (23%); in 6 of these a right aortic arch was present. In isolated *lævocardia* without atrial inversion, the aortic arch may be on the right or left side: Keith *et al.* (1958) reported the occurrence of a right aortic arch in 16 of 28 cases of this type reviewed. In the present study, 17 patients with *lævocardia* had two separate atria with a right-sided venous atrium: 5 of these had a right aortic arch (30%). In *lævocardia* with a common atrium, the aortic arch may be right- or left-sided (Ivemark, 1955; Ruttenberg *et al.*, 1964). Six patients with *lævocardia* of this series had a common atrium: in one the aortic arch was right-sided.

As a general rule, in dextrocardia and *lævocardia* associated with situs solitus or inversus, the atria follow the position of the viscera (Van Praagh *et al.*, 1964), and the aortic arch is usually opposite the side of the venous atrium. In those cases in which the venous atrium does not follow the position of the viscera, or with a common atrium, splenic abnormalities and partial heterotaxy are very likely to be present, and the aortic arch may be either right- or left-sided.

In cases of mixed *lævocardia* with bulboventricular inversion and situs solitus (usual form of so-called corrected transposition), the presence of a

right aortic arch is rare (Lochte, 1898). Only one such instance was seen in our series.

It is of interest to note that anomalies involving abnormal persistence of the fourth right branchial arterial arch, other than right aortic arch itself, have a similar association with certain cardiac defects. Thus, Bahnson and Blalock (1950) found 19 instances of anomalous right subclavian artery and an equal number of anomalous left subclavian artery among 841 cyanotic patients on whom a palliative shunt operation was performed (4.3%). Pattinson and Emanuel (1957) found 4 cases with aberrant right subclavian artery in a series of 44 patients with tetralogy of Fallot (9%). This vascular anomaly occurs with a higher incidence in patients with tetralogy of Fallot than in the general population, where it is less than 2 per cent. Thus, Liechty *et al.* (1957) found an anomalous right subclavian artery present in 13 of over 1000 cadavers without cardiac lesions. Others have reported a similar or even lower incidence among routine anatomy dissections (Quain, 1844; Thomson, 1893; Harvey, 1917; Goldbloom, 1922; Cairney, 1925; DeGaris, 1923).

Although a double aortic arch is usually not associated with other cardiac anomalies, 3 of the 841 cyanotic patients of Blalock and Bahnson (1948) had a double aortic arch. We have seen 6 children with this vascular anomaly. Two had associated cardiovascular lesions—one a common atrio-ventricular orifice, the other a patent ductus arteriosus.

SUMMARY AND CONCLUSIONS

A series of 116 children and young adults with a right-sided aortic arch proven by angiography or necropsy is analysed. The findings are compared with reported data in subjects with and without congenital heart disease. Knowledge of the statistical distribution of a right-sided aortic arch among the various types of congenital heart disease is probably important for the understanding of the pathogenesis of some forms of congenital heart lesions.

Part II

Several variations of the aortic arch system are known to occur in association with a right aortic arch or right descending aorta. Some of these are of interest only to the embryologist or anatomist, while others have, in addition, clinical significance.

Anatomical classifications of the various forms of aortic arch and their branches were published by Krause (1868), Poynter (1916), Adachi (1928), Liechty *et al.* (1957), and Anson (1961), based on

large series of post-mortem specimens. Adachi (1928) classified these forms into types A to G, and this grouping was later expanded to 16 types by Williams and Edmonds (1935) and Nakagawa (1939a, b). According to the sequence of origin of their branches, the right aortic arches have been divided into two forms: the mirror-image type (type M of Adachi-Williams-Nakagawa) and the form with the left subclavian artery originating as the last branch (type N) (Fig. 1).

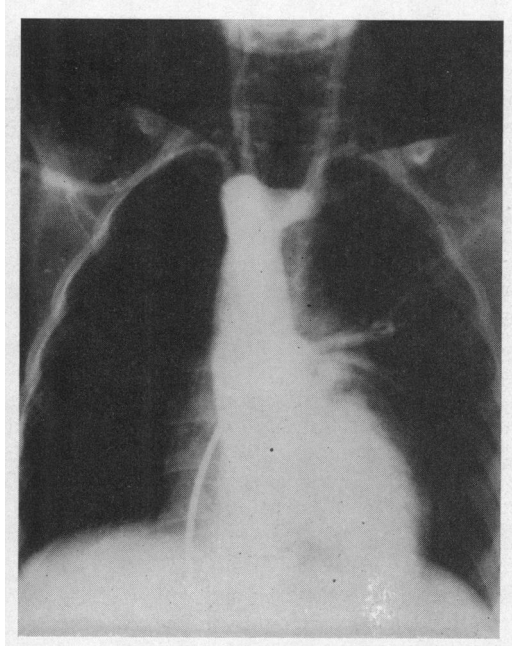


FIG. 1.—Selective angiogram of a child with a normal heart and a right aortic arch. The aortic arch is high and the left subclavian artery originates as the last brachiocephalic branch, from a conical diverticulum.

Congdon (1922) and Barry (1951) provided excellent embryological descriptions of the aortic arch system, and Edwards (1948b, 1953), and more recently Stewart *et al.* (1964), have presented a well-accepted classification for anomalies of the derivatives of the aortic arch system.

The present study deals with the anatomical variations found in a series of 116 children or young adults with a right aortic arch or right descending aorta and a review of the published reports. The aortic arch anomaly was demonstrated either by angiography, operation, or necropsy. The anatomical variations of right aortic arch are as follows.

- (1) Circumflex retro-oesophageal aortic arch:
 - (a) right aortic arch with left descending aorta;

and (b) left aortic arch with right descending aorta.

- (2) Cervical right aortic arch.
- (3) Right aortic arch with variations in the location of the ductus arteriosus and in the origin of the left subclavian artery.
- (4) Right aortic arch with isolation of the left subclavian from the aorta.
- (5) Right aortic arch with unilateral absence of a pulmonary artery.
- (6) Hemi-truncus with right aortic arch.

CIRCUMFLEX RETRO-OESOPHAGEAL AORTIC ARCH

The two anomalies in this group are mirror images of each other: (1) right aortic arch with left descending aorta and (2) left aortic arch with right descending aorta. In both situations the terminal portion of the aortic arch crosses the midline just anterior to the spine, before it turns abruptly downwards to continue as the descending aorta.

The large smooth round pulsating notch produced by the retro-oesophageal aorta on a barium swallow renders the clinical diagnosis of a circumflex aortic arch relatively easy. Sub-varieties of circumflex aortic arch are known, depending on whether the subclavian artery on the side opposite the aortic arch arises anteriorly from an innominate artery or posteriorly as the fourth branch of the aortic arch. Another variable is the ductus (or ligamentum) arteriosus which may be located on either right or left side. When the ductus (or ligamentum) arteriosus is on the side opposite the aortic arch, a vascular ring may be formed encircling the trachea and oesophagus. Right aortic arch with left descending aorta has been said to occur in 4 to 5 per cent of all patients with tetralogy of Fallot (Heim de Balsac, 1960), though Pattinson and Emanuel (1957) did not find a single such instance in a series of 60 patients with this cardiac malformation. In the present series, there were 3 such cases among 167 patients with tetralogy of Fallot in whom the location of the aortic arch and descending aorta had been ascertained by angiography or post-mortem examination (1.8%). Of the 116 patients with right aortic arch analysed in this study, 9 had a circumflex aortic arch with left descending thoracic aorta (Fig. 2). One of four people with a right aortic arch and normal heart had a left descending aorta.

To our knowledge, only 7 patients with left aortic arch with right descending aorta have been reported (Paul, 1948; Edwards, 1948a; Heinrich and Perez Tamayo, 1956; Heim de Balsac, 1960; Sterz, 1961; Schlamowitz, Di Giorgi, and Gensini, 1962). We have studied 3 additional ones (Table III). The aortic anomaly was diagnosed by angiography

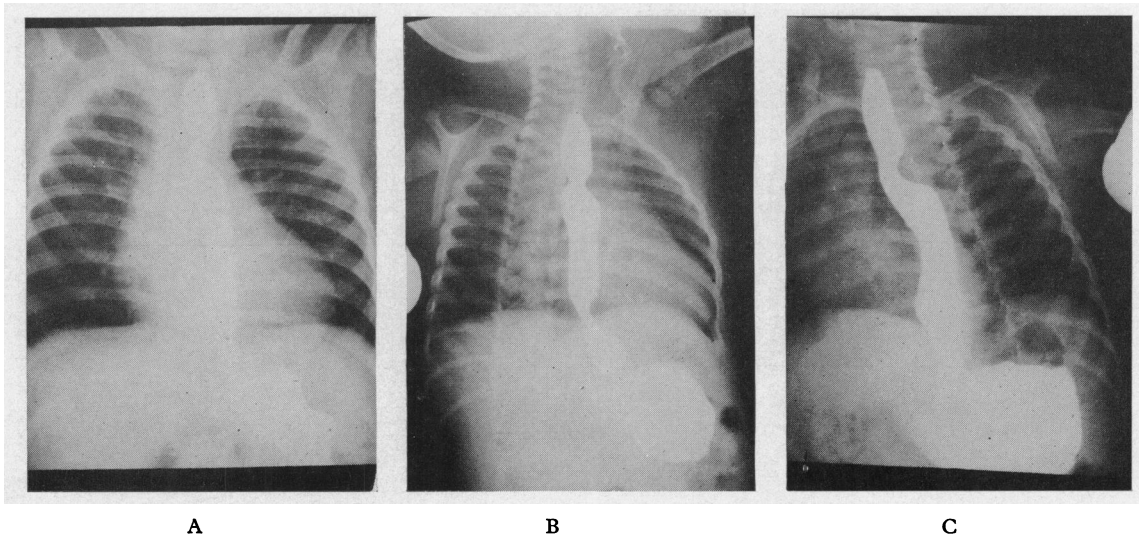


FIG. 2.—(A) Postero-anterior, (B) right anterior oblique, and (C) left anterior oblique projections of barium swallow of a patient with right circumflex aortic arch and left descending aorta, demonstrating the retro-oesophageal aortic impression.

in 2 of these (Fig. 3 and 4). One was a 6-month-old girl with aortic valvular stenosis, and the other an 8-year-old girl with a ventricular septal defect and infundibular pulmonary stenosis. The findings of our third patient are briefly described.

C.O. was an 11-month-old girl with a history of "gurgling in the throat" and chronic intermittent cough since 3 weeks of age. The cardiovascular examination, including electrocardiogram and radiographs, was normal. Barium swallow examination revealed an indentation of the oesophagus on its left and posterior

TABLE III
ANATOMICAL AND CLINICAL FINDINGS IN PATIENTS WITH LEFT AORTIC ARCH WITH RIGHT DESCENDING AORTA

Author	Age (yr.)	Sex	Diagnosed by	Associated congenital defects	Sequence of origin of branches arising from aorta	Pressure symptoms	Ligamentum arteriosus, right or left
Paul (1948)	7	F	X-rays with barium swallow; confirmed at operation	"Cyanotic heart disease"	Normal	Absent	Unknown
Paul (1948)	11	M	X-rays with barium swallow	Tetralogy of Fallot	Probably normal	Absent	Unknown
Edwards (1948a)	17 mth.	M	Necropsy	Imperforate anus; no cardiac defect	Rt. common carotid; Lt. common carotid; Lt. subclavian; Rt. subclavian	Dysphagia for solid food	Rt.-sided
Heim de Balsac (1960)	77	M	X-rays with barium swallow (calcified aorta)	None	Unknown	Absent	Unknown
Heinrich and Perez Tamayo (1956)	50	M	X-rays with barium swallow (calcified aorta)	None	Unknown	Absent	Unknown
Schlamowitz <i>et al.</i> (1962)	17	M	Selective angiography and aortography	Persistent left superior vena cava	Rt. common carotid; Rt. common carotid; Lt. subclavian; Rt. subclavian	Absent	Probably Rt.-sided
Sterz (1961)	69	M	X-rays with barium swallow (calcified aorta)	None	Unknown	Dysphagia for solid food	Unknown
Our Case 1	6 mth.	F	Selective angiography	Aortic stenosis	Normal	Absent	Unknown
Our Case 2	8	F	Selective angiography	VSD and infundibular pulmonary stenosis	Unknown	Absent	Unknown
Our Case 3	11 mth.	F	Surgery	Large thymus; no cardiac defect	Normal	Respiratory symptoms	Lt.-sided

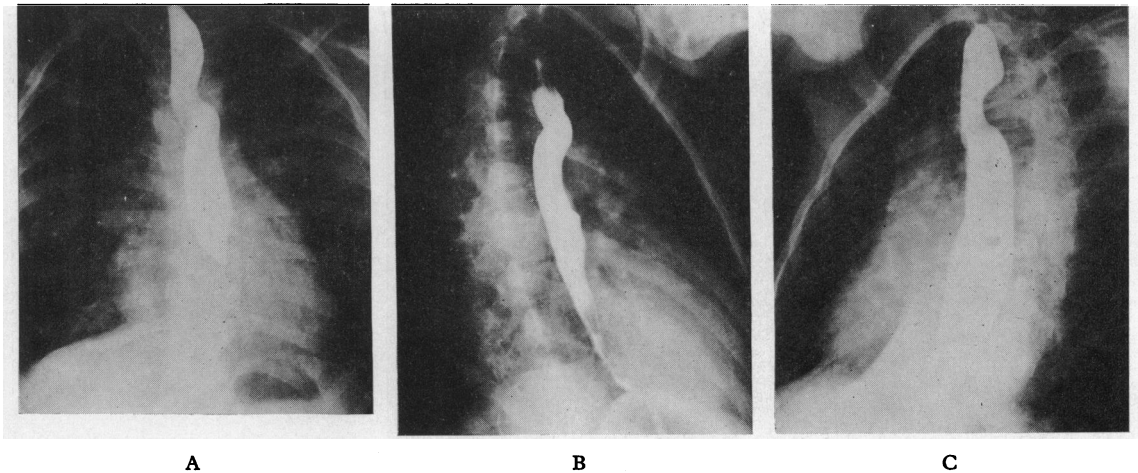


FIG. 3.—(A) Postero-anterior, (B) right anterior oblique, and (C) left anterior oblique projections, of barium swallow of a child with circumflex left aortic arch and right descending aorta (Case J. P.). The retro-oesophageal impression produced by the aorta is horizontal in the LAO projection but somewhat oblique in the RAO projection, indicating that the aorta changes its course while in its retro-oesophageal location.

aspects at the level of the aortic arch, and also a filling defect caused by a foreign body just above this level. The foreign body, a button, was removed by oesophagoscopy. At thoracotomy (sternal splitting incision) the aortic arch was dissected in its entirety. A very large thymus was found and removed. The aortic arch was left-sided but crossed behind the oesophagus horizontally

to descend on the right of the spine. The aorta gave off the right innominate, left common carotid, and left subclavian arteries, in that order. No atretic right aortic arch segment could be found, and the vascular ring was thus incomplete. A left ligamentum arteriosum was identified, which joined the left pulmonary artery to the contiguous aspect of the aortic arch.

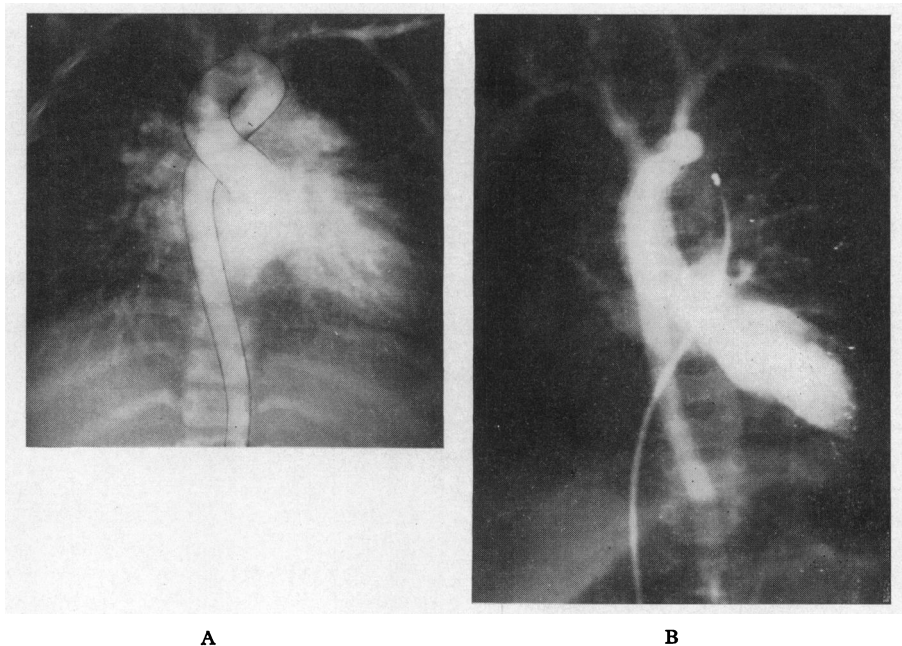


FIG. 4.—(A) and (B) angiocardigrams of two children with a circumflex left aortic arch and right descending aorta (Cases J. P. and B. L.).

TABLE IV
ANATOMICAL AND CLINICAL FINDINGS IN CERVICAL AORTIC ARCH

Author	Age (yr.)	Sex	Aortic arch	Descending aorta	Symptomatic vascular ring	Stenosis of left subclavian artery	Surgery
Beavan and Fatti (1947)	9	F	Right	Left	Present	Not mentioned	Misdiagnosed as aneurysm; ligated, died
Harley (1959)	5	M	Right	Left	Present	Probable stenosis (BP Rt. arm 112/86 mm. Hg) (BP Lt. arm 92/84 mm. Hg)	Vascular ring divided surgically; symptoms relieved
Gravier <i>et al.</i> (1959)	4	M	Right	Left	Absent	Not mentioned	No surgery
Massumi <i>et al.</i> (1963)	7	M	Right	Left	Present	Atresia	Vascular ring divided surgically; symptoms relieved
Our Case 1	6	M	Right	Left	Absent	Probable stenosis	No surgery
Our Case 2	10	F	Right	Left	Absent, headaches	Atresia	No surgery (very high location of arch, subcranial)

This particular combination of lesions (left aortic arch, left ductus arteriosus, and right descending aorta) has, to our knowledge, never been described before. In fact, Edwards (1960) stated that "though such malformations are hypothetical possibilities it is unlikely that they would occur".

Of the 10 reported patients with a left-sided aortic arch and right-sided descending aorta, 5 had coexisting cardiac malformations. In only one was a true vascular ring proved to exist (Edwards, 1948a). Another patient, however, experienced mild dysphagia (Sterz, 1961). The abnormal findings of the barium swallow examination (Fig. 3) in this anomaly were well described by Paul (1948).

CERVICAL RIGHT AORTIC ARCH

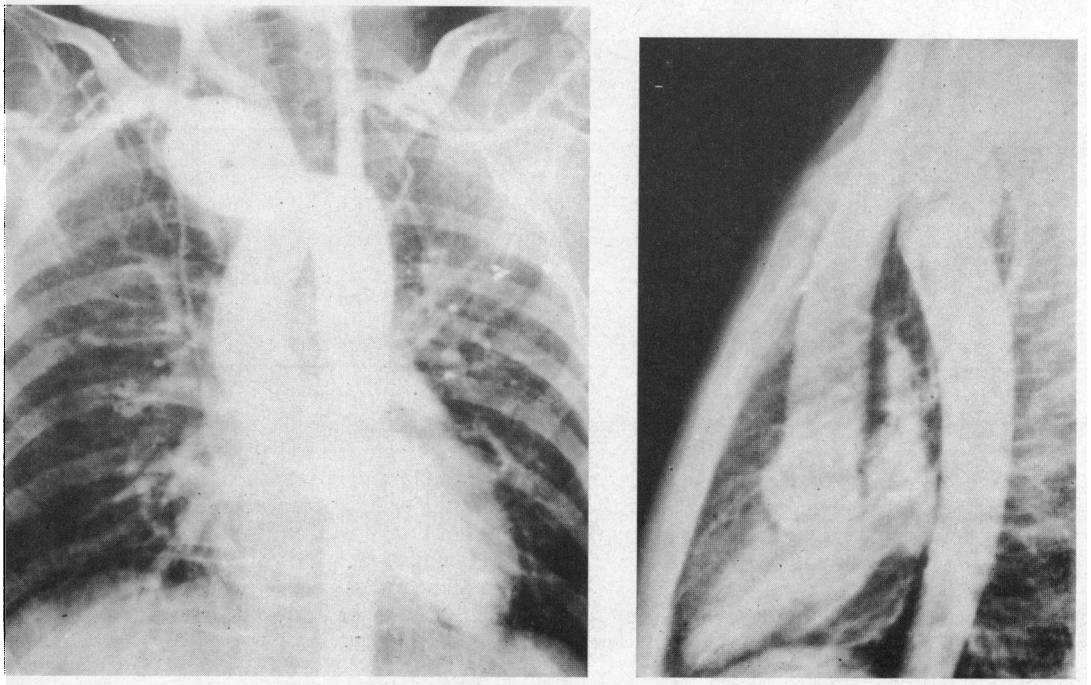
A true cervical aortic arch is very rare. The 4 previously reported patients (Beavan and Fatti, 1947; Harley, 1959; Gravier, Vialtel, and Pinet, 1959; Massumi, Weiner, and Charif, 1963) and one of ours were strikingly similar (Table IV; Case 1) and were associated with certain unusual anatomical and clinical features (Fig. 5). In all 5 patients the aortic arch was right-sided and elongated, presenting as a pulsatile swelling on the right side of the neck. The aortic arch had a typical appearance, and its terminal portion crossed the midline behind the oesophagus to descend on the left of the thoracic spine. The first branch given off by the aorta was the left common carotid artery; it originated from the ascending aorta in all cases. The right subclavian and either both right external and internal carotid arteries (our case; Beavan and Fatti, 1947), or a right common carotid artery (Harley, 1959), arose separately from the apex of the arch, except in one case in which a right brachiocephalic trunk was present (Gravier *et al.*, 1959). The common carotid artery was atretic in another case (Massumi *et al.*, 1963). The left subclavian artery originated always as the last branch of the aortic arch, with its origin

at the junction of the retro-oesophageal and descending segments of the aorta, where a conical diverticulum usually existed, which also gave rise to a ductus or ligamentum arteriosus. The left subclavian artery was atretic at its origin in one case (Massumi *et al.*, 1963), and was probably stenotic in ours since aortography revealed later visualization and lesser opacification than the other brachiocephalic vessels.

Patient 2 of the present series, a 10-year-old Negro girl, had a high variety of cervical aortic arch with its apex situated above the angle of the mandible just below the level of the mastoid. The girl complained of frontal headaches, and presented with a large pulsating right cervical mass with a thrill and a continuous bruit. Cardiac catheterization was consistent with a normal heart. Selective angiograms from the root of the aorta are shown in Fig. 6. The first brachiocephalic branch is a large left carotid artery; it originates from the ascending aorta. The right internal and external carotid arteries originate independently from the apex of the arch. The initial descending portion of the aorta is directed towards the right, and gives origin to the right subclavian artery. It then turns leftwards and becomes retro-oesophageal, and finally descends on the left side of the spine. There appears to be complete atresia of the left subclavian artery at its origin, this vessel being supplied by the vertebral and other collateral arteries.

No instance of a left cervical aorta has yet been described.

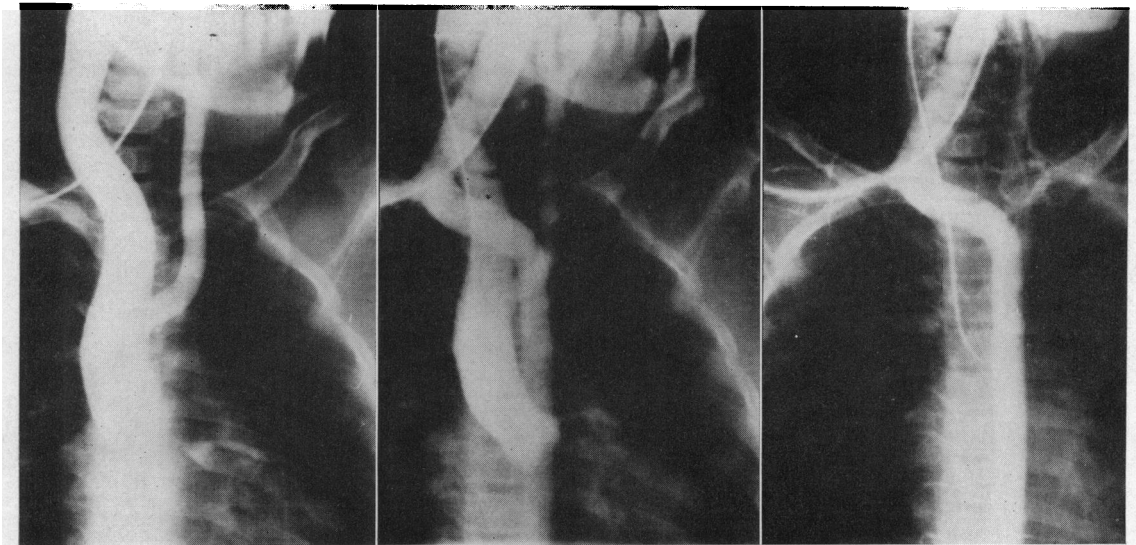
Of the 6 reported patients with a cervical right aortic arch, 3 had symptoms of tracheo-oesophageal compression (Beavan and Fatti, 1947; Harley, 1959; Massumi *et al.*, 1963). This was caused by a vascular ring consisting of the right circumflex aortic arch, the left ligamentum arteriosum, and the pulmonary artery. Division of the ligamentum arteriosum in two of these cases relieved the symptoms of constriction. A clinical diagnosis of this rare anomaly would be suggested by a combination of: (1) symptoms of tracheal and oesophageal obstruction; (2) a pulsatile right cervical swelling; (3) a retro-



A

B

FIG. 5.—(A) Antero-posterior and (B) lateral projections of an angiogram of a child with a cervical aortic arch (Case D. M.). The aortic arch is right-sided, abnormally elongated, and takes a horizontal retro-esophageal course across the midline before it descends to the left of the spine.



B

B

C

FIG. 6.—Selective angiograms of a patient with a very high cervical (subcranial) aortic arch. (A) shows the ascending aorta and the origin of a large left carotid artery as its first branch. (B) shows the very high aortic arch. The right internal and external carotid arteries originate independently from the apex. The right subclavian artery originates from the initial descending portion of the aorta. (C) shows a later phase of the angiogram. The left subclavian artery is isolated from the aorta. There appears to be complete atresia of its origin and it is supplied by collateral arteries.

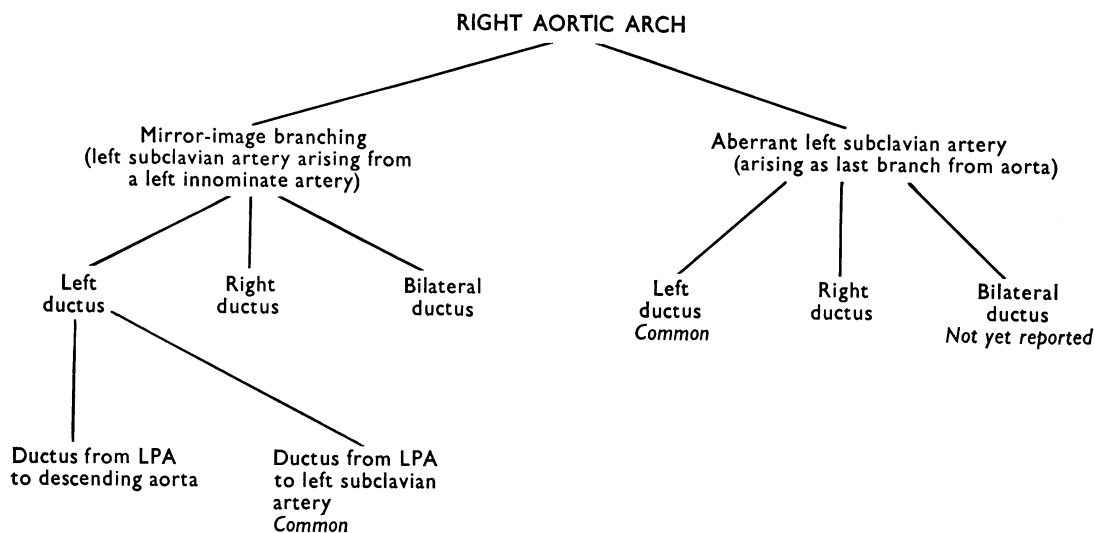


FIG. 7.—Anatomical variations involving the ductus arteriosus and left subclavian artery, occurring in association with right aortic arch.

oesophageal aortic impression on a barium swallow examination; (4) disappearance or diminution of the femoral pulses when the cervical swelling is compressed.

RIGHT AORTIC ARCH WITH VARIATIONS IN CONNECTION OF LEFT SUBCLAVIAN ARTERY AND OF THE DUCTUS ARTERIOSUS TO THE AORTA

Bedford and Parkinson (1936) distinguished two types of right aortic arch: (1) with "mirror-image branching", in which a left innominate artery arises as the first branch off the aortic arch, and then divides into a left common carotid and left subclavian artery (type M of Adachi-Williams-Nakagawa); (2) with aberrant left subclavian artery, which arises as a fourth branch off the aortic arch (type N of Adachi-Williams-Nakagawa). The aorta is often dilated into a conical diverticulum at the point of origin of the left subclavian artery (Fig. 1), producing a retro-oesophageal impression very similar to that made by a retro-oesophageal circumflex aortic arch.

Since the ductus arteriosus can be right-sided, left-sided, or bilateral, further sub-categories exist (Fig. 7). Some of these sub-varieties are extremely rare, but two of them are commonly encountered:

(a) Right aortic arch with mirror-image branching and left ductus arteriosus (or ligamentum arteriosus) connecting the left innominate artery or the root of the left subclavian artery to the left pulmonary artery. This type does not form a vascular ring and causes no symptoms. Nearly always a cyanotic cardiac anomaly coexists.

(b) Right aortic arch with an aberrant left subclavian artery arising as a fourth branch from the aortic arch. More often than not, the heart is normal.

Almost all Felson and Palayew's 26 patients (1963) with right aortic arch and "mirror-image" type of branching had cyanotic heart disease, while almost all their 33 patients with the other type of right aortic arch had normal hearts, except 3 who had a patent ductus arteriosus, and one other unusual case. The latter patient had a right innominate artery arising as the first branch off the aorta and also a coarctation of the aorta proximal to the origin of the left subclavian artery. One of our patients with right aortic arch unassociated with heart disease underwent investigation for a suspected superior mediastinal tumour before the correct diagnosis of right aortic arch was made. This error has been reported several times before, and such people have even been subjected to unnecessary thoracotomy.

A left ductus arteriosus (or ligamentum arteriosus) usually joins the root of the aberrant left subclavian artery to the left pulmonary artery and, thus, completes a vascular ring. Fontana and Edwards (1962) collected 26 such cases from the published material, and noted that in only 6 were there symptoms of tracheo-oesophageal compression. Gross and Neuhauser (1951), however, reported 7 children with this type of vascular ring who needed surgical relief. They commented on the fact that symptoms caused by this variety of vascular ring usually appear later in life and are less severe than those associated with double aortic arch. Felson and Palayew (1963) had

5 patients with symptoms of tracheo-oesophageal compression, 3 of whom underwent surgical correction.

An aberrant left subclavian artery is a frequent accompaniment of a right aortic arch, especially when such a person has a normal heart. Although, as a rule, such an aberrant left retro-oesophageal subclavian artery causes no symptoms, Gross and Neuhauser (1951) have reported "hesitancy in swallowing" in one child. When both an aberrant left subclavian artery and a "posterior" left ductus arteriosus coexist in a patient with right aortic arch, the left subclavian artery may sometimes be a more important cause of oesophageal compression than the left ductus, as in a child reported by Felson and Palayew (1963).

Blake and Manion (1962) mention one instance of a right aortic arch associated with a left innominate artery that crossed the midline posterior to the trachea and oesophagus.

The various impressions produced on the tracheal air shadow and on the barium-filled oesophagus by the right aortic arch, left ductus arteriosus, and aberrant left subclavian artery, can be detected in plain x-ray studies of the chest. These radiological manifestations have been recently reviewed in detail (Felson and Palayew, 1963; Stewart *et al.*, 1964).

RIGHT AORTIC ARCH WITH LEFT SUBCLAVIAN ARTERY ISOLATED FROM AORTA AND ARISING FROM THE PULMONARY ARTERY

Very few such cases have been described (Table V) (Holst, 1837; Barger, Bregman, and Edwards, 1956; Brown and Morris, 1951; Stewart *et al.*, 1964), though the earliest report was more than a century ago. An associated cardiac anomaly has usually also been present, except in one patient (Barger

et al., 1956). The left subclavian artery, which has no anatomical connexion with the aorta, is connected to the root of the left pulmonary artery via a left ductus arteriosus. Since the ductus, in all reported cases, has undergone obliteration, blood flow to the left subclavian artery takes place through collateral vessels (Fig. 8). Retrograde flow in the ipsilateral vertebral artery has been demonstrated. The left radial pulse is weak or absent. This so-called "subclavian steal" phenomenon, generally considered to be a very recent concept (Contorni, 1960; Reivich *et al.*, 1961; Massumi, 1963), was commented upon as long ago as 1837 by Holst.

There were 3 instances of a right aortic arch with isolation of the left subclavian artery in the present series. Case 1 was that of a 4-year-old girl with a ventricular septal defect, a moderate left-to-right shunt, and normal pulmonary artery pressures. Aortography showed delayed opacification of the distal left subclavian artery through collaterals. A catheter passed retrogradely into this artery could not progress beyond its proximal portion: this suggested that the arterial lumen at this site was obliterated. Simultaneous pressures recorded in the left brachial artery and the descending aorta (Fig. 9) revealed a significant gradient in pressure between these two vessels. In Case 2, the anomalous origin of the left subclavian artery from the pulmonary artery was demonstrated at necropsy. The associated lesions were double outlet right ventricle with pulmonary stenosis, mitral atresia, a persistent left superior vena cava entering the coronary sinus, and a bicuspid pulmonary valve. Case 3, a male infant with pulmonary stenosis, intact ventricular septum, and right aortic arch, was unique in that the left common carotid as well as the left subclavian artery had no connexion whatever with the aorta. Both these vessels arose from a left

TABLE V
ANATOMICAL AND CLINICAL FINDINGS IN ISOLATION OF LEFT SUBCLAVIAN ARTERY FROM THE AORTA

Author	Aortic arch	Abnormal subclavian artery	Ductus arteriosus	Associated anomaly
Edwards (1948b) No. 1	Left	Right	Bilateral	VSD, ASD, coarctation of aorta
Stewart <i>et al.</i> (1964) No. 2	Right	Left	Left	Tetralogy of Fallot
Barger <i>et al.</i> (1956)	Right	Left	Bilateral	No heart defect
Holst (1837)	Side not stated; probably right	Left	Left; possibly bilateral	ASD; double outlet right ventricle
Brown and Morris (1951) No. 1	Right	Left	Left; possibly bilateral	Tetralogy of Fallot
No. 2	Right	Left	Left	VSD
Our Case 1	Right	Left	Left	Double outlet right ventricle with pulmonary stenosis, mitral atresia, persistent left superior vena cava
Our Case 2	Right	Left	Left	Pulmonary stenosis with intact ventricular septum
Our Case 3	Right	Left	Left	VSD
Our Case 4	Left	Right	Bilateral; right patent	

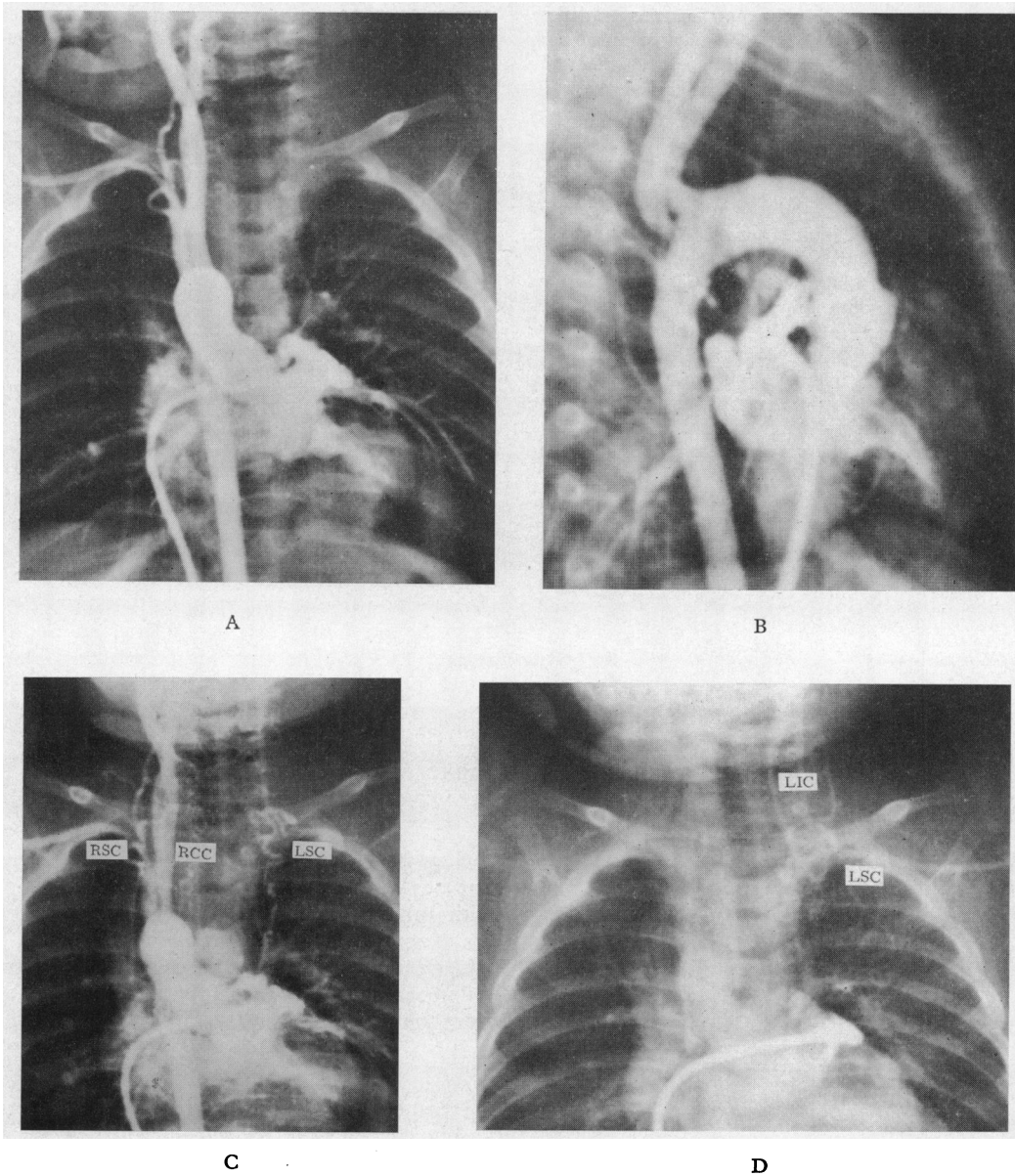


FIG. 8.—Selective angiogram in a patient with isolated pulmonary valvular stenosis associated with right aortic arch and isolation of both the left subclavian and left carotid arteries from the aorta (Case M. M.). (A) and (B) show early aortic opacification with non-visualization of the left common carotid and left subclavian arteries. (C) is a later frame demonstrating the collateral circulation carrying blood to the left common carotid and left subclavian arteries which are opacified in (D), a yet later frame, when dye has almost disappeared from corresponding arteries on the right side. RCC—right common carotid artery; RSC—right subclavian artery; LIC—left internal carotid artery; LSC—left subclavian artery.

ductus arteriosus and were shown by angiography to opacify, through collaterals, much later than the right subclavian and right common carotid arteries (Fig. 8). The diagnosis was confirmed at necropsy.

Only one report exists of a “mirror-image” equivalent anomaly, e.g. a left aortic arch with isolation of the right subclavian artery from the aorta (Stewart *et al.*, 1964). An additional case was encountered in our series.

A 7-year-old Negro boy had a ventricular septal defect, a moderate left-to-right shunt, and normal pulmonary artery pressures. In addition to the harsh pansystolic murmur at the left lower sternal border and the mid-diastolic rumble at the apex, there was also a higher-pitched continuous murmur at the upper right sternal border. The child had a left aortic arch. When extracorporeal circulation was instituted, with the heart opened and fibrillating, a large amount of oxygenated blood could be seen flowing retrogradely through the pulmonary valve. There was a continuous thrill in the pulmonary artery. There was a ligamentum arteriosus on the left, and, in addition, a patent ductus arteriosus on the right connecting to the right subclavian artery. The subclavian artery had no connexions with the aorta. The blood flow was retrograde from the subclavian through the ductus into the pulmonary artery. The right patent ductus arteriosus was ligated and divided. The right carotid artery was the first branch of the aortic arch.

Isolation of one or both subclavian arteries from the proximal aorta in patients with interruption of the aortic arch has also been described. There are 3 such cases in our series, proven at necropsy.

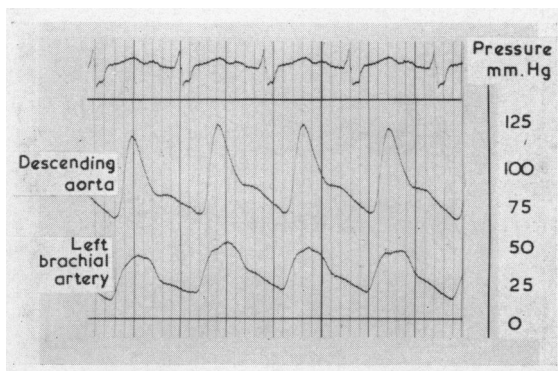


FIG. 9.—Simultaneous pressure curves obtained from the left brachial artery and descending aorta in a patient with ventricular septal defect associated with right aortic arch and isolation of the left subclavian artery from the aorta (Case S. C.).

RIGHT AORTIC ARCH WITH UNILATERAL ABSENCE OF A PULMONARY ARTERY

Pool, Vogel, and Blount (1962) recently reviewed all cases of unilateral absence of a pulmonary artery (excluding those associated with a persistent truncus arteriosus or agenesis of a lung). These authors found that of 18 anatomically proven cases of absent left pulmonary artery, at least 10 had a right-sided aortic arch. Tetralogy of Fallot was an accompanying lesion in 6 of these 10 patients. Neither right aortic arch nor tetralogy of Fallot was mentioned as an associated finding in any of 22 patients with

proven absence of the right pulmonary artery. McKim and Wigglesworth (1954) had earlier noted the high incidence of location of the aortic arch on the side opposite the absent pulmonary artery: all 3 patients had a right aortic arch and absent left pulmonary artery. Emanuel and Pattinson (1956) reviewed 20 published cases of tetralogy with absent left pulmonary artery (including those with angiocardigraphic diagnosis only). They noted that 12 of these had a right aortic arch (60%), which constitutes a higher incidence than is usually found in uncomplicated tetralogy of Fallot.

Excluding cases of persistent truncus arteriosus and agenesis of one lung, we have studied 8 patients with unilateral absence of a pulmonary artery: tetralogy of Fallot was an associated lesion in 4. Angiocardigraphy in 3 of them, all of whom are still living, demonstrated a right aortic arch and absent left pulmonary artery. In the other patient with tetralogy of Fallot, necropsy revealed a left aortic arch and absent right pulmonary artery, thus proving an exception to the rule that absence of the right pulmonary artery eliminates tetralogy of Fallot from the differential diagnosis of a given case (Pool *et al.*, 1962). The only other reported case of tetralogy of Fallot with absent right pulmonary artery was associated with total situs inversus.

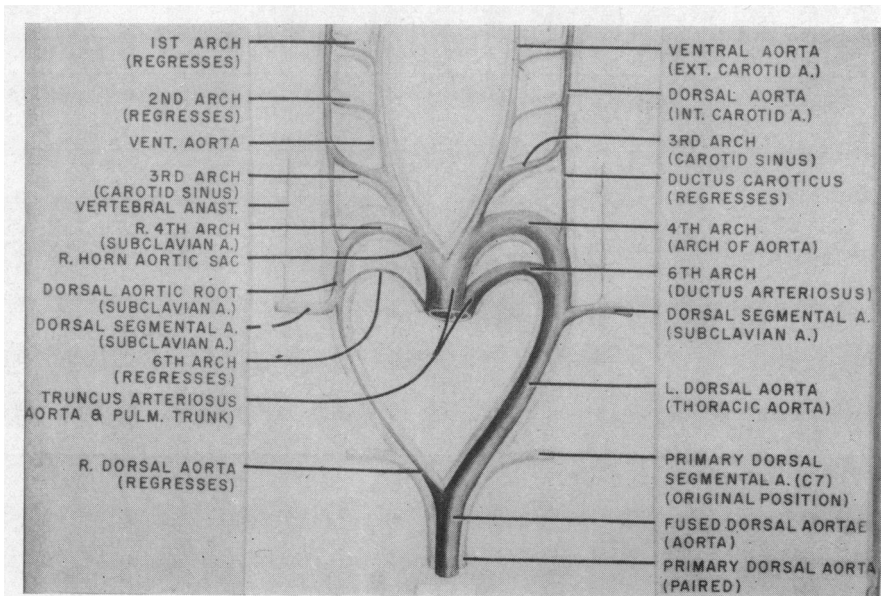
RIGHT AORTIC ARCH WITH ORIGIN OF THE LEFT PULMONARY ARTERY FROM THE AORTA (HEMI-TRUNCUS)

Stewart *et al.* (1964) described the necropsy findings in one such patient. This was an infant with multiple congenital defects who died three hours after birth. The aortic arch was right-sided. The right pulmonary artery arose normally from the pulmonary trunk but the left pulmonary artery arose from the ascending aorta.

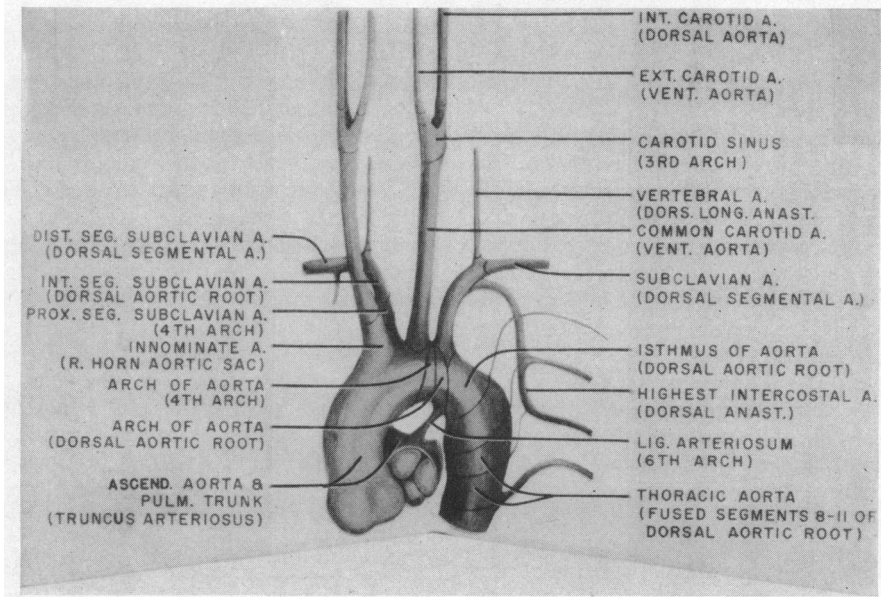
EMBRYOLOGY

Prenatally, formation of the arch of the aorta and its branches is principally determined by the progressive caudal descent of the heart and partitioning of the truncus arteriosus. The extent to which the intracardiac streams of flow play a part in establishment of the normal aortic arch system is yet to be ascertained.

During the early phase of cardiogenesis, arterial arches are elaborated within the branchial arches of the embryo as undeclared delicate endothelial channels. While six pairs of aortic arches comprise the theoretical primitive plan, all do not exist simultaneously and the first two pairs are short lived (Fig. 10, Table VI). The fifth arch must be regarded as transient and apparently non-contributory



A



B

FIG. 10.—(A) Silhouette of primary arch system in background (light). Rudiments of derived definitive vessel shown in relief over background diagram and indicated in parenthesis. (B) Postnatal plan of aortic arch and major divisions. The derivation of the different segments of the aorta is indicated. Embryonic rudiment in parenthesis. (Both reproductions by courtesy of R. Licata in *Blood Vessels and Lymphatics*. Edited by D. I. Abranson, Academic Press, New York and London, 1962).

TABLE VI
ANATOMICAL AND CLINICAL FINDINGS IN CHRONOLOGY OF DEVELOPMENT OF AORTIC ARCHES
(adapted largely after Congdon, 1922)

Vascular structure	Age of embryo	Length of embryo (crown to rump) (mm.)	
Arch I	3 weeks	1.5-3.5	Transient; drops out at end of 3rd week when 3rd arch appears
Arch II	3-4 weeks	3-4	
Arch III	Appears 3-1/2 to 4 weeks	4.5 to term	
Arch IV	Appears 4th week	5 to term	Transient Takes configuration of carotid sinus complex at 11 mm.; maximal endothelial development at 10 mm.
Arch V	5th week	4-7	Definitive aortic arch completed at 18-20 mm. (6-8 weeks) (maximal endothelial development at 10 mm.) subclavian artery first established at 6 mm.
Arch VI	Appears 5 weeks	4-5, established by 6-11	Transient Mediastinal plexus and proximal segment of arch VI meet at 11 mm.; pulmonary artery established at 6-11 mm.; interruption of distal right arch VI at 12 mm. (45 days)
Ductus caroticus (rt. dorsal aorta between arches III and IV)			Together with distal part of right arch VI, it begins to drop out at 8-10 mm. and disappears at 14-16 mm.
Right dorsal aorta (arteria aberrans); dorsal aortae descent of heart			Begins to drop out at 12 mm.; fuse at 22 sonite stage (3 weeks); period of rapid descent completed at 18 mm. (50 days)

to the definitive arterial arches system. Persistence of certain segments of the primitive arterial arches is determined by a combination of factors. Abandonment of certain segments of the arch system is probably determined only partly by hæmodynamic alterations. In addition, the absence of local conditions normally promoting persistence and growth of these segments must also be regarded as important. Furthermore, an interdependence of the various segments represents an additional factor; for example, atrophy of the right dorsal aorta is apparently normally related to loss of the distal segment of the right sixth arch.

Once the definitive arterial arch system is declared hæmodynamically, histological differentiation ensues, during which certain segments develop specialized functions. Thus, it seems very probable that extravascular environmental factors at the level of the carotid sinuses, pressor-receptor aortic arch region, and the ductus arteriosus, influence the functional and perhaps also the histological differentiation of these regions.

Embryologically, the anterior part of a right aortic arch is developed principally from the ventral aortic root (right horn of the aortic sac) between the fourth and sixth arches. The region developed from the primitive truncus arteriosus lies below (proximal to) this level. Therefore, right aortic arch is not directly involved in the partitioning process of the truncus, though the streams of flow resulting from faulty partitioning of the truncus may secondarily contribute to the formation of the aortic arch on the right side.

The septation of the truncus arteriosus and subsequent closure of the ventricular septum is completed late in the second and early in the third month of intrauterine life. The fourth arches are

established at the end of the fourth week as endothelial channels. Normally the left fourth arch is definitively declared as the persistent arch by the sixth week. At this stage, partitioning of the truncus and formation of the ventricular septum is far from completion. It is open to question, therefore, whether the direction in which blood is ejected into the primitive aorta principally determines whether the right or the left fourth arch will persist. The association between the altered ventricular anatomy of Fallot's tetralogy and a high incidence of right aortic arch may not be one of cause and effect. Abnormal "controlling" tissue elements may be more important than hæmodynamic factors in causing persistence of the right arch.

Distally, the right aortic arch is derived from the right dorsal aorta involving compressed somatic segments 3-10 and a small intermediate segment representing the fourth right arch proper. The aortic arch anterior to the right subclavian artery is derived from segments 3-7, and posterior to it from segments 8-10 of the dorsal aorta.

From a phylogenetic point of view, it is worth noting that a right aortic arch is normal in birds. Perhaps a transitory phase occurs in the development of the human aortic arch system during which the right ventral aortic root (right horn of the aortic sac) is favoured over its mate on the left to persist as the definitive aortic arch.

All reported instances of cervical aortic arch have been located on the right side. This anomaly has been attributed to persistence of the third right arterial arch and of the ductus caroticus, with involution of the fourth right arch, so that the right internal and external carotid arteries take separate origin from the aortic arch (Beavan and Fatti, 1947). Another possibility is that the fourth right arch par-

takes in the formation of the arch of the aorta, but for some unaccountable reason it fails to migrate into the thorax. One would have to postulate, in addition, that the right ductus caroticus persists, to explain why the right internal and external carotid arteries arise separately from the aorta (Harley, 1959). A third possible theory is that the right third and fourth arterial arches become confluent at a phase when the primitive arches are cervically located, perhaps due to anomalous growth of the pharyngeal pouch tissue in that area. The mode of the origin of the left subclavian artery from a right aortic arch apparently depends on which part of the left fourth arch and related dorsal aorta persists, and which part disappears. If the segment of the latter immediately dorsal to the left subclavian artery atrophies, this vessel arises anteriorly from a left innominate artery. If the fourth left arch immediately anterior to the left subclavian artery disappears, it will take origin posteriorly as fourth and last branch of the aortic arch. If the elements of the left fourth arch and dorsal aorta both ventral and dorsal to the subclavian artery should atrophy, with the exception of that part entering into the formation of the left ductus arteriosus, the left subclavian artery will have no anatomical connexion whatever with the aorta, but will apparently arise directly from the pulmonary artery. The fact that such an anomalous left subclavian artery undergoes obliteration at its root is explained by the presence of ductal tissue (left ductus arteriosus) in this segment.

The many theories postulated to explain unilateral absence of a pulmonary artery have been recently reviewed (Cucci, Doyle, and Lewis, 1964). These invoke persistence of the fifth arch and atrophy of the sixth (Ambrus, 1936), reabsorption of the proximal portion of the sixth arch (McKim and Wiglesworth, 1954), failure of the right sixth arch to migrate dorsally and to the left around the primitive truncus arteriosus (Schneiderman, 1958), and defective septation of the truncus (Cucci *et al.*, 1964). According to the latter authors, the frequency of observed combination of tetralogy of Fallot, right aortic arch, and "absent" left pulmonary artery results from a simple primordial error: a dorso-rotation of the left truncal ridge extending throughout the truncoconus.

SUMMARY AND CONCLUSIONS

The anatomical variations found in a series of 116 children and young adults with a right-sided aortic arch or right descending aorta are presented. The associated congenital cardiac anomalies are analysed, and the various hypotheses concerning the embryology of the right aortic arch and its variations are

reviewed. It is felt that the findings presented are of importance for the understanding of the embryology of the normal and abnormal human aortic arch.

We are indebted to Dr. Milton H. Paul, Director, Department of Cardiology, Children's Memorial Hospital, and to Dr. Harvey White, Director, Department of Radiology, Children's Memorial Hospital, for providing us with data on two patients.

REFERENCES

- Abbott, M. (1936). *Atlas of Congenital Cardiac Disease*. American Heart Association, New York.
- Adachi, B. (1928). *Das Arteriensystem der Japaner*, vol. 1, pp. 22-41. (Verlag der Kaiserliche—Japanische Universität zu Kyoto.) (Cited by Kasai, 1962.)
- Ambrus, G. (1936). Congenital absence of the right pulmonary artery with bleeding into the right lung. *J. techn. Meth.*, **15**, 103.
- Anson, B. J. (1961). The aortic arch and its branches. In *Development and Structure of the Cardiovascular System*, ed. A. A. Luisada, p. 119. McGraw-Hill, New York, Toronto, London.
- Arcilla, R. A., and Gasul, B. M. (1961). Congenital dextrocardia. Clinical, angiocardiographic and autopsy studies on 50 patients. *J. Pediat.*, **58**, 39.
- Bahnsen, H. T., and Blalock, A. (1950). Aortic vascular rings encountered in the surgical treatment of congenital pulmonic stenosis. *Ann. Surg.*, **131**, 356.
- Baker, C., Brock, R. C., Campbell, M., and Suzman, S. (1949). Morbus cæruleus: A study of 50 cases after the Blalock-Taussig operation. *Brit. Heart J.*, **11**, 170.
- Barger, J. D., Bregman, E. H., and Edwards, J. E. (1956). Bilateral ductus arteriosus with right aortic arch and right-sided descending aorta. *Amer. J. Roentgenol.*, **76**, 758.
- Barry, A. (1951). The aortic arch derivatives in the human adult. *Anat. Rec.*, **111**, 221.
- Beavan, T. E. D., and Fatti, L. (1947). Ligature of aortic arch in the neck. *Brit. J. Surg.*, **34**, 414.
- Bedford, D. E., and Parkinson, J. (1936). Right-sided aortic arch. *Brit. J. Radiol.*, **9**, 776.
- Biedermann, F. (1931). Der rechtsseitige Aortenbogen im Röntgenbild. *Fortschr. Röntgenstrahl.*, **43**, 168.
- Blake, H. A., and Manion, W. C. (1962). Thoracic arterial arch anomalies. *Circulation*, **26**, 251.
- Blalock, A., and Bahnsen, H. T. (1948). Operations performed and vascular anomalies encountered in the treatment of congenital pulmonic stenosis. *Ann. roy. Coll. Surg. Engl.*, **3**, 57.
- Bressie, J. L. (1964). Pulmonary valvular stenosis with intact ventricular septum and right aortic arch. *Brit. Heart J.*, **26**, 154.
- Brinton, W. D., and Campbell, M. (1953). Necropsies in some congenital diseases of the heart, mainly Fallot's tetralogy. *Brit. Heart J.*, **15**, 335.
- Brotmacher, L., and Campbell, M. (1958). The natural history of ventricular septal defect. *Brit. Heart J.*, **20**, 97.
- Brown, C. J. O., and Morris, K. N. (1951). Results of surgery in congenital deformities of the heart. *Aust. N.Z. J. Surg.*, **21**, 1.
- Cairney, J. (1925). The anomalous right subclavian artery considered in the light of recent findings in arterial development; with a note on 2 cases of an unusual relation of the innominate artery to the trachea. *J. Anat. (Lond.)*, **59**, 265.

- Campbell, M. (1954). Simple pulmonary stenosis: pulmonary valvular stenosis with a closed ventricular septum. *Brit. Heart J.*, **16**, 273.
- Collett, R. W., and Edwards, J. E. (1949). Persistent truncus arteriosus: a classification according to anatomic types. *Surg. Clin. N. Amer.*, **29**, 1245.
- Congdon, E. D. (1922). Transformation of the aortic arch system during the development of the human embryo. *Contr. Embryol. Carneg. Instn*, **14**, 47.
- Contorni, L. (1960). Il cricolo collaterale vertebro-vertebrale vella obliterazione dell'arteria subclavia alla sua origine. *Minerva chir.*, **15**, 268.
- Corvisart, J. N. (1818). *Essais sur les Maladies et les Lésions Organiques du Cœur et des Gros Vaisseaux*, 3rd ed., p. 206. Méquignon-Marvis, Paris.
- Cucci, C. E., Doyle, E. F., and Lewis, E. W., Jr. (1964). Absence of a primary division of the pulmonary trunk: An ontogenic theory. *Circulation*, **29**, 124.
- Dammann, J. F., Jr., Gibson, S., and Potts, W. J. (1949). Observations on 117 patients operated on for congenital pulmonary stenosis. *Pediatrics*, **3**, 575.
- DeGaris, C. F. (1923). Modes of origin of the subclavian artery in whites and negroes, with report of a case of anomalous right subclavian artery. *Anat. Rec.*, **26**, 235.
- Edwards, J. E. (1948a). Retro-esophageal segment of the left aortic arch, right ligamentum arteriosum and right descending aorta causing a congenital vascular ring about the trachea and esophagus. *Proc. Mayo Clin.*, **23**, 108.
- (1948b). Anomalies of the derivatives of the aortic arch system. *Med. Clin. N. Amer.*, **32**, 925.
- (1953). Malformations of the aortic arch system manifested as "vascular rings". *Lab. Invest.*, **2**, 56.
- (1960). Congenital malformations of the heart and great vessels. In *Pathology of the Heart*, 2nd edn., ed. S. E. Gould. Charles C. Thomas, Springfield, Illinois.
- Eisen, D. (1944). Right aortic arch with report of eight cases. *Radiology*, **42**, 570.
- Elliott, L. P., Neufeld, H. N., Anderson, R. C., Adams, P., Jr., and Edwards, J. E. (1963). Complete transposition of the great vessels. I. An anatomic study of sixty cases. *Circulation*, **27**, 1105.
- Emanuel, R. W., and Pattinson, J. N. (1956). Absence of the left pulmonary artery in Fallot's tetralogy. *Brit. Heart J.*, **18**, 289.
- Espino-Vela, J., and Mata, L. A. (1956). Eisenmenger's complex. A clinical and pathologic study of four cases. *Amer. Heart J.*, **51**, 284.
- Felson, B., and Palayew, M. J. (1963). The two types of right aortic arch. *Radiology*, **81**, 745.
- Fioratti, and Aglietti, F. (1763). Quoted by Sprong, D. H., Jr., and Cutler, N. L. (1930). A case of human right aorta. *Anat. Rec.*, **45**, 365.
- Fontana, R. S., and Edwards, J. E. (1962). *Congenital Cardiac Disease: A Review of 357 Cases Studied Pathologically*. W. B. Saunders, Philadelphia.
- Goldbloom, A. A. (1922). The anomalous right subclavian artery and its possible clinical significance. *Surg. Gynec. Obstet.*, **34**, 378.
- Gravier, J., Vialtel, M., and Pinet, F. (1959). A propos d'une tumeur pulsatile du cou: un cas d'aorte cervicale. *Pédiatrie*, **14**, 437.
- Gross, R. E., and Neuhauser, E. B. D. (1951). Compression of the trachea or esophagus by vascular anomalies. Surgical therapy in 40 cases. *Pediatrics*, **7**, 69.
- Harley, H. R. S. (1959). The development and anomalies of the aortic arch and its branches, with the report of a case of right cervical aortic arch and intrathoracic vascular ring. *Brit. J. Surg.*, **46**, 561.
- Harvey, R. W. (1917). Notes on 2 cases of anomalous right subclavian artery. *Anat. Rec.*, **12**, 329.
- Heim de Balsac, R. (1960). Left aortic arch (posterior or circumflex type) with right descending aorta. *Amer. J. Cardiol.*, **5**, 546.
- Heinrich, W. D., and Perez Tamayo, R. (1956). Left aortic arch and right descending aorta: case report. *Amer. J. Roentgenol.*, **76**, 762.
- Holst, F. (1837). Merkwürdige Missbildungen des Herzens und seiner grossen Gefässe. *Hufeland's J. pract. Heilk.*, **84**, 98. (Abstracted in *Amer. J. med. Sci.*, **21**, 457 [1838]).
- Ivemark, B. I. (1955). Implications of agenesis of the spleen on the pathogenesis of cono-truncus anomalies in childhood. *Acta paediat. (Uppsala)*, Suppl. 104.
- Kasai, T. (1962). Topographic changes of the surrounding structures of the arch of the aorta in various anomalies of aorta in man. *Acta anat. Nippon.*, **37**, 275.
- , Kohara, M., Inatomi, Y., and Hirai, S. (1962). A case of the right sided arch of the aorta with the left subclavian artery as its last branch. *Acta anat. Nippon.*, **37**, 268.
- Keith, J. D., Rowe, R. D., and Vlad, P. (1958). *Heart Disease in Infancy and Childhood*. Macmillan, New York.
- Krause, W. (1868). Varietäten des Aortensystems. In *Handbuch der systematischen Anatomie des Menschen*, ed. J. Henle, vol. 3, pp. 203–235. Vieweg, Braunschweig.
- Lev, M., Alcalde, V. M., and Baffes, T. G. (1961). Pathologic anatomy of complete transposition of the arterial trunks. *Pediatrics*, **28**, 293.
- Liechty, J. D., Shields, T. W., and Anson, B. J. (1957). Variations pertaining to the aortic arches and their branches. *Quart. Bull. Northw. Univ. med. Sch.*, **31**, 136.
- Lochte (1898). Ein Fall von Situs viscerum irregularis, nebst einem Beitrag zur Lehre von der Transposition der arteriellen grossen Gefässstämme des Herzens. *Beitr. path. Anat.*, **24**, 187.
- Lowe, J. B. (1953). The angiocardigram in Fallot's tetralogy. *Brit. Heart J.*, **15**, 319.
- McKim, J. S., and Wiglesworth, F. W. (1954). Absence of the left pulmonary artery. *Amer. Heart J.*, **47**, 845.
- Marder, S. N., Seaman, W. B., and Scott, W. G. (1953). Röntgenologic considerations in the diagnosis of congenital tricuspid atresia. *Radiology*, **61**, 174.
- Massumi, R. A. (1963). The congenital variety of the "subclavian steal" syndrome. *Circulation*, **28**, 1149.
- , Weiner, L., and Charif, P. (1963). The syndrome of cervical aorta. *Amer. J. Cardiol.*, **11**, 678.
- Nadas, A. S. (1963). *Pediatric Cardiology*, 2nd ed., p. 430. W. B. Saunders, Philadelphia.
- Nakagawa, M. (1939a). *J. Juzen med. Soc.*, **44**, 229. (Cited by Kasai (1962) and by Kasai et al. (1962)).
- (1939b). *J. Juzen med. Soc.*, **44**, 243. (Cited by Kasai (1962) and by Kasai et al. (1962)).
- Nozaki, S., and Maki, T. (1950). *Tokyo-Iji-Shinshi*, **67**, 5. (Cited by Kasai et al. (1962)), (in Japanese).
- , and Sekiya, S. (1948). *Niigata med. J.*, **62**, 145. (Cited by Kasai et al. (1962)), (in Japanese).
- Pattinson, J. N., and Emanuel, R. W. (1957). The aorta and pulmonary arteries in Fallot's tetralogy. *Brit. Heart J.*, **19**, 201.
- Paul, R. N. (1948). A new anomaly of the aorta; Left aortic arch with right descending aorta. *J. Pediat.*, **32**, 19.
- Pool, P. E., Vogel, J. H. K., and Blount, S. G., Jr. (1962). Review: Congenital unilateral absence of a pulmonary artery. *Amer. J. Cardiol.*, **10**, 706.
- Poynter, C. W. M. (1916). Arterial anomalies pertaining to the aortic arches and the branches arising from them. *Univ. Stud. Univ. of Nebraska*, **16**, 229.

- Quain, R. (1844). *The Anatomy of the Arteries of the Human Body*, p. 153. Taylor and Walton, London.
- Reivich, M., Holling, H. E., Roberts, B., and Toole, J. F. (1961). Reversal of blood flow through the vertebral artery and its effect on cerebral circulation. *New Engl. J. Med.*, **265**, 878.
- Ruttenberg, H. D., Neufeld, H. N., Lucas, R. V., Carey, L. S., Adams, P., Anderson, R. C., and Edwards, J. E. (1964). Syndrome of congenital cardiac disease with asplenia. Distinction from other forms of cyanotic cardiac disease. *Amer. J. Cardiol.*, **13**, 387.
- Schlamowitz, S. T., Di Giorgi, S., and Gensini, G. G. (1962). Left aortic arch and right descending aorta. *Amer. J. Cardiol.*, **10**, 132.
- Schneiderman, L. J. (1958). Isolated congenital absence of the right pulmonary artery: a caution as to its diagnosis, and a proposal for its embryogenesis.—Report of a case with review. *Amer. Heart J.*, **55**, 772.
- Selzer, A., and Laqueur, G. L. (1951). The Eisenmenger complex and its relation to the uncomplicated defect of the ventricular septum. *Arch. intern. Med.*, **87**, 218.
- Shaher, R. M., and Johnson, A. M. (1963). Isolated levocardia and isolated dextrocardia. Pathology and pathogenesis. *Guy's Hosp. Rep.*, **112**, 127.
- Sommers, S. C., and Johnson, J. M. (1951). Congenital tricuspid atresia. *Amer. Heart J.*, **41**, 130.
- Spencer, J., and Dresser, R. (1936). Right-sided aorta. *Amer. J. Roentgenol.*, **36**, 183.
- Sterz, H. (1961). Dysphagie durch eine seltene Anomalie der Aorta thoracalis: Arcus aortæ sinister circumflexus und Dextroposition der Aorta descendens. *Wien. Z. inn. Med.*, **42**, 420.
- Stewart, J. R., Kincaid, O. W., and Edwards, J. E. (1964). *An Atlas of Vascular Rings and Related Malformations of the Aortic Arch System*. Charles C. Thomas, Springfield, Illinois.
- Tandon, R., Hauck, A. J., and Nadas, A. S. (1963). Persistent truncus arteriosus. A clinical, hemodynamic, and autopsy study of nineteen cases. *Circulation*, **28**, 1050.
- Thomson, A. (1893). Third Annual Report of the Committee of Collective Investigation of the Anatomical Society of Great Britain and Ireland for one year 1891–92. *J. Anat. Physiol. (Lond.)*, **27**, 183.
- Van Praagh, R., Van Praagh, S., Vlad, P., and Keith, J. D. (1964). Review: Anatomic types of congenital dextrocardia. Diagnostic and embryologic implications. *Amer. J. Cardiol.*, **13**, 510.
- Williams, G. D., and Edmonds, H. W. (1935). Variations in the arrangement of the branches arising from the aortic arch in American whites and Negroes. *Anat. Rec.*, **62**, 139.
- Wittenborg, M. H., Neuhauser, E. B. D., and Sprunt, W. H. (1951). Röntgenographic findings in congenital tricuspid atresia with hypoplasia of the right ventricle. *Amer. J. Roentgenol.*, **66**, 712.
- Wood, P. (1956). *Diseases of the Heart and Circulation*, 2nd ed. Eyre and Spottiswoode, London.
- (1958). The Eisenmenger syndrome or pulmonary hypertension with reversed central shunt. *Brit. med. J.*, **2**, 701.