



Case report

Tooth aspiration following emergency endotracheal intubation



Nagesh D. Dhadge

13, Trailokya, Prashant Society, Paud Road, Pune 411038, India

ARTICLE INFO

Article history:

Received 9 September 2015

Received in revised form

27 April 2016

Accepted 4 May 2016

Keywords:

Tooth aspiration

Emergent endotracheal intubation

Flexible bronchoscopy

ABSTRACT

Tooth aspiration in adults during endotracheal intubation is very rare. There are several risk factors for this rare event such as old age, loose teeth, difficult intubation etc. which predispose patients for tooth aspiration in tracheobronchial tree in emergent endotracheal intubation. Although extraction of aspirated tooth with flexible bronchoscopy is a difficult and complex intervention, it is still preferred over rigid scopes due to number of advantages.

This case underlines that appropriate precautions should be taken to prevent a potentially serious medico-legal complication during airway management in emergent circumstances. Also it shows how flexible bronchoscope can be used effectively for extraction of foreign body without major complications.

© 2016 The Author. Published by Elsevier Ltd. This is an open access article under the CC BY-NC-ND license (<http://creativecommons.org/licenses/by-nc-nd/4.0/>).

1. Introduction

Facial trauma or an unfortunate emergency intubation involving dental injury can rarely risk inhalation of tooth in tracheobronchial tree. Meticulous management of airway during emergency clinical situation is of vital importance in preventing such complication. In one of the series incidence of dental injury during endotracheal intubations was 0.2% [4].

2. Case history

A 72 year old elderly male while undergoing permanent pacemaker insertion for complete heart block in cardiac intervention laboratory suffered cardiorespiratory arrest. Patient was given CPR as per existing ACLS guidelines. Patient was also intubated under emergent condition during resuscitation. After successful resuscitation the patient was shifted to ICU with temporary pacemaker.

A check chest X-Ray (Fig. 1) taken after the resuscitation showed a tooth lying in the mid-zone close to hilum which was probably aspirated during intubation into right intermediate bronchus along with subcutaneous emphysema. This was confirmed by absence of previous upper incisor tooth on examination of oral cavity.

Decision to remove inhaled tooth with flexible bronchoscopy was taken. It was a special challenge to remove the tooth from tracheobronchial tree in a post cardiac arrest scenario with pace maker. Diagnostic examination with flexible bronchoscopy done

under local anaesthesia via nasal route showed incisor tooth lodged into apical segment of right lower lobe. Initial multiple attempts to catch tooth with Alligator forceps failed to hold the tooth firmly due to slippery smooth surface. The dormia basket was then passed through the side channel of the fiberoptic bronchoscope and opened after passing it beyond the tooth in the apical segment. The dormia basket was pulled out very slowly while it was open. With this technique, after few attempts it was possible to grasp tooth in the basket. As the size of foreign body was larger than side channel of the bronchoscope, bronchoscope and tooth along with dormia basket forceps was withdrawn en block (Fig. 2).

There was no major trauma while removing assembly of scope and forceps altogether from tracheobronchial tree. The patient tolerated the procedure very well despite being on temporary pacemaker and compromised cardiac function.

3. Discussion

In particular, emergency endotracheal intubations face increased risk of intubations related complications as opposed to non-emergent intubations [4,6,8]. Among few possible complications, rarely tooth aspiration in bronchial tree can occur in cases where enough care is not taken while intubating the patient. Although tooth aspiration in the setting of emergency endotracheal intubation is uncommon but a well-known complication [1]. This is especially true in old age with loose teeth and in patients with maxillofacial injury [9].

Removal of aspirated foreign body by bronchoscopy is a complicated intervention especially in unfavourable clinical

E-mail address: ndhadge@hotmail.com.

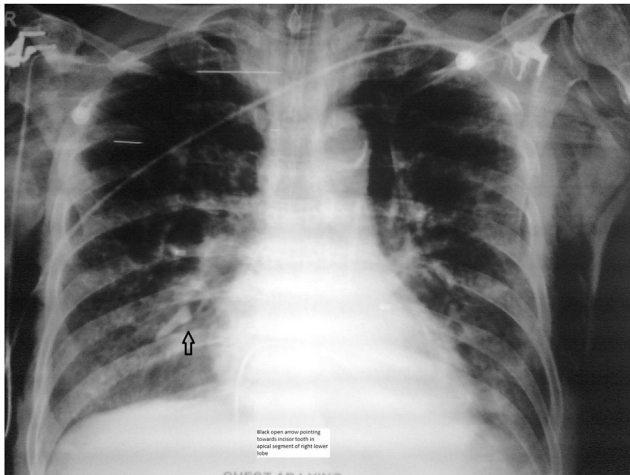


Fig. 1. Black open arrow showing incisor tooth in apical segment of right lower lobe.

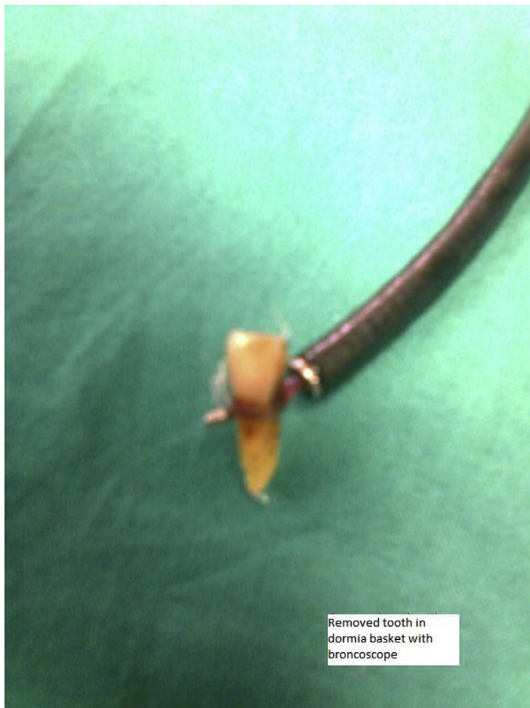


Fig. 2. Removed incisor tooth held in dormia basket with bronchoscope.

circumstances [5].

Previously rigid bronchoscopy was a natural choice for removal of tracheobronchial foreign bodies. But with greater availability of flexible bronchoscopes with technically advanced forceps, especially retrieving forceps, foreign bodies are being increasingly

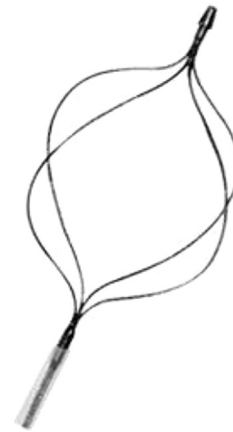

Fig. 3. Dormia basket forceps.

removed by flexible bronchoscope as illustrated in the present case [2,3].

Flexible bronchoscope is preferred in clinical situations where foreign bodies are lodged in peripheral airways or when the patient is unstable. This is largely because the structural design of the flexible bronchoscope allows greater flexibility in accessing the foreign body and making intervention easier than rigid scopes and also it can be performed under local anaesthesia with mild sedation [7]. The type of forceps which are used is guided primarily by the type of foreign body to be removed [7].

Dormia basket (Fig. 3) is an ideal forceps for removing aspirated tooth due to its excellent grasping ability over smooth and slippery surface. The success rate of foreign body removal reported with fiberoptic bronchoscope in literature ranges from 40 to 90% in adults [6].

References

- [1] Y. Ostrinsky, Z. Cohen, Images in clinical medicine. Tooth aspiration, *N. Engl. J. Med.* 354 (2006 Jun 15) e25.
- [2] Y.C. Dong, G.W. Zhou, C. Bai, H.D. Huang, Q.Y. Sun, Y. Huang, et al., Removal of tracheobronchial foreign bodies in adults using a flexible bronchoscope: experience with 200 Cases in China, *Intern Med.* 51 (2012) 2515–2519.
- [3] R. Goyal, S. Nayar, P. Gogia, M. Garg, Removal of tracheobronchial foreign bodies in adults using a flexible bronchoscope – extraction of tracheobronchial foreign bodies in children and adults with rigid and flexible bronchoscopy, *J. Bronchology Interv. Pulmonol.* 19 (2012) 35–43.
- [4] L.D. Martin, J.M. Mhyre, A.M. Shanks, K.K. Tremper, S. Kheterpal, 3,423 emergency tracheal intubations at a university hospital: airway outcomes and complications, *Anesthesiology* 14 (2011) 42–48.
- [5] M. Mahmoud, S. Imam, H. Patel, M. King, Foreign body aspiration of a dental bridge in the left main stem bronchus, *Chest* 2012 (2012) 798163.
- [6] A.H. Limper, U.B. Prakash, Tracheobronchial foreign bodies in adults, *Ann. Intern Med.* 112 (1990) 604–609.
- [7] J.F. Fieselmann, D.C. Zavala, L.W. Keim, Removal of foreign bodies (two teeth) by fiberoptic bronchoscopy, *Chest* 72 (1977) 241–243.
- [8] D.A. Taryle, J.E. Chandler, J.T. Good, D.E. Potts, S.A. Sahn, Emergency room intubations-complications and survival, *Chest* 75 (1979) 541–543.
- [9] M.C. Newland, S.J. Ellis, K.R. Peters, J.A. Simonson, T.M. Durham, F.A. Ullrich, et al., Dental injury associated with anesthesia: a report of 161,687 anesthetics given over 14 years, *J. Clin. Anesth.* 19 (2007) 339–345.