

# Brain damage complicating septic shock

## Acute haemorrhagic leucoencephalitis as a complication of the generalised Shwartzman reaction

D. I. GRAHAM, P. O. BEHAN, AND I. A. R. MORE

*From the University Departments of Neuropathology and Neurology, Institute of Neurological Sciences, Glasgow, and the University Department of Pathology, Western Infirmary, Glasgow*

**SUMMARY** The neuropathological findings in six patients who developed neurological signs after the onset of "septic shock" caused by Gram-negative septicaemia are described. The changes in the brains were characteristic of acute haemorrhagic leucoencephalitis, and there was evidence, particularly in the kidneys, of disseminated intravascular coagulation with tubular necrosis and, in some, appearances indistinguishable from membrano-proliferative glomerulonephritis. It is agreed that acute haemorrhagic leucoencephalitis is another manifestation of a generalised Shwartzman reaction, and it is suggested that activation of complement is the final common pathway that produces tissue damage in the brain and kidney.

Acute haemorrhagic leucoencephalitis (Hurst, 1941), known also as acute necrotising haemorrhagic encephalopathy (Adams *et al.*, 1949), is a distinct clinical and pathological entity, characterised by a rapid and dramatic onset, a short clinical course and, usually, a fatal outcome (Behan *et al.*, 1973). Even though it is uncommon and its exact incidence is unknown, it would be wrong to consider it rare, since most laboratories of neuropathology will have encountered several cases. Hurst (1941) was the first to suggest that acute haemorrhagic leucoencephalitis (AHLE) was a demyelinating disease, although it had been well described previously both clinically and pathologically (Strümpell, 1891; Leichtenstern, 1892; Brie, 1897). The aetiology is unknown but most evidence favours an immunopathological basis.

Most cases arise in the wake of a banal upper respiratory tract infection but some have been described in association with diseases presumed to be autoallergic—for example, thrombotic thrombocytopenic purpura (Symmers, 1956), ulcerative colitis (Glotzer *et al.*, 1964), acute rheumatism (Dobbs and de Saram, 1938), acute glomerulonephritis (Aldridge, 1956), and asthma and other atopic phenomena (Greenfield, 1950; Moossy *et al.*, 1954; Aronson and Aronson, 1966). Acute

haemorrhagic leucoencephalitis may occur after sensitisation to drugs—for example, sulphonamides (Fisher and Gilmour, 1939; Henson and Russell, 1942), arsphenamine (Russell, 1937), oxyphenarsine (Symmers, 1956), and para-amino salicylic acid (Edge, 1951; Marsh, 1952; Cavanagh, 1953). It has also followed pertussis immunisation (Moossy *et al.*, 1954) and administration of antitetanus serum (Csermely, 1950).

There is one well-documented report of AHLE occurring in association with the generalised Shwartzman reaction complicating Gram-negative septicaemia (Masland and Barrows, 1962). We describe here six further cases of AHLE occurring with the generalised Shwartzman reaction, and suggest that a common pathological mechanism involving damage to the endothelium of small vessels may underlie this association.

### Subjects and methods

There were six patients, three men and three women, with an age range from 30 to 75 years. In some instances particular details were missing either because the study was retrospective and the pertinent investigations were not undertaken, or the patient's condition was so critical that the first priority was that of resuscitation.

A comprehensive necropsy was undertaken in each case, and representative blocks were taken from all major organs and embedded in paraffin

Address for correspondence and reprint requests: Dr D. I. Graham, Department of Neuropathology, Institute of Neurological Sciences, Southern General Hospital, Glasgow, G51 4TF.

Accepted 2 July 1978

wax. Sections were stained routinely with haematoxylin and eosin and by Martius' Scarlet Blue for fibrin. Each brain was suspended in 10% formol saline for three weeks before dissection. The mid-brain was transected, and the cerebral hemispheres were cut in the coronal plane into slices 10 mm thick. After removing the cerebellum the brainstem was cut horizontally at a number of levels. Representative blocks of the cerebral hemispheres, cerebellum, and the brainstem were embedded in paraffin wax, and sections were stained by haematoxylin and eosin, Martius' Scarlet Blue, and a method that combines Luxol fast blue and cresyl violet.

### Clinico-pathological summaries

#### CASE 1

A 30 year old, previously healthy man (TC) was admitted to hospital after a road accident with a fracture of the pelvis and intra-abdominal injuries. At operation there was rupture of the left dome of the diaphragm and of the spleen, perforation of the jejunum, laceration of the tail of the pancreas, and retroperitoneal haemorrhage. After operation his blood pressure was "very variable," and over the next 48 hours he was transfused with 8 units of blood and 1 unit of plasma. He then became comatose, and was found to have a left superficial retinal haemorrhage and a left hemiparesis. He was treated with hydrocortisone but his blood pressure continued to fall, and he died four days after admission.

At necropsy there was evidence of resolving peritonitis. The kidneys were enlarged (each 250 g), and microscopy showed evidence of tubular necrosis and nonspecific glomerular abnormalities in the form of mild mesangial hypercellularity.

#### CASE 2

A 41 year old man (EB) was admitted to hospital with an acute haematemesis. There was a pancytopenia with a haemoglobin level of 7 g/dl, a total white cell count of  $1.4 \times 10^9$ /litre, and a thrombocytopenia of  $20 \times 10^9$ /litre. He was transfused with four units of blood and treated with prednisolone 20 mg per day before discharge some two days later. Sixteen months previously he had had a clear cell carcinoma of the left kidney treated by nephrectomy and a course of radiotherapy. He had been well until the haematemesis. He was readmitted two days after discharge with bloody diarrhoea and a further haematemesis. A coagulation screen on both admissions showed only thrombocytopenia. He was transfused with a further four units of blood and continued on

steroid therapy. He continued to bleed, with haemorrhages into his lips, from his nose, and from the gastrointestinal tract. At this time superficial haemorrhages in the left retina were noted. He complained of headache which was worse on coughing, and he developed a fever. The patient was transfused with a further four units of blood on the sixth day after admission, and on the 14th day another two units were given. But the pancytopenia persisted, and on the 14th day his platelets were less than  $10 \times 10^9$ /litre. Blood cultures were negative until six days after admission when *Pseudomonas pyocyanea* was isolated. At this stage he was confused, obtunded, hypotensive, and oliguric. Despite intensive therapy he continued to deteriorate with further haemorrhage from the gastrointestinal tract, and he died 14 days after admission. During the last days of the illness the blood urea rose from 9.7 to 26.8 mmol/l.

At necropsy the upper respiratory tract contained a large amount of heavily blood-stained fluid. The lungs were haemorrhagic and heavy. There were numerous petechial haemorrhages in the epicardium, in the oesophagus, throughout the gastrointestinal tract, in the kidney, and in the bladder. The right kidney weighed 280 g, and there was no evidence of residual tumour at the site of left nephrectomy. No metastases were identified. The bone marrow was pale and excessively fatty. Microscopy confirmed multiple petechial haemorrhages in most organs. The bone marrow was markedly hypocellular and no evidence of tumour was found. The kidney showed acute tubular necrosis and mild mesangial hypercellularity.

#### CASE 3

A 53 year old married woman (JMCK) complained of severe constipation, excessive flatulence, and right upper abdominal pain of three years duration. Examination revealed tenderness in the right hypochondrium. A barium meal was normal, and a cholecystogram showed gallstones. She was admitted to hospital for a cholecystectomy. One week after an otherwise uneventful operation she developed "septic" shock characterised by hypotension, pyrexia, and oliguria. She was treated with intravenous fluids, hydrocortisone, and antibiotics. Blood cultures were sterile and, despite therapy, she became progressively more oliguric, the blood urea rising from 10 mmol/l to 40 mmol/l. Haemodialysis was started. On the sixth day after the onset of septic "shock" the patient developed aphasia and bilateral hemiparesis. Hours later she lapsed into coma, and remained comatose until her death six days later.

The principal findings at necropsy were bronchopneumonia and peritonitis localised to the right pericolic gutter. Each kidney weighed 170 g and showed pallor of the cortex. Microscopy showed evidence of acute necrosis and, in addition, the glomeruli showed generalised hypercellularity with accentuation of the lobular pattern, appearances indistinguishable from a membrano-proliferative glomerulonephritis. A few of the arterioles showed "onion-skin" change.

#### CASE 4

A 71 year old man (GMCI) was admitted to hospital with a transcervical fracture of the neck of the right femur. His health had been good until about two years before when he developed acute rheumatoid arthritis. This had been treated successfully with aspirin, indomethacin, and phenylbutazone. His fracture was fixed internally. After operation he became pyrexial and hypotensive because of a urinary tract infection. The next day he developed a right sided hemiplegia, and lapsed into coma. He was treated symptomatically but died hours later. In the days preceding death the blood urea rose from 9 to 36.3 mmol/l.

At necropsy there was extensive inflammation of the bladder and evidence of bilateral ascending pyelonephritis. The right kidney weighed 210 g and the left 160 g. Histologically there was an intense transmural acute cystitis and evidence of acute pyelonephritis with microabscess formation. There was no evidence of acute tubular necrosis. The glomeruli showed lobular accentuation of the tufts with occasional fibrin plugs. The smaller vessels showed focal subendothelial deposition of fibrin.

#### CASE 5

A 72 year old woman (JW) with a history of intermittent diarrhoea for about three years was admitted to hospital because of a particularly severe episode of diarrhoea when she had lost 9.5 kg in weight. On admission she was dehydrated with a left parotitis and tenderness over the left iliac fossa. Investigations showed that she had both diverticulitis and Crohn's disease. Her hospital course was complicated by a Heinz body anaemia secondary to sulphasalazine (Salazopyrin) therapy. She was treated with prednisolone 40 mg daily, and subsequently developed generalised oedema with a low total serum protein, a deep venous thrombosis of the left leg, and a severe oesophagitis. Her general condition necessitated parenteral feeding but the indwelling venous catheter became infected, giving rise to a septi-

caemia. *Candida albicans*, lactose fermenting coliforms, and *Staphylococcus aureus* were grown in blood culture. She was treated with steroids, fresh blood, antifungal agents, and antibiotics, but her pyrexia continued, and four days later she became drowsy and confused, and lapsed into coma. She died without having regained consciousness, two weeks after the onset of septicaemia. The blood urea rose to 20.2 mmol/l three days before death.

At necropsy there were multiple cutaneous petechiae. A large cavity was present in the right lung. The colon was thickened and its mucosa ulcerated: many diverticulae were seen. The kidneys weighed 160 g and 150 g. Microscopy of the lungs showed abscess formation secondary to infarction. Sections of the colon showed chronic inflammation consistent with Crohn's disease. As elsewhere (adrenal glands, heart, spleen, bone marrow, and colon) there were microinfarcts in the cortex and medulla of the kidneys with evidence of acute tubular necrosis. There was much deposition of fibrin in both glomerular capillary loops and in the walls of interlobular arteries and arterioles. Focal fibrinoid necrosis of glomerular tufts was also seen, and there was evidence of more widespread mesangial proliferation, features that were indistinguishable from a membrano-proliferative glomerulonephritis.

#### CASE 6

A 75 year old woman (NG) was admitted to hospital in a moribund condition. She was semicomatose and hypotensive, and had peripheral cyanosis and pyrexia. She was known to have ulcerative colitis and diverticulitis. She died on the day of admission and laboratory studies were not undertaken. Her relatives stated that she had developed severe diarrhoea and vomiting four days before admission.

The main findings at necropsy were a pelvic peritonitis secondary to obstruction of the sigmoid colon by an annular carcinoma. There were widespread metastases in the liver, lungs, and lymph nodes. There was evidence of ischaemic heart disease. Each kidney weighed 200 g. Microscopy confirmed a primary adenocarcinoma of the colon with multiple metastases. There was also evidence of underlying ulcerative colitis, and a recent infarct was identified in the myocardium. The renal glomeruli were hypercellular with accentuation of the lobular pattern and focal thickening of the basement membrane, appearances which, though not typical, were best regarded as a membrano-proliferative glomerulonephritis.

## Neuropathology

### MACROSCOPIC

In case 1 the brain (1330 g) was normal externally. On section there were large numbers of petechial haemorrhages scattered throughout the white matter of the cerebral hemispheres. There was no evidence of a head injury, and frozen sections showed no evidence of fat embolism. The cerebellum and brainstem were normal.

The brain (1725 g) in case 2 was swollen, and there was considerable flattening of the convolutions. There was also a tonsillar hernia and extensive recent subarachnoid haemorrhage in the basal cisterns. Coronal sections showed replacement of the lentiform nucleus, the corpus callosum, the external capsule, and much of the white matter of the posterior half of the cerebral hemisphere on the right by confluent petechial haemorrhages. A number of haemorrhages were also seen in the left internal capsule and in the midbrain.

The brain (1410 g) in case 3 was swollen with bilateral flattening of the convolutions but no evidence of internal herniation. Coronal sections showed bilateral and essentially symmetrical confluent petechial haemorrhages in the deep white matter of the cerebral and cerebellar hemispheres (Figs. 1 and 2). There was also some involvement of the lentiform and dentate nuclei.

The brain (1480 g) in case 4 showed an acute meningitis. On section there were confluent petechial haemorrhages and frank haematoma formation in the white matter of the posterior part of the temporal and occipital lobes of the right hemisphere. The cerebellum and brainstem were normal.

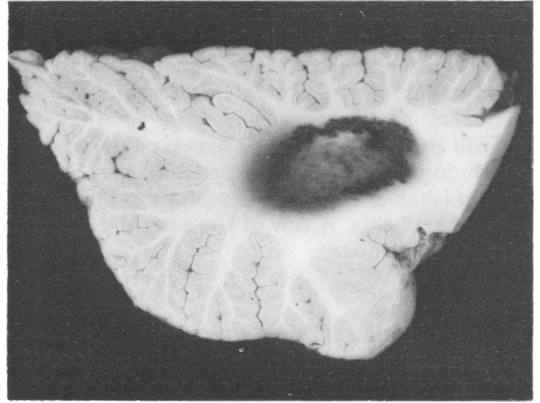


Fig. 2 Case 3. Right cerebellum. The deep white matter and dentate nucleus are obscured by confluent petechial haemorrhages.

In case 5 the brain (1150 g) was normal externally. On section a number of petechial haemorrhages were seen in the white matter of both the cerebral and cerebellar hemispheres.

In case 6 the brain (1300 g) was normal externally. On section areas of confluent petechial haemorrhages were seen in the white matter of the left temporal and occipital lobes (Fig. 3).

### MICROSCOPIC

The histological appearances were similar in each of the six cases, any differences being accounted for by the length of survival after the onset of the neurological signs until death.

Histological examination showed that the disease process extended beyond the haemorrhagic areas, although there was relative sparing of both

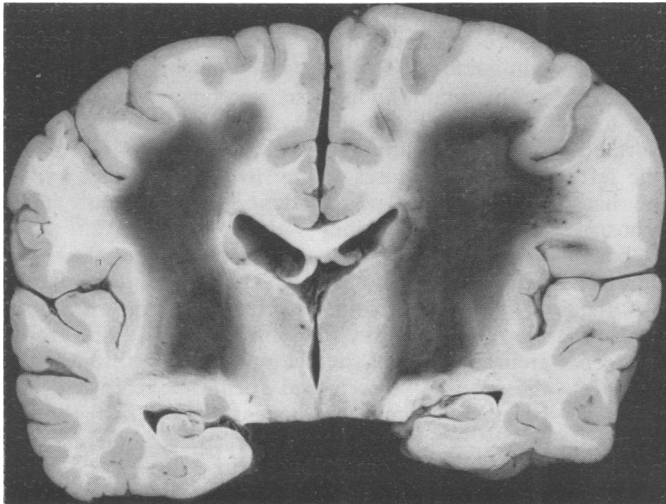


Fig. 1 Case 3. Coronal section of brain. Confluent petechial haemorrhage is present in the deep white matter including the internal capsules and in the lentiform nuclei.

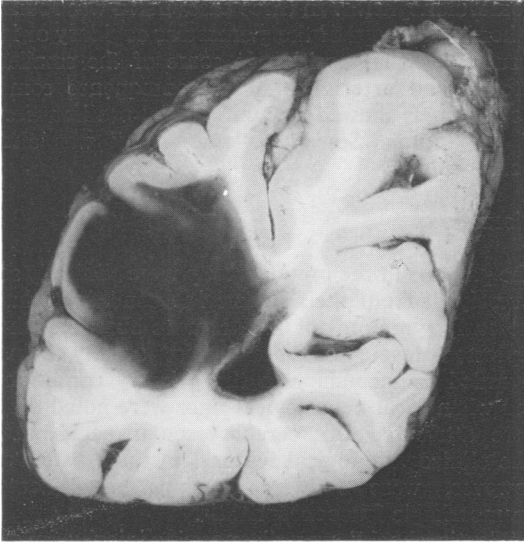

Fig. 3 Case 6. Coronal section of left occipital lobe. The white matter and part of the cortex of the lateral convexity are extensively haemorrhagic.

the cortex and the thalami. The features were typical of those associated with AHLE.

1. Necrosis of vessel walls with exudation of fibrin into and through the wall into the perivascular space. Most of these vessels appeared to be venules (Fig. 4).
2. Perivascular "oedema" which tended to become confluent and to affect fairly large areas of the white matter.
3. Infiltration of the abnormal areas by polymorphonuclear leucocytes in the early stages and later by mononuclear cells.
4. Zones of perivascular tissue destruction most easily seen in the preparations stained for myelin (Fig. 5). These were usually seen around vessels, not all of which showed evidence of fibrinoid necrosis. In cases with a short survival this necrosis was associated with hypertrophy of microglial cells and in later cases with lipid phagocyte formation.
5. Ball or ring haemorrhages or both, some of which were related to necrotic vessels (Fig. 6). The ring haemorrhages were usually centred on a thrombosed capillary around which there was a narrow zone of necrotic tissue.

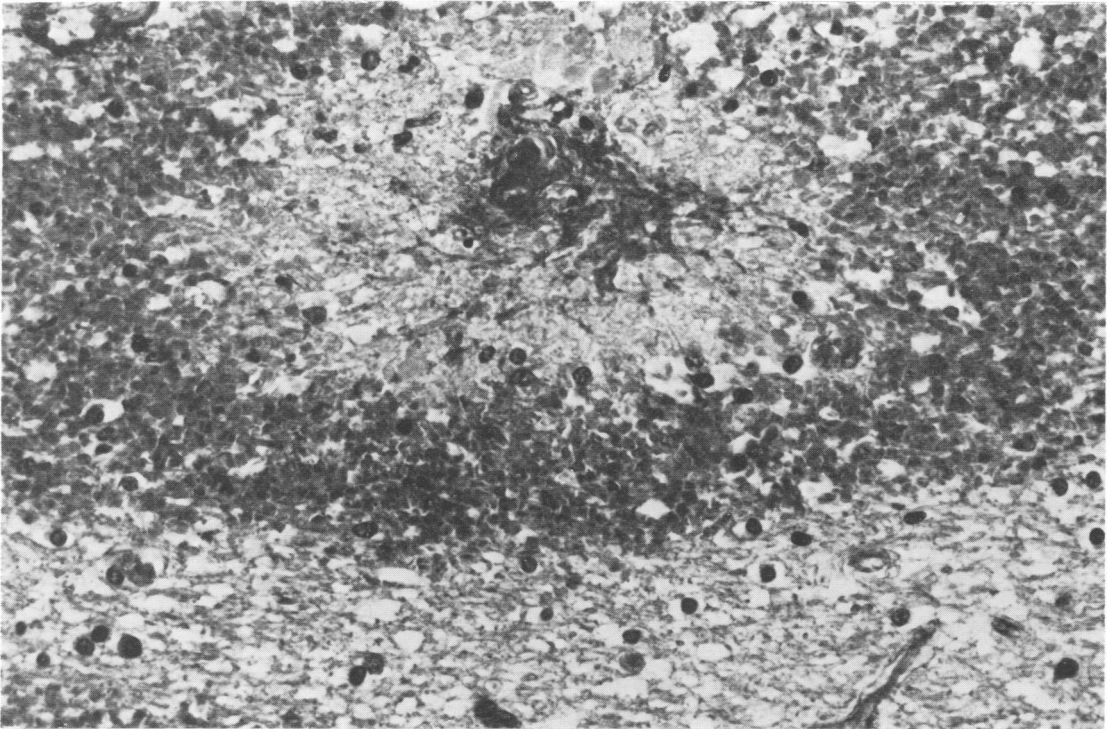


Fig. 4 Small vessel showing fibrinoid necrosis in centre of ring haemorrhage. There is some swelling of the perivascular space which also contains a mild infiltrate of mononuclear cells. Martius Scarlet Blue, original magnification  $\times 670$ .

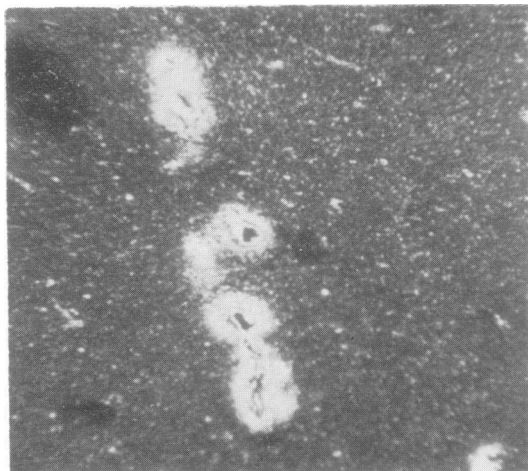


Fig. 5 Foci of perivascular demyelination. Woelcke's modification of Heidenhain's method for myelin, original magnification  $\times 160$ .

### Renal pathology

#### MICROSCOPIC

To summarise the kidney findings, five of the six cases showed evidence of acute tubular necrosis (Fig. 7), the enlarged kidneys demonstrating sleeve separation of the tubular epithelial cells, much debris in the lumen of the tubules, karyolysis, pyknosis, and evidence of mitotic activity. In addition, the glomeruli showed a spectrum of abnormalities ranging from nonspecific increase in mesangial cells and matrix to marked lobular accentuation of the glomerular tuft with thickening of the basement membrane—appearances indistinguishable from a membrano-proliferative

glomerulonephritis. In three cases fibrin was found either in the loops of the glomerular capillary or in a subendothelial position in some of the smaller arteries and arterioles. As a consequence some blood vessels showed circumferential proliferation of the intima. So-called "onion-skin" was also seen.

### Discussion

The patients in the present group were clinically so severely ill from their underlying conditions that the early symptoms of AHLE were obscured, the depressed level of consciousness usually being regarded as secondary to the primary condition, and when focal neurological signs were noted they were attributed to "cerebrovascular accidents." The clinicopathological features in these patients, however, were fully in keeping with acute haemorrhagic leucoencephalitis.

"Septic shock" was diagnosed clinically in all these patients and while an organism was isolated from only two cases, the underlying condition and the clinical findings leave little doubt that bacteraemic shock had occurred. Furthermore the finding in five of the six cases of renal tubular necrosis, together with fibrin thrombi, suggests that these patients may have had the generalised Schwartzman reaction which is known to complicate endotoxic shock (Mergenhagen *et al.*, 1969).

The generalised Schwartzman reaction, as usually described, is related to the lesions produced experimentally in young rabbits after two intravenous injections of Gram-negative endotoxin, spaced 24 hours apart. After the first injection occasional small fibrin thrombi may be found in the viscera (Brunson and Davis, 1955), and after the second

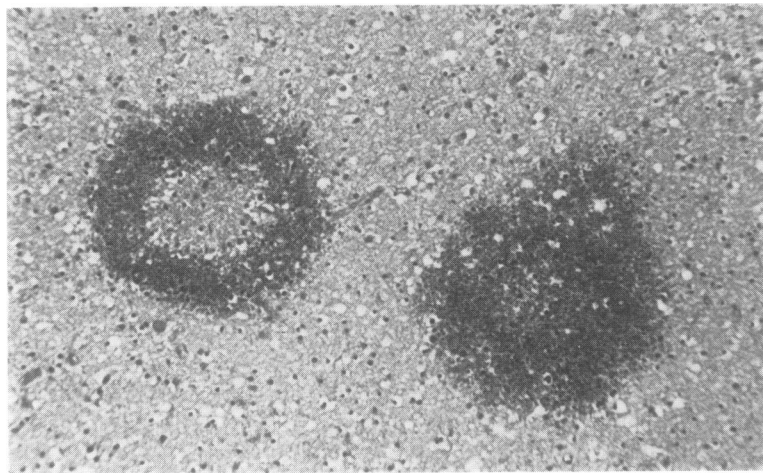


Fig. 6 Ring and ball haemorrhages. Haemalum and eosin, original magnification  $\times 370$ .

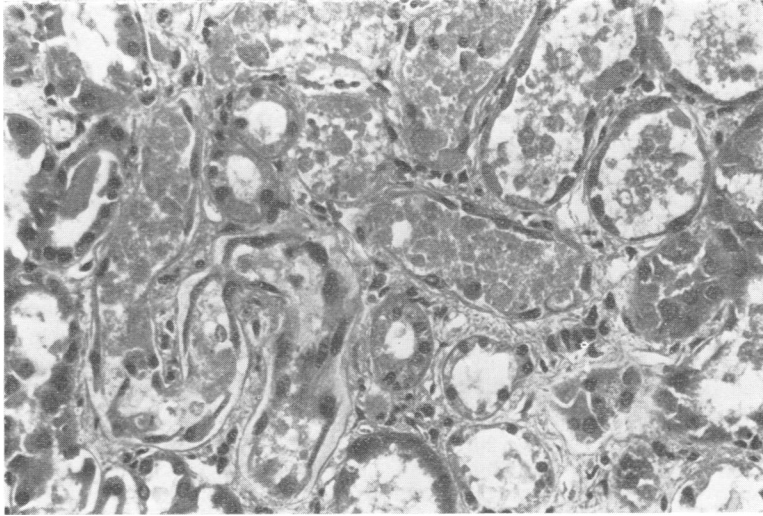


Fig. 7 Renal tubular necrosis. There is dilatation of tubules, which are full of debris, and sleeve separation of the epithelium. Mitotic figures were also seen. Haemalum and eosin, original magnification  $\times 370$ .

injection fibrin is deposited in the splenic sinusoids and in other tissues. This is often prominent in the kidney where acute tubular or cortical necrosis may develop. Accompanying the deposition of fibrin, a bleeding tendency with features of consumption coagulopathy and the red cell changes of microangiopathic haemolytic anaemia develop (Brain *et al.*, 1962). Tissue damage is due to ischaemia caused by widespread thrombosis of small vessels. In man, endotoxic shock is manifested clinically by sudden collapse with hypotension and pyrexia. It may occur after a variety of infections, commonly those arising in the urinary tract. It is considered to be secondary to the sudden entry into the blood of endotoxin and a positive blood culture may be obtained, or using the Limulus assay, a higher incidence of endotoxaemia can be detected (Wardle, 1975).

The major effects of endotoxin—that is, fever, shock, and the local tissue changes—can be reproduced in the laboratory using antigen-antibody reactions (Stetson, 1964). Indeed the striking analogy between the lesions produced by endotoxin and those caused by antigen-antibody complexes has made several workers postulate a similar final common pathway in both (Mergenhagen *et al.*, 1969). When complement is activated by antigen-antibody complexes, the factors produced cause a variety of reactions including immune adherence of platelets (Siqueira and Nelson, 1961), adherence of leucocytes (Nelson, 1961), and the production of anaphylatoxic factors (Cochrane and Müller-Eberhard, 1968), together with chemotactic factors (Ward *et al.*, 1965), and cytotoxic factors (Nelson, 1965; Müller-Eberhard *et al.*, 1966). It will be seen that these reactions produced by com-

plement activated by the classical pathway are analogous to the effects of endotoxin, and indeed studies have shown that endotoxin is capable of activating complement from C3 through the terminal sequence. Activation of C1, C4, and C2, as occurs in classical antigen-antibody reactions, is not affected (Gewurz *et al.*, 1968; Fearon *et al.*, 1975). Patients developing Gram-negative septicaemia have depressed levels of C3 (McCabe, 1973), implying that complement has been activated. Subsequent studies of these patients have shown that there is no depression in the levels of Clq, Cls, C4, or C2, in contrast to the marked depression of C3, thus suggesting that activation has occurred by means of the alternative or properdin pathway (Fearon *et al.*, 1975).

One case of the generalised Shwartzman reaction has been reported in which the condition was complicated by AHLE (Masland and Barrows, 1962). Other occasional reports have described brain lesions in Gram-negative septicaemia which may have been AHLE, but the authors did not mention its possible significance nor suggest that the lesions were indeed AHLE. Graber *et al.* (1960) described a patient with 90% body-surface burns who developed a urinary tract infection with *Serratia marcescens*. This patient had deepening coma, and was found at necropsy to have the histological changes of the Shwartzman reaction in the kidneys, but no mention was made of the brain. Similarly, encephalopathy has been described in a young woman with septic abortion (McKay *et al.*, 1959) and in children with epidemic gastroenteritis (McKay and Wahle, 1955), but the neuropathological findings were not exactly those of AHLE. There was, however, plugging of

capillary vessels with fibrin thrombi and some of the vessels were cuffed by inflammatory cells. Swelling of the brain with subarachnoid, subdural, and intraventricular haemorrhage was also found.

The patients described by Burger and Vogel (1977) would seem to be similar to those described in the present paper and, while the authors mentioned AHLE briefly in their discussion, they considered that "hypotension stands out as the common and presumably the major, though certainly not the sole, insult." This was also the conclusion of Ginsberg *et al.* (1976) who attributed the cerebral lesions in their cases of Gram-negative shock to hypoxia and ischaemia.

One of the characteristic histological features of AHLE is necrosis of small vessels, a feature that gives rise to the haemorrhage. Russell (1955) had earlier shown that the vascular lesions in AHLE were similar histologically to those found in polyarteritis nodosa. She also demonstrated that the small haemorrhages, together with the perivenous cellular infiltrates found in AHLE, were similar to those in the parainfective and post-infective encephalomyelitides, and suggested that AHLE was a hyperacute form of postvaccinal encephalomyelitis.

Experimental allergic encephalomyelitis (EAE) is an inflammatory disease of the white matter produced experimentally in susceptible mammals by sensitisation to myelin antigens, and there is good evidence that the pathogenesis of the disease is that of cell-mediated immunity to myelin antigens (Behan *et al.*, 1973). The earliest lesions in EAE occur in the cerebral vessels in which there is increased permeability to albumin and other serum proteins (Oldstone and Dixon, 1968; Leibowitz and Kennedy, 1972). Indeed using a fluorescent antibody method, leakage of fibrinogen, C3, and immunoglobulins from the cerebral vessels has been shown to occur before the appearance of inflammatory cells (Oldstone and Dixon, 1968). This suggests that factors as yet unknown may affect the cerebral vessels in EAE. In hyperacute EAE, especially as seen in primates (Behan *et al.*, 1973), the clinical, pathological, and immunological features are similar to those described in AHLE in man. In hyperacute EAE there is intense necrosis of small vessels. The role of complement in EAE has been studied in small animals. In one group of complement-depleted rats there was little effect on the development of the disease (Levine *et al.*, 1971), but another study showed that depletion of complement significantly affected the development of EAE. Indeed, the findings led the authors to propose that "the full expression of EAE requires both humoral and cellular immune

mechanisms" (Pabst *et al.*, 1971). The exact role of complement in the vascular lesions of EAE, however, is not fully known.

The most common cause of AHLE is a preceding virus infection. In these cases activation of complement may occur secondarily to the formation of antigen-antibody complexes. Complement-fixing antibodies to brain material have been demonstrated in the encephalitis after rabies vaccination (Kirk and Ecker, 1949; Koprowski and Le Bell, 1950), which are analogous to those found in EAE (Paterson, 1966). Acute haemorrhagic leucoencephalitis complicating serum sickness is readily explained on the basis of complement-mediated endothelial damage (Park and Good, 1974). A similar mechanism can be clearly seen to be involved in thrombotic thrombocytopenic purpura, and in the Arthus reaction associated with hypersensitivity to drugs (Park and Good, 1974).

We postulate, therefore, that AHLE complicating Gram-negative septicaemia occurs because the endotoxic shock produces a Shwartzman reaction, activates complement, and produces endothelial damage. Corroborative evidence for this suggestion is found in the kidneys of the present cases in which the features of disseminated intravascular coagulation were seen. Thus, at one end of the spectrum there is acute tubular necrosis (Clarkson *et al.*, 1970; MacDonald *et al.*, 1973; Wardle, 1973) and at the other, where abundant fibrin is deposited, there is progressive occlusion of vessels and glomeruli, leading in untreated patients to uraemia and death (Kincaid-Smith, 1975) with prominent "onion-skin" change of blood vessels.

The findings in the patients of this series suggest that complement is involved in the vasculopathy that gives rise to some forms of demyelination.

We would like to thank Professor J. H. Adams and Dr W. M. H. Behan for helpful criticism of the paper, the Department of Medical Illustration, Southern General Hospital, Glasgow, for photographic assistance, and Mrs J. Rubython for typing the manuscript.

## References

- Adams, R. D., Cammermeyer, J., and Denny-Brown, D. (1949). Acute necrotising haemorrhagic encephalopathy. *Journal of Neuropathology and Experimental Neurology*, **8**, 1-29.
- Aldridge, H. E. (1956). Acute haemorrhagic leucoencephalitis. *British Medical Journal*, **2**, 807-808.
- Aronson, S. M., and Aronson, B. E. (1966). Clinical neuropathological conference. *Diseases of the Nervous System*, **26**, 135-140.



- Behan, P. O., Kies, M. W., Lisak, R. P., Sheremata, W., and Lamarche, J. B. (1973). Immunological mechanisms in experimental encephalomyelitis in non-human primates. *Archives of Neurology (Chicago)*, **29**, 4-9.
- Brain, M. C., Dacie, J. V., and Hourihane, D. O'B. (1962). Microangiopathic haemolytic anaemia: the possible role of vascular lesions in pathogenesis. *British Journal of Haematology*, **8**, 358-374.
- Brie, Von D. (1897). Über einem Fall von primärer acuter Encephalitis haemorrhagica (nebenbei ein seltener Nierenbefund). *Neurologische Zentralblatt*, **16**, 2-10.
- Brunson, J. G., and Davis, R. L. (1955). Systemic fibrinoid disease: similarity to experimental lesions in rabbits. *Archives of Pathology (Chicago)*, **60**, 593-609.
- Burger, P. C., and Vogel, F. S. (1977). Hemorrhagic white matter infarction in three critically ill patients. *Human Pathology*, **8**, 121-132.
- Cavanagh, J. B. (1953). Encephalopathy following the administration of streptomycin and para-aminosalicylic acid. *Journal of Clinical Pathology*, **6**, 128-131.
- Clarkson, A. R., MacDonald, M. K., Fuster, V., Cash, J. D., and Robson, J. S. (1970). Glomerular coagulation in acute ischaemic renal failure. *Quarterly Journal of Medicine*, **39**, 585-599.
- Cochrane, C. G., and Müller-Eberhard, H. J. (1968). The derivation of two distinct anaphylatoxin activities from the third and fifth components of human complement. *Journal of Experimental Medicine*, **127**, 371-386.
- Csermely, H. (1950). Demyelinating encephalomyelitis following use of anti-tetanus serum. *Archives of Neurology and Psychiatry (Chicago)*, **64**, 676-684.
- Dobbs, R. H., and de Saram, G. S. W. (1938). Acute haemorrhagic encephalitis associated with acute rheumatism. *Journal of Pathology and Bacteriology*, **46**, 437-440.
- Edge, J. R. (1951). Diffuse encephalopathy after streptomycin treatment. *Tubercle*, **32**, 58-60.
- Fearon, D. T., Ruddy, S., Schur, P. H., and McCabe, W. R. (1975). Properdin pathway of complement in Gram-negative bacteremia. *New England Journal of Medicine*, **292**, 937-940.
- Fisher, J. H., and Gilmour, J. R. (1939). Encephalitis following administration of sulphanimide. *Lancet*, **2**, 301-305.
- Gewurz, H., Shin, H. S., and Mergenhagen, S. E. (1968). Interactions of the complement system with endotoxic lipopolysaccharide: consumption of the six terminal complement components. *Journal of Experimental Medicine*, **128**, 1049-1057.
- Ginsberg, M. D., Hedley-Whyte, E. T., and Richardson, E. P. (1976). Hypoxic-ischaemic leukoencephalopathy in man. *Archives of Neurology (Chicago)*, **33**, 5-14.
- Glotzer, D. J., Yuan, R. H., and Patterson, J. F. (1964). Ulcerative colitis complicated by toxic megacolon, polyserositis and haemorrhagic leucoencephalitis with recovery. *Annals of Surgery*, **159**, 445-450.
- Graber, C. D., Tumbusch, W. T., Rudnicki, R. P., and Vogel, E. H. (1960). Generalised Shwartzman-like reaction following *Serratia marcescens* septicemia in a fatal burn. *Surgery, Gynecology and Obstetrics*, **110**, 443-450.
- Greenfield, J. G. (1950). Encephalitis and encephalomyelitis in England and Wales during the last decade. *Brain*, **73**, 141-166.
- Henson, R. A., and Russell, D. (1942). Acute haemorrhagic leucoencephalitis: report of a case. *Journal of Pathology and Bacteriology*, **54**, 227-234.
- Hurst, E. W. (1941). Acute haemorrhagic leucoencephalitis: a previously undefined entity. *Medical Journal of Australia*, **2**, 1-6.
- Kincaid-Smith, P. (1975). Participation of intravascular coagulation in the pathogenesis of glomerular and vascular lesions. *Kidney International*, **7**, 242-253.
- Kirk, R. C., and Ecker, E. E. (1949). Time of appearance of antibodies to brain in human receiving anti-rabies vaccine. *Proceedings of the Society for Experimental Biology and Medicine*, **70**, 734-737.
- Koprowski, H., and Le Bell, I. (1950). The presence of complement-fixing antibodies against brain tissue in sera of persons who have received anti-rabies vaccine treatment. *American Journal of Hygiene*, **51**, 292-299.
- Leibowitz, S., and Kennedy, L. (1972). Cerebral vascular permeability and cellular infiltration in experimental allergic encephalomyelitis. *Immunology*, **22**, 859-869.
- Leichtenstern, O. (1892). Über primäre acute hämorrhagische Encephalitis mit Demonstration. *Deutsche Medizinische Wochenschrift (Stuttgart)*, **18**, 39-40.
- Levine, S., Cochrane, C. G., Carpenter, C. B., and Behan, P. O. (1971). Allergic encephalomyelitis: effect of complement depletion with cobra venom. *Proceedings of the Society for Experimental Biology and Medicine*, **138**, 285-289.
- McCabe, W. R. (1973). Serum complement levels in bacteremia due to Gram-negative organisms. *New England Journal of Medicine*, **288**, 21-23.
- MacDonald, M. K., Clarkson, A. R., and Davison, A. M. (1973). The role of coagulation in renal disease. In *Glomerulonephritis*, pp. 809-828. Edited by P. Kincaid-Smith, T. H. Mathew, and E. L. Becker. Wiley: New York.
- McKay, D. G., and Wahle, G. H. (1955). Epidemic gastroenteritis due to *Escherichia coli* O<sub>11</sub> B<sub>4</sub>. *Archives of Pathology*, **60**, 679-693.
- McKay, D. G., Jewett, J. F., and Reid, D. E. (1959). Endotoxin shock and the generalised Shwartzman reaction in pregnancy. *American Journal of Obstetrics and Gynecology*, **78**, 546-566.
- Marsh, J. M. K. (1952). Streptomycin-PAS. Hypersensitivity treated with ACTH. *Lancet*, **2**, 606-608.
- Masland, W. S., and Barrows, L. J. (1962). A case of generalised Shwartzman phenomenon in the human. *Archives of Neurology (Chicago)*, **7**, 64-73.

- Mergenhausen, S. E., Snyderman, R., Gewurz, H., and Shin, H. S. (1969). Significance of complement to the mechanism of action of endotoxin. In *Current Topics in Microbiology and Immunology*, vol. 50, pp. 37-77. Edited by W. Arber, W. Braun, and F. Cramer. Springer-Verlag: Berlin.
- Moossy, J., Wolf, A., and Cowen, D. (1954). Acute hemorrhagic leuco-encephalitis. Its relationship to the demyelinating diseases. *American Journal of Pathology*, **30**, 642-643.
- Müller-Eberhard, H. J., Nilsson, U. R., Dalmaso, A. P., Polley, M. J., and Calcott, M. A. (1966). A molecular concept of immune cytolysis. *Archives of Pathology*, **82**, 205-217.
- Nelson, R. A. (1961). Immune-adherence. In *Mechanisms of Cell and Tissue Damage Produced by Immune Reactions*. 2nd International Symposium on Immunopathology. Benno Schwabe: Basel.
- Nelson, R. A. (1965). The role of complement in immune phenomena. In *The Inflammatory Process*. Edited by B. W. Zweifach, L. H. Grant, and R. J. McCluskey. Academic Press: New York.
- Oldstone, M. B. A., and Dixon, F. J. (1968). Immunohistochemical study of allergic encephalomyelitis. *American Journal of Pathology*, **52**, 251-263.
- Pabst, H., Day, N. K., Gewurz, H., and Good, R. A. (1971). Prevention of experimental allergic encephalomyelitis with cobra venom factor. *Proceedings of the Society for Experimental Biology and Medicine*, **136**, 555-560.
- Park, B. H., and Good, R. A. (1974). Complement and biologic amplification. In *Principles of Modern Immunobiology*. Lea and Fabinger: Philadelphia.
- Paterson, P. Y. (1966). Experimental allergic encephalomyelitis and autoimmune disease. *Advances in Immunology*, **5**, 131-208.
- Russell, D. S. (1937). Changes in the central nervous system following arsphenamine medication. *Journal of Pathology and Bacteriology*, **45**, 357-366.
- Russell, D. S. (1955). The nosological unity of acute haemorrhagic leucoencephalitis and acute disseminated encephalomyelitis. *Brain*, **78**, 369-376.
- Siqueira, M., and Nelson, R. A. (1961). Platelet agglutination by immune complexes and its possible role in hypersensitivity. *Journal of Immunology*, **86**, 516-525.
- Stetson, C. A. (1964). Role of hypersensitivity in reactions to endotoxin. In *Bacterial Endotoxins*. Edited by M. Landy and M. Braun. Rutgers University Press: New Brunswick, New Jersey.
- Strümpell, A. (1891). Über primäre acute Encephalitis. *Deutsches Archiv für Klinische Medizin*, **47**, 53-74.
- Symmers, W. St. C. (1956). Thrombotic microangiopathy (thrombotic thrombocytopenic purpura) associated with acute haemorrhagic leucoencephalitis and sensitivity to oxophenarsine. *Brain*, **79**, 511-520.
- Ward, P. A., Cochrane, C. G., and Müller-Eberhard, H. J. (1965). The role of serum complement in chemotaxis of leucocytes in vitro. *Journal of Experimental Medicine*, **122**, 327-346.
- Wardle, E. N. (1973). Intravascular coagulation in experimental acute renal failure: assessment by radiofibrinogen techniques. *Thrombosis et Diathesis Haemorrhagica*, **29**, 579-591.
- Wardle, E. N. (1975). Endotoxinaemia and the pathogenesis of acute renal failure. *Quarterly Journal of Medicine (New Series)*, **XLIV**, 389-398.