

Xanthochromic cysts associated with meningioma

H. J. W. NAUTA, W. S. TUCKER, W. J. HORSEY,
J. M. BILBAO, AND C. GONSALVES

*From the Division of Neurosurgery and Departments of Pathology and Radiology,
St Michael's Hospital, Toronto, Ontario, Canada*

SUMMARY Three cases of cystic meningioma encountered in one year are presented. It appears from a review of the literature, and an analysis of these three cases, that large xanthochromic cerebral cysts may be associated with meningiomas in any of three configurations: (1) centrally within the tumour; (2) peripherally within the tumour; (3) in the adjacent brain. Regardless of which configuration applies, the CAT scan appearance of such cystic meningiomas may mimic that of a glial tumour with cystic or necrotic change, and lead to an incorrect presumptive diagnosis. This false impression may be perpetuated by the gross appearance at operation, which can also mimic malignant glioma. Although several radiological features should suggest the possible presence of a cystic meningioma, we know of no definitive radiological means of differentiating this lesion from the more common malignant glioma. This finding should underline the need to biopsy all suspected cerebral neoplasms, regardless of how much their appearance on CAT scan may suggest malignant glioma.

While cysts associated with glial tumours are common, cysts associated with meningioma are generally considered to be uncommon. The older literature contains conflicting reference to cystic meningiomas concerning both their frequency of occurrence and the mechanism and site of cyst formation. In his pioneering account, Penfield (1932) writes of meningiomas in general: "Only in very rare cases is there cyst formation. Degeneration takes place, if at all, in the center; the zone which is most widely removed from the peripheral blood supply."

Cushing and Eisenhardt (1938), however, comment on cyst formation in at least eight cases in their monumental series of 313 meningiomas and state that: "Xanthochromic cysts appear to form at the periphery of many tumours where they sometimes coalesce into fairly large cavities with no evidence of adjacent tumour degeneration. Even small convexity tumours may show this tendency and yet produce marked pressure symptoms, for these cystic meningiomas seem particularly prone to cause oedema of the adjacent cerebral tissue and with a degree of intracranial tension that may be out of proportion to the size of the tumour."

A further comment on the mechanism of cyst formation appears in a later chapter (p. 421): "Why xanthochromic cerebrospinal fluid is not more often trapped in the spaces about a meningioma is unexplainable."

The more recent literature contains little reference to cysts associated with meningioma. Russell and Rubinstein (1977) state that such cysts are rare, and illustrate a case (unique in their experience) of a large cerebellar cyst forming at the periphery of a tentorial meningioma. Blackwood and Corsellis (1976) describe macroscopically visible cysts resulting from "oedema of long duration" in the temporal lobe overlying a middle fossa meningioma, (see their Fig. 3.56, third edition). Zulch's (1971) histological atlas shows an example of small cysts forming as a "regressive process in a meningioma." Lake and co-workers (1973) reported a case of recurrent cystic meningioma in which, at the time of third operation, the cyst appeared to be peripheral but was entirely within a rim of tumour tissue. Henry *et al.* (1974) emphasised how easily these lesions could mimic astrocytoma on gross appearance at operation. Of the three cases they reported, one came to necropsy before the true nature of the lesion was appreciated despite previous biopsy. In this necropsied case, "the cyst wall contained a compact syncytium composed of meningothelial cells."

Address for correspondence and reprint requests: W. S. Tucker, 33 Shuter Street Annex, Toronto, Ontario, M5B 1W8, Canada.

Accepted 28 November 1978

Indirect reference to cysts associated with meningioma can be found in Szilwowski and Cumings' analysis (1961) of fluid obtained from 40 cerebral cysts, two of which proved to be meningioma. They identified no diagnostic features of the fluid allowing differentiation of the meningioma cyst from the more common malignant tumour cyst. The protein concentration of fluid obtained from their two meningiomas (16 and 32 g/l) was within the range found for malignant tumour cysts. SGOT and LDH tended to be lower in meningioma cyst fluid but these changes were not considered diagnostic.

The importance of recognising that xanthochromic cerebral cysts of considerable size can occur in association with meningiomas is illustrated by the three cases reported here. In all cases a CAT scan was carried out early in the diagnostic investigations, and all showed an appearance considered typical of a malignant glial tumour. Also, in all cases the cyst fluid was xanthochromic and considered at operation to be consistent with that of a glial tumour. In only one of the cases (case 3) was the nature of the tumour appreciated during operation on the basis of a quick section report. In the remaining two cases (cases 1 and 2) the initial pathological quick section

report was inconclusive, and it was not until all the tissue obtained at first operation was examined that a diagnosis of meningioma was made. In these two cases, reoperation was necessary to effect a total removal.

Case reports

CASE 1

This 53 year old right handed woman (MC) came to attention because of an eight month history of right frontal headache, especially severe in the three weeks before admission to hospital. Her family stated that she had become increasingly forgetful, and on occasion they noted her speech to be mildly slurred and repetitive. The patient herself denied any symptom other than headache, and specifically denied any visual disturbance. Her general physical examination was unremarkable, and there was no papilloedema. There were no focal neurological findings, and her visual fields were normal. There was no clear evidence of dementia. Her skull radiographs were normal. A CAT scan showed a mass lesion in the left temporal lobe consisting of a large cyst with denser, contrast-enhancing peripheral tissue (Fig. 1a, b). A subsequent angiogram showed a temporal mass

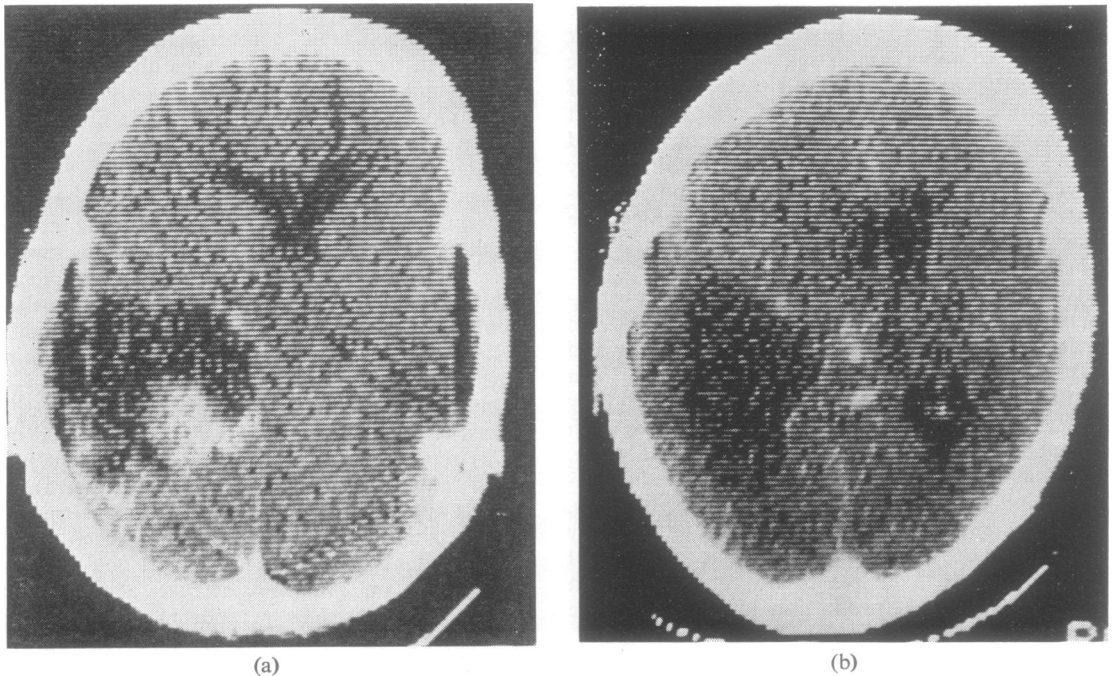


Fig. 1 This contrast-enhanced CAT scan from case 1 (MC) shows a cystic mass in the left temporal lobe with contrast enhancement of the tumour nodule and cyst wall.

supplied by the meningohypophyseal trunk of the left internal carotid artery. Although this finding strongly suggested a diagnosis of meningioma, we nonetheless thought the patient had a cystic glioma on the basis of the CAT scan. On 11 July 1977 she underwent left temporoparietal craniotomy. A brain needle was introduced and, as expected, a cyst was encountered and drained of some 50 ml of greenish-yellow fluid. Through a cortical incision the cyst was entered revealing a grey, firm, rubbery mass of tumour tissue along its inferior aspect. Biopsy of this tissue produced brisk bleeding. Intraoperative quick section report was inconclusive. Because the patient was without neurological deficit and because we strongly suspected a glial tumour, the procedure was limited to a cyst drainage and biopsy. Her postoperative course was uneventful except for a mild dysphasia which cleared rapidly. Subsequent pathology reports based on a complete examination of the tissue fragments obtained at operation demonstrated meningioma (Fig. 2). The patient returned home and was symptom-free for about six months.

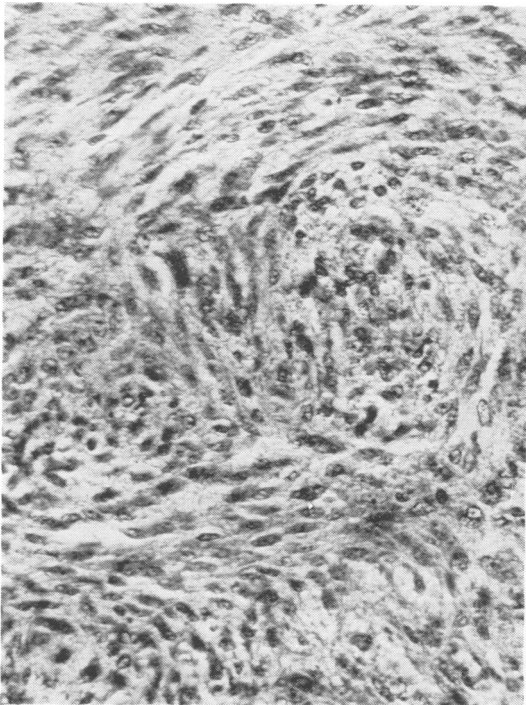


Fig. 2 Histological appearance typical of transitional meningioma from case 1 (MC). H and E stain. Original magnification $\times 400$.

Thereafter her headaches recurred and, after a single seizure, she agreed to undergo reoperation. She was readmitted on 5 May 1978, and again she showed no papilloedema or focal neurological deficits. A CAT scan was repeated and demonstrated recurrence of her cyst and residual solid tumour. The next day she underwent a repeat left temporal craniotomy, and again a large xanthochromic cyst was found and drained. The underlying meningioma was then identified arising from the dura mater over the petrous bone and extending medially across the middle fossa to the incisura. It was totally removed. Postoperatively she awoke with a right homonymous hemianopsia which subsided to a persistent right homonymous upper quadrantanopsia. She was otherwise symptom-free when seen three months later. A follow-up CAT scan (Fig. 3) performed three months after operation showed no evidence of residual tumour or cyst.

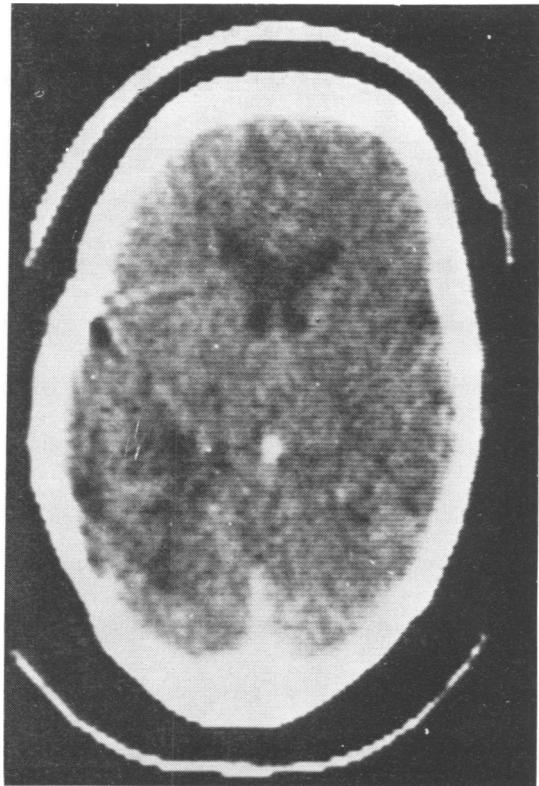


Fig. 3 CAT scan of case 1 (MC) showing absence of tumour and cyst three months after second operation.

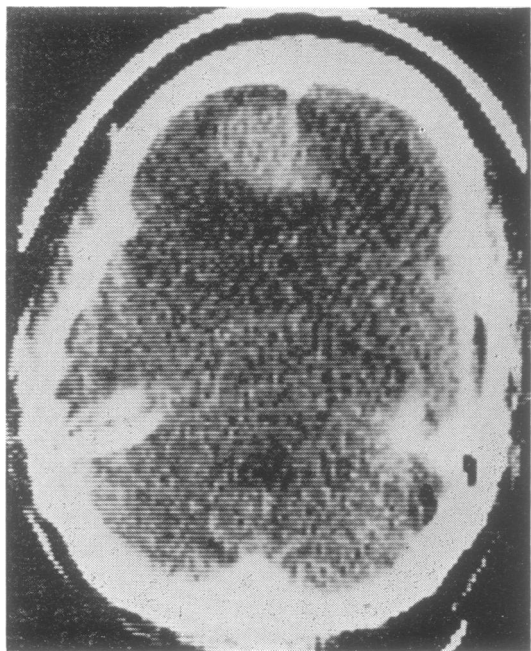
CASE 2

This 50 year old business man (CA) presented with a one year history of episodic dizziness associated with bifrontal headache and stumbling. In the weeks before admission to hospital, the episodes occurred two or three times per day, and lasted an estimated two or three minutes each. His general physical examination was unremarkable. There was bilateral papilloedema, but no focal neurological deficits or pathological reflexes. During his preoperative stay in hospital, he was noted to have, in addition to several of his usual dizzy spells, an apraxia-like episode lasting about a minute during which he was aware of and able to remember the commands of an examiner, but unable to carry them out.

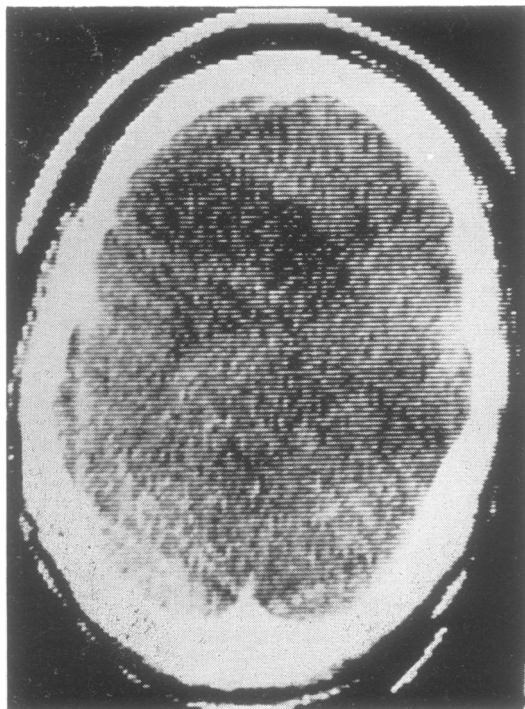
Routine skull radiographs were normal. A CAT scan showed a contrast-enhancing left frontal mass (Fig. 4a, b), crossing the midline. Adjacent to this, a low density area was thought to represent either cyst or marked oedema. Angiography showed the effect of a space-occupying lesion but did not demonstrate a meningeal blood supply to the tumour. The radiographic appearance was considered most compatible with glioma.

On 12 January 1978 a left frontal craniotomy

was performed. A cyst was drained of about 20 ml of xanthochromic fluid, and the dura mater opened over the convexity to reveal apparently tough gliotic or neoplastic cerebral tissue. A cerebrotomy encountered both soft and scarified tissue with intervening cysts. A biopsy and quick section demonstrated reactive gliosis. Believing this to be a glioma with transcallosal spread to the other frontal lobe, the left frontal pole was resected along with some tougher, darker tumour attached to the falx, but no effort was made to seek or remove the small amount of tumour shown by the CAT scan to extend to the right of the falx. Later complete pathological examination of the different resected tissue fragments revealed both syncytial meningioma (Fig. 5) and oedematous cerebral tissue with glial reaction and microcavitation (see Fig. 6). There was no evidence of a glial tumour. The patient's postoperative course was uneventful. His symptoms were relieved, and he was able to conduct his business as before, without neurological deficit. When the nature of his tumour was fully appreciated he was persuaded to return for reoperation.



(a)



(b)

Fig. 4 This contrast-enhanced CAT scan from case 2 (CA) shows a left frontal mass crossing midline (a). A low density zone is evident adjacent to the frontal mass (a and b).

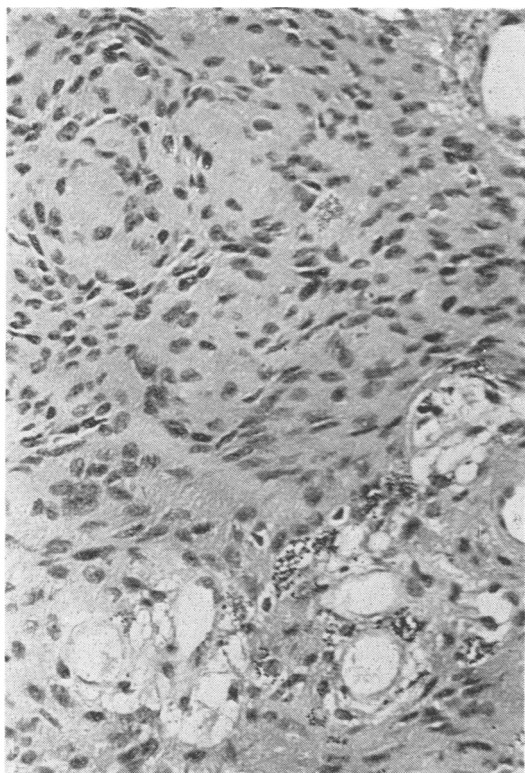


Fig. 5 Histological appearance typical of a syncytial meningioma from case 2 (CA) H and E stain. Original magnification $\times 400$.

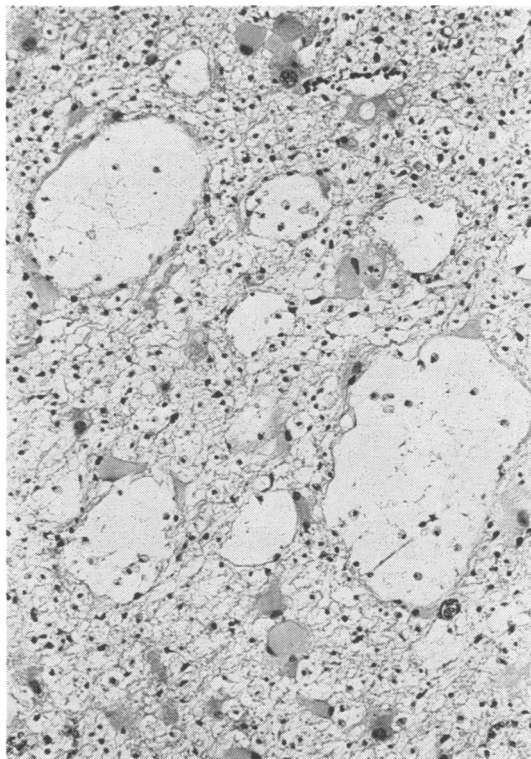


Fig. 6 This photomicrograph shows the appearance of brain tissue adjacent to the large cyst encountered in case 2. Note the oedema, glial reaction, microcavitation, and demyelination. H and E stain. Original magnification $\times 400$.

On readmission his physical examination was entirely normal. A CAT scan showed no residual cyst or tumour. On 6 April 1978 the left frontal craniotomy was reopened. The left hemisphere was retracted laterally allowing complete removal of the small plaque of residual tumour which extended to the right of the falx. Pathological examination confirmed that this residual tumour was meningioma. His postoperative course was uneventful, and there were no residual neurological deficits.

CASE 3

This 53 year old Italian woman sought medical help after she experienced three episodes of "confusion" during a four month period. The episodes lasted between two and three minutes each, and were accompanied by slurred speech and transient numbness in the left arm and face. There were no convulsive movements and no loss of consciousness. She denied headache. Her physical exam-

ination was entirely normal. There was no papilloedema, and there were no neurological deficits or pathological reflexes. Skull radiographs and EEG were unremarkable. A CAT scan was performed and showed a large right parietal mass with a cyst as shown in Fig. 7. An angiogram demonstrated a mass in the right parietal area but no meningeal feeding vessels could be identified.

On 17 August 1978 she underwent right frontoparietal craniotomy. No bony changes were encountered, and the exposed dura mater did not show a vascular pattern, bulge, or palpable firmness to betray the tumour's location. A needle was passed into a cyst and xanthochromic fluid returned. The incised dura mater could be peeled back from the underlying soft, grey tumour mass without bleeding. The tumour was then removed piecemeal, some of it soft enough to come up in the sucker. On quick section it proved, surprisingly, to be a syncytial meningioma. Pathological

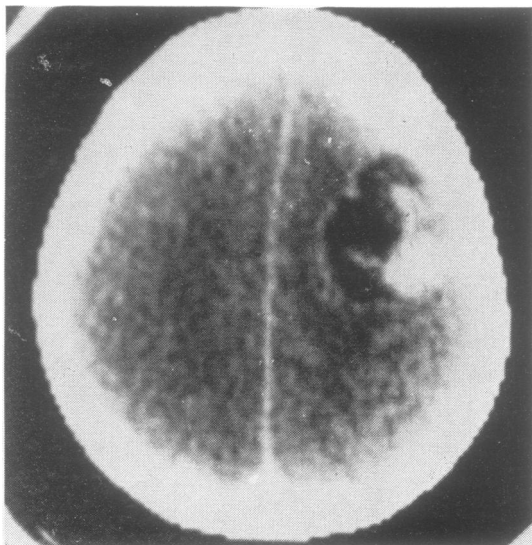


Fig. 7 This contrast-enhanced CAT scan shows a right parietal cyst with a tumour nodule.

examination further showed that the tumour apparently arose from the overlying dura mater (Fig. 8). While removing deeper parts of the tumour, the cyst was entered. Biopsy of the distal cyst wall showed gliosis in cerebral tissue beneath a compact rim of meningioma tissue (Fig. 9). After the operation the patient experienced mild left arm paresis which rapidly subsided.

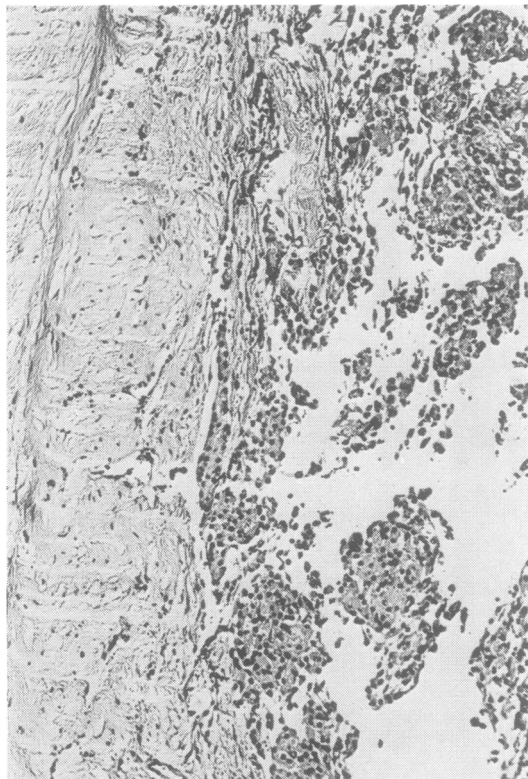


Fig. 8 This photomicrograph shows the dural attachment of the syncytial meningioma encountered in case 3 (MM). H and E stain. Original magnification $\times 250$.

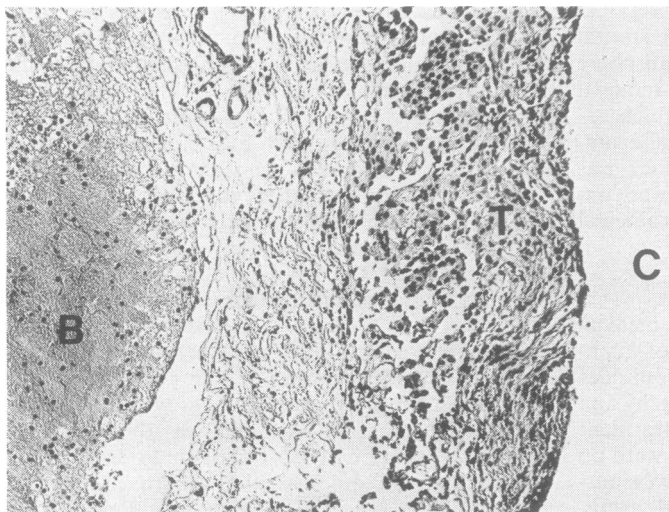


Fig. 9 This photomicrograph shows the cyst wall from case 3 (MM). Note the microscopic rim of tumour tissue (T), adjacent brain (B), and the cyst cavity (C). H and E stain. Original magnification $\times 250$.

Discussion

Two aspects of the cases presented warrant further comment. In the first place, we would like to emphasise again, that although probably uncommon, large cysts containing xanthochromic fluid can occur in association with meningioma. The appearance of these lesions on CAT scan can mimic a malignant glioma with cyst or necrosis and, at present, in the absence of classical angiographic changes, we know of no way to differentiate the two lesions with certainty by radiographic means. This finding should underline the need to biopsy all suspected cerebral neoplasms regardless of how much their appearance on CAT scan may suggest malignant glioma.

Secondly, we would like to clarify some apparent contradictions in the literature concerning the mechanism of cyst formation. Figure 10 illustrates diagrammatically four hypothetical relationships between a tumour, associated cysts, and surrounding brain. In the *type 1* configuration, the cyst is contained wholly within the tumour and, being located centrally, or nearly so, is surrounded by macroscopic tumour throughout. Penfield (1932) refers only to this type of cyst formation, and although Cushing and Eisenhardt (1938) do not mention it specifically in their general comments on cyst formation, they illustrate at least one clear example (see their Fig. 524). In the *type*

2 configuration, the cyst is at the periphery of, but still wholly within the margins of the tumour, there being a microscopically visible attenuated rim of tumour cells along the peripheral margins of the cyst. Our case 3 appears to conform to this configuration (Figs. 8 and 9), as do several reported cases, including the case of Lake *et al.* (1973) and the first of the three cases presented by Henry *et al.* (1974). In the *type 3* configuration the cyst again appears to be peripheral, and indeed actually lies within the adjacent brain rather than within the tumour itself. Cushing and Eisenhardt (1938) alluded to this mechanism of cyst formation and we believe our case 2 is a documented example (Figs. 5 and 6). Russell and Rubinstein's illustrated case also seems to fit this pattern (see their Fig. 34), as does that illustrated by Blackwood and Corsellis (1976, see their Figs 3.56). In the *type 4* configuration, the cyst appears at the interface between the tumour and brain as a loculation of CSF in the subarachnoid space, and does not appear within either the tumour or brain itself. Cushing and Eisenhardt (1938; p. 421) refer to this mechanism in reference to their case 40, although their documentation seems incomplete. We can find no further evidence for this mechanism occurring in association with meningiomas.

It appears that at least three cyst configurations may occur in association with meningioma, and that, therefore, the conflicting unitary views held by some past authors may simply reflect the rarity of the lesion.

References

- Blackwood, W., and Corsellis, J. A. N. (1976). *Greenfield's Neuropathology*. Third edition. Edward Arnold: London.
- Cushing, H., and Eisenhardt, L. (1938). *Meningiomas*. Charles C. Thomas: Springfield, Illinois.
- Henry, J. M., Schwartz, F. T., Sartawi, M. A., and Fox, J. L. (1974). Cystic meningiomas simulating astrocytomas. *Journal of Neurosurgery*, **40**, 647-650.
- Lake, P., Heiden, J. S., and Minkler, J. (1973). Cystic meningiomas. *Journal of Neurosurgery*, **38**, 638-641.
- Penfield, W. (1932). Tumors of the sheaths of the nervous system. In *Penfield's Cytology and Cellular Pathology of the Nervous System*, vol. 3, p. 962. P. B. Hoeber: New York.
- Russell, D. S., and Rubinstein, L. J. (1977). *Pathology of Tumours of the Nervous System*. Fourth edition. Edward Arnold: London.
- Szilwowski, H. B., and Cumings, J. N. (1961). The diagnostic value of the chemical examination of cerebral cyst fluids. *Brain*, **84**, 204-211.
- Zulch, K. L. (1971). *Atlas of the Histology of Brain Tumors*. Springer-Verlag: New York.

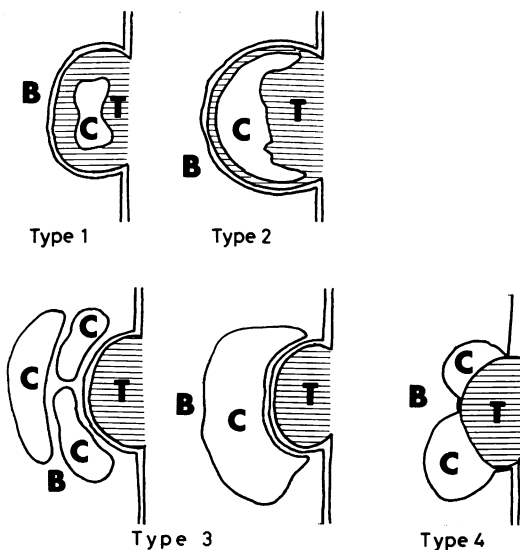


Fig. 10 The four possible configurations of a tumour (T), cyst (C), and brain (B), discussed in the text.