

Case Report

Urrets-Zavalía syndrome after implantable Collamer lens placement

Ahmed Al Habash, MD,^a Khalid Al Arfaj, MD,^a and Omar Al Abdulsalam, MD^b

Author affiliations: ^aDepartment of Ophthalmology, University of Dammam, Dammam, Saudi Arabia;

^bDepartment of Ophthalmology, King Abdulaziz Hospital, Al Ahsa, National Guard Health Affairs, Saudi Arabia

Summary

We describe the case of a healthy 28-year-old woman who underwent implantation of a posterior chamber, phakic, toric, implantable Collamer lens (ICL) in both eyes for correction of bilateral high myopia with astigmatism. On the first postoperative day the patient developed increased intraocular pressure (IOP) and a fixed, mid-dilated pupil in her left eye. The elevated IOP was corrected within 3 days by medical treatment. However, the pupil remained mid-dilated and nonreactive to both light and accommodative effort during 2 months of follow-up; there was no reaction to pilocarpine (0.125% or 4%) eyedrops. The patient was diagnosed with Urrets-Zavalía syndrome (UZS), which has been reported in association with ICL implantation only once previously.

Introduction

Currently, posterior chamber, phakic intraocular lenses (pIOLs) are gaining wide acceptance as an alternative treatment for ametropia of various refractive ranges.¹ Two models of posterior chamber pIOLs are available: the implantable Collamer lens (ICL) and the phakic refractive lens (PRL).² The ICL is the most widely implanted posterior chamber pIOL. The Visian ICL (STAAR Surgical Co, Monrovia, CA) obtained US Federal Food and Drug Administration approval for the correction of moderate to high myopia in 2005.³

In 1963 Urrets-Zavalía described fixed dilated pupil, iris atrophy, and secondary glaucoma after penetrating keratoplasty in patients with keratoconus who received postoperative atropine.⁴ Subsequently, other possible features were added to this syndrome, including anterior subcapsular lens opacities (Glaukomflecken), iris ectropion, and pigment dispersion.⁵ Urrets-Zavalía syndrome (UZS) can also occur as a complication of other ophthalmic procedures, such as cataract surgery, different types of pIOL implantation, trabeculectomy, iridoplasty, goniotomy, in addition to other forms of keratoplasty including deep anterior lamellar keratoplasty (DALK), and Descemet stripping automated endothelial keratoplasty (DSAEK).⁶ UZS has also been reported in associ-

ation with intracameral C₃F₈ injection for acute corneal hydrops, iatrogenic dilation in pigment dispersion syndrome, and as a sequel of toxic anterior segment syndrome (TASS).⁶ To our knowledge, Kummelil et al were the first to report an association between UZS and ICL implantation (Poster P85, American Society of Cataract and Refractive Surgery, May 25–29, 2011, San Diego).

Case Report

A 28-year-old healthy woman underwent implantation of a posterior chamber, phakic, toric implantable Collamer lens (ICL; STAAR Surgical, Nidau, Switzerland) in both eyes for correction of bilateral high myopia with astigmatism. Preoperatively, best-corrected visual acuity was 20/30 in the right eye with a refraction of $-14.50 -3.50 \times 15$ and 20/20 in the left eye with a refraction of $-12.50 -2.75 \times 160$. Slit-lamp examination of the anterior segment was unremarkable. Both pupils were light-reactive and isocoric, with 5 mm diameters under scotopic illumination. Fundus examination showed myopic changes, with no evidence of retinal tear bilaterally. On applanation tonometry, intraocular pressure (IOP) was 14 mm Hg in each eye. The preoperative corneal topography using Pentacam (Oculus Optikgeräte GmbH, Wet-

Published September 30, 2015.

Copyright ©2015. All rights reserved. Reproduction in whole or in part in any form or medium without expressed written permission of the Digital Journal of Ophthalmology is prohibited.

doi:10.5693/djo.02.2014.09.002

Correspondence: Dr. Ahmed Al Habash, Department of ophthalmology, University of Dammam, Dammam, Saudi Arabia, P.O. Box 31010, Khobar 31952, Saudi Arabia (email: ahmedalhabash@gmail.com).

zlar, Germany) revealed bilateral regular astigmatism, with no specific findings identified on the anterior or posterior elevation maps. The central corneal thicknesses were 564 μm in the right eye and 576 μm in the left eye. Anterior chamber depths in right and left eyes were 3.60 mm and 3.40 mm, respectively. Limbus-to-limbus measurements were 11.5 mm in both eyes.

The surgical procedure was performed under topical anesthesia. Thirty minutes before surgery, tropicamide 1% and phenylephrine 2.5% eyedrops were instilled. Five minutes before surgery, povidone iodine 5.0% was applied. After performing two superior and inferior paracentesis incisions, the anterior chamber was filled with sodium hyaluronate 1.0%. A temporal 3.2 mm clear corneal incision was then made to inject the ICL and each foot plate in turn was placed beneath the iris without placing pressure on the crystalline lens. All viscoelastic material was carefully removed. Finally, intracameral acetylcholine 1% was used to achieve miosis, and peripheral iridectomy was performed.

One week after an uneventful postoperative course in the right eye, the left eye was operated. Postoperatively, the patient received topical moxifloxacin 0.5% and prednisolone acetate 1% eyedrops 4 times daily. On the first postoperative day, the patient developed increased IOP (52 mm Hg) and a fixed, mid-dilated pupil in the left eye. The uncorrected visual acuity was 20/100. Slit-lamp examination revealed corneal epithelial edema, with moderate anterior chamber reaction (3+ cell) but with no fibrin. The peripheral iridectomy was patent, with no pupillary block observed. Fundus examination did not reveal any significant pathology. The patient was treated with antiglaucoma medications (topical timolol 0.5%, latanoprost 0.01%, brimonidine 0.15%, and oral acetazolamide).

On the third day of treatment, the IOP was controlled. However, the left pupil was found to be mid-dilated (Figure 1), with no direct or consensual response to light and no constriction to accommodation. There was also no reaction to pilocarpine (0.125% or 4%) eyedrops. The right pupil was normal.

Two weeks postoperatively, the uncorrected visual acuity in the left eye improved to 20/30, and the IOP was 16 mm Hg. The corneal edema resolved. The ICL was well positioned, with a visible space that existed between the crystalline lens and the ICL. Pigment deposits were observed on the ICL surface (Figure 2). Anterior-segment optical coherence tomography (AS-OCT) of the left eye showed well-positioned ICL with

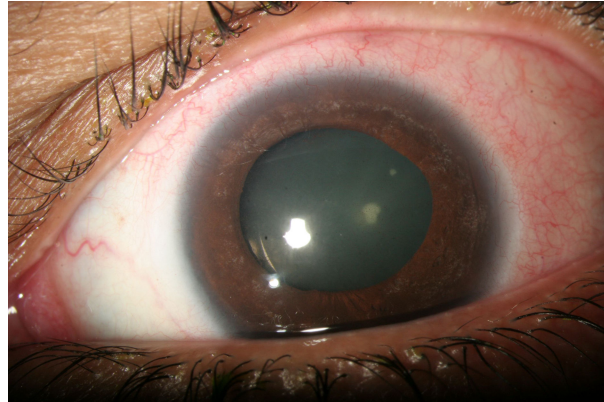

Figure 1. Anterior segment photo of the left eye showing a mid-dilated pupil (after management of the elevated intraocular pressure).

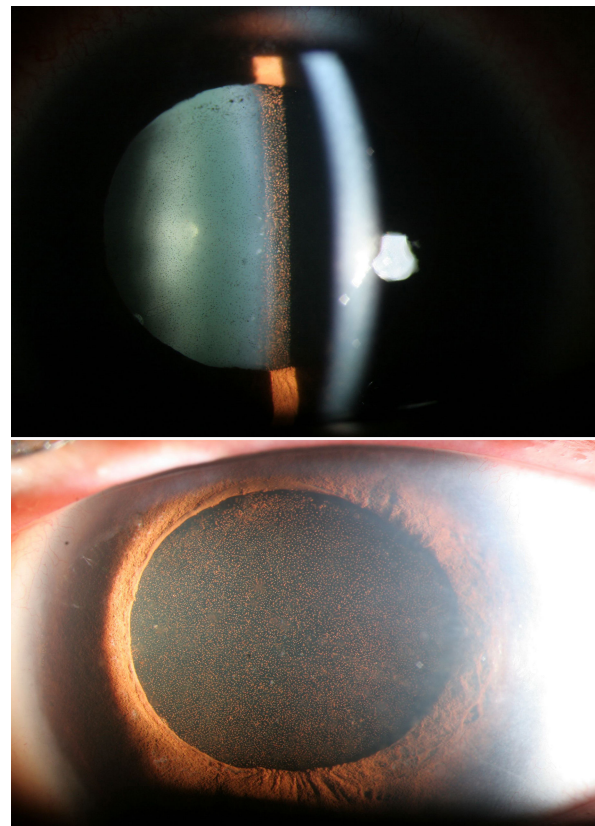


Figure 2. Anterior segment photographs of the left eye showing the mid-dilated pupil with pigment deposits on the surface of the implantable Collamer lens (ICL), after management of the elevated IOP.

normal vault (Figure 3). The patient developed visual discomfort and bothersome glare at night following sur-

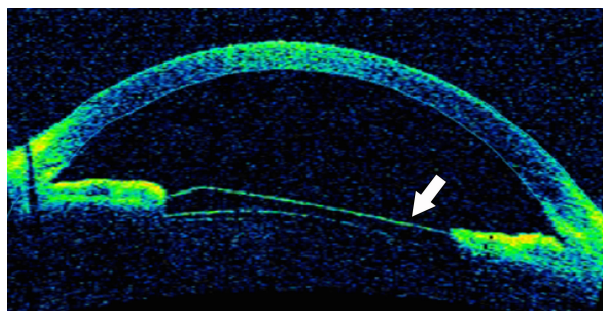


Figure 3. Anterior segment optical coherence tomograph showing a well-positioned ICL with normal vault. The arrow indicates the anterior surface of the ICL.

gery. Her left pupil remained fixed and mid-dilated throughout 2 months of postoperative follow-up, with no response to pilocarpine.

Discussion

The major postoperative complications of ICL implantation include anterior subcapsular cataract, increased IOP, pupillary block, endothelial cell loss, and retinal detachment.⁷

The mechanism of UZS is not fully understood. The most widely accepted theories are ischemia of the iris, acute rise in IOP, and presence of iris abnormalities, which may be more common in keratoconus.⁷ The instillation of strong mydriatics and the intraoperative contact between the iris and peripheral cornea are other presumed triggers.⁷ Ischemic iris atrophy is the leading explanation for the development of UZS.⁷ Possible causes for iris ischemia include acute postoperative increase in IOP^{6,8} and viscoelastic material left in the anterior chamber angle.⁹ However, UZS was usually reported in patients with normal IOP,^{10,11,4} and none of the cases in Urrets-Zavalía's original article had elevated IOP.

Iris atrophy in UZS is either multifocal or sectorial. The degree of ischemia and iris atrophy determines the extent to which the pupil dilates and whether dilatation is transient or permanent.^{12,13} Three types of pupillary dilatation were identified in patients with UZS: (1) reactive pupil with anisocoria, at least 1.5 mm larger than the fellow eye; (2) an unreactive pupil that returns slowly to its normal state; and (3) irreversible pupil dilatation with iris atrophy.¹⁴

Biochemical changes in iris innervation have also been suggested as a cause for UZS,^{15,16} including injury to parasympathetic nerve fibers causing denervation of the

constrictor muscles¹⁷ and sympathetic spasm of the iris dilator muscles.¹⁸

Although UZS has been reported classically in the setting of penetrating keratoplasty, several cases have been reported after the implantation of different types of anterior chamber pIOL.^{19–21} Yuzbasioglu et al reported a case of fixed, dilated pupil associated with elevated IOP after implantation of angle supported anterior chamber pIOL.¹⁹ Park et al reported UZS (without elevated IOP) after iris-claw anterior chamber pIOL implantation²⁰; Plainer et al reported UZS (with elevated IOP) after I-CARE (Corneal, France) anterior chamber pIOL implantation.²¹

UZS has also been reported twice in association with posterior chamber pIOL implantation.²² The first case involved implantation of ICL (as in the current report); the second, implantation of a PRL. The surgery was uneventful in both cases, and UZS was attributed to a rise in IOP (without iris atrophy) during the immediate postoperative period secondary to viscoelastic retention.

Theoretically, posterior chamber pIOLs, which are designed to be placed at the ciliary sulcus (ICL)⁷ or rest in the zonules (PRL),² are less likely to be complicated with UZS. This is in contrast to anterior chamber pIOLs, which have a direct contact to the iris and angle structures.

Topical mydriatic drops (tropicamide 1% and phenylephrine 2.5%) were administered preoperatively to our patient. The role of these agents in UZS is controversial. They were originally thought to play a major role in the development of the condition; however, several reports questioned this association, claiming that mydriatics play no role in the pathogenesis of UZS.^{23,24} Some authors encourage the use of postoperative strong mydriatics because they may protect against this complication.^{25,26}

The implantation surgery in our patient was performed under topical anesthesia and was uneventful. The patient had a similar presentation of elevated IOP and a fixed, mid-dilated pupil in the left eye during the first postoperative day. There was a moderate anterior chamber reaction (not suggestive of TASS), which has been reported to be associated with UZS in some cases.¹¹ The most probable explanation for the increase in IOP is the retained viscoelastic material in the anterior chamber angle. The IOP was medically controlled within 3 days. However, the pupil remained fixed and mid-dilated. No focal or sectorial iris atrophy were observed. There was no evidence of keratoconus under slit-lamp and topo-

graphic examinations, with no postoperative use of mydriatic drops. Adie's tonic pupil was ruled out, because there was no constriction to accommodation or 0.125% pilocarpine instillation. Our case report emphasizes the possibility of a fixed, mydriatic pupil associated with IOP rise as a potential complication after the implantation of this modality of posterior chamber pIOL.

References

- Sanders DR, Doney K, POCO M. United States Food and Drug Administration clinical trial of the implantable Collamer lens (ICL) for moderate to high myopia: three-year follow-up. *Ophthalmology* 2004;111:1683-92.
- Pérez-Cambrodí RJ, Piñero DP, Ferrer-Blasco T. The posterior chamber phakic refractive lens (PRL): a review. *Eye (Lond)* 2013;27:14-21.
- The Implantable Contact Lens in Treatment of Myopia (ITM) Study Group. U.S. Food and Drug Administration clinical trial of the Implantable Contact Lens for moderate to high myopia. *Ophthalmology* 2003;110:255-66.
- Urrets Zavalía A. Fixed, dilated pupil, iris atrophy and secondary glaucoma. *Am J Ophthalmol* 1963;56:257-65.
- Tuft SJ, Buckley RJ. Iris ischaemia following penetrating keratoplasty for keratoconus (Urrets-Zavalía syndrome). *Cornea* 1995;14:618-22.
- Spierer O, Lazar M. Urrets-Zavalía syndrome (fixed and dilated pupil following penetrating keratoplasty for keratoconus) and its variants. *Surv Ophthalmol* 2014;59:304-10.
- Fernandes P, González-Méijome JM, Madrid-Costa D, Ferrer-Blasco T, Jorge J, Montés-Micó R. Implantable Collamer posterior chamber intraocular lenses: a review of potential complications. *J Refract Surg* 2011;27:765-76.
- Walton DS. Urrets-Zavalía syndrome following goniotomy in a child. *J AAPOS* 2013;17:114-5.
- Bourcier T, Laplace O, Touzeau O, et al. Urrets-Zavalía syndrome. *J Fr Ophtalmol* 2001;24:303-8.
- Alberth B, Schnitzler A. Irreversible mydriasis following keratoplasty for keratoconus. *Klin Monbl Augenheilkd* 1971;159:330-5.
- Nizamani NB, Bhutto IA, Talpur KI. Cluster of Urrets-Zavalía syndrome: a sequel of toxic anterior segment syndrome. *Br J Ophthalmol* 2013;97:976-9.
- Davies PD, Ruben M. The parietic pupil: its incidence and aetiology after keratoplasty for keratoconus. *Br J Ophthalmol* 1975;59:223-8.
- Gasset AR. Fixed dilated pupil following penetrating keratoplasty in keratoconus (Castroviejo syndrome). *Ann Ophthalmol* 1977;9:623-6.
- Minasian, Meg; Ayliffe, William. Fixed dilated pupil following deep lamellar keratoplasty (Urrets-Zavalía syndrome). *Br J Ophthalmol* 2002;86:115-6.
- Bonnet M, Lemarchands H, Martin J. Prevention and treatment of the "irreducible mydriasis-progressive atrophy of the iris" syndrome following perforating keratoplasty for keratoconus. *Ann Ocul (Paris)* 1969;202:1139-46.
- Ohmi G, Kinoshita S, Matsuda M, Maeda N. Insufficient accommodation in patient with keratoconus. *Nihon Ganka Gakkai Zasshi* 1990;94:186-9.
- Espana EM, Ioannidis A, Tello C, Liebmann JM, Foster P, Ritch R. Urrets-Zavalía syndrome as a complication of argon laser peripheral iridoplasty. *Br J Ophthalmol* 2007;91:427-9.
- Lagoutte F, Thienpont P, Comte P. Proposed treatment of the Urrets-Zavalía syndrome: a propos of one reversible case. *J Fr Ophtalmol* 1983;6:291-4.
- Yuzbasioglu E, Helvacioğlu F, Sencan S. Fixed, dilated pupil after phakic intraocular lens implantation. *J Cataract Refract Surg* 2006;32:174-6.
- Park SH, Kim SY, Kim HI, Yang SW. Urrets-Zavalía syndrome following iris-claw phakic intraocular lens implantation. *J Refract Surg* 2008;24:959-61.
- Plainer S, Wenzl E, Saalabian AA, et al. Long-term follow-up with I-CARE phakic IOLs. *Br J Ophthalmol* 2011;95:710-4.
- Pérez-Cambrodí RJ, Piñero-Llorens DP, Ruiz-Fortes JP, Blanes-Mompó FJ, Cerviño-Expósito A. Fixed mydriatic pupil associated with an intraocular pressure rise as a complication of the implant of a phakic refractive lens (PRL). *Semin Ophthalmol* 2014;29:205-9.
- Geyer O, Rothkoff L, Lazar M. Atropine in keratoplasty for keratoconus. *Cornea* 1991;10:372-3.
- Bertelsen T, Seim V. Irreversible mydriasis following keratoplasty in keratoconus [proceedings]. *Acta Ophthalmol* 1975;125(Suppl 1):45-6.
- Naumann GO. Iris ischaemia following penetrating keratoplasty for keratoconus (Urrets-Zavalía syndrome). *Cornea* 1997;16:120.
- Tucker DN, Barraquer FJ, Barraquer JI. Penetrating keratoplasty without peripheral iridectomy. *Ann Ophthalmol* 1972;4:338-42.