

REVIEW

# Darwin's Tubercle: Review of a Unique Congenital Anomaly

Tiffany Y. Loh  · Philip R. Cohen

Received: February 24, 2016 / Published online: April 7, 2016  
© The Author(s) 2016. This article is published with open access at Springerlink.com

## ABSTRACT

**Background:** “Darwin's tubercle” is a term used to describe an atavistic swelling of the posterior helix that is present in some individuals. Little is known about its prevalence, characteristics, and function. With growing interest in the individuality of external ear patterns and its possible applications to personal identification, more knowledge about this tubercle is warranted.

**Purpose:** We review the history, clinical presentation, and modern-day influences of Darwin's tubercle.

**Method:** A comprehensive review of the literature was performed. Pubmed was searched with the key words: auricle, congenital, Darwin, ear, evolution, helix, pinna, tubercle, Woolnerian.

**Enhanced content** To view enhanced content for this article go to [www.medengine.com/Redeem/F984F06057D5D352](http://www.medengine.com/Redeem/F984F06057D5D352).

T. Y. Loh  
School of Medicine, University of California San Diego, La Jolla, CA, USA  
e-mail: [tiffany.yv.loh@gmail.com](mailto:tiffany.yv.loh@gmail.com)

P. R. Cohen (✉)  
Department of Dermatology, University of California San Diego, La Jolla, CA, USA  
e-mail: [mitehead@gmail.com](mailto:mitehead@gmail.com)

**Result:** Darwin's tubercle has been documented to be present in about 10.5% of the Spanish adult population, 40% of Indian adults, and 58% of Swedish school children. It has a variety of clinical presentations, which may be classified by its degree of protuberance. The influence of genetics on the expression of Darwin's tubercle is unclear, and there are conflicting observations about its correlations with age and gender. Although usually present bilaterally in individuals who do possess this trait, a portion of this population does display asymmetric expression.

**Conclusion:** Darwin's tubercle is a benign and unique helical feature. It contributes to the individuality of human ears and may have applications toward personal identification in the future.

**Keywords:** Auricle; Congenital; Darwin; Ear; Evolution; Helix; Pinna; Tubercle; Woolnerian

## INTRODUCTION

“Darwin's tubercle” refers to a unique congenital prominence that may be found on the posterior helix of the ear [1, 2]. Composed

predominantly of cartilage with an overlying layer of skin, it is a feature that is thought to be a remnant from the evolutionary past, but its function is unclear. In recent years, studies of patterns of the external ear have suggested that their various morphological features may be distinctive to each individual [3–5]. Some have even proposed that ears may be used for personal identification in the future, with possible applications to forensic science and courts of law [3]. Thus, Darwin's tubercle, once thought to be merely an atavistic feature, which is a characteristic typical of an ancestral form, may prove to be useful in this regard. Here, we review the history, epidemiology, and clinical presentation of Darwin's tubercle.

## HISTORY

Although its discovery is often attributed to the evolutionary theorist Charles Darwin, hence giving rise to the moniker "Darwin's tubercle," the posterior prominence of the auricular helix was actually first described by English sculptor and poet Thomas Woolner, who theorized that it was an atavistic feature [1]. Woolner's sculpture of a figure "Puck" depicted a creature with pointed ears and drew the attention of Darwin. In a letter in 1869 from Darwin to Woolner, the former thanked the sculptor for sending him a drawing of the figure and referred to the prominence on the helix as the "Woolnerian tip" [1].

Darwin later developed a theory on the origins of the "Woolnerian tip," writing that [1]

The helix obviously consists of the extreme margin of the ear folded inwards; and this folding appears to be in some manner connected with the whole external ear being permanently pressed backward. In many monkeys, which do not stand high

in the order, as baboons and some species of macaca, the upper portion of the ear is slightly pointed, and the margin is not at all folded inwards; but if the margin were to be thus folded, a slight point would necessarily project inwards towards the centre; and this I believe to be their origin.

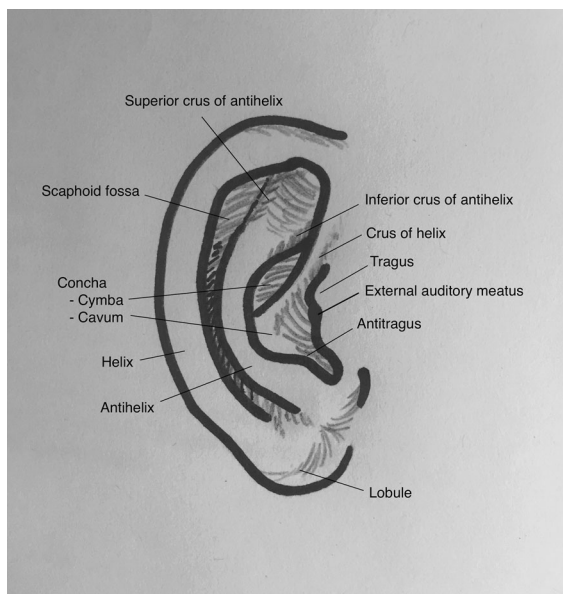
Darwin described the auricular prominence in *The Descent of Man* as a characteristic that indicated that primates shared common ancestry. From then on, it has been known colloquially as "Darwin's tubercle."

## EXTERNAL EAR EMBRYOGENESIS AND ANATOMY

The external ear consists of the auricle (or pinna) and external acoustic meatus, ending at the tympanic membrane, and it serves to collect and amplify sound, which is then transmitted to the middle and inner ear [6–9].

The auricle consists of elastic fibrocartilage covered by a thin layer of skin. Its main features include an outer ridge (helix), inner ridge (antihelix), a lobe that consists of fatty tissue, the tragus, and antitragus (Fig. 1). Notable spaces of the auricle are the concha, scaphoid fossa, triangular fossa, and intertragal notch. As a whole, the auricle is attached to the skull by three extrinsic muscles, the superior, anterior, and posterior auricular muscles, as well as by the cartilage of the concha bowl, which is continuous with the cartilage of the external auditory meatus [6].

The external auditory meatus consists of an outer cartilaginous portion and an inner osseous portion. The junction between the two is called the osseo-cartilaginous junction, which occurs at about one-third to one-half the way along the canal from the opening of the external auditory meatus. The cartilaginous



**Fig. 1** Diagram of the external ear

section is an extension from the cartilage of the concha, and the bony part develops from the tympanic and squamous portions of the temporal bone. The canal traverses a serpiginous course, travelling anteriorly, posteriorly, and anteriorly again until it reaches the tympanic membrane [6].

The human external ear is derived from the embryonic pharyngeal arch [8]. At the end of the fourth week of gestation, four pairs of pharyngeal arches are developed in the neck region of the embryo. During the fifth week, six nodular swellings known as the hillocks of His appear on the first two arches, termed the mandibular and hyoid arches, and they eventually fuse to form the auricle. Shortly after the appearance of the hillocks, the dorsal portion of the first pharyngeal cleft forms a depression, which eventually develops into the external auditory canal. During the eighth week, the developing external canal deepens toward the middle ear space, and the ectodermal lining of this deep portion proliferates to form the meatal plate, the

innermost portion of which eventually becomes the outer layer of the tympanic membrane.

Although the exact development of Darwin's tubercle during the process of the ear's embryogenesis is unknown, it is thought to form as a result of unequal turning in of the helix in the fetus [10].

## EPIDEMIOLOGY AND INHERITANCE

Darwin's tubercle has been studied in various populations and has been estimated to be present in about 10.5% of the Spanish adult population [11], 40% of Indian adults [12], and 58% of Swedish school children [13]. Inheritance of this trait was once thought to follow an autosomal dominant pattern, but some studies have called this theory into question [2, 14, 15].

Quelprud et al. [14] studied the presence of Darwin's tubercle in German families and found that, in 52 families in which neither parent possessed the auricular prominence, 45% ( $n = 22$ ) of the children possessed the tubercle. In addition, Beckman et al. [15] performed a similar study, in which he found that 24% ( $n = 14$  of 58) of individuals whose parents did not possess Darwin's tubercle, had the atavistic prominence. The results of these two studies are inconsistent with an autosomal dominant pattern of inheritance.

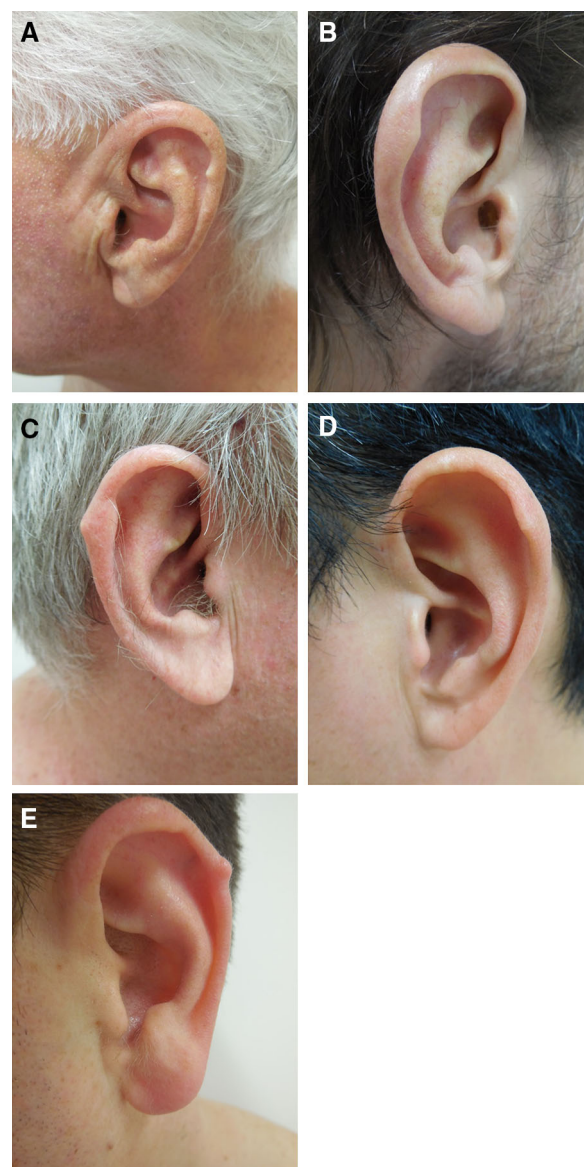
However, despite attempts to characterize the inheritance pattern of Darwin's tubercle, it remains unclear what genetic influences, if any, control the expression of this trait. Quelprud performed additional studies on identical twins and found 58 pairs in which both individuals had Darwin's tubercle and 32 pairs in which neither individual possessed it [14]. He also found 26 pairs of twins in which one individual

possessed the trait and the other did not. In addition, although some studies have found no differences in the prevalence of Darwin's tubercle with sex or age, [16, 17], others have observed associations with both. For example, Vollmer et al. [18] found that greater degrees of expression were associated with older males. Thus, the extent of genetic and environmental influences on the expression of Darwin's tubercle remains unclear.

### Clinical Presentation

Darwin's tubercle is most commonly described as a swelling on the posterior superior portion of the helix [24]. However, variations may occur in the location and degree of prominence (Fig. 2), and various classifications of Darwin's tubercle have been proposed; informed consent was obtained from the patients for being included in this review. Bertillon [19] was the first to suggest categorization of the tubercle into four groups: nodosity, enlargement, projection, and tubercle. Subsequently, Gurbuz [17] proposed five categories (undeveloped, semi-developed, fully developed, very significant, and multiple), and Singh and Purkait et al. [12] characterized three (nodosity, enlargement, and projection). To date, no consensus has been established regarding the classifications of Darwin's tubercle.

Additionally, Darwin's tubercle may be present on both ears or just on one ear. Dharap and Than [20] observed in a study of 1435 Malaysian subjects that, of 498 individuals who possessed Darwin's tubercle, 50% ( $n = 249$ ) had the prominence present on both ears, 26.5% ( $n = 132$ ) only on the right ear, and 23.5% ( $n = 117$ ) only on the left ear. Studies from Singh et al. [21] revealed similar findings, portions of the study population displaying the



**Fig. 2** a–e Men with Darwin's tubercle

trait asymmetrically, although the majority of individuals with Darwin's tubercle did possess the trait on both ears.

Of note, various studies on patterns of the external ears have documented the individuality of ears, observing that even the right and left ears of the same individual are not identical [3]. Thus, the asymmetric presentation of Darwin's tubercle may further contribute to the uniqueness of human ears.



Darwin's tubercle has also been linked to a number of associated conditions, such as congenital absence of the helix, accessory tragus, and weathering nodules [22] (Fig. 3). Although Darwin's tubercle and its associated conditions appear to be benign with no significant clinical sequelae, surgical treatment may be an option in order to address cosmetic concerns [7]. This may be accomplished through full-thickness excision of the skin and the prominent cartilage underneath [25, 26].

### Animal Analogues of Darwin's Tubercle

As an atavistic feature linking humans and primates to a common ancestor, an exploration of the presence of this feature in the animal kingdom is warranted. Among primates, two genera of the Cercopithecidae, the *Macaca* and *Papio*, have been found to have a pointed upper margin of the ear, similar to Darwin's tubercle in humans [23]. Interestingly, although pointed ears are found in many lower mammals, no other anthropoids except for the *Macaca* and *Papio* have a pointed stage during the development of their ears [23]. It is unclear

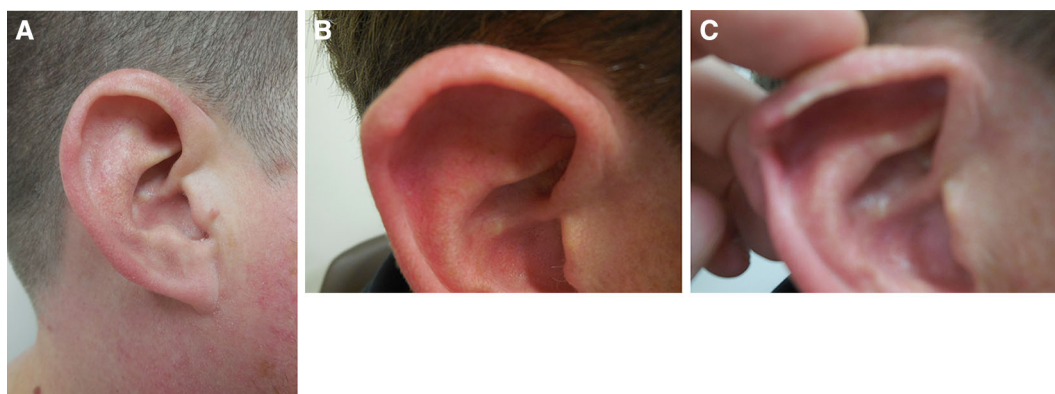
whether the presence of a pointed ear provides any functional advantage in these primates, or whether, like in humans, they are merely a vestigial remnant of the past.

### INFLUENCE OF DARWIN'S TUBERCLE OUTSIDE OF MEDICINE

Although Darwin's tubercle is generally regarded as an atavistic feature that does not require medical treatment, this characteristic has reached beyond medicine to influence a variety of fields.

Regarding forensic science, Darwin's tubercle may be considered as a feature that contributes to the uniqueness of the human ear. Many studies have suggested the possible use of the distinctiveness of each individual's ear in personal identification [3–5]. Some have even suggested that if enough variability exists, ear prints may be used in courts of law in the future [3]. Darwin's tubercle, with its various presentations, undoubtedly contributes to the uniqueness of each human ear, and may be helpful in such applications.

In modern cinema, deformities similar to Darwin's tubercle have been featured in a



**Fig. 3** Darwin's tubercle and associated conditions: accessory tragus (a) and weathering nodules (b, c). When pressure is applied to the helix, the weathering nodules blanch (c)

variety of notable characters. For example, the pointed “Spock ears” of the Vulcans from *Star Trek* may have been inspired by Stahl’s ear, which is a deformity in which the outer rim of the ear is flattened and an extra fold in the cartilage extends through the helical rim to give the ear a prominent shape [23]. Depictions of elves, in the *Lord of the Rings* trilogy may have also drawn inspiration from similar congenital ear abnormalities.

The presence of Darwin’s tubercle has also historically been associated with criminal tendencies in studies of criminology and modern human evolution [27–29]. However, some authors have also found no apparent association between Darwin’s tubercle and thievery [30]. Whether the two are related remains to be determined.

## CONCLUSION

Darwin’s tubercle is a vestigial characteristic that was first documented by Thomas Woolner in the 1800s and brought to the public attention by Charles Darwin. The roles of environmental and genetic factors in its development remain unclear, and it is a benign lesion that does not appear to have significant clinical sequelae. Nevertheless, with its wide variety of presentations and the recent attention on the possible use of ears in personal identification, Darwin’s tubercle may prove to have useful applications in the future.

## ACKNOWLEDGMENTS

No funding or sponsorship was received for this study or publication of this article. All named authors meet the International Committee of Medical Journal Editors (ICMJE) criteria for

authorship for this manuscript, take responsibility for the integrity of the work as a whole, and have final approval for the version to be published.

**Disclosures.** Tiffany Y. Loh and Philip R. Cohen have nothing to disclose. They do not have any personal, financial, commercial, or academic conflicts of interest.

**Compliance with Ethics Guidelines.** Informed consent was obtained from the patients for being included in the study.

**Open Access.** This article is distributed under the terms of the Creative Commons Attribution-NonCommercial 4.0 International License (<http://creativecommons.org/licenses/by-nc/4.0/>), which permits any noncommercial use, distribution, and reproduction in any medium, provided you give appropriate credit to the original author(s) and the source, provide a link to the Creative Commons license, and indicate if changes were made.

## REFERENCES

1. Millard DR, Pickard RE. Darwin’s tubercle belongs to Woolner. *Arch Otolaryng.* 1970;91:334–5 (PMID: 4909009).
2. McDonald JH. *Myths of human genetics.* Baltimore: Sparky House; 2011.
3. Purkait R, Priyanka S. A test of individuality of human external ear pattern: its application in the field of personal identification. *Forensi Sci Int.* 2008;178:112–8 (PMID: 18423922)
4. Chattopadhyay PK, Bhatia S. Morphological examination of ear: a study of an Indian population. *Leg Med (Tokyo)* 2009;Suppl 1:S190–193. (PMID: 19409832).
5. Sforza C, Grandi G, Binelli M, Tommasi DG, Rosati T, Ferrario VF. Age- and sex-related changes in the normal human ear. *Forensic Sci Int.* 2009;187:e1–7 (PMID: 19356871)

6. Alvord LS, Farmer BL. Anatomy and orientation of the human ear. *J Am Acad Audiol*. 1997;8:383–90 (PMID: 9433684)
7. Tolleth H. Artistic anatomy, dimensions, and proportions of the external ear. *Clin Plast Surg*. 1978;5:337–45 (PMID: 699488)
8. Wright CG. Development of the human external ear. *J Am Acad Audiol*. 1997;8:379–82 (PMID: 9433683)
9. Salasche SJ, Bernstein G, Senkarik M. Ear. In: *Surgical anatomy of the skin*. Norwalk: Appleton & Lange; 1988. p. 218–222.
10. Tulane University, Department of Anatomy. *Contributions by Members of the Department of Anatomy, Volume 1*. The Department, 2015.
11. Ruiz A. An anthropometric study of the ear in an adult population. *Int J Anthropol*. 1986;1(135):135–243 (PMID not available).
12. Singh P and Purkait R. Observations of external ear—an Indian study. *Homo* 2009;461–472 (PMID: 19748090).
13. Hildén K. Studien über das Vorkommen der darwischen Ohrspitze in der Bevölkerung Finnlands. *Fennia*. 1929;52:3–39 (PMID not available).
14. Quelprud T. Zur erblichkeit des darwischen höckerchens. *Z Morphol Anthropol*. 1936;34:343–63 (PMID not available).
15. Beckman L, Böök JA, Lander E. An evaluation of some anthropological traits used in paternity tests. *Hereditas*. 1960;46:543–69 (PMID not available).
16. Rubio O, Galera V, Alonso MC. Anthropological study of ear tubercles in a Spanish sample. *Homo*. 2015;66:343–56 (PMID: 25916201)
17. Gurbuz H, Karaman F, Mesut R. The variations of auricular tubercle in Turkish people. *Acta Morphol Anthropol*. 2005;10:150–6 (PMID not available).
18. Vollmer H. The shape of the ear in relation to body constitution. *Arch Pediatr*. 1937;54:574–90 (PMID not available).
19. Bertillon A. *identification Anthropométric: instructions signalétiques*. Melun: Imprimerie administrative; 1893.
20. Dharap AS, Than M. Five anthroposcopic traits of the ear in a Malaysian population. *Anthropol Anzeiger*. 1995;53:359–63 (PMID: 8579342)
21. Singh L, Goel KV, Mahendru P. Hypertrichosis pinnae auris, Darwin's tubercle and palmaris longus among Khatri and Baniyas of Patiala, India. *Acta Genet Med Gemellol (Roma)*. 1977;26:183–4.
22. Lykoudis EG, Seretis K, Spyropoulou GA. A 6-year experience in flat helix correction with a simple procedure. *Arch Facial Plast Surg*. 2011;13:168–72 (PMID: 21576663)
23. Ankel-Simons F. *Primate anatomy: an introduction*. San Diego: Elsevier; 2007.
24. Bean RB. Some characteristics of the external ear of American Whites, American Indians, American Negroes, Alaskan Eskimos, and Filipinos. *Am J Anat*. 1915;18:201–25.
25. Jones AP, Janis JE. *Essentials of plastic surgery: Q&A companion*. St. Louis: CRC; 2015.
26. Naumann A. Otoplasty—techniques, characteristics and risks. *GMS Curr Top Otorhinolaryngol Head Neck Surg* 2007;6:Doc04 (PMID: 22073080).
27. Homes SJ. The heritable basis in crime and delinquency. In: *The trend of the race*. New York: Harcourt, Brace and Company, Inc; 1921. p. 73–97.
28. Lombroso G. Examination of criminals. In: *Criminal man*. Youcanprint Selfpublishing; 2016.
29. Bowers PE. Criminal anthropology. *J Crim Law Criminol*. 1914;5:357–63 (PMID not available)
30. Lombroso C, Ferrero G. Facial and cephalic anomalies of female criminals. In: *The female offender*. New York: D. Appleton; 1895. p. 76–81.