

Association between the expression levels of tumor necrosis factor- α -induced protein 8 and the prognosis of patients with gastric adenocarcinoma

LING CHEN^{1,2}, XIGUI YANG², XIANGSHAN YANG³, KAIXI FAN²,
PING XIAO², JING ZHANG³ and XIUWEN WANG¹

¹Department of Medical Oncology, Cancer Center, Qilu Hospital, Shandong University, Jinan, Shandong 250012; Departments of ²Internal Medicine-Oncology and ³Pathology, Affiliated Hospital of Shandong Academy of Medical Sciences, Jinan, Shandong 250031, P.R. China

Received January 26, 2015; Accepted March 17, 2016

DOI: 10.3892/etm.2016.3327

Abstract. The present study aimed to investigate the expression levels of tumor necrosis factor- α -induced protein 8 (TNFAIP8) in gastric adenocarcinoma. TNFAIP8 expression levels in gastric adenocarcinoma tissue samples (with and without lymph node metastasis), adjacent normal tissue samples and metastatic lymph node tissue samples were detected by immunohistochemistry. The correlation between TNFAIP8 expression levels and clinicopathological data and gastric adenocarcinoma prognosis was analyzed. The results demonstrated that TNFAIP8 expression in gastric adenocarcinoma tissue samples and metastatic lymph node tissue samples markedly increased at a rate of 47.2% (50/106) and 81.7% (49/60), respectively, as compared with the adjacent normal tissue samples in which no TNFAIP8 expression was detected (0%). This increase in TNFAIP8 expression was statistically significant. TNFAIP8 expression rates in the primary tumors (60%, 36/60) of patients with lymph node metastasis were significantly higher compared with the primary tumors of patients without lymph node metastasis (30.4%, 14/46). TNFAIP8 expression was associated with an increase in the severity of TNM stage, tumor grade, vascular invasion, lymph node metastasis and serum CA72-4 levels. The overall survival rate of patients with gastric adenocarcinoma and high TNFAIP8 expression was poorer compared with patients with low TNFAIP8 expression, and TNFAIP8 expression was negatively correlated with patient prognosis. The results also demonstrated that TNFAIP8 was an independent prognostic marker in gastric adenocarcinoma

(relative risk, 1.736; $P=0.029$). In conclusion, the results of the present study demonstrated that TNFAIP8 expression was associated with the occurrence, development and metastasis of gastric adenocarcinoma, and negatively correlated with the prognosis of patients with gastric adenocarcinoma. TNFAIP8 may therefore serve as a prognostic factor for gastric adenocarcinoma.

Introduction

Gastric cancer (GC) is the most common malignant tumor of the digestive system and its incidence and mortality rank forth and second, respectively, among common malignancies worldwide (1). GC has the highest incidence and mortality rates among digestive tract malignant tumors in China (2-5). The incidence of GC varies greatly between regions due to variations in population susceptibility and exposure to GC risk factors (6). The risk factors for GC include *Helicobacter pylori* infection (7), poor living habits (including smoking, alcohol consumption and excessive consumption of smoked, salted and pickled foods) (8,9), chronic atrophic gastritis and gastric ulcers (9,10-17). GC includes various pathological types, among which gastric adenocarcinoma accounts for 90% of total cases (18). Gastric adenocarcinoma was therefore investigated in the present study. Due to the characteristics of occult onset, high degree of malignancy, rapid development and susceptibility to metastasis, the early diagnosis rates for GC are <10% and the prognosis of advanced GC is poor (19). Although progress has been made in the diagnosis and treatment of GC, surgical resection remains the most effective therapeutic strategy to cure GC at present (20). Numerous factors, stages and genes are involved in the occurrence, development and metastasis of GC (21,22); therefore, investigation of the gene mutations and alterations in factors that underlie this process will help determine the biological behavior of GC and evaluate the prognosis of patients with GC. It is important to screen effective biomarkers for early diagnosis, treatment and prognostic evaluation of GC.

Tumor necrosis factor- α (TNF- α)-induced proteins (TNFAIP) are involved in numerous biological processes via

Correspondence to: Dr Xiuwen Wang, Department of Medical Oncology, Cancer Center, Qilu Hospital, Shandong University, 107 Wenhuxi Road, Jinan, Shandong 250012, P.R. China
E-mail: fanchen_sci2014@126.com

Key words: tumor necrosis factor- α -induced protein 8, gastric adenocarcinoma, factor analysis, prognosis

their ability to activate nuclear factor- κ B (23,24). TNFAIP8 belongs to the TNFAIP family that also includes TNFAIP8 ligands 1, 2 and 3 (25). TNFAIP8 contains a death domain (25) and has a role in the regulation of processes including cell proliferation, inflammation and apoptosis (26,27). Previous studies demonstrated that the expression of TNFAIP8 in numerous human solid tumors is correlated with tumor occurrence, development, invasion, metastasis and prognosis (28-36). Overexpression of TNFAIP8 in tumor cells can enhance cell proliferation and promote tumor growth, and the cancerous characteristics of the tumor cells are significantly reduced following TNFAIP8 gene knocked out (28,37). To the best of our knowledge, there has yet to have been any investigation into the association between TNFAIP8 expression and the clinical pathological features of gastric adenocarcinoma, and the association between TNFAIP8 expression and gastric adenocarcinoma prognosis has yet to be fully elucidated.

In the present study, TNFAIP8 expression was detected in metastatic lymph node tissue samples and normal tissue adjacent to cancerous gastric cancer tissues, and the association between TNFAIP8 expression, clinical pathological features and gastric adenocarcinoma prognosis was assessed.

Materials and methods

Tissue specimens. Paraffin embedded tissue specimens were provided by the Department of Pathology of the Affiliated Hospital of Shandong Provincial Academy of Medical Sciences (Jinan, China). Tissue specimens were collected from 106 patients with gastric adenocarcinoma who were hospitalized between August 2008 and July 2013 at the Affiliated Hospital of Shandong Provincial Academy of Medical Sciences following surgical treatment. *In situ* gastric adenocarcinoma tissue samples and normal tissue samples adjacent to the tumor (>5 cm from cancer tissue margin; control) were collected from 106 patients with gastric adenocarcinoma. Among these 106 patients, 60 cases were also diagnosed with pathological lymph node metastasis, and tissue samples from the metastatic lymph nodes were also collected from these patients. Of the 106 patients, 70 were male and 36 were female, with ages of 26-83 years (mean age, 62 years). Study participants fulfilled the inclusion criteria of patients with gastric adenocarcinoma who had not received radiotherapy or chemotherapy prior to surgery. All cases of gastric adenocarcinoma were confirmed by pathological diagnosis (38), and their clinical data and follow-up data were complete. Patients were followed-up by telephone or via correspondence. The follow-up period ended in August 2013, and the median follow-up period was 21 months (3-58 months). Patients who succumbed to other diseases or did attend the follow-up were excluded from the study. Clinical and pathological indexes included histological grade (38), TNM stage, tumor size, lymph vessel invasion, depth of tumor invasion, lymph node metastasis, carbohydrate antigen 72-4 (CA72-4) levels and the survival time of the patients. CA72-4 levels were measured using an Roche 2010 automatic electrochemiluminescence immunoassay analyzer (Roche Diagnostics, Basel, Switzerland). The survival time was calculated from the date of the surgical procedure to the last follow-up date or until to the patient succumbed to the disease due to

recurrence or metastasis. Detailed clinical information is listed in Table I. TNM stage was classified according to the 2010 edition of the AJCC Cancer Staging Manual (39). The patients did not receive any systemic radiotherapy or chemotherapy prior to surgical intervention. Written and informed consent was obtained from the patients. The study protocol was approved by the Ethics Committee of Qilu Hospital, Shandong University (Jinan, China).

Immunohistochemical staining. Immunohistochemical ultra sensitive 2-Step plus Poly-horseradish peroxidase Anti-Mouse/Rabbit IgG Detection System kit (PV-9000) with 3,3'-diamino-benzidine (DAB) was purchased from Beijing Zhongshan Jinqiao Biological Technology Co., Ltd., (Beijing, China). Immunohistochemical staining was performed according to the manufacturer's protocol. Briefly, the tissue specimens (1-2 cm) were fixed with 4% paraformaldehyde (Sigma-Aldrich, St. Louis, MO, USA) and embedded in paraffin (Shanghai Huayong Shila Ltd., Shanghai, China). The paraffin-embedded tissue samples were cut into 4- μ m-thick sections using a Leica RM2126 microtome (Leica Microsystems GmbH, Wetzlar, Germany). The tissue sections were deparaffinized and rehydrated in xylene (Sigma-Aldrich) and a graded alcohol series. Antigen retrieval was achieved by incubation with boiled citric acid buffer (10 mM citric acid and 0.05% Tween 20; pH 6) for 15 min and endogenous peroxidase was blocked with 3% hydrogen peroxide in methanol (Shenzhen Huamei Science and Technology Co., Ltd., Beijing, China) for 30 min at room temperature. Non-specific binding was blocked by incubation with goat serum (12168A03; Zhongshan Golden Bridge Biological Technology Inc., Beijing, China). Primary rabbit anti-human TNFAIP8 monoclonal antibody (1:100; ab64988; Abcam, Cambridge, MA, USA) was added to the tissue sections and incubated at 37°C for 1 h. Phosphate-buffered saline (PBS) was used instead of the primary antibody as a blank control. Tissue sections were subsequently incubated with biotin-labeled goat anti-rabbit secondary antibodies (1:200) for 30 min at room temperature following washing with PBS. Horseradish peroxidase-labeled streptavidin was added and incubated for 30 min at 37°C. Immunoreactivity was visualized using DAB at room temperature at 1 h and terminated with distilled water until brown-colored particles appeared in the cytoplasm and non-specific coloration was detected in the surrounding tissue. Tissue sections were subsequently counterstained with hematoxylin, differentiated with hydrochloric acid ethanol, dehydrated with gradient alcohol and xylene, and mounted with neutral gum (all Sigma-Aldrich). Sections were observed under an Olympus BX51 optical microscope (Olympus Corporation, Tokyo, Japan).

Determination of immunohistochemical staining results. Each sample was observed in five high magnification fields (magnification, x400) and the cells exhibiting yellow-colored particles in the cytoplasm were considered to be positive for TNFAIP8 protein expression. The staining intensity was observed and the percentage of positive cells was calculated. Based on the staining intensity, the immunohistochemical staining results were scored as follows: Score 0, no positive staining (-); score 1, pale yellow staining (+); score 2, yellow staining (++) and

Table I. Correlation of TNFAIP8 expression with clinical and pathological characteristics of gastric adenocarcinoma patients.

Variable	Cases n	TNFAIP8 expression				χ^2	P-value
		Positive		Negative			
		n	%	n	%		
Total cases	106	50	47.2	56	52.8		
Gender						1.500	0.221
Male	70	36	51.4	34	48.6		
Female	36	14	38.9	22	61.1		
Age (years)							
≥ 60	74	34	45.9	40	54.1	0.147	0.701
< 60	32	16	50.0	16	50.0		
Pathological grading						4.413	0.110
Well differentiated	14	3	21.4	11	78.6		
Moderately differentiated	24	13	54.2	11	45.8		
Poorly differentiated	68	34	50.0	34	50.0		
Tumor size (maximum diameter)						0.482	0.488
≤ 5.0 cm	31	14	45.2	17	54.8		
> 5.0 cm	75	37	49.3	38	51.7		
Vascular invasion						9.974	0.002
Yes	66	39	59.1	27	40.9		
No	40	11	27.5	29	72.5		
CA72-4						22.718	< 0.001
≤ 6.9 KU/l	47	10	21.2	37	78.7		
> 6.9 KU/l	59	40	67.8	19	32.2		
Lymphatic node metastasis						9.133	0.003
No	60	36	60.0	24	40.0		
Yes	46	14	30.4	32	69.6		
TNM stage						15.222	< 0.001
I and II	27	4	14.8	23	85.2		
III	41	24	58.5	17	41.5		
IV	38	22	57.9	16	42.1		
Tumor stage						13.151	0.001
T1-T2	28	5	17.9	23	82.1		
T3	44	25	56.8	19	43.2		
T4	34	20	58.8	14	41.2		

TNFAIP8, tumor necrosis factor- α -induced protein 8; TNM, TNM Classification of Malignant Tumours; CA72-4, carbohydrate antigen 72-4.

score 3, dark brown staining (+++). Based on the percentage of positive staining, the immunohistochemical staining results were scored as follows: Score 0, 0% positive staining; score 1, 1-25% positive staining; score 2, 26-50% positive staining; and score 3, 51-100% positive staining. The degree of staining was calculated by two independent pathologists by combining the percentage of positive staining and the intensity of staining. A third pathologist was consulted until a consensus was reached if discrepancies occurred. Scores ≤ 2 were considered to indicate low TNFAIP8 expression, and scores > 2 were considered to indicate high TNFAIP8 expression. All tissue sections were carefully examined twice in order to ensure the reproducibility of the results.

Statistical analysis. All statistical analyses were performed using SPSS software (version 19.0; SPSS, Inc, Chicago, IL, USA). χ^2 tests were performed to analyze the association between TNFAIP8 expression and clinical pathological data. The Kaplan-Meier method (40) was performed to analyze survival rates, and a Log-rank test was conducted in order to compare the difference between survival rates. Single-factorial survival analysis and COX proportional-hazard regression model analysis were subsequently performed to analyze the independent prognostic factor and multi-factors for survival, respectively. Data were presented as the mean \pm standard deviation. $P < 0.05$ was considered to indicate a statistically significant result.

Results

Expression of TNFAIP8 in gastric adenocarcinoma tissue samples, normal adjacent tissue samples and lymph node metastatic tissue samples. In order to investigate the expression of TNFAIP8 in the gastric adenocarcinoma and adjacent normal tissue samples of 106 patients, as well as the expression of TNFAIP8 in the metastatic lymph nodes of 60 of these patients, immunohistochemical analysis was performed. Light yellow or brown-colored granules were present in the cytoplasm of gastric adenocarcinoma cells, but not in the interstitial tissue (Fig. 1A). In addition, brown-colored granules were present in the metastatic lymph nodes, indicating high TNFAIP8 expression (Fig. 1B). No or weak TNFAIP8 expression was detected in the adjacent normal gastric mucosa (Fig. 1C). A total of 47.2% (50/106) of the *in situ* gastric adenocarcinoma tumor cases presented with high TNFAIP8 expression, as compared with 81.7% (49/60) in the metastatic lymph node tissue cases. Among the 60 patients with lymph node metastasis, the number of cases with high TNFAIP8 expression in the gastric adenocarcinoma *in situ* tumor tissue samples accounted for 60% (36/60), and the number of cases with high TNFAIP8 expression in the metastatic lymph nodes accounted for 80.6% (49/60). These results were statistically significant ($P < 0.05$; Fig. 2A). Of the 46 cases of gastric adenocarcinoma without lymph node metastasis, only 14 cases exhibited high TNFAIP8 expression in the *in situ* gastric adenocarcinoma tumor tissue samples. This indicated that the number of patients with high TNFAIP8 expression in the *in situ* gastric adenocarcinoma tissue samples was significantly higher in patients with lymph node metastasis (60%, 36/60), as compared with patients without lymph node metastasis (30.4%, 14/46; $P < 0.05$; Fig. 2B). These results suggest that TNFAIP8 expression is closely correlated with lymph node metastasis in gastric adenocarcinoma.

Correlation between TNFAIP8 expression and clinical and pathological characteristics. The correlation between TNFAIP8 expression and clinical and pathological characteristics of the gastric cancer patients were analyzed. The 106 patients were grouped according to age, gender, tumor size, lymph node metastasis and vascular invasion (Table I). In the patients with high TNFAIP8 expression in the gastric adenocarcinoma tissue samples, 78% (39/50) exhibited vascular invasion, 72% (36/50) had lymph node metastasis, 76% (38/50) had TNM stage IV tumors and 90% (45/50) had T3 or T4 tumors. These results indicated that TNFAIP8 expression was correlated with progression and metastasis-associated factors such as TNM staging ($P < 0.001$), tumor grade ($P = 0.001$), vascular invasion ($P = 0.002$) and lymph node metastasis ($P = 0.003$). In addition, TNFAIP8 expression in patients with gastric adenocarcinoma was associated with high serum CA72-4 levels ($P < 0.001$). However, TNFAIP8 expression had no significant correlation with age, gender, histological grading or tumor area. These results suggest that TNFAIP8 expression is closely correlated with local invasion and metastasis of gastric adenocarcinoma.

Association between TNFAIP8 expression and the prognosis of patients with gastric adenocarcinoma. To reveal the association between TNFAIP8 expression and the prognosis of

Table II. Single-factorial survival analysis.

Variable	χ^2	P-value
Gender	0.395	0.530
Age	0.079	0.779
Tumor size	2.154	0.142
Vascular invasion	1.009	0.315
CA72-4	15.794	<0.001
Lymphatic node metastasis	9.117	0.003
TNM stage	55.954	<0.001
Invasive depth	47.830	<0.001
TNFAIP8 expression	9.918	0.002

TNFAIP8, tumor necrosis factor- α -induced protein 8; TNM, TNM Classification of Malignant Tumours; CA72-4, carbohydrate antigen 72-4.

the patients, the survival data of 98/106 patients with gastric adenocarcinoma with a follow-up period of 3-58 months were obtained. The postoperative survival rates of the patients with gastric adenocarcinoma and high or low TNFAIP8 expression were compared. The median survival time of patients with high TNFAIP8 expression (mean, 16 months) was shorter compared with patients with low TNFAIP8 expression (mean, 21 months). A Log-rank test demonstrated that the overall survival rates of the two groups were significantly different (Fig. 3; $P = 0.002$). Single-factorial survival analysis demonstrated that, in addition to the expression levels of TNFAIP8, lymph node metastasis ($P = 0.003$), CA72-4 levels ($P < 0.001$), TNM staging ($P < 0.001$) and tumor classification ($P < 0.001$) were important prognostic factors (Table II). The prognostic factors of gastric adenocarcinoma such as TNFAIP8 expression levels, lymph node metastasis, CA72-4 levels and TNM staging were included in the COX multivariate analysis. In addition, factors of age and gender were included as covariates in the model. The results of multivariate the COX proportional hazard model analysis demonstrated that with the exception of TNM staging, TNFAIP8 expression levels were the only independent prognostic marker for gastric adenocarcinoma survival (relative risk, 1.736; $P = 0.029$; Table III). These results indicate that TNFAIP8 is an independent prognostic factor for gastric adenocarcinoma.

Discussion

TNFAIP8 (also called SCC-S2/GG2-1/MDC3.13) was first identified by Patel *et al.* (23) in 1997 in a human head and neck squamous cell carcinoma cell line. It is the first member of the TNFAIP8 family (23). TNFAIP8 has important roles in promoting cell proliferation and inhibiting apoptosis (28,37). Overexpression of TNFAIP8 can promote DNA synthesis, cell proliferation and inhibit the activities of apoptosis enzymes of caspase 8 and caspase 3 (41). High expression levels of TNFAIP8 have been reported in tumor cells and decreasing the expression of TNFAIP8 can reduce the tumorigenicity of tumor cells (42). Therefore, TNFAIP8 has an important role in cell survival and malignant growth-associated

Table III. Multivariate survival analysis.

Variable	β	Wald	P-value	RR	95% CI for RR	
					Lower	Upper
Age	0.233	0.958	0.328	1.262	0.792	2.012
Gender	-0.592	4.417	0.063	0.565	0.345	0.925
Lymphatic node metastasis	-0.480	2.530	0.112	0.619	0.343	1.118
CA72-4	-0.587	3.728	0.054	0.556	0.306	1.009
TNM stage		35.621	<0.001			
TNM (I, II vs. IV)	-2.173	29.807	<0.001	0.114	0.052	0.248
TNM (III vs. IV)	-1.792	26.792	<0.001	0.167	0.085	0.328
TNFAIP8 expression	0.552	4.751	0.029	1.736	1.057	2.851

TNFAIP8, tumor necrosis factor- α -induced protein 8; TNM, TNM Classification of Malignant Tumours; CI, confidence interval; RR, relative risk.

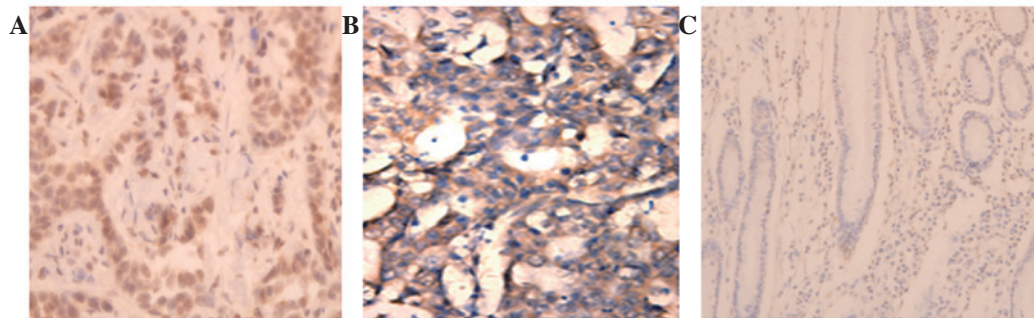


Figure 1. Analysis of TNFAIP8 expression using immunohistochemical staining (magnification, x400). Immunohistochemical staining was performed in gastric adenocarcinoma *in situ* tumor tissue samples, metastatic lymph node tissue samples and adjacent normal gastric mucosa samples. The tumor cells with yellow or brown granules were considered to be positively stained. Representative results are shown. (A) TNFAIP8 expression in gastric adenocarcinoma *in situ* tumor tissue samples. (B) TNFAIP8 expression in metastatic lymph node tissue samples. (C) TNFAIP8 expression in adjacent normal gastric mucosa samples. TNFAIP8, tumor necrosis factor- α -induced protein 8.

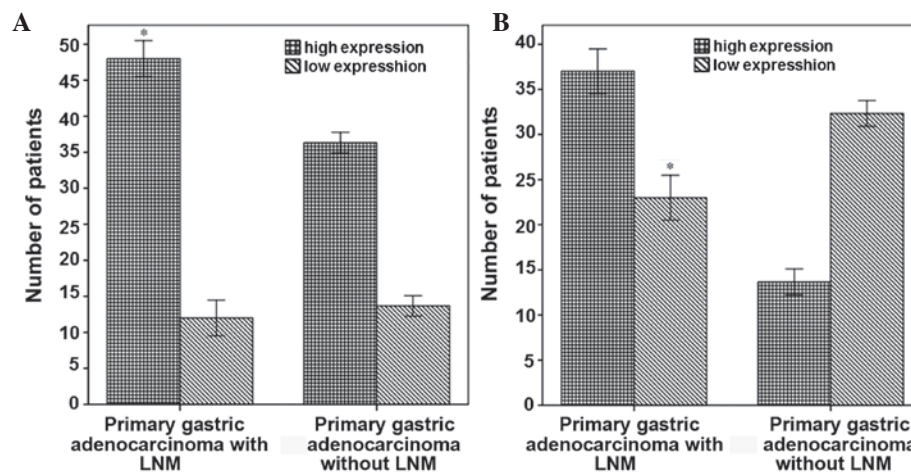


Figure 2. Comparative bar graph of TNFAIP8 expression in primary lesions and associated metastatic lymph nodes. (A) The incidence of high TNFAIP8 expression was significantly higher in metastatic lymph nodes compared with primary lesions ($P < 0.05$). (B) The incidence of low TNFAIP8 expression was significantly higher in the primary lesions of patients with lymph node metastasis compared with patients without lymph node metastasis ($P < 0.05$). LNM, lymph node metastasis; TNFAIP8, tumor necrosis factor- α -induced protein 8.

signaling pathways. Numerous recent studies demonstrated that TNFAIP8 was closely associated with the occurrence and development of several types of tumor, including renal

cell carcinoma (28), colon cancer (29), prostate cancer (30), esophageal squamous cell carcinoma (31), cervical cancer (32), non-small cell lung cancer (33), breast cancer (28), pancreatic

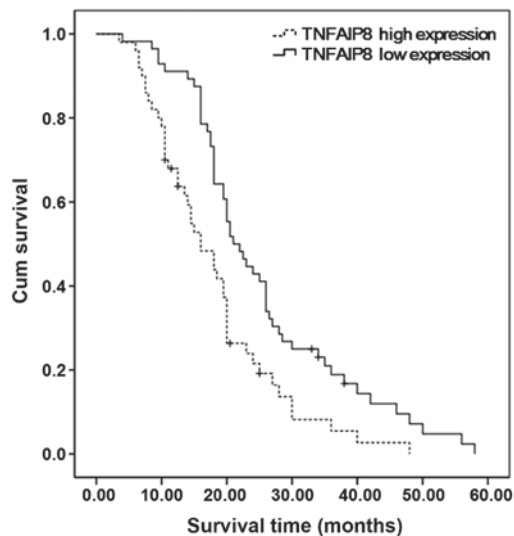


Figure 3. Survival curve of patients with gastric adenocarcinoma. Survival of patients with gastric adenocarcinoma and high or low TNFAIP8 expression was analyzed using the Kaplan-Meier method. The Kaplan-Meier survival curve is displayed. The differences in survival time were analyzed by Log-Rank test. Overall survival rates between patients with high and low TNFAIP8 expression were significantly different ($P < 0.05$). TNFAIP8, tumor necrosis factor- α -induced protein 8.

cancer (34), epithelial ovarian carcinoma (35) and endometrial carcinoma (36).

In the present study, TNFAIP8 expression in gastric adenocarcinoma, surrounding normal tissues and lymph node metastatic tissues were detected by immunohistochemistry. In addition, the correlation between TNFAIP8 expression and clinicopathological factors (including CA72-4) and prognosis were analyzed. The results of the present investigation demonstrated that the rates of high TNFAIP8 expression in metastatic lymph nodes was increased compared with *in situ* tumor tissue samples, and this result was concordant with a previous study (43). The rates of high TNFAIP8 expression in the *in situ* tumor tissue samples in patients with lymph node metastasis were significantly higher compared with the *in situ* tissue samples of patients without metastasis. Further analysis demonstrated that TNFAIP8 expression was associated with TNM stage, tumor grade, vascular invasion and lymph node metastasis. These results indicated that TNFAIP8 expression was correlated with the progression and metastasis of gastric adenocarcinoma, suggesting that it may have an important role in tumor invasion and metastasis. In addition, the data suggested that TNFAIP8 expression was correlated with serum CA72-4 levels. Previous studies have demonstrated that the serum levels of CA72-4 can be used for early diagnosis and prognosis evaluation of gastric adenocarcinoma (44-47). Therefore, we suggest that the combined detection of TNFAIP8 and CA72-4 in serum will be helpful for the accurate prediction of the prognosis of patients with gastric adenocarcinoma. Further studies are required in order to test this hypothesis.

Studies have shown that TNFAIP8 expression is negatively correlated with prognosis in numerous types of tumors, including prostate cancer (30), esophageal squamous cell carcinoma (31), cervical cancer (32), non-small cell lung cancer (33)

and epithelial ovarian cancer (35). In the current study, the survival results demonstrated that the median survival time of gastric adenocarcinoma patients with high TNFAIP8 expression patients was shorter than patients with low TNFAIP8 expression, and the overall survival rate of TNFAIP8-positive patients was relatively low. Through single-factorial survival analysis, the results indicated that in addition to TNFAIP8 expression, lymph node metastasis, TNM stage and the levels of serum CA72-4 all had important prognostic value. However, age, gender, histological differentiation and tumor size had no significant prognostic value. Survival and subsequent multivariate analysis demonstrated that TNFAIP8 expression levels were an independent prognostic factor of patients with gastric adenocarcinoma, indicating that TNFAIP8 may be used as a novel prognostic factor for gastric adenocarcinoma.

In summary, the results of the present study demonstrated that high expression levels of TNFAIP8 in gastric adenocarcinoma were associated with gastric adenocarcinoma progression and metastasis. The expression of TNFAIP8 was an independent prognostic indicator in gastric adenocarcinoma. In addition, high expression levels of TNFAIP8 indicated high metastasis and poor prognosis. Further studies are required in order to investigate the possible mechanism underlying the effects of TNFAIP8 on metastasis and prognosis of gastric adenocarcinoma.

Acknowledgements

The authors of the present study would like to thank Dr Xiuwen Wang for his suggestions, and are grateful for the technical assistance from the Department of Pathology, Affiliated Hospital of Shandong Academy of Medical Sciences.

References

1. American Cancer Society: Global cancer facts and figures, 2nd edition. Atlanta, USA, pp19-20, 2011.
2. Compare D, Rocco A and Nardone G: Risk factors in gastric cancer. *Eur Rev Med Pharmacol Sci* 14: 302-308, 2010.
3. Parkin DM: Global cancer statistics in the year 2000. *Lancet Oncol* 2: 533-543, 2001.
4. Parkin DM, Bray F, Ferlay J and Pisani P: Global cancer statistics, 2002. *CA Cancer J Clin* 55: 74-108, 2005.
5. Jemal A, Siegel R, Xu J and Ward E: Cancer statistics, 2010. *CA Cancer J Clin* 60: 277-300, 2010.
6. Chen J, Rocken C, Malferteiner P and Ebert MP: Recent advances in molecular diagnosis and therapy of gastric cancer. *Dig Dis* 22: 380-385, 2004.
7. Blaser MJ and Atherton JC: *Helicobacter pylori* persistence: Biology and disease. *J Clin Invest* 113: 321-333, 2004.
8. Zhang Y, Sun LP, Xing CZ, Xu Q, He CY, Li P, Gong YH, Liu YP and Yuan Y: Interaction between GSTP1 Val allele and *H. pylori* infection, smoking and alcohol consumption and risk of gastric cancer among the Chinese population. *PLoS One* 7: e47178, 2012.
9. Kim J, Cho YA, Choi IJ, Lee YS, Kim SY, Shin A, Cho SJ, Kook MC, Nam JH, Ryu KW, *et al*: Effects of interleukin-10 polymorphisms, *Helicobacter pylori* infection and smoking on the risk of noncardia gastric cancer. *PLoS One* 7: e29643, 2012.
10. Fukuda H, Saito D, Hayashi S, Hisai H, Ono H, Yoshida S, Oguro Y, Noda T, Sato T, Katoh M, *et al*: *Helicobacter pylori* infection, serum pepsinogen level and gastric cancer: A case-control study in Japan. *Jpn J Cancer Res* 86: 64-71, 1995.
11. Ohata H, Kitauchi S, Yoshimura N, Mugitani K, Iwane M, Nakamura H, Yoshikawa A, Yanaoka K, Arii K, Tamai H, *et al*: Progression of chronic atrophic gastritis associated with *Helicobacter pylori* infection increases risk of gastric cancer. *Int J Cancer* 109: 138-143, 2004.

12. Oishi Y, Kiyohara Y, Kubo M, Tanaka K, Tanizaki Y, Ninomiya T, Doi Y, Shikata K, Yonemoto K, Shiota T, *et al*: The serum pepsinogen test as a predictor of gastric cancer: The Hisayama study. *Am J Epidemiol* 163: 629-637, 2006.
13. Ren JS, Kamangar F, Qiao YL, Taylor PR, Liang H, Dawsey SM, Liu B, Fan JH and Abnet CC: Serum pepsinogens and risk of gastric and oesophageal cancers in the general population nutrition intervention trial cohort. *Gut* 58: 636-642, 2009.
14. Watabe H, Mitsushima T, Yamaji Y, Okamoto M, Wada R, Kokubo T, Doi H, Yoshida H, Kawabe T and Omata M: Predicting the development of gastric cancer from combining *Helicobacter pylori* antibodies and serum pepsinogen status: A prospective endoscopic cohort study. *Gut* 54: 764-768, 2005.
15. Ye W, Held M, Lagergren J, Engstrand L, Blot WJ, McLaughlin JK and Nyrén O: *Helicobacter pylori* infection and gastric atrophy: Risk of adenocarcinoma and squamous-cell carcinoma of the esophagus and adenocarcinoma of the gastric cardia. *J Natl Cancer Inst* 96: 388-396, 2004.
16. You WC, Blot WJ, Zhang L, Kneller RW, Li JY, Jin ML, Chang YS, Zeng XR, Zhao L, Fraumeni JF Jr, *et al*: Serum pepsinogens in relation to precancerous gastric lesions in a population at high risk for gastric cancer. *Cancer Epidemiol Biomarkers Prev* 2: 113-117, 1993.
17. Correa P: A human model of gastric carcinogenesis. *Cancer Res* 48: 3554-3560, 1988.
18. Zhang M, Wang X, Li W and Cui Y: miR-107 and miR-25 simultaneously target LATS2 and regulate proliferation and invasion of gastric adenocarcinoma (GAC) cells. *Biochem Biophys Res Commun* 460: 806-812, 2015.
19. Song YX, Zhou X, Wang ZN, Gao P, Li AL, Liang JW, Zhu JL, Xu YY and Xu HM: The association between individual SNPs or haplotypes of matrix metalloproteinase 1 and gastric cancer susceptibility, progression and prognosis. *PLoS One* 7: e38002, 2012.
20. Ajani JA, Barthel BJ and Bekall-Saab T: NCCN Clinical practice guidelines in oncology, gastric cancer, v.1.2011. Washington: National Comprehensive Cancer Network 26, 2011.
21. Saif MW, Makrilia N, Zalonis A, Merikas M and Syrigos K: Gastric cancer in the elderly: An overview. *Eur J Surg Oncol* 36: 709-717, 2010.
22. Brenner H, Rothenbacher D and Arndt V: Epidemiology of stomach cancer. *Methods Mol Biol* 472: 467-477, 2009.
23. Patel S, Wang FH, Whiteside TL and Kasid U: Identification of seven differentially displayed transcripts in human primary and matched metastatic head and neck squamous cell carcinoma cell lines: Implications in metastasis and/or radiation response. *Oral Oncol* 33: 197-203, 1997.
24. Kumar D, Whiteside TL and Kasid U: Identification of a novel tumor necrosis factor-alpha-inducible gene, SCC-S2, containing the consensus sequence of a death effector domain of fas-associated death domain-like interleukin-1 beta-converting enzyme-inhibitory protein. *J Biol Chem* 275: 2973-2978, 2000.
25. You Z, Quyang H, Lopatin D, Polver PJ and Wang CY: Nuclear factor-kappa B-inducible death effector domain-containing protein suppresses tumor necrosis factor-mediated apoptosis by inhibiting caspase-8 activity. *J Biol Chem* 276: 26398-26404, 2001.
26. Freundt EC, Bidere N and Lenardo MJ: A different TIPE of immune homeostasis. *Cell* 133: 401-402, 2008.
27. Sun H, Gong S, Carmody RJ, Hilliard A, Li L, Sun J, Kong L, Xu L, Hilliard B, Hu S, *et al*: TIPE2, a negative regulator of innate and adaptive immunity that maintains immune homeostasis. *Cell* 133: 415-426, 2008.
28. Zhang C, Chakravarty D, Sakabe I, Mewani RR, Boudreau HE, Kumar D, Ahmad I and Kasid UN: Role of SCC-S2 in experimental metastasis and modulation of VEGFR-2, MMP-1 and MMP-9 expression. *Mol Ther* 13: 947-955, 2006.
29. Miao Z, Zhao T, Wang Z, Xu Y, Song Y, Wu J and Xu H: SCC-S2 is overexpressed in colon cancers and regulates cell proliferation. *Tumour Biol* 33: 2099-2106, 2012.
30. Zhang C, Kallakury BV, Ross JS, Mewani RR, Sheehan CE, Sakabe I, Luta G, Kumar D, Yadavalli S, Starr J, *et al*: The significance of TNFAIP8 in prostate cancer response to radiation and docetaxel and disease recurrence. *Int J Cancer* 133: 31-42, 2013.
31. Hadisaputri YE, Miyazaki T, Suzuki S, Yokobori T, Kobayashi T, Tanaka N, Inose T, Sohma M and Kuwano H: TNFAIP8 overexpression: Clinical relevance to Esophageal squamous cell carcinoma. *Ann Surg Oncol* 19 (Suppl 3): S589-S596, 2012.
32. Shi TY, Cheng X, Yu KD, Sun MH, Shao ZM, Wang MY, Zhu ML, He J, Li QX, Chen XJ, *et al*: Functional variants in TNFAIP8 associated with cervical cancer susceptibility and clinical outcomes. *Carcinogenesis* 34: 770-778, 2013.
33. Dong QZ, Zhao Y, Liu Y, Wang Y, Zhang PX, Jiang GY, Dong XJ, Cui QZ and Wang EH: Overexpression of SCC-S2 correlates with lymph node metastasis and poor prognosis in patients with non-small-cell lung cancer. *Cancer Sci* 101: 1562-1569, 2010.
34. Liu K, Qin CK, Wang ZY, Liu SX, Cui XP and Zhang DY: Expression of tumor necrosis factor-alpha-induced protein 8 in pancreas tissues and its correlation with epithelial growth factor receptor levels. *Asian Pac J Cancer Prev* 13: 847-850, 2012.
35. Liu T, Gao H, Chen X, Lou G, Gu L, Yang M, Xia B and Yin H: TNFAIP8 as a predictor of metastasis and a novel prognostic biomarker in patients with epithelial ovarian cancer. *Br J Cancer* 109: 1685-1692, 2013.
36. Liu T, Gao H, Yang M, Zhao T, Liu Y and Lou G: Correlation of TNFAIP8 overexpression with the proliferation, metastasis and disease-free survival in endometrial cancer. *Tumour Biol* 35: 5805-5814, 2014.
37. Kumar D, Gokhale P, Broustas C, Chakravarty D, Ahmad I and Kasid U: Expression of SCC-S2, an antiapoptotic molecule, correlates with enhanced proliferation and tumorigenicity of MDA-MB 435 cells. *Oncogene* 23: 612-616, 2004.
38. Hamilton SR and Aaltonen LA (eds): Pathology and genetics of tumours of the digestive system In: World Health Organization Classification of Tumours. Lyon, France: IARC Press, pp38-52, 2000.
39. Stephen EB, David BR, Carolyn CC, April GF, Frederick LG and Andy T (eds): AJCC cancer staging manual. 7th edition. Lippincott-Raven, Philadelphia, PA, 2010. pp117-127, 2010.
40. Klein JP and Moeschberger ML (eds): Survival analysis: Techniques for censored and truncated data. Springer, New York, pp83-109, 2003.
41. Romanuik TL, Ueda T, Le N, Haile S, Yong TM, Thomson T, Vessella RL and Sadar MD: Novel biomarkers for prostate cancer including noncoding transcripts. *Am J Pathol* 175: 2264-2276, 2009.
42. Jacobs JJ, Lehe C, Cammans KD, Yoneda K, Das PK and Elliott GR: An automated method for the quantification of immunostained human Langerhans cells. *J Immunol Method* 247: 73-82, 2001.
43. Wen Q, Liao HF, Yuan SB, Qiu XF, Zhuang GH and Liu ZC: Expression and clinical significance of TNFAIP8 in gastric tissues. *Mian Yi Xue Za Zhi* 02: 181-184, 2012 (In Chinese).
44. Byrne DJ, Browning MC and Cuschieri A: CA72-4: A new tumor marker for gastric cancer. *Br J Surg* 77: 1010-1013, 1990.
45. Hamazoe R, Maeta M, Matsui T, Shibata S, Shiota S and Kaibara N: CA72-4 compared with carcinoembryonic antigen as a tumor marker for gastric cancer. *Eur J Cancer* 28A: 1351-1354, 1992.
46. Ikeguchi M, Katano K, Saitou H, Tsujitani S, Maeta M and Kaibara N: Pre-operative serum levels of CA72-4 in patients with gastric adenocarcinoma. *Hepatogastroenterology* 44: 866-871, 1997.
47. Sougioultzis S, Syrios J, Xynos ID, Bovaretos N, Kosmas C, Sarantonis J, Dokou A, Tzivras D, Zografos G, Felekouras E, *et al*: Palliative gastrectomy and other factors affecting overall survival in stage IV gastric adenocarcinoma patients receiving chemotherapy: A retrospective analysis. *Eur J Surg Oncol* 37: 312-318, 2011.