

Central nervous system complications of mycoplasma pneumoniae

G DECAUX, M SZYPER, M ECTORS, A CORNIL, AND L FRANKEN

From the University Hospital St Pierre, University of Brussels, Brussels, Belgium

SUMMARY Three cases of central nervous system complications of *Mycoplasma pneumoniae* infections are reported. There were several atypical findings: the first patient presented with an acute disseminated encephalitis with normal cerebrospinal fluid and hypogammaglobulinaemia. The second patient presented with a left sixth nerve palsy followed six weeks later by choreoathetoid movements and an acute psychosis. The third patient presented with an acute encephalitis associated with acute renal failure secondary to rhabdomyolysis and was the only patient who did not completely recover; he was discharged akinetic and mute, but with normal renal function. The diagnosis of complications of *Mycoplasma pneumoniae* may be difficult. In two of the three cases a raised red blood cell volume secondary to a high titre of cold agglutinins rapidly led to the correct diagnosis.

Mycoplasma pneumoniae has been shown to cause an acute respiratory illness ranging in severity from a mild upper respiratory tract infection to pneumonia.¹ Skin, cardiac, gastrointestinal, articular and haematological disorders are recognised as extrapulmonary complications.² Central nervous system complications of *Mycoplasma pneumoniae* infection have been described, including meningo-encephalitis, cerebellitis, meningitis, polyradiculopathy, transverse myelitis, cranial nerve palsies, and acute psychosis.² Of all *Mycoplasma pneumoniae* infections diagnosed by cultures or serological tests (or both), only 60 examples of neurological complications have been reported.³⁻¹² We describe three additional cases with atypical clinical findings.

Case reports

Case 1 A 57 year old right-handed man had been complaining for one week of respiratory distress and coughing but recovered. On the day of admission, he developed over a few hours a left hemiplegia. His temperature was 37.5°C. He was referred with a diagnosis of stroke. ^{99m}Tc radionuclide brain scan revealed three areas of increased uptake: two on the right, one on the left (fig). Multiple abscesses, metastases and arteritis were considered as possible diagnoses. The patient was given high doses of chloram-

phenicol and dexamethasone. The next morning his right upper limb was in a decorticate posture. His breathing was abnormal: there was a long and stertorous expiratory time and the patient tried to help himself by pressing his right hand on his sternum. Neurological examination revealed normal awareness, speech and intellectual function. There was a left central facial weakness and paralysis, hyperreflexia and spasticity of all four limbs. Sensory examination was normal. X-rays of the chest on admission revealed a patchy infiltrate at the base of the right lung. An electroencephalogram (EEG) showed theta-delta dysrhythmia on the right and irregular alpha rhythm on the left. A CT scan and bilateral carotid angiography were normal. Cerebrospinal fluid (CSF) was normal (table 1). Smears and cultures for bacteria, acid-fast bacteria, fungi and viruses were negative, as were cultures of blood, urine and pharyngeal secretions. The patient had a raised mean corpuscular volume due to cold-induced agglutination of the cells in the Coulter counter. As indicated in table 2, when the cold haemagglutinin level decreased, the mean corpuscular volume returned to a normal value. After the second day in hospital the diagnosis of acute disseminated encephalitis secondary to *Mycoplasma pneumoniae* infection was suspected; the patient was given 200 mg doxycycline daily, and the dexamethasone and chloramphenicol were gradually reduced.

Three weeks later, serum titres for *Mycoplasma pneumoniae* increased. A screen for auto-antibodies (nuclear, mitochondria, liver-renal antigens, smooth muscle, thyroid, parietal cells, salivary glands, pancreas, adrenals, striated muscle) was negative except for a slightly positive antinucleolar factor, which

Address for reprint requests: Dr G Decaux, Service de Médecine Interne, Hôpital Universitaire St Pierre, 322 rue Haute, B-1000 Bruxelles (Belgium).

Accepted 15 May 1980

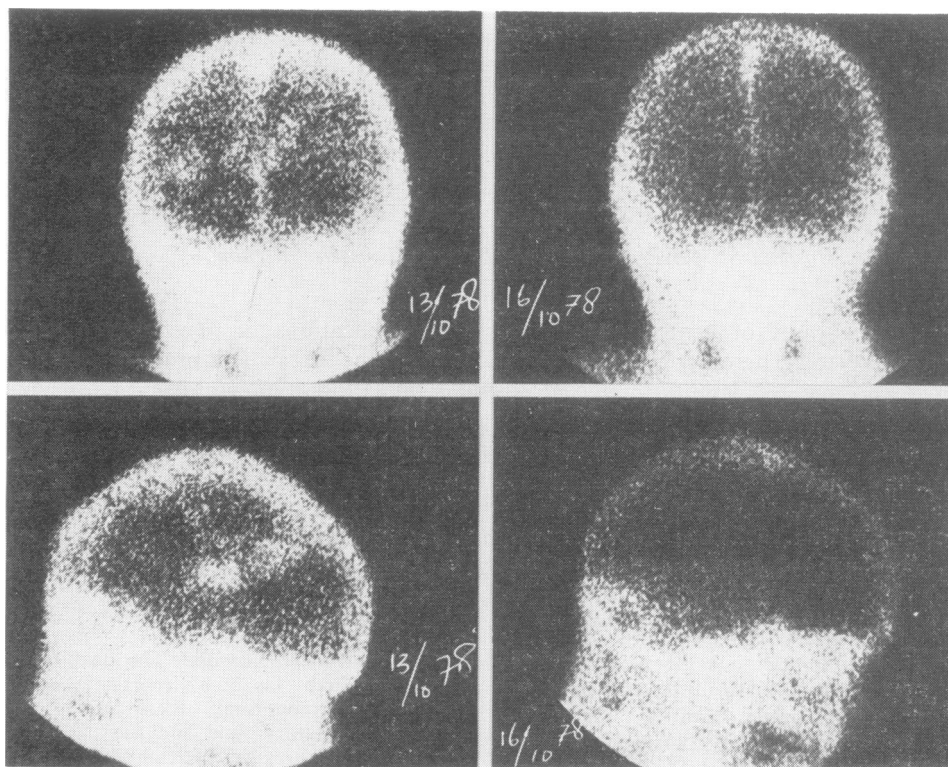


Figure ^{99m}Tc radionuclide brain scans of case 1 showing two areas of increased uptake on the right and one on the left and its normalisation after three days.

disappeared one month later. Total complement, fractions C_3 and C_4 were within normal limits. Quantitative immunoglobulin assay revealed a moderate hypogammaglobulinaemia (4.5–5.5 g/l; normal value: 7.5–15 g/l). Haptoglobin and bilirubin were normal.

The patient's condition began to improve after 10 days but he had urinary incontinence for more than two months, and the spastic quadriplegia slowly re-

gressed over a three-month period. CT scan then showed enlarged lateral ventricles. Six months later, he was mildly depressed but neurological examination was normal.

This patient thus had an acute disseminated encephalitis with normal CSF, and a moderate idiopathic hypogammaglobulinaemia; children with severe immunological deficiency may develop chronic infection due to *Mycoplasma pneumoniae*.¹³

Table 1 Cerebrospinal fluid findings in 3 patients with central nervous system complications of *Mycoplasma pneumoniae* infection

Case no	Date	WBC/mm ³	Lymphocyte (%)	Protein (mg/dl)	Glucose (mg/dl) CSF/blood	Lactic acid (mg/dl)	CF CSF	Diagnosis
1	15.10.78	1	15	26	108/209	34	—	Acute disseminated encephalitis
	8.11.78	0	—	21	50/80	18.9	—	
2	21.12.78	23	85	330	86/94	17	—	Acute psychosis Choreoathetosis Sixth nerve palsy
	2. 1.79	3	57	154	62/113	15	—	
3	31.1.79	12	35	74	85/100	34	—	Encephalitis Rhabdomyolysis Acute renal failure
	7.2.79	0	—	21	ND/ND	13	—	

CF = complement fixation

— = negative

ND = not done

Table 2 Blood analyses in 3 patients with central nervous system complications of *Mycoplasma pneumoniae* infection

Case no	Date	ESR (mm/h)	WBC	MCV Fl (μm^3)	CA	CF	SMGA	Throat + CSF culture	Chest X ray	Diagnosis
1	13.10.78	75	15 800	104	1/512	—	—	—	+	Acute disseminated encephalitis
	18.11.78	32	7 900	93	1/32	1/64	—	—	—	
2	21.12.78	30	11 600	92	1/64	—	—	—	—	Acute psychosis Choreoathetosis
	31.12.78	120	37 800	109	1/256	—	ND	—	—	
3	26. 1.79	72	6 300	90	1/16	1/64	ND	ND	—	Sixth nerve palsy
	31. 1.79	70	6 700	91	—	—	—	—	—	Encephalitis
	12. 2.79	50	9 900	91	—	1/64	ND	ND	—	Rhabdomyolysis Acute renal failure

CA = cold agglutinins

CF = complement fixation

SMGA = Streptococcus MG agglutinins

— = negative

ND = not done

Case 2 A 52 year old Spaniard, suffering from silicosis after 13 years work in a coal-mine, was in relatively good health until three months prior to admission, when he complained of persistent frontal and occipital headaches. Six weeks prior to admission he complained of double vision on left lateral gaze. No history of trauma was recorded. The blood pressure was normal. Neurological examination showed only a left sixth nerve palsy. EEG, skull X-ray and CT scan were normal. Glucose was within normal range. Serologic tests for syphilis were negative. This ocular palsy of unknown origin regressed partially.

One week prior to admission, he became apathetic and childish. He would not leave his bed or eat alone. Three days prior to admission, he became delirious and exhibited choreo-athetoid movements of all four limbs and mouth. He was then referred to our hospital.

He was not pyrexial. Neurological examination showed an awake but confused patient who was hallucinated. The cranial nerves were intact except for a left sixth nerve paresis. Motor examination was normal for strength and reflexes but constant involuntary choreoathetoid movements of all the limbs and an orofacial dyskinesia were noted. Sensory examination was normal. The patient refused to walk. He had no meningeal signs. Chest X-ray showed a category 3 coalworker's pneumoconiosis. An EEG showed diffuse theta slowing; CT and $^{99\text{m}}\text{Tc}$ radionuclide brain scans were normal. CSF contained 23 cells/mm³, a protein level of 3.30 g/l (see table 1); smears and cultures for bacteria, acid-fast bacteria, fungi and viruses were all negative. Initial laboratory data disclosed a cold agglutinin titre of 1/64. An autoantibody screen and search for circulating immune complexes were negative. Haptoglobin and bilirubin were normal.

Ten days after the onset of the psychotic episode serial serum samples revealed an increase in *Mycoplasma pneumoniae* complement fixation to a titre of 1/64; at that time the cold agglutinin titre was 1/256. The mean corpuscular volume was 109 fl (μm^3), and the white cell count was 37 800/mm³.

The choreo-athetoid movements disappeared after two weeks and the confusion regressed a week later. He was discharged from hospital after five weeks without any neurological sequelae.

Chorea has been described in meningoencephalitis¹⁴ but to our knowledge this is the first case of chorea associated with *Mycoplasma pneumoniae* infection. The sixth nerve palsy probably was not related to the *Mycoplasma pneumoniae* infection for it occurred six weeks before the psychosis and eight weeks before the sero-conversion.

Case 3 A 60 year old man was in excellent health until three days prior to admission when he complained of headaches, myalgia and fever. He was admitted to another hospital in a confused state of mind with a rectal temperature of 40°C. Neurological examination revealed a left hemiparesis and neck rigidity. Initial laboratory data disclosed 18 100/mm³ white blood cells in the peripheral blood, serum urea 8.3 mmol/l, serum creatinine 114 $\mu\text{mol/L}$, CPK 800 (N: 5–35 IU/dl), and normal electrolytes. CT was normal. The patient became drowsy, exhibited Cheyne-Stokes respiration, and required intubation. On his way to our hospital he had one grand mal seizure. His level of consciousness varied and at times he required ventilatory assistance.

Acute renal failure without oliguria became obvious when, on the third day, serum creatinine was 541 $\mu\text{mol/L}$ urea 43 mmol/l, uric acid 1.1 mmol/l, calcium 1.75 mmol/l, phosphorus 2.09 mmol/l; other electrolytes were normal. Dark urine was not observed, but myoglobinuria measured by counter immunoelectrophoresis was positive (400 mg/l). Evidence of rhabdomyolysis was shown by high levels of muscular enzymes (CPK 2,900 IU/ml; SGOT 314 IU/ml; LDH 2,500 IU/ml; aldolase 70 IU/ml). Haptoglobin and bilirubin levels were normal. The neurological examination revealed a varying level of consciousness and a left hemiparesis. An EEG showed bilateral slow waves. A $^{99\text{m}}\text{Tc}$ radionuclide brain scan was normal. Thorough search for infectious agents, including Leptospirosis and Herpes simplex did not yield a positive result. No autoantibody or circulating immune complexes were detected. Initial

CSF (table 1) contained 12 cells/mm³, a protein level of 0.74 g/l, a glucose level of 4.7 mmol/l (with a simultaneous blood glucose of 5.5 mmol/l). A complement fixation titre of 1/64 for mycoplasma pneumoniae was observed two weeks later in serial serum samples.

The patient required repeated haemodialysis during the first three weeks. Transient hypercalcaemia (3 mmol/l) was observed during the fourth week, when renal function returned to normal. The patient was discharged from hospital at the eleventh week with akinetin mutism, but the left hemiparesis had regressed.

Non-traumatic rhabdomyolysis accounted for 5% and 7% of all cases of acute renal failure in two large series.^{15 16} Usually it is due to drug or alcohol intake (in doses large enough to induce coma), producing muscle necrosis from compression, ischaemia and direct toxicity. Rhabdomyolysis with grand mal seizures also has been reported,¹⁷ but in this case the grand mal seizure occurred after the increase in muscle enzymes. To our knowledge, this is the first report of non-traumatic rhabdomyolysis, acute renal failure and encephalitis associated with *Mycoplasma pneumoniae* infection.

Discussion

Central nervous system complications of *Mycoplasma pneumoniae* infection are thought to be rare. In a Swedish series, however they occurred in approximately 0.1% of all *Mycoplasma pneumoniae* infections, and in 7% of the patients admitted to hospital with this diagnosis.⁷ Neurological features associated with *Mycoplasma pneumoniae* infection are so diverse and non-specific that the proper diagnosis cannot be made solely on clinical grounds. Moreover, a previous history of respiratory infection was about in 21% of the cases.⁵ Diagnosis is aided by standard tests for complement fixation, a fourfold or greater rise in titres between acute and convalescent phase specimens being of diagnostic value; a single titre of at least 1/64 also is highly suggestive.² Cold isohaemagglutinins for human type O erythrocytes appear by the end of the first week of infection in 33% to 76% of cases and are the first antibodies to disappear.¹⁸ Cold agglutinins are IgM antibodies containing both K and L light chains which react with the I antigen of the red blood cell membrane. The presence of cold agglutinins is not diagnostic; they occur in myeloproliferative and lymphoproliferative diseases, collagen diseases and other infectious diseases (mononucleosis, cytomegalovirus infection, listeriosis, subacute endocarditis, syphilis).¹ In other viral infections titres rarely exceed 1/32.² In a single specimen a combina-

tion of an elevated complement fixation titre ($\geq 1/64$) and a significant cold agglutinin titre ($\geq 1/64$) indicates recent infection.¹⁹ The presence of cold agglutinins in *Mycoplasma pneumoniae* infection rarely produces clinically significant hemolytic anaemia.² In our three patients, Coombs reactions were negative and total complement, C₃ and C₄ were normal. One other case of spurious elevation of mean corpuscular volume secondary to cold agglutinins was reported by Kopelman,²⁰ as erythrocyte clumps are mistaken for single cells in the Coulter counters. Isolation of *Mycoplasma pneumoniae* from throat culture also is diagnostic.

The pathogenesis of the neurological manifestations is unknown. Four hypotheses have been considered. They could be due to direct invasion of the nervous system by the organism, but *Mycoplasma pneumoniae* has been found in the cerebrospinal fluid only in one case of Guillain-Barré syndrome,²¹—and has never been isolated from the brain itself.

Another possibility is that *Mycoplasma pneumoniae* produce a neurotoxin. A toxic component of *Mycoplasma gallisepticum* injected intravenously produces arterial lesions resembling those of serum sickness in turkey poult,²² and an exotoxin of *Mycoplasma neurolyticum* produces spongiform degeneration of the brain to cause the "rolling disease" in rats and mice.²³

An autoimmune mechanism also has been proposed, perhaps a cross-reaction of an antibody to glycolipids or phospholipids of *Mycoplasma pneumoniae* and brain tissue. Antibodies to the brain have been demonstrated in many cases, but such brain antibodies also are found among patients who do not exhibit neurological dysfunction.²⁴

Finally, some symptoms could be explained by multiple vascular microthrombi within the central nervous system with or without blood hypercoagulability.²⁵

Tetracyclines or erythromycin are the drugs of choice to treat *Mycoplasma pneumoniae* infection, and tetracyclines diffuse in to the cerebrospinal fluid. Whether or not neurological complications can benefit from such treatment is unknown.

References

- 1 Chanock RM. Mycoplasma infections of man. *New Engl J Med* 1965; **273**:1199-206.
- 2 Levine DP, Lerner AM. The clinical spectrum of *Mycoplasma pneumoniae* infections. *Med Clin N Am* 1978; **62**:961-78.

- 3 Le Bigot P, Vachon F, Manuel C, Masson M. Manifestations neurologiques de l'infection à *Mycoplasma pneumoniae*. A propos de 12 observations. *Rev Neurol (Paris)* 1976; **132**:791-8.
- 4 Hodges GR, Fass RJ, Saslaw S. Central nervous system disease associated with *Mycoplasma pneumoniae* infection. *Arch Intern Med* 1972; **130**:271-82.
- 5 Lerer RJ, Kalavsky SM. Central nervous system disease associated with *Mycoplasma pneumoniae* infection: report of five cases and review of the literature. *Pediatrics* 1973; **52**:658-68.
- 6 Steele JC, Gladstone RM, Thanasophon S, Fleming PC. Acute cerebellar ataxia and concomitant infection with *Mycoplasma pneumoniae*. *J Pediatr* 1972; **80**:467-9.
- 7 Sterner G, Biberfeld G. Central nervous system complications of *Mycoplasma pneumoniae* infection. *Scand J Infect Dis* 1969; **1**:203-8.
- 8 Vuopala V, Junstila H, Takkunen J. Transient hemiplegia associated with *Mycoplasma pneumoniae* infection. *Ann Clin Res* 1970; **2**:167-70.
- 9 Taylor MJ, Burrow GN, Strauch B, Hartmann DM. Meningoencephalitis associated with pneumonitis due to *Mycoplasma pneumoniae*. *JAMA* 1967; **199**:813-6.
- 10 Kuzumaki N, Umezu M. Meningitis with a high titer of *Mycoplasma pneumoniae* complement fixation antibody. *Naika* 1970; **25**:781-3.
- 11 Endtz LJ, Joele LJ, Hoogland P, Hers JFP. Manifestations neurologiques de l'infection par le *Mycoplasma pneumoniae* à propos de 10 cas personnels et de 22 cas de la littérature. *Psychiat Neurol Neurochir (Amst)* 1973; **76**:275-84.
- 12 Berglund A, Wikberg KF. Komplicerande Meningoencefalit vid pneumoni förosakad av. *Läkartidningen* 1969; **66**:302-6.
- 13 Foy HM, Ochs H, Davis SD *et al.* *Mycoplasma pneumoniae* infections in patients with immunodeficiency syndromes. Report of four cases. *J Infect Dis* 1973; **127**:388-93.
- 14 Peters ACB, Vielvoye GJ, Versteeg J *et al.* ECHO 25 focal encephalitis and subacute hemichorea. *Neurology* 1979; **29**:676-81.
- 15 Grossman RA, Hamilton RW, Morse BM *et al.* Non-traumatic rhabdomyolysis and acute renal failure. *New Engl J Med* 1974; **291**:807-11.
- 16 Koffler A, Friedler RM, Massry SG. Acute renal failure due to non-traumatic rhabdomyolysis. *Ann Intern Med* 1976; **85**:23-8.
- 17 Diamond I, Aquino TI. Myoglobinuria following unilateral status epilepticus and ipsilateral rhabdomyolysis. *New Engl J Med* 1965; **272**:834-7.
- 18 Klimek JJ, Russman BS, Quintiliani R. *Mycoplasma pneumoniae* meningoencephalitis and transverse myelitis in association with low cerebrospinal fluid glucose. *Pediatrics* 1976; **58**:133-4.
- 19 Jones GR, Stewart SM. A prospective study of the persistence of *Mycoplasma pneumoniae* antibody levels. *Scott Med J* 1974; **19**:129-33.
- 20 Kopelman P. Raised mean cell volume and meningoencephalitis associated with *Mycoplasma pneumoniae* infection. *Br Med J* 1977; **1**:881-2.
- 21 Fleischauer P, Huben V, Mertens H *et al.* Von *Mycoplasma pneumoniae* im Liquor bei akuter Polineuritis. *Deutsch Med Wschr* 1972; **97**:678.
- 22 Thomas L, Davidson M, McCluskey RT. The production of cerebral polyarteritis by *Mycoplasma gallisepticum* in turkeys; the neurotoxic property of the *Mycoplasma*. *J Exp Med* 1966; **124**:897-912.
- 23 Thomas L, Aleu F, Bitensky MW *et al.* The neurotoxin of *Mycoplasma neurolyticum*. *J Exp Med* 1966; **124**:1067-80.
- 24 Biberfeld G. Antibodies to brain and other tissues in cases of *Mycoplasma pneumoniae* infection. *Clin Exp Immunol* 1971; **8**:319.
- 25 Mordh PA, Ursing B, Lind K. Persistent cerebellar symptoms after infection with *Mycoplasma pneumoniae*. *Scand J Infect Dis* 1975; **7**:157-60.