

## Case Report

# Disseminated Hemangiosarcoma in a Juvenile Rhesus Macaque (*Macaca mulatta*)

Amanda P Beck,<sup>1,\*</sup> Stanton B Gray,<sup>1</sup> and Beth K Chaffee<sup>1</sup>

Hemangiosarcoma is a malignant tumor of vascular endothelial origin that is sporadically reported in rhesus macaques. This report describes the clinicopathologic features of a 1-y-old rhesus macaque with spontaneous disseminated hemangiosarcoma that originally presented as a focal cutaneous mass. Histopathologic examination of multiple tumor foci revealed regions in which the neoplastic cells formed diffuse sheets, as well as the well-defined vascular channels typically associated with hemangiosarcoma. Multiple endothelial cell immunomarkers were used to confirm the diagnosis in this rhesus macaque. The tumor exhibited staining properties consistent with those seen in domestic animals and humans. In addition, to our knowledge, this animal represents the youngest case of any form of spontaneous hemangiosarcoma reported in the rhesus macaque to date.

**Abbreviations:** FVIII-ra, factor-VIII-related antigen; VEGF, vascular endothelial growth factor

Hemangiosarcoma is a malignant tumor of vascular endothelial cell origin that can develop in the skin or viscera.<sup>14,16,19,28</sup> In animals, these tumors arise with greatest incidence in dogs, but they also occur infrequently in cats, horses, cows, sheep, ferrets, birds, rodents, and NHP.<sup>14,16,19,28</sup> Although considered rare in rhesus macaques, sporadic cases of hemangiosarcoma have been reported.<sup>13,16,19,28</sup> The term ‘angiosarcoma’ describes the similar malignancy of blood vessel or lymphatic endothelial origin that occurs in humans.<sup>16,28</sup> Angiosarcomas are one of the rarest soft tissue tumors in humans, accounting for about 1% of solid malignancies in adults.<sup>4,12,16</sup> In humans and domestic animals, primary cutaneous angiosarcomas (that is, hemangiosarcomas) often present in middle-aged to geriatric adults and involve the head or extremities that are chronically exposed to sunlight.<sup>5,7,8</sup> Cases of human pediatric cutaneous or visceral angiosarcoma are considered extraordinarily rare and are commonly associated with preexisting congenital and genetic conditions, suggesting that the pathogenesis has more of a genetic basis than environmental.<sup>5,15</sup> In children, the 5-y survival rate is about 52% for cutaneous angiosarcoma, compared with 35% with visceral angiosarcoma.<sup>4,5</sup>

In all domestic animal species reported, primary cutaneous hemangiosarcoma is locally invasive with occasional metastasis but is generally less aggressive than is primary visceral hemangiosarcoma, which often disseminates to multiple locations, including the skin.<sup>7,8</sup> The diagnosis of disseminated hemangiosarcoma is characterized by multiple-organ involvement, typically documented at postmortem examination.<sup>26</sup> However, it remains debatable whether disseminated hemangiosarcoma represents a

primary tumor that has spread metastatically or concurrent multicentric neoplastic transformation of endothelial cells.<sup>27</sup>

The current report describes the clinicopathologic features of a 1-y-old rhesus macaque with spontaneous disseminated hemangiosarcoma that originally presented as a focal cutaneous mass. After surgical excision of the initial skin tumor, additional neoplastic foci were detected within cutaneous tissues and viscera, consistent with the disseminated form of hemangiosarcoma. Histopathologic examination of multiple tumor foci revealed regions in which the neoplastic cells formed diffuse sheets rather than the defined vascular channels typically associated with a well-differentiated hemangiosarcoma. Immunohistochemistry is often useful in the definitive diagnosis of vascular neoplasms in both humans and animals, particularly in less-differentiated tumors in which neoplastic cells fail to form characteristic vascular spaces.<sup>10,16,19</sup> In the current case, multiple endothelial cell immunostains were used to confirm the diagnosis. The staining properties of immunomarkers in this rhesus macaque were consistent with those seen in domestic animals and humans. In addition, to our knowledge, this animal represents the youngest case of any form of spontaneous hemangiosarcoma reported in rhesus macaques to date.

## Case Report

Animal care and husbandry practices conformed to standards established by AAALAC, the *Guide for the Care and Use of Laboratory Animals*, and the Animal Welfare Act. All procedures were approved by The University of Texas MD Anderson Cancer Center IACUC. The animal described in this report belonged to a closed breeding colony of Indian-origin rhesus macaques (*Macaca mulatta*) that is SPF for *Macacine herpesvirus 1*, simian retroviruses (SRV1, SRV2, SIV, and simian T-cell leukemia virus type 1), and *Mycobacterium tuberculosis* complex. The macaque was socially

Received: 14 Oct 2015. Revision requested: 15 Nov 2015. Accepted: 02 Dec 2015.

<sup>1</sup>Michale E. Keeling Center for Comparative Medicine and Research, Department of Veterinary Sciences, The University of Texas MD Anderson Cancer Center, Bastrop, Texas

\*Corresponding author. Email: amanda.beck@einstein.yu.edu

†Current affiliation: Albert Einstein College of Medicine, Department of Pathology, Bronx, New York

housed in a shaded, temperature-regulated, indoor–outdoor enclosure with numerous barrels, perches, swings, and various feeding puzzles and substrates to mimic natural foraging and feeding behaviors. Standard monkey chow, unlimited drinking water, and novel food enrichment items were provided daily.

This 1-y-old male rhesus macaque presented in February 2015 for extensive hemorrhage from a presumptive wound on the right aspect of the caudal dorsum that was approximately 3 cm in diameter. The macaque was sedated with ketamine (10 mg/kg IM), and blood was drawn for CBC and serum chemistry analysis. The physical exam was unremarkable except for mild dehydration, evident by mild skin tenting, and pale pink mucous membranes. Probing the circumscribed area of hemorrhage revealed a dermal mass with thick walls and trabecular inner architecture that did not extend into the underlying muscle or abdominal wall. Initial (day 0) serum chemistry abnormalities included panhypoproteinemia and mild azotemia, and hematology revealed a moderately severe anemia (Table 1). The anemia with panhypoproteinemia was consistent with hemorrhage, and the mild azotemia was presumed to be due to mild dehydration. Although neoplasia (primarily hemangioma or hemangiosarcoma) was considered to be a possibility based on the gross appearance of the mass, the initial tentative diagnosis was a traumatic wound, in light of the young age of the animal. The macaque was initially treated with penicillin G procaine (50,000 IU/kg SC daily for 5 d), meloxicam (0.2 mg/kg SC on the first day, then 0.1 mg/kg SC daily for 2 more days), systemic antibiotics and analgesics, topical sugar–iodine paste to support granulation tissue formation, and an absorbable compressed-gelatin sponge product to aid in hemostasis.

After several days of continued intermittent mild hemorrhage and lack of granulation tissue formation, neoplasia became the primary differential diagnosis. In addition to hemorrhage, the presence of schistocytes on blood-smear examination after day 6 (Table 1) was consistent with intravascular trauma to erythrocytes, further supportive of hemangioma or hemangiosarcoma. Despite a robust regenerative reticulocyte response (Table 1) and the macaque's bright and responsive demeanor and adequate skin color, the anemia had worsened on day 6 (Table 1). On day 7, the mass was surgically removed with approximately 1 cm margins and tension-relieving incisions parallel to the primary incision. At this time, 40 mL of whole blood from a compatible cross-matched donor was transfused to the macaque. Surgical anesthesia was achieved by induction with ketamine (10 mg/kg IM) followed by maintenance with isoflurane (1% to 2%) via endotracheal tube. Postoperatively, penicillin G procaine (50,000 IU/kg SC daily for 3 d) and meloxicam (0.2 mg/kg SC on the first day, then 0.1 mg/kg SC daily for 2 more days) were administered. Hemostasis was achieved, the surgical site appeared to be healing well, and the macaque was bright and alert with normal pink color in the skin of the face and mucous membranes. Three days after surgery, hematology revealed a markedly improved Hct of 28.8% (Table 1).

The mass was fixed in 10% buffered formalin, processed routinely for histologic sectioning, cut at 4  $\mu$ m, and then stained with hematoxylin and eosin. The dermis and underlying subcutis contained an unencapsulated, infiltrative neoplasm composed of plump spindlyloid neoplastic cells that dissected between and wrapped thick collagen trabeculae (Figure 1 A). Multifocally, the neoplastic cells formed variably sized blood-filled spaces and channels and, in more densely cellular and less well-differentiated

areas, neoplastic cells were arranged in short, haphazard streams and bundles or in sheets (Figure 1 B). Neoplastic cells were pleomorphic and had indistinct borders and moderate amounts of fibrillar amphophilic cytoplasm. Nuclei were round to oval, with finely stippled chromatin and generally a single distinct basophilic nucleolus. Anisocytosis and anisokaryosis were moderate, with occasional large multinucleated neoplastic cells, and mitoses ranged from 0 to 6 per high-power field. Multifocally, there were areas of hemorrhage and necrosis within the mass, as well as scattered hemosiderophages, lymphocytes, eosinophils and neutrophils. There was extensive ulceration of the surface of the neoplasm, with replacement by abundant serocellular necrotic debris admixed with hemorrhage and bacterial colonies. The histologic features of the mass were consistent with hemangiosarcoma.

Because the neoplasm extended to the lateral and deep margins of resection, a second surgery was performed approximately 6 d after the initial mass removal, to excise wider margins of approximately 2 cm. At this time, an additional 0.3-cm diameter, raised, blood-filled cutaneous nodule was noted adjacent to the original incision line and was excised. Numerous parallel tension-releasing incisions were again necessary. Surgical anesthesia again was achieved by induction with ketamine (10 mg/kg IM) followed by maintenance with isoflurane (1% to 2%) via endotracheal tube. Postoperatively, penicillin G procaine (50,000 IU/kg SC daily for 3 d) and meloxicam (0.2 mg/kg SC on the first day, then 0.1 mg/kg SC daily for 2 more days) were administered. The macaque again recovered well postoperatively. On histopathologic examination, all margins from the original mass were clean and unaffected, indicating complete excision. The newly submitted cutaneous mass was a hemangiosarcoma (with cellular features similar to the previously diagnosed tumor), and excision of this additional, smaller neoplasm appeared complete, with clean lateral and deep margins. Prior to surgery, ultrasonographic imaging had been performed on the abdominal organs but was inconclusive for evidence of visceral tumors.

About 1 w after the second resection, the macaque began to scratch occasionally at an area adjacent to the original incision site that was associated with very mild intermittent bleeding and was recognized to be a possible recurrence of the tumor. The macaque was provided extra environmental enrichment to deter picking and scratching at the incision, and he continued to be monitored closely in the hospital. He remained bright and alert with pink coloration and only very mild intermittent hemorrhage until 11 d after the second resection, when the macaque appeared acutely lethargic and pale with a moderate amount of blood noted in the cage. Euthanasia by intravenous injection of a pentobarbital and phenytoin solution while under deep ketamine sedation was elected at this time, in light of the poor prognosis associated with the presumptive diagnosis of hemangiosarcoma recurrence and dissemination.

A complete necropsy was performed after euthanasia. A 9.5-cm skin incision was present on the dorsal lumbar area, slightly to the right of midline, at the site of the previous cutaneous mass excisions. The caudal portion of the incision and the skin and tail caudal to the incision were covered in crusted blood. Along and adjacent to the incision line were 6 firm, red, hemorrhagic masses ranging in size from 0.5 to 1.0 cm in diameter (Figure 2 A). Removal of the skin in this area revealed numerous pink to red hemorrhagic masses (diameter,  $\leq$  1.5 cm) in the subcutaneous tissue and underlying muscle. In addition, there was

**Table 1.** Hematology and serum chemistry data from a 1-y-old rhesus macaque with disseminated hemangiosarcoma

Reference range	Analyte	Day 0	Day 6	Day 7	Day 10	Day 13
19–37	ALT, IU/L	16	101	No data	54	22
20–30	AST, IU/L	31	137	No data	41	37
144–338	LDH, IU/L	406	933	No data	533	493
155–464	Creatine kinase, IU/L	238	803	No data	127	186
14–22	BUN mg/dL	31	16	No data	15	16
6.5–7.3	Total protein, g/dL	4.8	5.2	No data	6.4	6.0
4.2–4.8	Albumin, g/dL	3.2	3.1	No data	3.5	3.4
2.1–2.7	Globulin, g/dL	1.6	2.1	No data	2.9	2.6
83–140	Iron, µg/dL	95	137	No data	21	54
6.6–15.5	WBC, 10 <sup>6</sup> /µL	9.30	12.58	9.35	13.93	5.62
0–0.05	Band neutrophils, × 10 <sup>3</sup> /µL	0	0.12	0	0	0
4.1–7.8	RBC, × 10 <sup>6</sup> /µL	3.10	1.99	2.21	3.57	3.76
11.5–14.0	Hgb, g/dL	7.2	4.7	5.5	8.6	8.7
34.8–55.2	Hct, %	22.8	16.6	18.8	28.8	30.1
63.7–86.9	MCV, fl%	73.5	83.4	85.1	80.7	80.1
19.1–27.7	MCH, pg	23.2	23.7	24.7	24.1	23.0
28.9–35.4	MCHC, g/dL%	31.6	28.3	29.3	29.9	28.9
10.9–15.3	RBC distribution width, %	15.2	21.9	23.4	20.1	16.9
	Anisocytosis	Marked	Moderate	Marked	NS	Marked
	Polychromasia	Mild	Moderate	Marked	Mild	Mild
	Poikilocytosis	NS	NS	1+	NS	2+
	Target cells	NS	1+	NS	1+	1+
	Hypochromasia	2+	1+	1+	1+	None
	Acanthocytes	None	None	Rare	None	None
	Schistocytes	None	1+	1+	Rare	1+
	Spherocytes	Rare	None	None	None	None
0–0.2	Relative reticulocytes, %	No data	2.6	9.2	2.1	No data
193–676	Platelets, × 10 <sup>3</sup> /µL	249	525	560	585	Adequate

On day 7, the macaque underwent surgical removal of the initial cutaneous tumor and whole-blood transfusion.

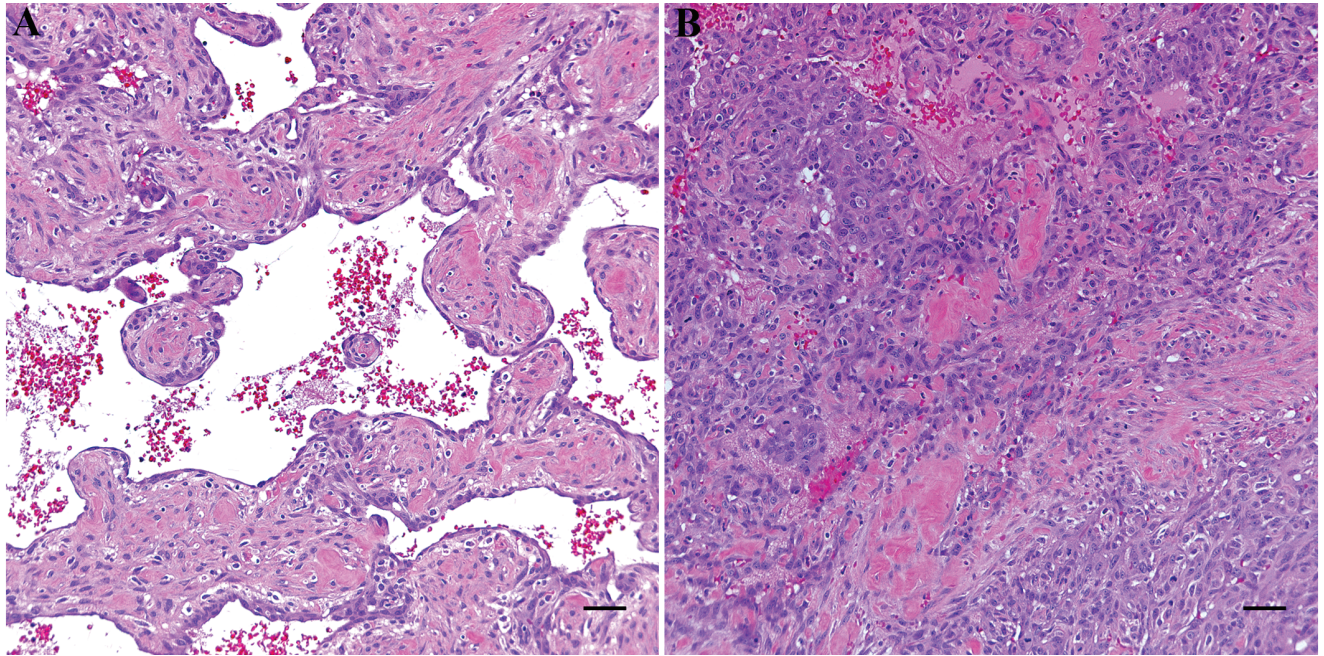
an intramuscular mass (diameter, 2 cm) on the caudal proximal aspect of the right thigh that, on cut surface, revealed multiple blood-filled spaces within the center. The dorsal abdominal wall contained multiple intramuscular masses, with the largest measuring 1.0 cm in diameter; these abdominal masses resembled those in the subcutaneous tissue and muscle.

Within the splenic parenchyma was a 0.3-cm pale nodule that was visible from the surface but did not protrude from the capsule and a second 0.7-cm hemorrhagic mass within the parenchyma that was not visible from the surface (Figure 2 B). The overall size of the spleen was normal. The right sublumbar lymph node was enlarged, and both kidneys were diffusely pale. Microscopic examination of the subcutaneous, intramuscular, and splenic masses revealed them all to be hemangiosarcomas with features as described earlier (Figure 2 C through F). The right sublumbar lymph node contained draining hemorrhage and hemosiderin but no evidence of metastasis. The majority of the kidney parenchyma was microscopically normal, and the pale color was attributed to anemia.

To further characterize the neoplastic cell population, we performed immunohistochemistry on the original cutaneous mass. As described earlier, this mass contained neoplastic cells that formed distinct channels (interpreted as more differentiated regions; Figure 3 A) and ones that were arranged in dense short

streams or sheets (interpreted as less differentiated areas). Immunohistochemistry was conducted on formalin-fixed, paraffin-embedded tissues, and 6 immunostains were used: vimentin (clone V9 monoclonal antibody, Ready-to-Use, Dako, Carpinteria, CA), factor-VIII-related antigen (FVIII-ra; polyclonal antibody, Ready-to-Use, Dako), CD31 (clone 1A10 monoclonal antibody, Ready-to-Use, Leica Biosystems, Buffalo Grove, IL), vascular endothelial growth factor (VEGF; 1:100; polyclonal antibody, Santa Cruz Biotechnology, Dallas, TX), Ki67 (1:300; clone MIB1 monoclonal antibody, Dako), and CD34 (clone QBEnd/10 monoclonal antibody, Ready-to-Use, Leica Biosystems). All sections were cut at 4 µm, and 3,3'-diaminobenzidine was used as a chromogen for all stains. Antigen-retrieval methods were used for 4 of the immunostains (vimentin [EnVision FLEX Target Retrieval Solution, low pH; Dako], FVIII-ra [proteinase K; Dako], CD31 [Bond Epitope Retrieval Solution 2, high pH; Leica Biosystems], and CD34 [Bond Epitope Retrieval Solution 2, high pH; Leica Biosystems]).

All neoplastic cells exhibited diffuse, strong, positive cytoplasmic staining for vimentin (Figure 3 B). The neoplastic cells that lined vascular channels exhibited strong positive staining for FVIII-ra, CD31 and VEGF, but the less-differentiated neoplastic cells arranged in sheets showed only sporadic and weaker staining. Positive staining for FVIII-ra was diffusely cytoplasmic as well as punctate in some cells (Figure 3 C), whereas positive



**Figure 1.** Histopathologic features of a dermal and subcutaneous mass on the dorsum of a 1-y-old rhesus macaque. (A) The dermis and subcutis contain an infiltrative neoplasm composed of spindlyoid neoplastic cells that wrap thick collagen bundles and multifocally form blood-filled channels. Hematoxylin and eosin stain; scale bar, 50  $\mu$ m. (B) In less well-differentiated areas, neoplastic cells are arranged in short, haphazard streams and sheets. Hematoxylin and eosin stain; scale bar, 50  $\mu$ m.

staining for CD31 was primarily membranous with less prominent cytoplasmic labeling (Figure 3 D), and positive staining for VEGF was cytoplasmic (Figure 3 E). Approximately 20% to 30% of neoplastic cells lining vascular channels exhibited strong, positive, nuclear staining for Ki67 (Figure 3 F), whereas approximately 50% to 60% of the neoplastic cells arranged in sheets exhibited strong, positive, nuclear Ki67 staining. All neoplastic cells were negative for CD34. Endothelial cells of nonneoplastic vessels (internal positive control) within the histologic sections labeled appropriately positively with vimentin, FVIII-ra, CD31, and VEGF.

## Discussion

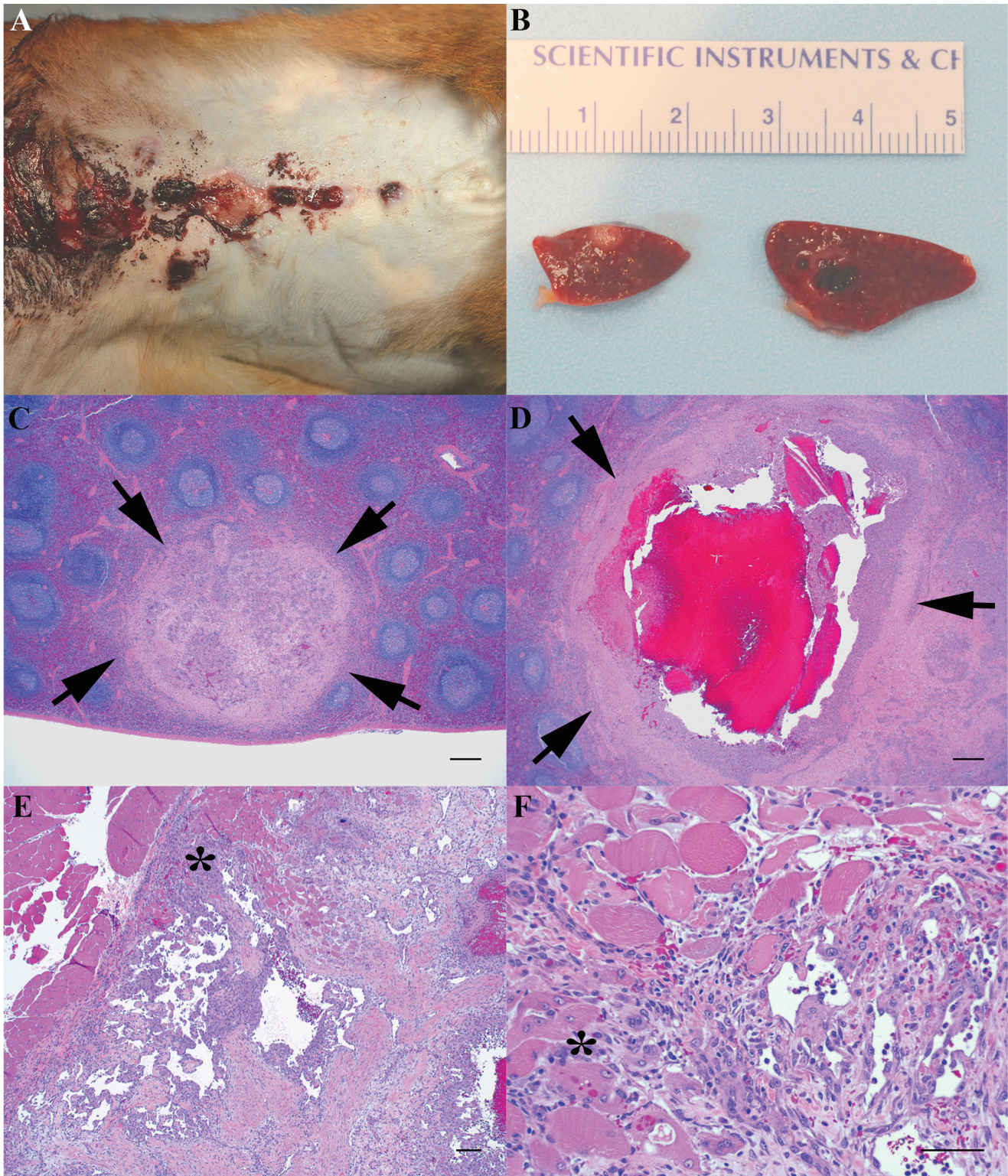
This report describes a case of spontaneous disseminated hemangiosarcoma in a 1-y-old rhesus macaque, the first of this lesion ever diagnosed at this facility. Reviewing the archives of pathology submissions (both biopsy and necropsy) of rhesus monkeys at our institution since 1975 revealed only 2 cases of hemangioma and no cases of hemangiosarcoma among 1728 submissions. The 2 hemangiomas occurred in adult rhesus monkeys, with one presenting in the liver and the other within the skin of the canthus of the eye. In the macaque described in the current report, we were unable to definitively determine the primary site of origin due to disseminated disease present at the time of diagnosis. The largest mass was the intramuscular hemangiosarcoma on the right thigh; however in other animal species, the spleen is more likely to be the primary site.<sup>23,25</sup>

Immunohistochemistry is often useful in the definitive diagnosis of vascular neoplasms in both humans and animals, particularly in less-differentiated tumors. Poorly differentiated hemangiosarcoma may form solid sheets of spindlyoid neoplastic cells without formation of characteristic vascular spaces, either diffusely or multifocally, thereby confusing the diagnosis of

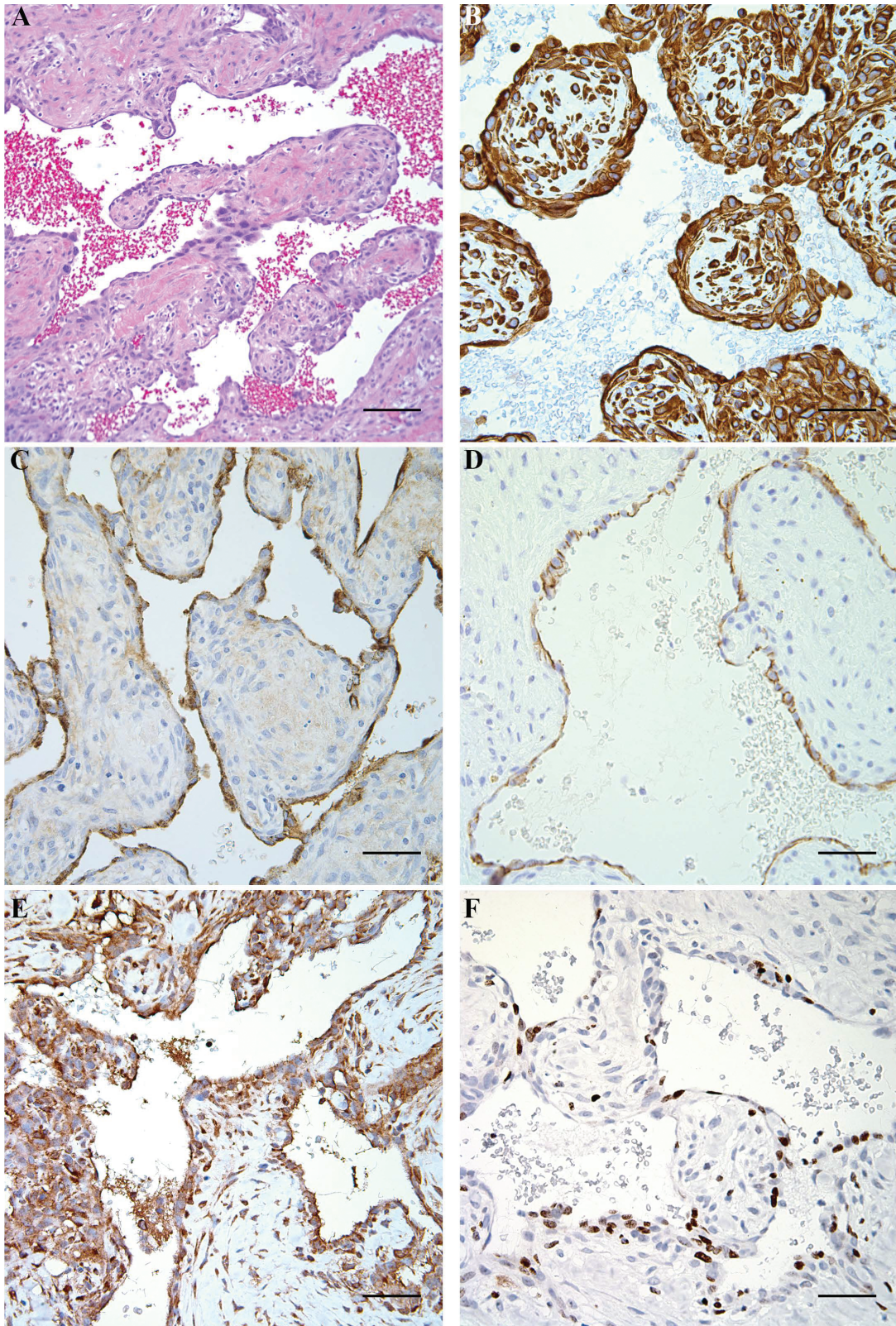
endothelial cell origin.<sup>10</sup> This was the case in the rhesus monkey described here: in many areas, the neoplastic cells formed diffuse sheets rather than well-defined vascular channels. To confirm the diagnosis of hemangiosarcoma and better characterize the neoplastic cells in this case, as well as evaluate the immunostaining properties in the reported rhesus macaque, immunohistochemistry was performed by using immunomarkers that have been well-established in the identification of neoplastic endothelial cells in humans.<sup>10,16</sup>

FVIII-ra is a glycoprotein that is synthesized by endothelial cells, platelets, and megakaryocytes and is stored in Weibel-Palade bodies in endothelial cells and in platelet  $\alpha$ -granules.<sup>10,18,19,29</sup> It is released by stimulated endothelial cells and mediates platelet adhesion to the walls of injured vessels.<sup>29</sup> FVIII-ra is used as an endothelial cell marker in many animal species and humans, although various limitations, such as variation in staining of normal endothelium of different tissues and inconsistent staining of malignant endothelial cells, have been noted.<sup>19,20</sup> The current case demonstrated strong, positive staining of neoplastic cells in well-differentiated regions of the tumor and sporadic, weak, positive staining of the poorly differentiated neoplastic cells in other areas of the mass.

CD31, also known as platelet endothelial cell adhesion molecule 1 (PECAM1), is a transmembrane glycoprotein found in large quantities on the surface of endothelial cells and less abundantly on platelets and leukocytes.<sup>10,18,29</sup> This protein has an important role in many cellular interactions, particularly in adhesion between endothelial cells and leukocytes during inflammation and between adjacent endothelial cells during angiogenesis.<sup>18,29</sup> CD31 is positively expressed in nearly all human vascular neoplasms.<sup>10</sup> As seen with FVIII-ra, the neoplasm described here exhibited strong positive staining in well-differentiated regions and weaker positive staining in less-differentiated areas.



**Figure 2.** Gross postmortem evaluation of a 1-y-old rhesus macaque revealed disseminated hemangiosarcoma. (A) The skin incision along the caudal dorsum is associated with multiple hemorrhagic cutaneous masses. (B) The spleen contains a 0.3-cm pale nodule and a 0.7-cm hemorrhagic mass. (C) The pale splenic nodule noted grossly and (D) the hemorrhagic splenic mass are histologically consistent with hemangiosarcoma. Arrows delineate the margins of the mass from adjacent normal splenic parenchyma. Hematoxylin and eosin stain; scale bar, 250  $\mu$ m. (E and F) The mass from the right thigh also is consistent with hemangiosarcoma, with muscular invasion by the neoplastic cells (\*). Hematoxylin and eosin stain; scale bar, 100  $\mu$ m (E), 50  $\mu$ m (F).



**Figure 3.** Immunohistochemical characterization of the initial presenting cutaneous mass diagnosed as a hemangiosarcoma. (A) Histologic appearance of a well-differentiated area of the hemangiosarcoma. Hematoxylin and eosin stain; scale bar, 100  $\mu$ m. (B) Vimentin immunohistochemistry. All neoplastic cells exhibit diffuse strong positive cytoplasmic staining. Scale bar, 50  $\mu$ m. (C through F) Neoplastic cells lining vascular channels exhibit strong positive immunostaining for (C) factor VIII-ra, (D) CD31, (E) VEGF, and (F) Ki67. Scale bar, 50  $\mu$ m.

CD34 is a commonly used diagnostic endothelial marker, although its *in vivo* function has not been fully determined.<sup>10,18</sup> CD34 is a transmembrane glycoprotein that is expressed in endothelial cells and hematopoietic stem cells, as well as nerves, hair follicles, muscle bundles, and sweat glands.<sup>2,10,18</sup> It is assumed to play a role in the formation of endothelial adherens junctions and to function as an adhesion molecule or cell-trafficking molecule for leukocytes and hematopoietic stem cells.<sup>2,10,18</sup> In diagnostic immunohistochemistry, CD34 is well known to label both endothelial cell neoplasms and nonvascular neoplasms.<sup>10</sup> The mass described here was diffusely negative for CD34 staining. In humans, CD34 positivity is seen in many cases of angiosarcoma, but typically only in regions with vascular channel formation.<sup>11,28</sup> Therefore, the utility of CD34 in making the diagnosis of angiosarcoma in poorly differentiated tumors composed primarily of solid sheets of neoplastic cells is limited and may at least partly explain the lack of positive staining in our macaque.<sup>28</sup> In addition, there have been reports of negative CD34 immunostaining in human patients with angiosarcoma.<sup>1,11</sup>

Other immunohistochemical markers have also been used to characterize vascular neoplasms and their prognosis. VEGF has an important role in promoting and regulating normal and abnormal angiogenesis, and VEGF mRNA is upregulated in many different types of human tumors.<sup>6,9,21</sup> Interestingly, human angiosarcomas have been found both to express the receptors for VEGF (VEGF-R1 and VEGF-R2) and to produce VEGF, creating a potential method of autocrine-mediated growth stimulation.<sup>6,9,21</sup> As with FVIII-ra and CD31, the neoplasm we described here exhibited strong positive staining in well-differentiated regions and weaker positive staining in less-differentiated areas. The Ki67 antibody recognizes nuclear proteins present in proliferating cells during all nonG0 phases of the cell cycle.<sup>16,24</sup> In humans, Ki67 has been used in the prognosis of a variety of vascular tumors (including breast hemangioma and hemangiosarcoma) and in the distinction between benign and malignant lesions on the premise that malignant lesions show significantly higher proliferative activity.<sup>16,24</sup> In the case presented here, Ki67 staining was more frequent in the less-differentiated parts of the lesion, consistent with the malignant histopathologic cellular features of the neoplasm.

In summary, this report describes a case of spontaneous disseminated hemangiosarcoma in a 1-y-old rhesus macaque with multiple tumors in the skin, subcutis, muscle, and spleen. The initial clinical presentation of this case allowed a presumptive diagnosis of hemangioma or hemangiosarcoma within a few days of presentation, on the basis of the physical exam, hematology and serum chemistry values, and gross appearance and behavior of the tumor. Specifically, the originally noted area of hemorrhage was associated with a ruptured hollow cutaneous mass and was accompanied by anemia and panhypoproteinemia due to blood loss. The lack of appropriate clotting (despite adequate platelet counts) and absence of granulation tissue formation after initial presentation was inconsistent with the behavior expected of a traumatic wound, and mild but continued hemorrhage resulted in a severe anemia, although the animal appeared bright, alert, and responsive. Excessive bleeding from cutaneous tumor sites also was noted in a 4-y-old rhesus macaque with spontaneous epithelioid hemangiosarcoma.<sup>28</sup> In addition to the chronic hemorrhage in the current case, the presence of schistocytes provided evidence suggestive of concurrent intravascular erythrocyte trau-

ma, further supporting the presumptive diagnosis of hemangiosarcoma.

Given the lack of identifiable environmental risk factors for development of hemangiosarcoma (such as chronic exposure to UV rays) and the early age at presentation in this animal, the tumor in the present case may have arisen due to a genetic defect. Most human pediatric cases of primary cutaneous angiosarcoma are associated with rare preexisting genetic conditions, such as xeroderma pigmentosum, an autosomal recessive disease involving impaired repair mechanisms of UV radiation-induced DNA damage.<sup>5</sup> Very few human angiosarcomas have been analyzed cytogenetically, and various chromosomal aberrations have been detected.<sup>3,17,22,30</sup> In addition, most karyotype analyses of angiosarcomas have revealed complex chromosomal changes in both structure and number, with gains in chromosomes 8 and 20 and losses in chromosome 22 as the most commonly documented.<sup>3,11,17,22,30</sup> To our knowledge, cytogenetic analysis of rhesus hemangiosarcoma has not been reported, and no candidate gene or genomic analyses have been performed on this juvenile rhesus macaque to date. If additional cases of pediatric hemangiosarcoma arise in this rhesus macaque colony in the future, particularly in animals with shared kinship, the likelihood of a causative heritable genetic defect would rise considerably and would justify intensive genetic characterization, such as whole-exome sequencing. In addition, because a genetic component is possible, continued yearly monitoring of the dam, sire, and all full or partial siblings of the affected monkey will be performed, including physical exam, bloodwork, and ultrasonography of the abdominal viscera and heart.

To our knowledge, the current report describes the youngest case of hemangiosarcoma yet reported in rhesus macaques, although at least 2 other publications describe cases in young rhesus macaques.<sup>16,28</sup> The aggressiveness of the tumor in the current case, in addition to its immunohistochemical characterization, appear to be consistent with these previous reports in rhesus macaques as well as descriptions of angiosarcomas in human children.<sup>4,5</sup> Wide surgical resection of the initial cutaneous masses was attempted, because a previously reported case of subcutaneous hemangiosarcoma in an adult rhesus macaque as well as dermal and subcutaneous hemangiosarcomas in dogs and cats have been effectively managed in this manner.<sup>19</sup> However, this intervention was ultimately unsuccessful due to the disseminated nature of the tumor in this case.

## References

1. Aggerholm-Pedersen N, Baerentzen S, Holmberg Jorgensen JP, Safwat A. 2011. A rare case of CD30(+), radiation-induced cutaneous angiosarcoma misdiagnosed as T-cell lymphoma. *J Clin Oncol* 29:e362–e364.
2. Anthony PP, Ramani P. 1991. Endothelial markers in malignant vascular tumours of the liver: superiority of QB-END/10 over von Willebrand factor and Ulex europaeus agglutinin 1. *J Clin Pathol* 44:29–32.
3. Baumhoer D, Gunawan B, Becker H, Fuzesi L. 2005. Comparative genomic hybridization in 4 angiosarcomas of the female breast. *Gynecol Oncol* 97:348–352.
4. Deyrup AT, Miettinen M, North PE, Khoury JD, Tighiouart M, Spunt SL, Parham D, Weiss SW, Shehata BM. 2009. Angiosarcomas arising in the viscera and soft tissue of children and young adults: a clinicopathologic study of 15 cases. *Am J Surg Pathol* 33:264–269.
5. Deyrup AT, Miettinen M, North PE, Khoury JD, Tighiouart M, Spunt SL, Parham DM, Shehata BM, Weiss SW. 2011. Pediatric

- cutaneous angiosarcomas: a clinicopathologic study of 10 cases. *Am J Surg Pathol* **35**:70–75.
6. **Ferrara N, Davis-Smyth T.** 1997. The biology of vascular endothelial growth factor. *Endocr Rev* **18**:4–25.
  7. **Ginn P, Mansell J, Ranch P.** 2007. Vascular Neoplasms, p 102–105. In: Maxie MG editor. Jubb, Kennedy and Palmer's pathology of domestic animals 5th ed. Edinburgh (UK): Elsevier.
  8. **Gross TL, Ihrke PJ, Walder EJ, Affolter VK.** 2005. Skin diseases of the dog and cat: clinical and histopathologic diagnosis, 2nd ed. Ames (IA): Wiley–Blackwell.
  9. **Hashimoto M, Ohsawa M, Ohnishi A, Naka N, Hirota S, Kitamura Y, Aozasa K.** 1995. Expression of vascular endothelial growth factor and its receptor mRNA in angiosarcoma. *Lab Invest* **73**:859–863.
  10. **Jennings RN, Miller MA, Ramos-Vara JA.** 2012. Comparison of CD34, CD31, and factor VIII-related antigen immunohistochemical expression in feline vascular neoplasms and CD34 expression in feline nonvascular neoplasms. *Vet Pathol* **49**:532–537.
  11. **Kharkar V, Jadhav P, Thakkar V, Mahajan S, Khopkar U.** 2012. Primary cutaneous angiosarcoma of the nose. *Indian J Dermatol Venereol Leprol* **78**:496–497.
  12. **Lahat G, Dhuka AR, Hallevi H, Xiao L, Zou C, Smith KD, Phung TL, Pollock RE, Benjamin R, Hunt KK, Lazar AJ, Lev D.** 2010. Angiosarcoma: clinical and molecular insights. *Ann Surg* **251**:1098–1106.
  13. **Martin CB Jr, Misenhimer HR, Ramsey EM.** 1970. Ovarian tumors in rhesus monkeys (*Macaca mulatta*): report of 3 cases. *Lab Anim Care* **20**:686–692.
  14. **Maxie M, Robinson W.** 2007. Neoplastic and reactive diseases of the skin and mammary glands, p 746–781. In: Maxie MG editor. Jubb, Kennedy and Palmer's pathology of domestic animals 5th ed. Edinburgh (UK): Elsevier.
  15. **McLaughlin ER, Brown LF, Weiss SW, Mulliken JB, Perez-Atayde A, Arbiser JL.** 2000. VEGF and its receptors are expressed in a pediatric angiosarcoma in a patient with Aicardi's syndrome. *J Invest Dermatol* **114**:1209–1210.
  16. **Mejía AF, Gierbolini L, Jacob B, Westmoreland SV.** 2009. Pediatric hepatic hemangiosarcoma in a rhesus macaque (*Macaca mulatta*). *J Med Primatol* **38**:121–124.
  17. **Mertens F, Panagopoulos I, Mandahl N.** 2010. Genomic characteristics of soft tissue sarcomas. *Virchows Arch* **456**:129–139.
  18. **Muller AM, Hermanns MI, Skrzynski C, Nesslinger M, Muller KM, Kirkpatrick CJ.** 2002. Expression of the endothelial markers PECAM-1, vWf, and CD34 in vivo and in vitro. *Exp Mol Pathol* **72**:221–229.
  19. **Myers DD Jr, Dysko RC, Chrisp CE, Decoster JL.** 2001. Subcutaneous hemangiosarcomas in a rhesus macaque (*Macaca mulatta*). *J Med Primatol* **30**:127–130.
  20. **Ordóñez NG, Batsakis JG.** 1984. Comparison of Ulex europaeus I lectin and factor VIII-related antigen in vascular lesions. *Arch Pathol Lab Med* **108**:129–132.
  21. **Rathmell WK, Acs G, Simon MC, Vaughn DJ.** 2004. HIF transcription factor expression and induction of hypoxic response genes in a retroperitoneal angiosarcoma. *Anticancer Res* **24**:167–169.
  22. **Schuborg C, Mertens F, Rydholm A, Brosjo O, Dictor M, Mitelman F, Mandahl N.** 1998. Cytogenetic analysis of 4 angiosarcomas from deep and superficial soft tissue. *Cancer Genet Cytogenet* **100**:52–56.
  23. **Schultheiss PC.** 2004. A retrospective study of visceral and nonvisceral hemangiosarcoma and hemangiomas in domestic animals. *J Vet Diagn Invest* **16**:522–526.
  24. **Shin SJ, Lesser M, Rosen PP.** 2007. Hemangiomas and angiosarcomas of the breast: diagnostic utility of cell cycle markers with emphasis on Ki-67. *Arch Pathol Lab Med* **131**:538–544.
  25. **Smith AN.** 2003. Hemangiosarcoma in dogs and cats. *Vet Clin North Am Small Anim Pract* **33**:533–552 [vi.].
  26. **Southwood LL, Schott HC 2nd, Henry CJ, Kennedy FA, Hines MT, Geor RJ, Hassel DM.** 2000. Disseminated hemangiosarcoma in the horse: 35 cases. *J Vet Intern Med* **14**:105–109.
  27. **Stock ML, Smith BI, Engiles JB.** 2011. Disseminated hemangiosarcoma in a cow. *Can Vet J* **52**:409–413.
  28. **Tsuchiya T, Gray TL, Gatto NT, Forest T, Machotka SV, Troth SP, Prahallada S.** 2014. Spontaneous epithelioid hemangiosarcoma in a rhesus monkey (*Macaca mulatta*). *Comp Med* **64**:309–313.
  29. **Wang D, Stockard CR, Harkins L, Lott P, Salih C, Yuan K, Buchsbaum D, Hashim A, Zayzafoon M, Hardy R, Hameed O, Grizzle W, Siegal GP.** 2009. Immunohistochemistry in the evaluation of neovascularization in tumor xenografts. *Biotech Histochem* **83**:179–189.
  30. **Xu L, Zhang Y, Zhao H, Chen Q, Ma W, Li L.** 2015. Well-differentiated angiosarcoma of spleen: a teaching case mimicking hemangioma and cytogenetic analysis with array comparative genomic hybridization. *World J Surg Oncol* **13**:300.