

*Short report*

## Exercise-induced pain, stiffness, and tubular aggregation in skeletal muscle

ROGER A BRUMBACK, R DENNIS STATON,  
AND MARSHA E SUSAG

*From the Neurology and Psychiatry Service and Neuromuscular Pathology Laboratory, Veterans Administration Medical Center and Department of Neuroscience School of Medicine, University of North Dakota, Fargo, North Dakota*

**SUMMARY** The case is described of a 36 year old man with exercise-induced pain, stiffness, and tubular aggregation in skeletal muscle. Persistent CPK elevation and a normal forearm ischaemic exercise test were demonstrated. Electromyography was normal. Muscle biopsy showed aggregates of tubular structures in most fibres by histochemical and ultrastructural analysis. A relationship of this syndrome to known defects in muscle energy metabolism is postulated.

Two diseases of exercise-induced muscle pain and stiffness have defined metabolic defects (myophosphorylase deficiency and phosphofructokinase deficiency).<sup>1-6</sup> In both of these conditions, painful muscle stiffness and cramping follow repeated muscle contraction. In each disease there is: (1) reduced muscle lactate production with exercise (forearm ischaemic exercise test); (2) elevated serum CPK at rest, with further elevation following exercise; (3) markedly reduced muscle fibre anaerobic glycolysis; and (4) tubular aggregation associated with marked degeneration of type-II muscle fibres.<sup>1 7-10</sup> Iodoacetate inhibition of the glycolytic enzyme glyceraldehyde-3-phosphate dehydrogenase produces similar findings in experimental animals.<sup>11 12</sup>

Other less well-defined defects in muscle glycolytic enzyme systems, associated with exercise-induced pain, have been described.<sup>13-19</sup> We report a case of a syndrome first described by Morgan-Hughes *et al*<sup>20</sup> in which exercise-induced muscle pain is associated with tubular aggregates in affected muscle fibres.

### Case report

A 36 year old white male, was studied for exercise-induced muscle pain and stiffness. His birth and early

Address for reprint requests: Dr Roger A Brumback, VA Medical Center, Fargo, North Dakota 58102, USA.

Accepted 22 October 1980

development were normal. He was active in athletics throughout his school years. His symptoms began insidiously at about age 20 years, when he noted calf pain and stiffness with walking (particularly after prolonged Marine Corps guard duty). Initially, this pain and stiffness would disappear after a brief rest. Over the next several years pain and stiffness occurred with lesser degrees of activity, involved all the lower extremity musculature and resolved more slowly with rest (sometimes requiring up to 36 hours for resolution). By age 23 years he was experiencing symptoms in legs, hips, arms, back and neck. During the next 13 years he experienced progressively worsening pain and stiffness with exercise and marked reduction in his exercise tolerance. By age 30 years he would develop severe back and leg pain and stiffness after walking only one to two blocks. Standing for 15–20 minutes would result in back pain and stiffness. During the two years prior to our study he experienced pain and stiffness with such activities as walking up a flight of stairs or writing a single page. For three months he took occasional small doses of aspirin and diazepam, but took no medication for the four months prior to his initial evaluation and first muscle biopsy. He did not experience fasciculations or tremors. He had no pigmenturia. He had no alcoholic intake. There was no family history of neuromuscular disease.

General and neurological examination was normal except for a mild genu varus deformity bilaterally. His muscles were firm and non-tender to palpation. No percussion myotonia was elicited. There was no muscle weakness. Multiple investigations were normal, including: serum electrolytes, serum calcium, urinary creatinine clearance, serum total protein and protein

electrophoresis, rheumatoid factor, fluorescent anti-nuclear antibody, cryoglobulins, serum thyroxine, serum alkaline phosphatase, SGOT, SGPT, and LDH. Examination of a 24-hour urine collection for uroporphyrins, coproporphyrins, porphobilinogens and urobilinogens was normal. There was persistent serum CPK elevation of  $1\frac{1}{2}$  times normal at rest, with further increase of serum CK to twice normal after exercise. During a glucose tolerance test, his blood sugar rose to 102 mg/dl from a fasting level of 92 mg/dl, while his serum potassium did not significantly change from the fasting value of 4.0 mEq/l. With the forearm ischaemic exercise test,<sup>6,8</sup> the patient developed no stiffness or cramp after 90 seconds of exercise and the serum lactate rose normally from a pre-exercise level of 8.7 mg/dl to 20.3 mg/dl three minutes post-exercise. Potassium loading produced no symptoms. Electromyography of the deltoid, biceps brachii, rectus femoris, and gastrocnemius was normal.

#### Muscle pathology

Muscle biopsies were obtained (on two occasions one year apart) under local anaesthesia from the left

biceps brachii muscles. Muscle specimens were fresh-frozen for histochemistry (fig 1) or fixed in glutaraldehyde for electron microscopy (fig 2). In the sections stained with the modified Gomori trichrome stain, over 25% of the muscle fibres in any particular cross section contained bright red staining subsarcolemmal material. With serial sectioning, it was possible to demonstrate involvement of different fibres at different levels. This same accumulated material stained basophilic with haematoxylin and eosin. A rare degenerating fibre or small angular fibre was evident. The abnormal accumulations also stained dark blue-black in sections stained with adenylate deaminase,<sup>21</sup> Sudan black B, toluidine blue, glyceraldehyde-3-phosphate dehydrogenase-tetrazolium reductase, DPNH-tetrazolium reductase, TPNH-tetrazolium reductase, and menadione-linked alpha-glycerophosphate dehydrogenase. The accumulations were reddish with the periodic acid-Schiff (PAS) stain and maintained PAS-positive staining after diastase digestion. The accumulations were stained reddish-orange with the non-specific esterase. With SDH-tetrazolium reductase, alizarin red-S, phosphorylase, alkaline phosphata-

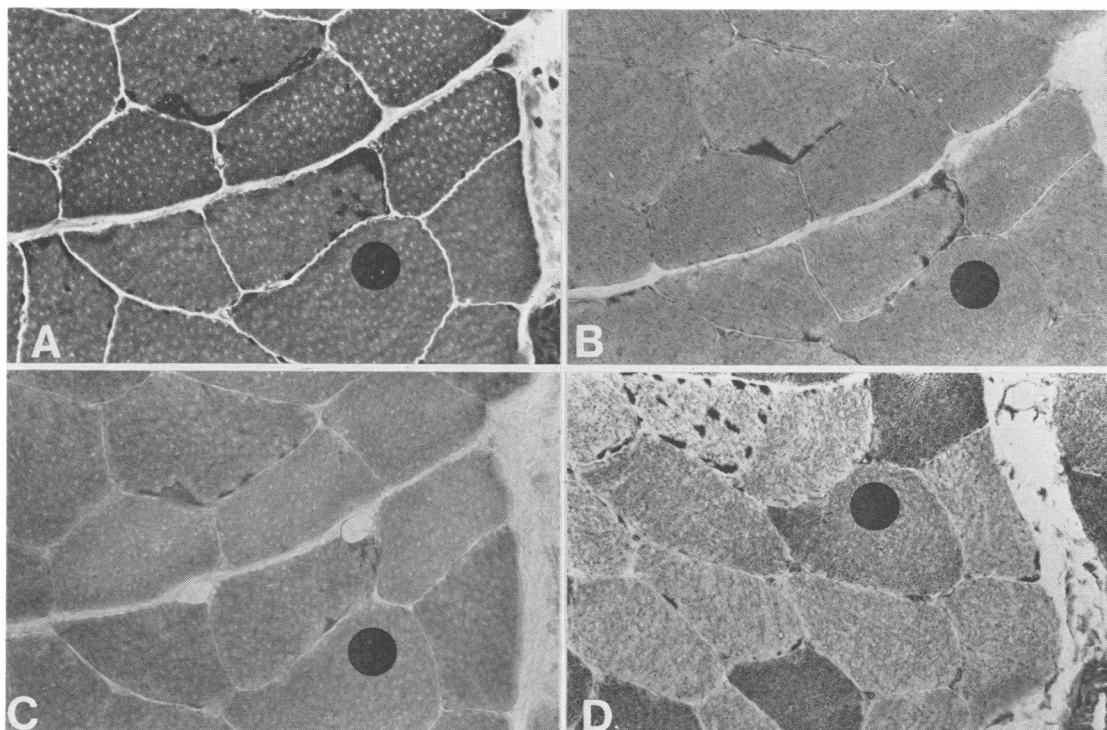
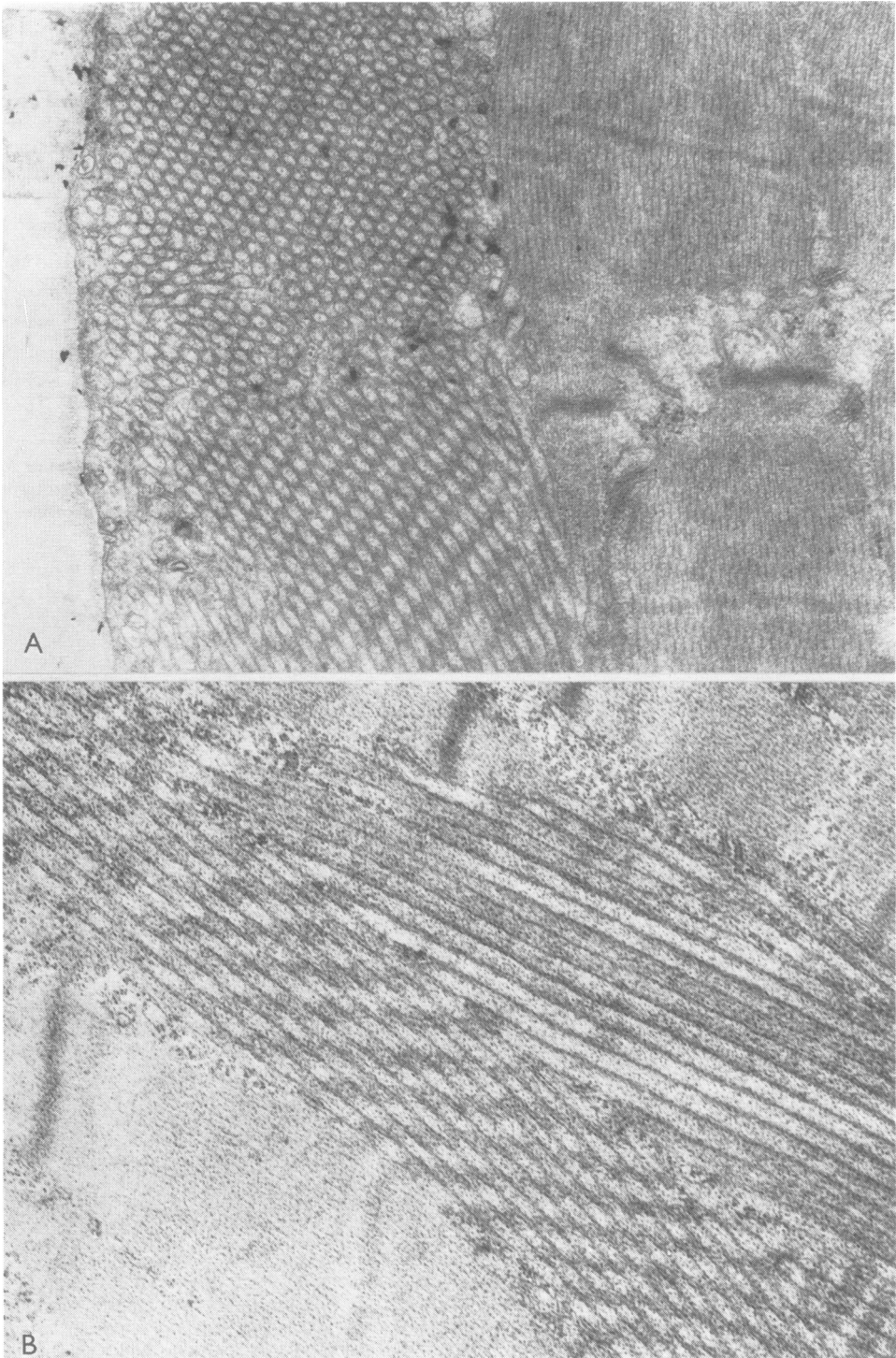


Fig 1 Low power photomicrographs of serial sections of left vastus lateralis muscle biopsy showing subsarcolemmal tubular aggregates (dot marks same fibre in each section). Note involvement of different fibres and different parts of same fibre at different levels.  $\times 240$ . A. Reddish staining of tubular aggregates with modified Gomori trichrome. B. Dark blue-black stained tubular aggregates with adenylate deaminase. C. Purple-black staining of tubular aggregates with menadione-linked alpha-glycerophosphate dehydrogenase. D. Dark blue-black staining of tubular aggregates with DPNH-TR.



**Fig 2** Electron microscopic photographs of subsarcolemmal tubular aggregates from left vastus lateralis muscle biopsy. A.  $\times 7700$ ; B.  $\times 13\,000$ .

tase, and acid phosphatase the muscle fibres stained normally with no evidence of the accumulations. With both alkaline (pH 9.4) and acid-preincubated (pH 4.3) myofibrillar ATPase stains, the accumulations were identifiable as unsustained subsarcolemmal holes in type-II muscle fibres only.

Ultrastructural study (fig 2) revealed aggregates of tubular structures situated immediately beneath the plasma membrane. Tubules in these aggregates were randomly oriented. Tubules cut in cross-section contained a core of amorphous material surrounded by an inner membrane.

### Discussion

Our patient and two previously described patients<sup>20, 22</sup> have presented with: (1) normal ischaemic lactate production with exercise-induced muscle pain and stiffness; (2) mildly elevated serum CPK; and (3) tubular aggregation in type-II muscle fibres with little histologically-evident muscle fibre degeneration. The tubular aggregates that have been reported as incidental findings in porphyria, periodic paralysis, and myotonic dystrophy<sup>23</sup> appear relatively empty in cross-section under electron microscopy. In contrast, the tubular aggregates in our patient (fig 2) and reported by Morgan-Hughes (personal communication) contain an electron dense core.

We suggest that patients with this syndrome have a defect of skeletal muscle energy metabolism which causes type-II fibre tubular aggregation but does not destroy these fibres (as occurs with the tubular aggregation in myophosphorylase deficiency and phosphofructokinase deficiency). Biochemical study of such patients should reveal a defect of energy metabolism which causes less severe impairment of cellular function than does deficient activity of myophosphorylase, phosphofructokinase, or glyceraldehyde-3-phosphate dehydrogenase. Many different categories and degrees of muscle glucose/glycogen metabolic disturbance may exist, all characterised by the triad of exercise-induced stiffness, muscle pain, and tubular aggregation with varying degrees of associated muscle fibre degeneration and CPK elevation.

R W Leech, T P Freeman, and Ms Susan McKay provided valuable assistance. This study was supported by the Veterans Administration.

### References

- Rowland LP. Glycogen-storage diseases of muscle. In: Goldensohn ES, Appel SH, ed. *Scientific Approaches to Clinical Neurology*, Philadelphia: Lea and Febiger, 1977: 1692-1714.
- Layzer RB, Rowland LP, Ranney HM. Muscle phosphofructokinase deficiency. *Archiv Neurol (Chicago)* 1967; **16**:455.
- Tarui S, Okuna G, Ikura Y, Tanaka T, Suda M, Nishikawa M. Phosphofructokinase deficiency in skeletal muscle. A new type of glycogenosis. *Biochem Biophys Res Commun* 1965; **19**:517-23.
- Pearson CM, Rimer D, Mommaerts WFHM. A metabolic myopathy due to absence of muscle phosphorylase. *Amer J Med* 1961; **30**:502.
- Schmid R, Mahler R. Chronic progressive myopathy with myoglobinuria. Demonstration of a glycogenolytic defect in the muscle. *J Clin Invest* 1959; **38**:2044.
- McArdle B. Myopathy due to defect in muscle glycogen breakdown. *Clin Sci* 1951; **10**:13-35.
- Brooks BR, Brumback RA, Rosenbaum RB, Engel WK. Triglyceride-mediated prevention of exercise-induced rhabdomyolysis in myophosphorylase deficiency. *Neurology (Minneapolis)* 1977; **27**:379.
- Kula RW, Brumback RA, Engel WK, Line BR. Ischemic contracture in muscle phosphorylase deficiency: Clinical scanning and histochemical and auto-radiographic studies. *Neurology (Minneapolis)* 1977; **27**:401-2.
- Korenyi-Both A, Smith BH, Baruah JK, McArdle's syndrome. Fine structural changes in muscle. *Acta Neuropathol (Berl)* 1977; **40**:11-19.
- Bertorini TE, Brumback RA, Kula RW, Engel WK. Electrophysiologic and histochemical observation in five patients with muscle phosphorylase deficiency (MPD). *Transact Am Neurol Assoc* 1977; **102**:141-2.
- Brumback RA, Kula RW, Engel WK. A model of defects in muscle glycogenolysis/glycolysis (GG/Gly). *J Neuropath Exp Neurol* 1977; **36**: 596.
- Brumback RA, Susag ME, Gerst JW. Animal model of human disease: Defective skeletal muscle glucose and/or glycogen metabolism. *Am J Pathol* 1980; **101**:241-4.
- Satoyoshi E, Kowa H. A myopathy due to glycolytic abnormality. *Archiv Neurol (Chicago)* 1967; **17**:248.
- Strugalska-Cynowska M. Disturbances in the activity of phosphorylase-b-kinase in a case of McArdle myopathy. *Folia Histochem Cytochem (Krakow)* 1967; **5**:151.
- Thomson WHS, McLaurin JC, Prineas JW. Skeletal muscle glycogenosis: An investigation of two dissimilar cases. *J Neurol Neurosurg Psychiatry* 1963; **26**:60.
- Holmes JM, Houghton CR, Woolf AL. A myopathy presenting in adult life with features suggestive of glycogen storage disease. *J Neurol Neurosurg Psychiatry* 1960; **23**:302.
- Olivier L, Schulman K, Larner J. Myopathy associated with glycogen deposition resulting from generalized lack of amylo-1, 6-glucosidase. *J Clin Res* 1961; **9**:243.

- 18 Mrozek K, Niebroj-Dobosz I, Lazarowicz J. Miopatia glikogenowa z prawdopodobnym niedoborem fosfoheksoizomerazy. *Neur Neurochir Pol T VII* 1973; **23**:267-71.
- 19 Karpati G, Carpenter S, Wolfe LS, Sherwin A. A peculiar polysaccharide accumulation in muscle in a case of cardioskeletal myopathy. *Neurology (Minneapolis)* 1960; **19**:553.
- 20 Morgan-Hughes JA, Mair WGP, Lascelles PT. A disorder of skeletal muscle associated with tubular aggregates. *Brain* 1970; **93**:873-80.
- 21 Fishbein WN, Armbrustmacher VW, Griffin JL. Myoadenylate deaminase deficiency: A new disease of muscle. *Science* 1978; **200**:545-8.
- 22 Lewis PD, Pallis C, Pearse AGE. "Myopathy" with tubular aggregates. *J Neurol Sci* 1971; **13**:381-8.
- 23 Engel WK, Bishop DW, Cunningham GG. Tubular aggregates in type-II muscle fibres: Ultrastructural and histochemical correlation. *J Ultrastruct Res* 1970; **31**:507-25.