

Retrocaval Ureter in Children: A Report of Eight Cases

J-S Sun¹, G Zhang¹, T Lin²

ABSTRACT

Objective: The aim of this study is to report on our last nine years' experience in the diagnosis and treatment of retrocaval ureter.

Methods: Eight patients with retrocaval ureter were reviewed. Intravenous urography and retrograde pyelography were used for confirming the diagnosis. All of the patients had undergone surgery, one case being done laparoscopically. The mean age of the patients was 9.2 years (range 2 to 13 years).

Results: Five patients were boys and three were girls. The clinical manifestations were right flank pain in three (37.5%), gross haematuria in one (12.5%), and urinary tract infection in one (12.5%). Three asymptomatic patients were diagnosed by routine physical examination. All of the patients had Type 2 and right-sided retrocaval ureter. Associated anomalies were seen in none of the patients. Retrocaval ureter is a rare anomaly in the paediatric age group.

Conclusion: Laparoscopy is a promising method to repair the retrocaval ureter.

Keywords: Children, retrocaval ureter

Uréter Retrocavo en Niños: Reporte de Ocho Casos

J-S Sun¹, G Zhang¹, T Lin²

RESUMEN

Objetivo: El objetivo de este estudio es reportar nuestra experiencia sobre el diagnóstico y tratamiento del uréter retrocavo en los nueve últimos años.

Métodos: Se examinaron ocho pacientes con uréter retrocavo. A fin de confirmar el diagnóstico, se usaron la urografía intravenosa y la pielografía retrógrada. Todos los pacientes habían sido intervenidos quirúrgicamente, y una de las intervenciones fue realizada mediante laparoscopia. La edad promedio de los pacientes fue de 9.2 años (rango de 2 a 13 años).

Resultados: Cinco pacientes eran varones y tres eran niñas. Las manifestaciones clínicas fueron: dolor en el flanco derecho en tres (37.5%), hematuria macroscópica en uno (12.5%), e infección urinaria en uno (12.5%). Tres pacientes asintomáticos fueron diagnosticados mediante examen físico de rutina. Todos los pacientes tenían uréter retrocavo derecho tipo 2. No se observaron anomalías asociadas en ninguno de los pacientes. El uréter retrocavo es una anomalía rara en el grupo de edad pediátrica.

Conclusión: La laparoscopia es un método prometedor para la reparación del uréter retrocavo.

Palabras claves: Niños, uréter retrocavo

West Indian Med J 2015; 64 (4): 397

INTRODUCTION

Retrocaval ureter is a rare congenital abnormality in association with upper urinary tract obstruction and usually has an

S-shape or fishhook appearance on intravenous urography (IVU) that is due to the passage of the ureter posterior to the inferior vena cava (IVC). Retrocaval ureter occurs in 1 in 1000 population (1). The aetiology is mostly due to abnormal persistence of the right subcardinal vein positioned ventral to the ureter in the definitive IVC (2, 3). Although individuals with this anomaly usually present in the third to fourth decade of life, symptomatic patients in the paediatric age group have also been reported (1, 4).

From: ¹Department of Pediatric Surgery, Affiliated Hospital of Jining Medical University, 79 Gu Huai Road, Jining 272000, People's Republic of China and ²Department of Pediatric Urology, Children's Hospital of Chongqing Medical University, 136 Zhongshan 2nd Road, Yuzhong District, Chongqing 400014, People's Republic of China.

Correspondence: Dr T Lin, Department of Pediatric Urology, Children's Hospital of Chongqing Medical University, 136 Zhongshan 2nd Road, Yuzhong District, Chongqing 400014, China. E-mail: taolindoc@163.com

CASE REPORTS

Medical records of eight patients with retrocaval ureter who had been treated in Chongqing Children's Hospital between January 2000 and November 2008 were reviewed. The definite diagnosis was made by IVU (Fig. 1), computed tomography [CT] (Fig. 2) and retrograde pyelography. The type of the retrocaval ureter was identified according to the classification by Bateson and Atkinson (5). Intravenous urography had been performed for all patients 12 months postoperatively, as well. Age, gender, hospital stay, treatment modality, treatment outcome and associated anomalies were collected from the patients' data sheets.

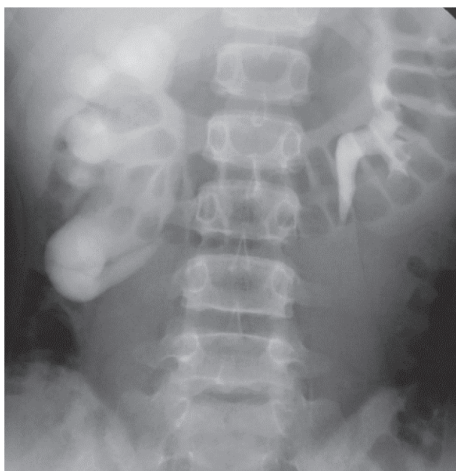

Fig. 1: Intravenous urogram shows right-sided hydronephrosis and dilatation of the proximal ureter up to the level of the transverse process of L3–L4.

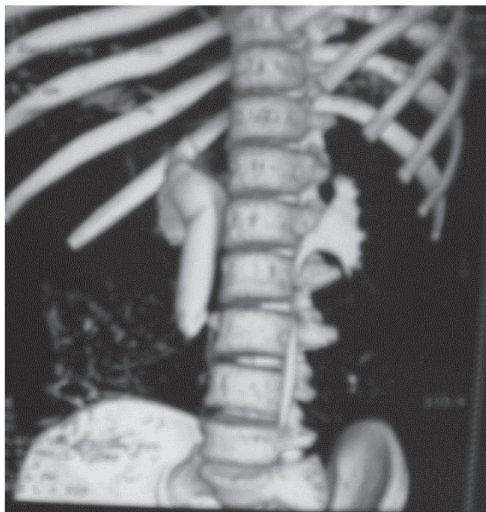


Fig. 2: Abdominal computed tomography (CT) reveals right-sided hydronephrosis and dilatation of the proximal ureter.

A total of eight patients had retrocaval ureter. The median age of the patients was 9.2 years (range 2 to 13 years). Five patients (62.5%) were boys and three (37.5%) were girls. The reason for seeking treatment was right flank pain in three (37.5%), gross haematuria in one (12.5%) and urinary tract infection in one (12.5%). Three asymptomatic patients were diagnosed by routine physical examination. The retrocaval ureter was Type 2 and right-sided in all of the patients.

End-to-end ureteroureterostomy through an extraperitoneal incision at the 12th rib was performed in all patients (Fig. 3). On the follow-up IVU performed six months postoperatively, there were no remarkable findings and no complication occurred during the follow-up.

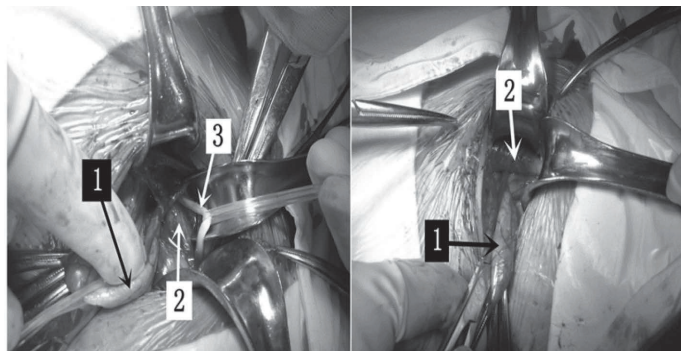


Fig. 3: Intraoperative photograph showing dilated pelvis and proximal ureter (1) with the proximal ureter curving medially and then passing behind the inferior vena cava (2); (3) indicates distal normal ureter.

DISCUSSION

Retrocaval ureter, also called circumcaval ureter, is a rare congenital abnormality in association with upper urinary tract obstruction. There is a male to female ratio of 3:1 (1). It occurs more commonly on the right side than the left side and is usually associated with other IVC anomalies (2, 3). Common presentations are abdominal pain in the right lumbar region, recurrent urinary tract infection and haematuria (6, 7).

Retrocaval ureter can be classified into two types based on radiologic appearance (7). In the Type 1 variant (high loop), the renal pelvis and upper ureter lie horizontally or very nearly so, so the retrocaval segment of the ureter is on the same level as the renal pelvis and retrograde pyelogram of this type shows the appearance of an inverted J appearance. In Type 2 retrocaval ureter (low loop), the dilated upper ureter is seen to descend from the renal pelvis and then curve upward and medially, forming a reversed J appearance on intravenous pyelogram. Retrograde pyelogram of the Type 2 variant shows an S-shaped outline. The level of retrocaval segment was most frequently at the third lumbar vertebrae. These eight patients are all of this type.

With the advances in urologic laparoscopic surgery, surgical correction has been attempted by these minimally invasive approaches. These anomalies have been managed by transperitoneal and retroperitoneoscopic laparoscopy. Ramalingam and Selvarajan (7) found that transperitoneal intracorporeal suturing was less time-consuming and relatively easier than retroperitoneoscopic suturing. We believe that transperitoneal laparoscopic management is a safer, easier and less time-consuming technique.

In symptomatic cases, surgical intervention should be performed and renal function should improve after the operation. Laparoscopy is a promising method to repair the retrocaval ureter.

CONFLICT OF INTEREST

All authors have no conflict of interest regarding this paper.

REFERENCES

1. Soundappan SV, Barker AP. Retrocaval ureter in children: a report of two cases. *Pediatric Surg Int* 2004; **20**: 158–60.
2. Ishitoya S, Arai Y, Waki K, Okubo K, Suzuki Y. Left retrocaval ureter associated with the Goldenhar syndrome (brachial arch syndrome). *J Urol* 1997; **158**: 572–3.
3. Rubinstein I, Cavalcanti AG, Canalini AF, Freitas MA, Accioly PM. Left retrocaval ureter associated with IVC duplication. *J Urol* 1999; **162**: 1373–4.
4. Acharya SK, Jindal B, Yadav DK, Singha S, Bagga D. Retrocaval ureter: a rare cause of hydronephrosis in children. *J Pediatr Surg* 2009; **44**: 846–8.
5. Bateson EM, Atkinson D. Circumcaval ureter: a new classification. *Clin Radiol* 1969; **20**: 173–7.
6. Brito RR, Zulian R, Albuquerque J, Borges HJ. Retrocaval ureter. *Br J Urol* 1973; **45**: 144–52.
7. Ramalingam M, Selvarajan K. Laparoscopic transperitoneal repair of retrocaval ureter: report of two cases. *J Endourol* 2003; **17**: 85–7.