

*Short report*

## Cortical deafness in multiple sclerosis

T TABIRA, S TSUJI, T NAGASHIMA, T NAKAJIMA,\*  
AND Y KUROIWA

*From the Department of Neurology, Neurological Institute, and the Department of Otorhinolaryngology,\* Kyushu University, Fukuoka, Japan.*

**SUMMARY** Cortical deafness in a patient with multiple sclerosis is reported. Complete recovery from total deafness was seen following stages of auditory agnosia and pure word deafness. The otological and neurophysiological studies suggested lesions in subcortical white matter. This report stresses the rarity of the condition, its subcortical origin and good prognosis.

Cortical deafness is a rare condition, seen in patients with bilateral temporal lobe lesions.<sup>1</sup> In multiple sclerosis (MS) deafness due to lesions at the lower levels of the auditory pathway is seen in a few per cent<sup>2,3</sup> and audiometric examination increases the incidence.<sup>4,5</sup> Cortical deafness, however, is rarely observed.<sup>3</sup> This report concerns a case of MS with transient cortical deafness and describes the results of otological and neurophysiological studies and its natural course. A preliminary report was published elsewhere.<sup>6</sup>

### Case report

A 29-year-old right handed man had an acute onset in March, 1977, of numbness on the right side of the body below the neck without any previous symptoms, followed by quadriplegia with some diplopia in April. He was admitted first to Kyushu University Hospital, when neurological examination revealed horizontal nystagmus on lateral gaze, positive Lhermitte's sign, marked quadriplegia with increased knee and ankle jerks, Babinski signs, and some sensory impairment below the level of C5. Cerebrospinal fluid (CSF) contained 0.635 g/l total protein (normal range 0.1-0.4 g/l), 0.108 g/l IgG (0.005-0.045 g/l), IgG ratio 1.6 (less than 1.5), and 11 lymphocytes (less than 5) mm<sup>-3</sup>. Other laboratory data, EEG and CT scan were normal. A diagnosis of acute disseminated encephalomyelitis was made, and corticosteroids were given; the patient recovered.

The second relapse followed a common cold in August, 1977, when he complained ataxic gait, weakness of the left limbs, and acute loss of vision in the right eye. On admission, the abnormal neurological findings were euphoric mental state, marked impairment of vision with central scotoma bilaterally, more on the right, mild left hemiparesis including the face with positive pyramidal signs, mild hyperalgesia on the left, and mild gait ataxia. Routine laboratory examinations were normal except for a mild leukocytosis in the peripheral blood. The CSF showed marked pleocytosis (78 lymphocytes/cmm), and contained increased total protein (0.56 g/l), IgG (0.104 g/l) and IgG ratio (1.9). Oligoclonal immunoglobulin bands were not found. Complement fixation and haemagglutination inhibition antibodies against measles and rubella were normal. The EEG was abnormal, with disorganised background activity with excessive diffuse slow waves more in the right and continuous localised irregular delta waves in the right temporal region. CT scan showed a transient low density area in the right parietotemporal region. Corticosteroids were given and the symptoms and signs gradually improved. However, during the course of convalescence he had a generalised convulsion on October 28, 1977. He had another generalised convulsion in April, 1978 but no other symptoms recurred. He was discharged in May with slight dementia and visual impairment (Vd=0.03 X-5.0 D, Vs=0.1 X-3.0 D), with temporal pallor of both optic discs.

The third exacerbation occurred with ataxic gait and hypersomnia after he had mild fever and diarrhoea at the end of July, 1978. Diplopia, ptosis and visual impairment followed this in September. When he was admitted to the hospital on September 21, he was drowsy. But he was oriented and

Address for reprint requests: Dr Takeshi Tabira, Department of Neurology, Faculty of Medicine, Kyushu University 60, Fukuoka City, Japan 812

Accepted 16 March 1981

comprehending when awake. Neurological findings included apathetic dull mentation, hypersomnia, decreased visual acuity bilaterally with optic atrophy, increased deep reflexes with Babinski sign bilaterally, left limb ataxia and truncal ataxia, and left hemi-hyperaesthesia. CSF examination showed a normal cell count, increased total protein (0.616 g/l) and IgG (0.078 g/l). After admission hypersomnia increased and he slept most of the time. A few days later we noticed he did not respond to sounds or words even while he was awake. He appeared totally deaf with no startle response to loud sounds, but he understood written commands, performed and spoke correctly. He could write, read, copy and calculate with figures. His perception (except auditory) and praxis also were normal. On the other hand he could not hear, echo or dictate. The EEG showed a drowsy and light sleep record of diffuse theta waves mixed with occasional spindle activities, being activated by passive eye opening or by sounds. Auditory brainstem responses on September 29 showed normal wave pattern with slight prolongation of latencies in the P II-V waves, but cortical auditory potentials were markedly reduced (fig 1). Repeated CT scans did not show any abnormalities apart from slightly enlarged lateral ventricles

and widened Sylvian fissure of the left. He began to improve after treatment with corticosteroids was started. By October 5 he was awake in the daytime. Pure tone audiogram then showed -80 dB hearing loss in all pitches bilaterally (fig 2a), but the stapedius muscle reflex was normal. By the end of October he became able to respond to sounds such as hand clapping, bell ringing and music, but these were indistinguishable. Pure tone audiogram on October 28 showed marked improvement except with high pitched sound (fig 2a). By the end of November he became able to differentiate these sounds but still could not understand words well. Although pure tone audiogram became normal on November 24 (fig 2a), word audiogram was markedly abnormal on November 27 (fig 2b). At the same time Békésy audiometry and the short increment sensitivity (SISI) test were tried but were not performed because he did not understand the manoeuvres. On December 18 word audiogram was better than the previous one, but was still abnormal (fig 2b). By the end of December he became able to understand words, but he could not detect the direction of a sound. Word audiogram became close to normal on January 17, 1979 (fig 2b). Auditory cortical potentials were normal on January 19 (fig 1b).

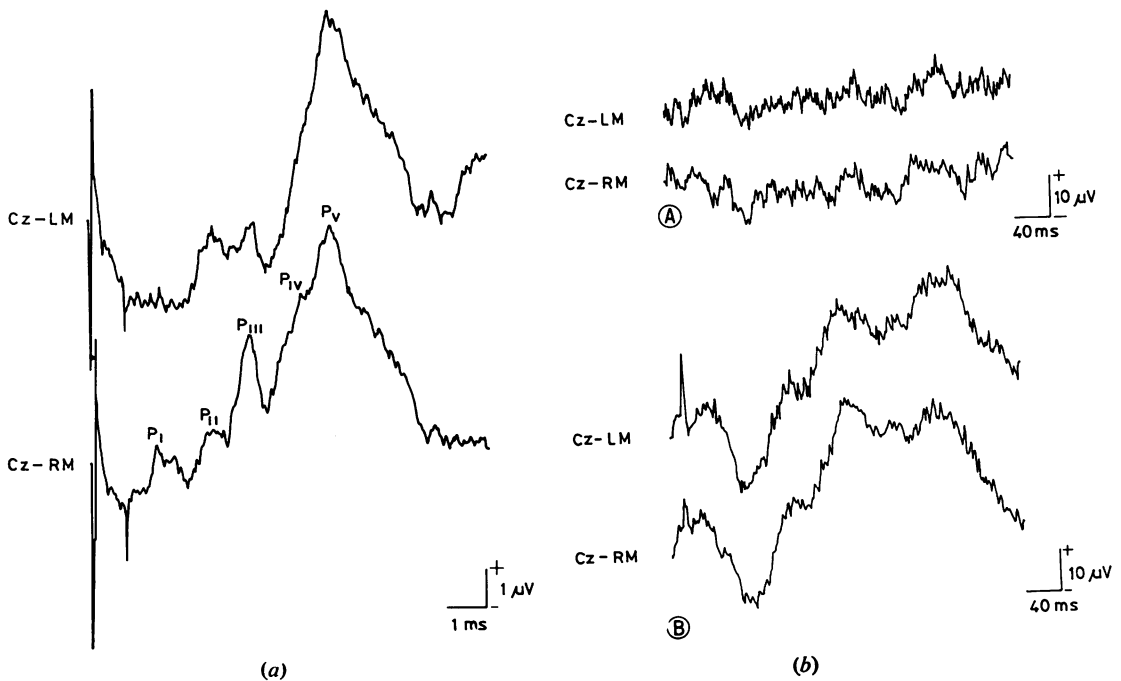
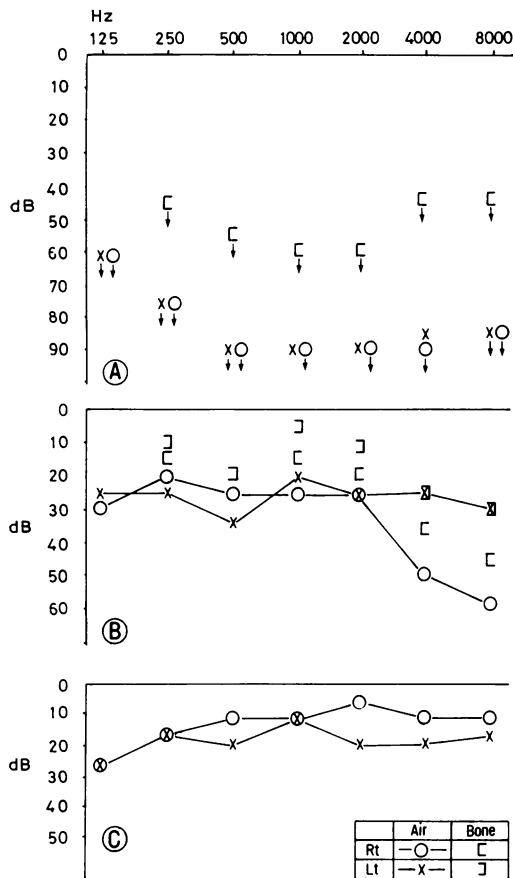
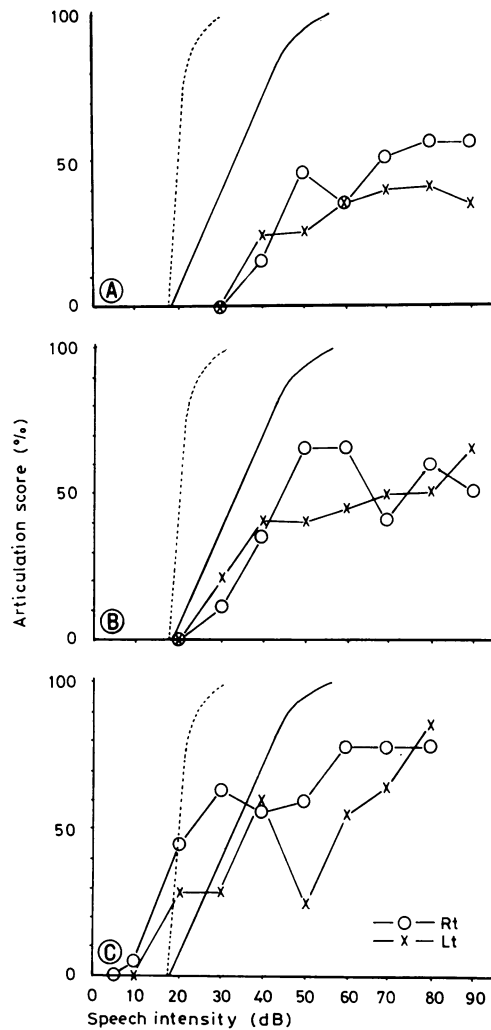


Fig 1 (a) Auditory brainstem response (ABSR). This ABSR was recorded on September 29, 1978 by binaural click sounds ( $n=1,024$ ) with analysis time of 10.24 ms. While the patient was totally deaf, ABSR shows normal pattern with slight delay of peak latencies in PII-PV. (P<sub>I</sub> 1.76, P<sub>II</sub> 3.18, P<sub>III</sub> 4.18, P<sub>IV</sub> 5.51, P<sub>V</sub> 6.22 ms). LM: left mastoid, RM: right mastoid. (b) Auditory cortical evoked potential (ACEP). ACEP was recorded by 90 dB tone bursts into right ear with analysis time of 409.6 ms ( $n=1024$ ). (A) ACEP on September 29, 1978, when the patient was totally deaf. Ambiguous peaks are seen but the responses are markedly reduced. (B) ACEP on January 19, 1979, when the patient had recovered from cortical deafness.

He was discharged with mild dementia, optic atrophy, cerebellar ataxia and pyramidal signs. Throughout the entire course no physical or laboratory findings suggested collagen diseases, syphilis or sarcoidosis. Sural nerve biopsy done in April, 1978 also was normal.



(a)



(b)

Fig 2 (a) Pure tone audiogram. (A) October 5, 1978, when the patient had recovered from hypersomnia. The audiogram shows marked hearing loss bilaterally. (B) On October 28, 1978, when he became able to recognise sounds. (C) On November 24, 1978, when he was able to distinguish sounds but could not understand spoken words well. (b) Word audiogram. (A) On November 27, 1978, when the patient had pure word deafness. (B) On December 18, when he was better at understanding words. (C) In January, 1979, when he could understand words well.

**Discussion**

This is a case with scattered lesions in the optic nerves and other sites in the central nervous system. From its remitting and exacerbating course, and elevated CSF IgG, the diagnosis of multiple sclerosis was clinically definite, although the patient showed relatively unusual manifesta-

tions such as complete quadriplegia, severe visual impairment, epilepsy and deafness. Our former studies,<sup>7,8</sup> and a comparative study among Orientals and Caucasians,<sup>9</sup> delineated some characteristic features of Japanese MS, of which severe involvement of optic nerves and spinal cord is the most distinctive. Epilepsy and deafness are, however, uncommon even in Japanese MS.

Activation of the EEG by sounds, the presence of responses of the stapedius muscle reflex and the normal pattern of auditory evoked brainstem responses indicate a normal lower level of the auditory pathway. Consistency in the repeated audiograms and the course of recovery do not suggest hysterical deafness. Markedly reduced cortical auditory evoked potentials and the discrepancy between pure tone audiogram and word audiogram were compatible with deafness of cortical or subcortical origin. The presence of a PV peak in auditory brainstem responses indicates that the location of the demyelinating lesion was above the midbrain.<sup>10</sup>

The most common cause of cortical deafness is cerebrovascular disease affecting both temporal lobes.<sup>1</sup> Lesions have been shown by necropsy,<sup>11</sup> by angiogram<sup>12</sup> and by CT scan.<sup>13</sup> In our case CT scan did not reveal the demyelinating lesions, but neurophysiological techniques were more informative.

Since vascular lesions involve both cortex and white matter, it may be questioned whether only subcortical lesions can cause cortical deafness. Only Clark and Russel<sup>14</sup> have shown cortical deafness of subcortical origin. Our case demonstrates the possibility of cortical deafness due to subcortical white matter lesions. This case has also shown the sequence of recovery from cortical deafness. Initially the patient was totally deaf, then he showed auditory agnosia, and finally pure word deafness. A similar sequence has been seen in a case of viral encephalitis.<sup>15</sup> Earlier and complete recovery in our case suggests a better prognosis for cortical deafness in MS.

We are very grateful to Dr Hiroshi Shibasaki, associate professor of neurology at Kyushu University, for his revision of this paper.

#### References

- 1 Graham J, Greenwood R, Lecky B. Cortical deafness. A case report and review of the literature. *J Neurol Sci* 1980; **48**:35-49.
- 2 Muller R. Studies on disseminated sclerosis, with special reference to symptomatology, course and prognosis. *Acta Med Scand* 1949; **Suppl 222**: 1-214.
- 3 McAlpine D, Lumsden CE, Acheson ED. *Multiple sclerosis. A reappraisal*. Edinburgh: Churchill Livingstone 1972.
- 4 Von Leden H, Horton BT. The auditory nerve in multiple sclerosis. *Acta Otolaryngol (Stockh)* 1948; **48**:51-7.
- 5 Bentzen O, Jelnes K, Thygesen P. Acoustic and vestibular function in multiple sclerosis. *Acta Psychiatr Neurol Scand* 1951; **26**:265-95.
- 6 Nagashima T, Tabira T, Tsuji S, Nakajima T, Kuroiwa Y. A case of multiple sclerosis with transient cortical deafness. *Clin Neurol (Tokyo)* 1979; **19**:616-22.
- 7 Kuroiwa Y, Shibasaki H. Clinical study of multiple sclerosis in Japan. A current appraisal of 83 cases. *Neurology (Minneapolis)* 1973; **23**:609-17.
- 8 Kuroiwa Y, Igata A, Itahara K, et al. Nationwide survey of multiple sclerosis in Japan. *Neurology (Minneapolis)* 1975; **25**:845-51.
- 9 Shibasaki H, Okihiro MM, Kuroiwa Y. Multiple sclerosis among Orientals and Caucasians in Hawaii; a reappraisal. *Neurology (Minneapolis)* 1978; **28**:113-8.
- 10 Stockard JJ, Rossiter VS. Clinical and pathological correlates of brain stem auditory response abnormalities. *Neurology (Minneapolis)* 1977; **27**: 316-25.
- 11 Mott FW. Bilateral lesion of the auditory cortical centre: complete deafness and aphasia. *Br Med J* 1907; **2**:310-5.
- 12 Jerger J, Weikers NJ, Sharbrough FW III, Jeger S. Bilateral lesions of the temporal lobe. A case study. *Acta Otolaryngol (Stockh)* 1969; **Suppl 258**:1-51.
- 13 Earnest MP, Monroe PA, Yarnell PR. Cortical deafness: Demonstration of the pathologic anatomy by CT scan. *Neurology (Minneapolis)* 1977; **27**:1172-5.
- 14 Clark WE Le Gros, Russel WR. Cortical deafness without aphasia. *Brain* 1938; **61**:375-83.
- 15 Goldstein MN, Brown M, Hollander J. Auditory agnosia and cortical deafness; analysis of a case with three-year followup. *Brain Lang* 1975; **2**: 324-32.