

Spontaneous Bladder Rupture and Pelvic Fracture Due To Bladder Cancer

Mesane Kanserine Bağlı Gelişen Pelvis Kırığı ve Mesane Rüptürü

Deniz ORAY, Onder LIMON, Cem ERTAN, Asli UGURHAN

Department of Emergency Medicine, Izmir University Faculty of Medicine, Izmir

SUMMARY

Bladder rupture is a rare complication following bladder cancer, but has a high mortality rate. Since bladder rupture is an emergency, the diagnosis and treatment of the cancer is usually delayed. Here we report a 56-year-old male patient who presented to our emergency department with severe abdominal pain, abdominal distension, left leg pain and difficulty in walking without history of significant trauma and ended up with diagnoses of spontaneous bladder rupture and non-traumatic pelvic fracture caused by bladder carcinoma.

Key words: Bladder cancer; bladder rupture; emergency department; pelvic fracture.

ÖZET

Mesane rüptürü, mesane kanserinin nadir bir komplikasyonu olsa da, gerçekleştiğinde mortalite hızı yüksek seyretmektedir. Mesane rüptürü acil bir durum olduğundan, altta yatan neden olarak kanserin tanınması ve etiyolojiye yönelik tedavi gecikebilmektedir. Bu yazıda, acil servise travma öyküsü olmaksızın şiddetli karın ağrısı, batında şişkinlik, sol bacakta ağrı ve yürüme güçlüğü ile başvuran ve mesane kanserine bağlı spontan mesane rüptürü ve pelvis kırığı tanısı alan 56 yaşında bir erkek hasta sunuldu.

Anahtar sözcükler: Mesane kanseri; mesane rüptürü; acil servis; pelvis kırığı.

Introduction

Spontaneous bladder rupture is usually described in association with recent trauma, malignant diseases, anatomical outflow obstructions, indwelling catheters, instrumentation or a combination of these.^[1,2] Bladder rupture is a rare complication following bladder cancer, but has a high mortality rate. This condition is an emergency, therefore the diagnosis and treatment of the underlying disease is usually delayed.^[3] Pelvic fracture co-exists with 83% of bladder ruptures.^[4]

Here we report a patient with bladder carcinoma with a pathologic fracture of the pelvic bone and spontaneous extra-peritoneal bladder rupture in combination with intra-peritoneal rupture.

Case Report

A 56-year-old male presented to our emergency department (ED) with severe abdominal pain, abdominal distension, left leg pain and difficulty in walking without any history of trauma which started about 24 hours ago. He was discharged in a good condition from another university hospital three days earlier following a pelvic radiotherapy session for his bladder carcinoma. At presentation, his pulse rate was 110 beats per minute, the blood pressure was 90/50 mmHg and pulse oximeter value was 93% in room air. He was oriented and cooperated. The abdomen was distended and there was guarding with rebound tenderness. There was tenderness at the left iliac bone with direct pressure application. An 18

Submitted: February 18, 2014 **Accepted:** March 21, 2014 **Published online:** June 24, 2014

Correspondence: Dr. Cem Ertan. Medical Park Izmir Hastanesi, Acil Servisi, Yeni Girne Blv., Karşıyaka, Izmir, Turkey.

e-mail: cem_ertan@hotmail.com

© 2014 Emergency Medicine Association of Turkey. Production and Hosting by Elsevier B.V. Originally published in [2014] by Kare Publishing. This is an open access article under CC BY-NC-ND license (<http://creativecommons.org/licenses/by-nc-nd/4.0/>)

Turk J Emerg Med 2014;14(3):139-141 doi: 10.5505/1304.7361.2014.55707



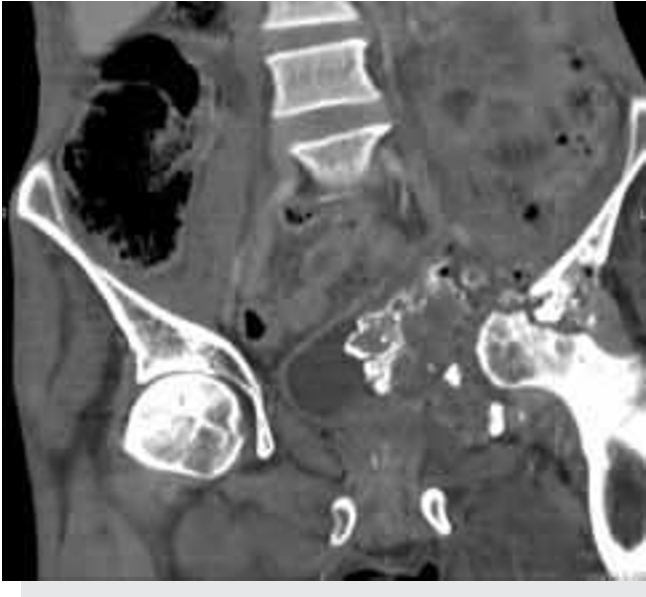

Figure 1. Contrast enhanced abdomen CT showing the iliac bone fracture.

gauge IV line was inserted and 2000 ml of normal saline infusion was started. The abdominal ultrasound scan revealed that there was only a small amount of urine in the bladder. It also showed free fluid in the peritoneal cavity. A contrast enhanced computed tomography (CT) scan of the abdomen and retrograde CT cystogram were ordered. The CT scan showed a 10 cm x 9 cm mass with soft tissue components at the left iliac bone along with a pathological fracture and

confirmed the presence of extensive free fluid both in the peritoneal space and extra-peritoneal area (Figure 1). The CT cystogram revealed the extravasation of the contrast medium from the left side of the bladder, thru the mass defined by the CT, surrounding the iliopsoas muscle (Figure 2).

A Foley catheter was inserted and there was urine drainage of 100 ml. Emergent antibiotic therapies with ampicillin, cefotaxime and metronidazole, along with ongoing fluid therapy was started in the ED. The patient was assessed by a medical oncologist, a urologist and an orthopedic surgeon, and was hospitalized for medical treatment and possible surgical repair. But he unfortunately died before surgery.

Discussion

Bladder rupture is an alarmingly mortal pathology (12-22%) which usually occurs in association with blunt or penetrating lower abdominal injuries.^[3] It is commonly classified as extra-peritoneal or intra-peritoneal. Extra-peritoneal ruptures are found alone in 62% of cases, intra-peritoneal ruptures alone constitute 25% of all bladder injuries and they are combined in a 12% of cases.^[3] It is reported that 83% of all bladder ruptures are accompanied by a pelvic fracture.^[4]

Spontaneous rupture of the urinary bladder is a rare occurrence; in the available literature it is predominantly associated with risk factors such as radiotherapy for pelvic malignancies.^[2,5-7] According to a recent article by Baxter et

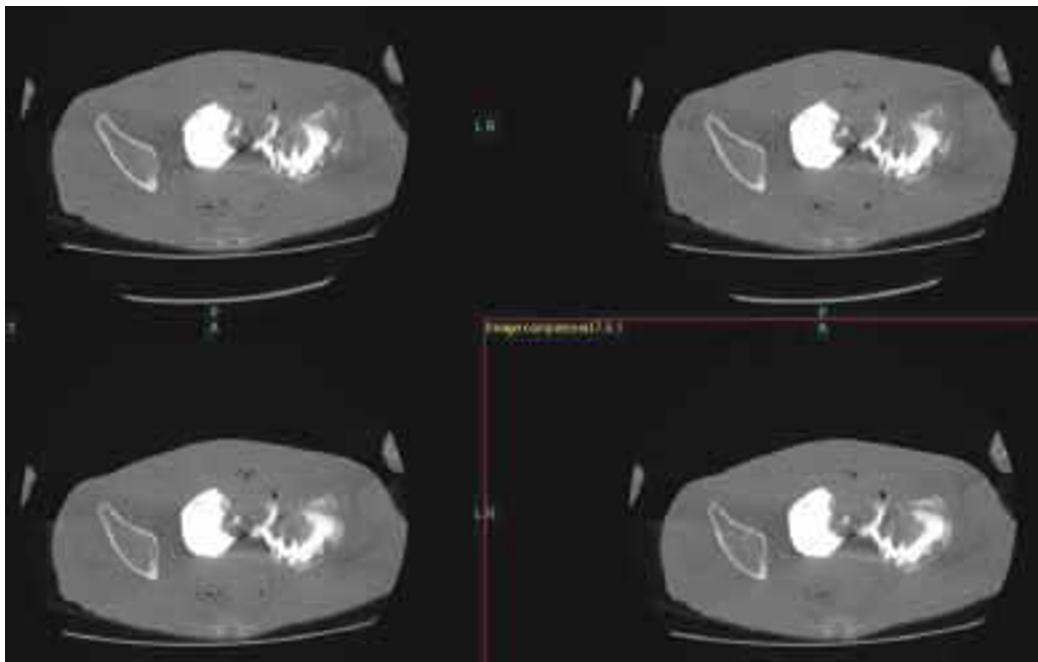


Figure 2. CT cystogram showing contrast extravasation from the left side of the bladder and iliac bone fracture.

al., women who undergo radiation therapy to the pelvis for cancers of the cervix, rectum, or anus are at an increased risk for pelvic fractures.^[8] In other cases, substance abuse with alcohol, cocaine and amphetamine have all been associated with bladder rupture.^[9,10] Our case, in concordance with the literature, had metastatic malignancy under treatment with radiotherapy which was anticipated to be the possible cause of the pathological pelvic fracture.

The presentation of spontaneous bladder rupture is usually with acute abdominal pain. Urine may continue to drain after bladder catheterization and the injury, if unsuspected, may go undiagnosed for period ranging from days to weeks.^[2,11] The combination of CT and cystography is an accurate method for assessing bladder pathology.^[12] Clinical suspicion is the key to early diagnosis. Our patient presented with acute abdominal pain and left leg pain without any trauma. Urine was drained from the bladder following urinary catheterization. He was completely symptom free at his discharge three days before re-admission. Another possible cause of bladder rupture to be advocated in this patient was pelvic bone metastasis due to bladder cancer. A CT cystogram was diagnostic for both the rupture and the fracture in our case.

Operative treatment includes drainage of urine from the peritoneal cavity, closing the rupture and instituting good vesicle drainage. Early diagnosis and prompt surgical treatment decreases the morbidity and mortality associated with this condition.^[1,11] In our present case the patient never had the chance to make it through to surgery despite his early admission to the hospital and timely diagnosis and treatment efforts in the ED. But on the other hand, the patient being under heavy pain medication with fentanyl patches, and somehow got used to living with pelvic discomfort might have delayed presentation to the hospital.

In the presented case we suggest that the cause of the rupture is a combination of pelvic fracture caused by metastatic bladder carcinoma and radiotherapy for pelvic malignancy. Appropriate management of high risk group patients during follow up and at presentation to ED may decrease the morbidity and mortality associated with this condition.

Conflict of Interest

The authors declare that there is no potential conflicts of interest.

References

1. Haddad FS, Wachtel TL. Spontaneous intraperitoneal rupture of the bladder. *Urol Int* 1987;42:467-9. [CrossRef](#)
2. Engin O, Yakan S, Yıldırım M, Kozacıoğlu Z. A rare cause of acute abdomen: bladder rupture due to catheterization. *J Clin Anal Med* 2013;4:327-8. [CrossRef](#)
3. Santucci RA, Mcaninch JW. Bladder injuries: evaluation and management. *Int Braz J Urol* 2000;26:408-14.
4. Chan DP, Abujudeh HH, Cushing GL Jr, Novelline RA. CT cystography with multiplanar reformation for suspected bladder rupture: experience in 234 cases. *AJR Am J Roentgenol* 2006;187:1296-302. [CrossRef](#)
5. Schein M, Weinstein S, Rosen A, Decker GA. Spontaneous rupture of the urinary bladder-delayed sequel of pelvic irradiation. A case report. *S Afr Med J* 1986;70:841-2.
6. Fujikawa K, Yamamichi F, Nonomura M, Soeda A, Takeuchi H. Spontaneous rupture of the urinary bladder is not a rare complication of radiotherapy for cervical cancer: report of six cases. *Gynecol Oncol* 1999;73:439-42. [CrossRef](#)
7. Addar MH, Stuart GC, Nation JG, Shumsky AG. Spontaneous rupture of the urinary bladder: a late complication of radiotherapy-case report and review of the literature. *Gynecol Oncol* 1996;62:314-6. [CrossRef](#)
8. Baxter NN, Habermann EB, Tepper JE, Durham SB, Virnig BA. Risk of pelvic fractures in older women following pelvic irradiation. *JAMA* 2005;294:2587-93. [CrossRef](#)
9. Lynn SJ, Mark SD, Searle M. Idiopathic spontaneous bladder rupture in an intoxicated patient. *Clin Nephrol* 2003;60:430-2.
10. Pradhan AA. Spontaneous rupture of bladder: a rare clinical entity. *MJAFI* 2007;63:92-3.
11. Heyns CF, Rimington PD. Intraperitoneal rupture of the bladder causing the biochemical features of renal failure. *Br J Urol* 1987;60:217-22. [CrossRef](#)
12. Limon O, Unluer EE, Unay FC, Oyar O, Sener A. An unusual cause of death: spontaneous urinary bladder perforation. *Am J Emerg Med* 2012;30:2081.e3-5.