

Comparison of angiography with continuous wave Doppler ultrasound in the assessment of extracranial arterial disease

T K HAMES, K N HUMPHRIES, T V POWELL, AND
D L McLELLAN

From the Wessex Regional Medical Physics Department and Wessex Neurological Centre, Southampton General Hospital, Southampton

SUMMARY Extracranial arterial disease was assessed using non-invasive continuous wave Doppler ultrasound. The results of the Doppler study were compared with those of angiography. There was a positive correlation between the results of angiography and the shape of the Doppler waveform, but the correlation was improved by adding a compression manoeuvre to the procedure.

This paper presents our experience with continuous wave (CW) Doppler ultrasound as a non-invasive technique for diagnosing the extent of arterial disease in the extracranial circulation. The results suggest a spectrum of different waveforms that can be used to identify carotid artery disease in patients suffering from cerebral ischaemia. The growing success of this technique in the non-invasive diagnosis of peripheral vascular disease has encouraged its use in cerebrovascular disease. Progress in this area has generally been slower because of the relative complexity of the cerebral circulation. For clinical diagnosis a non-invasive test is badly needed which can define a patient as having either no extracranial cerebrovascular disease or severe disease in an extracranial artery. In selected cases, such a test would avoid the risks of angiography.¹ To this end considerable work has been carried out²⁻⁴ regarding the use, and confidence level of the temporal artery test originally described by Brockenbrough.⁵ The method was subsequently modified by Barnes⁶ and Moore.⁷ The test uses the effect of compressing the temporal and infraorbital arteries in order to identify collateral supply to the brain in the presence of a severely diseased, or occluded, internal carotid artery. Keller³ states that a decrease of the supra-trochlear signal on compression of the superficial temporal or facial artery has a strong positive

correlation with severe stenosis or occlusion of the internal carotid artery. Moore⁷ obtained an accuracy of 94% in diagnosing lesions of this type. He claimed that the Doppler test was of particular value in identifying patients with significant lesions in the absence of 'bruits'. To obtain further information of clinical significance, such as the presence of mild disease in the internal carotid artery, increased attention was given to changes apparent in the common carotid waveform.

Subjects and methods

Subjects

Seventy-seven patients referred for angiography were observed with CW Doppler ultrasound. The patients were aged 21 to 79 years (mean 51 years) and there were 52 males. Thirty-nine had presented with transient cerebral ischaemic attacks (TIAs) in carotid artery territory, two with TIAs in basilar artery territory, 16 with minor strokes presumed to be due to vascular occlusion in carotid territory, nine with intermittent claudication of the limbs, four with a hemisphere tumour, three with ophthalmoplegic migraine and one each with coronary artery disease, oculomotor nerve palsy, Huntington's chorea and internal hydrocephalus. Twenty of these 77 patients had bruits over one or both carotid arteries. The blood pressure measured in the ward when the patient was admitted for angiography was also recorded in all but two patients. A recorded diastolic blood pressure of 95 mmHg or more was accepted as an indication of hypertension.

Address for reprint requests: Dr TK Hames, Southampton General Hospital, Shirley, Southampton SO9 4XY, England.

Accepted 18 May 1981

Continuous wave Doppler ultrasound

All the Doppler measurements were made on the patients within 24 hours prior to their having carotid angiography via a femoral catheter or by direct puncture of the common carotid artery. For all our measurements we employed a Sonicaid BV380 Doppler Ultrasound Velocimeter with a working frequency of 8 MHz and the heterodyne modification described elsewhere.⁸ In addition to this a filter was incorporated to remove all signals within ± 200 Hz of the zero Doppler shift frequency in an attempt to remove wall motion artefact encountered especially at the common carotid measurement site. The experimental procedure was explained to the patient who was then allowed to relax in the supine position before starting the measurements. During this period three adhesive electrodes were attached to the sternum to provide an ECG. The R-wave of this ECG signal was used to trigger a short tone burst, which was then mixed with the Doppler shift signal to provide a time marker of heart activity. Doppler shift signals were then obtained from the measurement sites shown in fig 1 with the probe pointing towards the heart, that is flow towards the transducer. This was achieved by placement of the probe over the arterial site and movement of the probe until the strongest signal was obtained on the headphones. The supraorbital artery is a branch of the ophthalmic artery, itself a branch of the internal carotid artery. It is located under the eyebrow at the supraorbital ridge which is usually near the middle of the orbit. The supratrochlear artery also derives from the internal carotid artery via the ophthalmic artery and can be found in the medial angle of the orbit. The common carotid artery is easily located in the neck and the superficial temporal artery, a branch of the external carotid artery, runs over the zygomatic process of the temporal bone.

Next, the blood pressure in the brachial artery on each arm was recorded before completing the measurements with a compression test. Upon compression of the temporal or facial arteries the possible responses of the signals at the ipsilateral supraorbital and supratrochlear were recorded as an increase, no change, decrease or reversal (fig 3). Compression tests providing increases or no changes were called Negative Compression Tests, whilst those producing at least

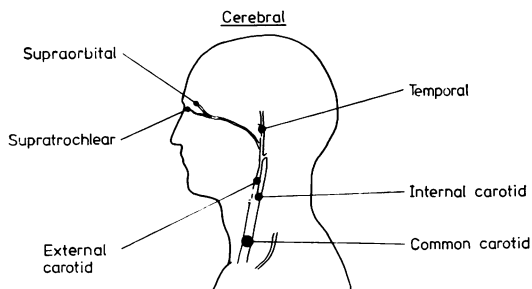




Fig 1 Cerebral measurement sites.



Control (50 years old)



Control (25 years old)

Fig 2 Common carotid waveforms (type 1)

one decrease, or reversal, were called Positive Compression Tests. The compression was produced by finger pressure over the artery for four to five cycles.

The Doppler audio information was recorded onto a cassette tape recorder at the bedside and converted to hard copy immediately after the examination using a Kay Sonagraph Spectrum Analyser. For the cerebral circulation the Doppler information when displayed in a frequency versus time mode has a form as shown in fig 2, the envelope or Doppler "signature" being defined by the variation of the maximum Doppler shift frequency with time. The intensity variation within the signature is proportional to the number of blood cells having that particular Doppler shift frequency at that point in time. Hence the variation in intensity relates to the variation of the velocity profile within the artery. Typically three cardiac cycles of information were obtained from each measurement site, the capture time of the sonograph being 2.4 seconds for the 0-8 KHz working range.

Cerebral angiography

The 77 patients were assessed angiographically, 105 carotid arteries in all. Twenty-eight carotid vessels were examined by standard arch angiography using a pressure injection of contrast medium into the ascending aorta. The remaining 77 were either selectively catheterised by a femoral artery puncture or percutaneous cannulation of the common carotid artery followed by hand injections of contrast medium.




Fig 3 Compression test criteria.

In all 28 arch angiograms, a single projection only of the neck vessels was obtained, whereas 59 of the selective examinations were biplane, the two projections being approximately at right angles. The films were reviewed for evidence of atheroma in the common carotid artery, its bifurcation and internal carotid artery as far as its division within the skull, noting also any disease present in the proximal external carotid artery. In the case of arch angiograms comment could only be made upon the proximal internal carotid artery to the level of the mandible.

The degree of disease was categorised according to the percentage reduction in vessel diameter, so up to 25% reduction indicated mild disease, 25%–75% moderate disease, 75% or more, including complete occlusion, defined severe disease. Thus including normal examinations, there were four categories of angiographic result.

Results

DOPPLER RECORDINGS

(a) *Normal waveform* Various descriptions of the

normal common carotid Doppler signature^{3,9} have been given. A unique description is particularly important, especially for the diagnosis of the absence of arterial disease and since it appears that the progressive changes in the signature away from this normal state represents an important part of the non-invasive diagnosis of the severity of arterial disease in the internal carotid artery. Fig 2 shows a normal (type 1) waveform for controls aged 25 and 50 years. In both cases the waveforms exhibit five well defined features: (1) a sharp well defined A peak, (2) a B peak, (3) an inscure, (4) a reasonable diastolic component well above zero, (5) a smooth, well defined maximum frequency envelope. The major difference between the two waveforms lies in the B peak. In the young control it is spur-like and in some cases lower than the diastolic “peak” whereas in the elderly control the appearance is much flatter or plateau-like. The velocity profile within the waveform, or Doppler “signature,” is also significant. It can be seen from fig 2 that during the systolic phase a plug-like flow exists in the artery, with a black edge and grey interior indicating that the majority of blood cells are travelling at peak velocity over this period. Beyond this peak, the velocity profile changes to a more laminar state with the distribution of velocities spreading over the minimum to maximum range.

(b) *Damped waveform* Fig 4 is an example of a damped (type 4) waveform. Here the initial three features of the normal waveform are lost. The

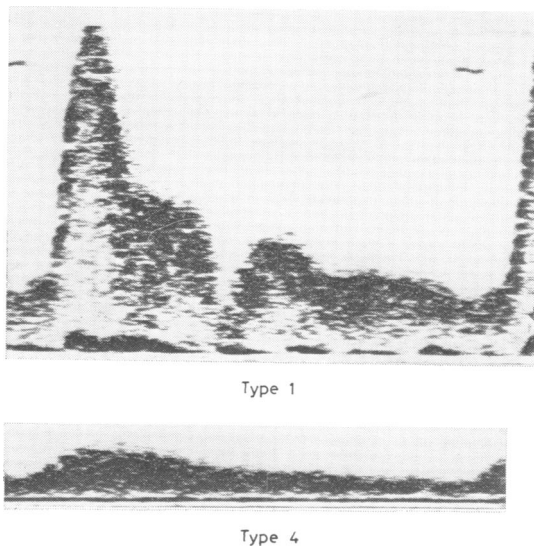



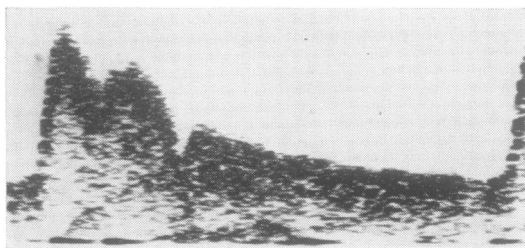
Fig 4 Common carotid waveforms (type 1 and 4).

diastolic component is variable and the pulsatile nature of the normal waveform is not apparent. This type of waveform is generally found at the distal sites but can be obtained at the common carotid and superficial temporal sites.

(c) *Mild disease waveform* Fig 5 exhibits examples of the types of waveform found at the distal common carotid (near the bifurcation) in the presence of mild disease in the internal carotid artery. The main difference between the type 2.1 and the normal waveform appears to be a loss of the B peak, that is a filling in between the A and B peaks. The type 1.3 waveform exhibits however a more prominent B peak.



Type 1



Type 1.3



Type 2.1

Fig 5 Common carotid waveforms (types 1, 1.3 and 2.1).

CLINICAL CORRELATION

The angiogram was normal in 42 patients (50 vessels); in 32 patients (39 vessels) the angiogram and Doppler were both normal and in the remainder the Doppler suggested the presence of mild disease. The 32 patients in whom both investigations agreed included 14 with TIAs (two of whom had hypertension) and seven with strokes (four of whom had hypertension). None of these patients had bruits in the neck.

The 11 patients with normal angiograms but mild disease on the Doppler tests included eight with TIAs, of whom two had hypertension. A soft bruit was heard over two of these vessels, but these angiographically normal vessels were each contralateral to an abnormal vessel causing symptoms, over which loud bruits were present. Angiography of these contralateral vessels showed severe stenosis in one patient and occlusion in the other. The bruits over the angiographically normal vessels could therefore have indicated a compensatory increased flow.

The Doppler was normal in 37 patients (44 vessels). One of these patients, on whom no compression test was performed, had TIAs, hypertension and loud bruits over both carotid arteries, with severe stenosis on angiography. Three other patients had mild angiographic disease, two of these having had TIAs and one a stroke.

The Doppler was mildly abnormal in 26 patients (37 vessels). In 23 of these patients (34 vessels) the angiogram was normal or only mildly abnormal, but in three vessels (two with no compression test, one negative compression test) there was severe angiographic disease. One of these patients presented with TIAs, no bruits, and normal blood pressure; angiography showed severe stenosis at the origin of the internal carotid artery. Another patient presented with TIAs, bilateral carotid bruits and normal blood pressure and the angiogram showed severe stenosis at the origin with a further narrowed segment in the internal carotid artery above the level of the jaw. The third patient presented with TIAs, a bruit in the aortic area apparently radiating into both carotid arteries, and normal blood pressure; angiography showed severe stenosis at the origin of the internal carotid artery.

Angiographically, 18 vessels were severely stenosed, whereas the Doppler suggested the presence of severe disease in 14 vessels. Of these 14 patients, 12 had definite symptoms of carotid disease and nine had bruits. Two of those without bruits had complete occlusion of the internal carotid artery. Thus, one patient with symptoms of carotid artery disease but no bruit was correctly

identified by the Doppler test as having severe disease requiring surgery.

No patient whose Doppler test suggested severe disease had mild or no disease.

In conclusion, the Doppler test missed severe stenosis in four of 18 patients, 12 of whom had unmistakable symptoms of carotid artery disease. All these four patients had symptoms of disease and two of them had bruits, so that two of 18 (approximately 6%) of patients with a history of carotid artery disease, severe stenosis and *no bruit* were missed by the Doppler. Three of these four patients, however, did not receive the compression test.

CORRELATION WITH ANGIOGRAPHY

The total number of comparisons made with angiography was 105. The first 32 examinations were performed without using the compression test. The diagnostic criteria employed regarding waveform type were the same as with the compression test. Initially normal and severely diseased internal carotid arteries were successfully diagnosed but a patient was then encountered with normal (type 1) waveforms at proximal and distal sites, in the presence of severe stenosis of the internal carotid artery. At this point the compression test was introduced as part of the procedure.

The breakdown of the comparisons into the four angiographic groupings is shown in table 1 and the comparisons with, and without, the compression test are shown in tables 2 and 3 respectively.

Table 1 Total number of comparisons made between angiography and Doppler ultrasound

Angiogram Classification	Total number of vessels	Comparisons (without compression test)	Comparisons (with compression test)
Normal	50	18	32
Mild	27	8	19
Moderate	10	3	7
Severe occlusion	18	3	15
	105	32	73

Table 2 Comparisons (made without compression test)

Angiogram	Doppler	Common Carotid waveform type		
		1	1.3	2.1
Normal	Normal	17	—	—
Normal	Mild	1	—	1
Mild	Mild	6	2	4
Mild	Normal	2	—	—
Severe	Normal	1	—	—
Severe	Mild	2	—	2

Table 3 Comparisons (made with compression test)

Angiogram	Doppler	Common carotid waveform type		
		1	1.3	2.1
Normal	Normal	22	—	—
Normal	Mild	10	3	7
Mild	Mild	17	9	8
Mild	Normal	2	—	—
Severe	Severe	14	2	10
Severe	Mild	1	1	—

Discussion

In summary our results show that by observing the Doppler signatures at the common carotid, superficial temporal, supraorbital and supratrochlear sites and utilising the compression test we could define the following pathological categories:

- (1) No extracranial disease present; type 1 waveforms at all sites with a Negative Compression Test.
- (2) Mild disease (1%–25% stenosis of the internal carotid artery) type 1.3 or 2.1 waveform at the distal common carotid artery (near the bifurcation) measurement site and a Negative Compression Test.
- (3) Severe disease (stenosis occluding the diameter of the lumen to 75% or greater) in the internal carotid artery; type 4 waveforms at either the supraorbital or supratrochlear sites or a Positive Compression Test or both.
- (4) Severe disease in the external carotid artery; type 4 waveform at the superficial temporal artery.

In 50 carotid arteries assessed as angiographically normal, the ultrasound results were normal in 39. In the other 11 arteries, the Doppler ultrasound results suggest mild abnormalities in the ICA. In the mild disease angiographic category, the very good agreement (23/27) between the Doppler and angiogram tests is encouraging evidence that the presence of mild disease in the internal carotid artery is indeed being monitored non-invasively. The 11 “false-positive” results detailed in the angiographically normal group could be due to the fact that the angiogram and Doppler tests are providing different information about the patient, that is morphological as opposed to haemodynamic. With regard to the diagnosis of the presence of mild disease in the internal carotid artery the following points should be made. Firstly, two positions along the common carotid artery are observed as part of the test and these are called the proximal and distal common carotid arterial measurement sites, that is at the base of

the neck and near to the bifurcation. An example of this technique is shown in fig 6, exhibiting the Doppler signatures obtained from a patient with mild disease at the origin of the internal carotid artery where there is a waveform change in evidence along the common carotid artery from a normal type 1 to type 2.1 in the more distal position. This procedure was initially developed in

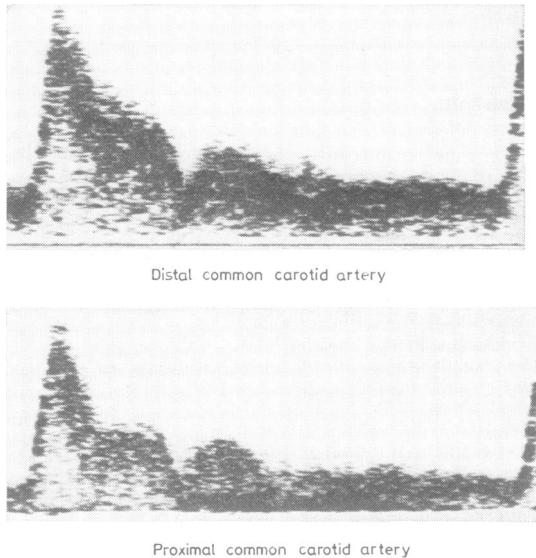
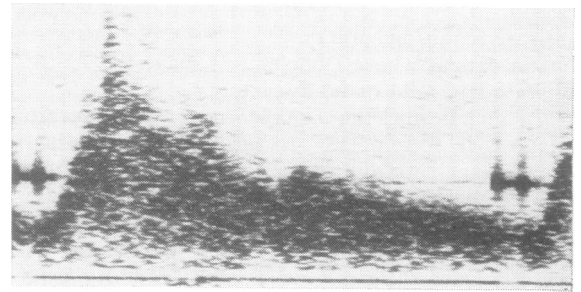
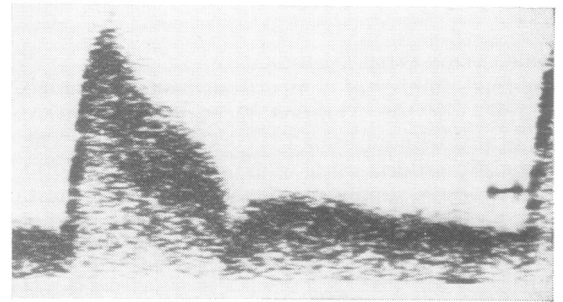


Fig 6 Common carotid waveforms (proximal and distal in the presence of mild disease in the internal carotid artery).

an attempt to assess the presence of disease in the common carotid artery. It was anticipated that no change in the waveform would imply the absence of disease in that segment but it appears that the distal common carotid waveform can detect disease in the internal carotid artery. This study concentrated on the common carotid arterial measurement site because of its readily accessible position. Some additional measurements have now been carried out on the less accessible internal carotid artery and fig 7 shows a type 2.1 waveform at the distal common carotid position and a confirmatory turbulent internal carotid artery signal in the presence of mild disease at the origin of the internal carotid artery. The internal carotid artery turbulence appears to be very localised and hence not always easily detectable along a length of artery, without the aid of imaging, whereas the common carotid artery signal is easily accessible. The three false negative results all occurred for patients measured at an early point in the study and can probably be ascribed to operator inexperience.



Internal carotid artery



Distal common carotid artery

Fig 7 Distal common carotid and internal carotid waveforms in the presence of mild disease in the internal carotid artery.

ence. It is of interest that two waveform types, 1.3 and 2.1, have been identified in relation to the presence of mild disease in the internal carotid artery and we feel it is particularly important to establish the reasons for this so that waveforms relating to other disease states can confidently be recognised.

We have encountered only 10 patients in this study with moderate disease in the internal carotid artery. In seven of these 10 cases the waveform type observed is shown in fig 8. In three cases the waveforms were type 1, but recorded at the proximal common carotid artery site in the early part of the study.

In the severe disease category 15 comparisons with angiography were made and in 14 of these the agreement was good. In the one false negative case the degree of stenosis was judged to be 75%, that is just on the threshold of the severe stenosis category. The waveform at the distal common carotid measurement site, however, was of the type usually associated with mild disease. The patient gave a history of TIAs in left carotid artery territory and had a bruit in the aortic area appearing to radiate into both sides of the neck.

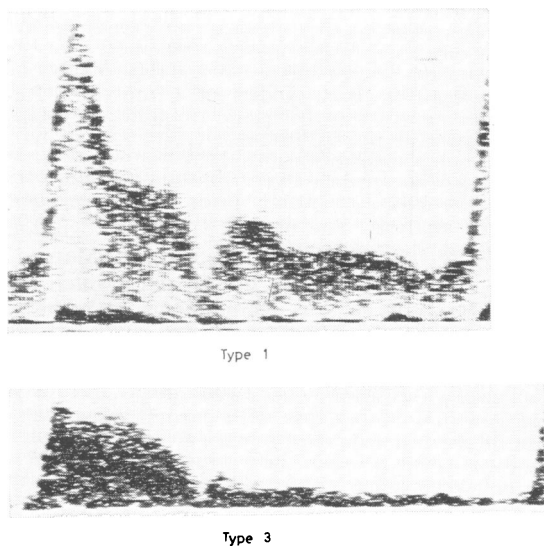


Fig 8 Common carotid waveforms (types 1 and 3).

In our experience a positive compression test or a damped waveform at *either* the supraorbital *or* supratrochlear measurement site identifies severe disease. It is essential to use both criteria at both sites. We have found it is possible to obtain a type 1 waveform at one of these sites and a type 4 at the other, leading to a false negative result if both are not used. In five of the cases only the compression test was positive, showing as mentioned previously, that a situation can exist where the internal carotid artery can be severely diseased, or even occluded, but as a result of efficient collaterals supplying arteries a normal (type 1) signature can exist at the distal sites. The distal sites available for indirect assessment of the internal carotid arterial segment are the supraorbital and supratrochlear arteries. Events in these vessels do indeed appear to reflect changes occurring in the internal carotid artery. Various workers,^{4,10} have chosen only one of these sites on the grounds that one of the two is more uniquely defined. It is generally agreed that in some cases the vascular anatomy is such that more than two signals can be obtained when probing over the eye and usually it is the supratrochlear which gives the more easily found and stronger signals. The quality of the signals from these sites may be impaired by the restricted angle between the probe and artery, that is low Doppler shift frequency, as well as the amount of ultrasound power that one can safely use around the eye. Although the pressure applied to the skin by the operator is kept minimal at all times it has been found necessary on some oc-

casions to apply a layer of jelly between the probe and skin, avoiding direct skin contact to obtain a reasonable signal. At present the compression test is carried out by two people with one obtaining the optimum signal and the other carrying out the compression. Both are wearing headphones and make an independent assessment as to the change in the signal on compression. We feel that problems such as probe movement upon compression are minimised by this arrangement. Audio assessment has been used for the majority of the measurements reported here which enabled us to distinguish between a significant decrease in the signal and a complete loss on compression. Examples of the compression test using a maximum frequency detector are shown in fig 3.

Further investigation of this aspect of the work is needed to provide clinically useful information regarding both the identity and the efficiency of collateral vessels in the cerebral circulation. With severe disease in the internal carotid artery collateral flow may occur via the vertebral posterior communicating arteries, and through the contralateral carotid arteries. In an attempt to assess the latter some workers have carried out common carotid artery compression, but this introduces the risk of transient cerebral ischaemia or of provoking occlusion in the presence of severe stenosis and in our view is contradicted in such patients. By using the direction of flow through the supraorbital and supratrochlear arteries,^{8,11} we were not reliably able to predict the presence of severe disease in the internal carotid artery. It is possible to obtain signals of which the direction is uncertain,¹¹ that is simultaneous forward and reverse. On a sonogram such signals are of equal intensity in both directions as distinct from the "shadowing" obtained occasionally as a limitation of the heterodyning electronics and the angle of the probe. It is also to be noted that retrograde flow into the orbit was detected in two patients with normal angiograms.

The ability to distinguish between a severe stenosis and a complete occlusion non-invasively is clinically desirable but our present technique cannot reliably make this distinction. Keller³ refers to the asymmetry of the diastolic components of the common carotid waveforms in the presence of an occlusion, that is a particularly low value on the side of the occlusion. In our experience this criteria has been successful only in four out of six angiographically proven occlusions of the internal carotid artery. An example of the Doppler waveforms for this condition are shown in fig 9. Other promising areas of use of this character-

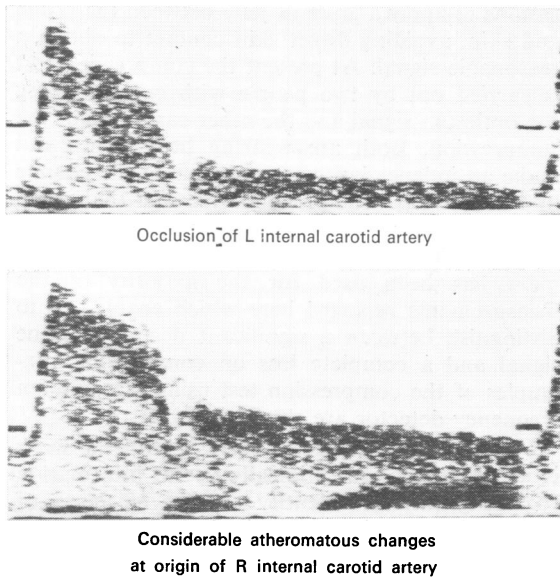


Fig 9 L and R common carotid waveforms from a patient with an occlusion of the L internal carotid artery.

istic appear to be in diagnosis of proximal and intracranial lesions.

How does the accuracy of the technique we have described compare with other non-invasive methods such as oculoplethysmography and carotid phonoangiography developed in recent years? The false negative rates for detecting severe stenosis by these methods are reported to vary from 40%¹⁹ to 9%²⁰ of cases, suggesting perhaps that the skill of the operator is a critical factor particularly in oculoplethysmography.²⁰ We know of no previous comparison of these methods with the full Doppler test procedure we have described, but comparisons have been reported in which not all our compression sites were used,^{20 21} or the details of the Doppler method were not given.²² Most authors agree that the accuracy is far greater in patients with a greater than 75% angiographic stenosis whichever test is used, and that their diagnostic accuracy is better using all three methods than using any method singly. There is also general agreement that Doppler techniques give fewer false positive results than the others in all categories of angiographic stenosis. We suggest that the reason for this is that Doppler techniques are easier to standardise and are less subject to inter-observer error but we have no firm evidence to support this impression which is worth further study.

Quantitative analysis of the data has been attempted¹²⁻¹⁴ without useful separation of the patients into the various disease states. Values of the A/B ratio, ICR (Index of Circulatory Resistance) and transit time between various measurement sites were calculated both for the patient group and a set of asymptomatic volunteers of comparable age range prior to the present form of analysis. The use of pattern recognition techniques similar to those described by Martin¹⁵ may allow quantification of the data which we feel is essential if this technique is to be used widely in the early detection of arterial disease and patients experiencing transient ischaemic attacks or minor strokes. From the literature it appears that in patients with carotid disease the site of the lesion is within 3-4 cm of the bifurcation in at least 75% of cases.¹⁵ Separation of proximal and distal effects on the Doppler signature can be difficult with both extracranial and proximal arterial disease. We are attempting to overcome such problems by including measurements at the aortic arch, subclavian and brachial arteries and analysing the results in conjunction with the common carotid arterial measurements. These results will be discussed in a future publication.

We suggest, in conclusion, that the test described in this paper could be adopted as a screening procedure in a vascular or neurological clinic and would assist in the separation of patients with severe carotid disease from those with mild or no disease. This grading is available from a combination of the compression test and the waveform characteristics of the Doppler signature obtained from the common carotid artery. The sensitivity of the CW Doppler Test to mild and moderate disease should be improved by use of the presence of turbulence on the internal carotid artery signals, in the cases where this is easily obtained.¹⁷ On the basis of our initial experience in using the Doppler test to separate severe from mild or no disease, false positive results do not occur. False negative results in patients with severe disease are reduced to one out of 15 (approximately 6%) by incorporation of the compression test into the measurement procedure. In clinical practice this percentage would be further reduced if the presence of a bruit were accepted as an indication of moderate or severe disease. Our current clinical practice is not to recommend arterial surgery for patients with mild disease, so that the accurate identification of patients with mild disease or no disease would eliminate the need for angiography in these patients. Whether a

3% to 6% risk of a false negative is acceptable for a particular patient will depend upon the clinical problem and the practice of the unit in which he is being treated. The localisation and quantification of the disease at the bifurcation and particularly the separation of severe stenosis from complete occlusion will require the use of pulsed Doppler imaging facilities;¹⁸ these are under development at this laboratory.

We thank Mrs VA Cannon, Mr SWJ Smith and Mr G Westgarth for their assistance in execution of the tests and to the other consultant neurologists and neurosurgeons at the Wessex Neurological Centre, and the vascular surgeons at the Royal South Hants Hospital, Southampton for allowing their patients to take part in this study. The authors would also like to thank Mrs M Peacock for her typing of the manuscript.

References

- Deck MDF. Radiologic examination of patients with stroke. *Postgrad Med* 1976; **59**:123-31.
- Bone GE, Barnes RW. Limitations of the Doppler cerebrovascular examination in hemispheric cerebral ischaemia. *Surgery* 1976; **5**:577-80.
- Keller H, Meier W, Yonekawa Y, Kumpe D. Non invasive angiography for the diagnosis of carotid disease using Doppler ultrasound. *Stroke* 1976; **7**:354-63.
- Wise G, Brockenbrough EC, Marty R, Griep R. The detection of carotid artery obstruction: a correlation with arteriography. *Stroke* 1971; **2**: 105-13.
- Brockenbrough EC. Screening for the prevention of stroke: use of the Doppler flowmeter. Brochure issued by the Alaska/Washington Regional Medical Programme 1969.
- Barnes RW, Russell HE, Bone GE, Slaymaker EE. Doppler cerebrovascular examination: improved results with refinements in technique. *Stroke* 1977; **8**:468-71.
- Moore WS, Bean B, Burton R, Goldstone J. The use of ophthalmoscopy in the diagnosis of carotid artery stenosis. *Surgery* 1977; **82**:107-15.
- Coghlan BA, Taylor MG. Directional Doppler techniques for the detection of blood velocities. *Ultrasound Med Biol* 1976; **2**:181-8.
- Rutherford RB, Hiatt WR, Kreutzer EW. The use of velocity waveform analysis of carotid occlusive disease. *Surgery* 1977; **82**:695-702.
- Muller HR. The diagnosis of internal carotid artery occlusion by directional Doppler sonography of the ophthalmic artery. *Neurology (Minneapolis)* 1972; **22**:816-23.
- Lunt MJ, Reuben JR, duBoulay EPGH. Preliminary report on some ultrasonic methods for detecting carotid artery disease. *J Med Eng Technol* 1978; **2**:289-97.
- Baskett JJ, Beasley MG, Murphy GJ, Hyams DE, Gosling RG. Screening for carotid junction disease by spectral analysis of Doppler signals. *Cardiovasc Res* 1977; **11**:147-55.
- Horrocks M, Roberts VC, Cotton LT. Assessment of carotid artery stenosis using pulse wave transit time. *Br J Surg* 1979; **66**:265-8.
- Planiol T, Pourcelot L. Doppler effect study of the carotid circulation. In: deVlieger M, ed. *Proceedings of the second world congress on ultrasonics in medicine*. Amsterdam: Acta Medica 1974; 104-11.
- Martin TRP, Barber DC, Sherriff SB, Pritchard DR. Objective feature extraction applied to the diagnosis of carotid artery disease using a Doppler ultrasound technique. *Clin Phys Physiol Measurement* 1980; **1**:71-81.
- Hass WK, Fields WS, North RR, Kricheff II, Chase NE, Bauer RB. Joint study of extracranial arterial occlusion II arteriography, techniques sites, and complications. *JAMA* 1968; **203**:961-8.
- Kitney RI, Giddens DP, Mabon RF. Flow disturbance analysis of aortic velocity waveforms. BE5 20th anniversary international conference on blood flow theory and practice (proceedings). Biological Engineering Society.
- Woodcock JP, Hope DT, Skidmore R, Lusby RJ. Doppler scanning of the extracranial carotid arteries. In: Baird RN and Woodcock JP, eds. *Diagnosis and Monitoring in Arterial Surgery*. Bristol: John Wright and Sons, 1980; 63-8.
- Keagy BA, Pharr WF, Thomas DD, Bowes DE. Oculoplethysmography/carotid phonoangiography. It's value as a screening test in patients with suspected carotid artery stenosis. *Arch Surg* 1980; **115**:1199-202.
- House SL, Mahalingham K, Hyland MJ, Ferris EB, Comerota AJ, Cranley JJ. Non invasive flow techniques in the diagnosis of cerebrovascular disease. *Surgery* 1980; **87**:696-700.
- O'Donnell TF Jr, Pauker SG, Callow AD, Kelly JJ, McBride KJ, Korwin S. The relative value of carotid non-invasive testing as determined by receiver operator characteristic curves. *Surgery* 1980; **87**:9-19.
- Goran A, Moore G. Value of the non invasive cerebrovascular laboratory in diagnosis of extracranial carotid artery disease. *Stroke* 1980; **11**: 325-8.