

Invasive Squamous Carcinoma and Adenocarcinoma of an Unreconstructed Exstrophic Bladder with HPV Infection

Mesut Altan^a Burak Çıtamak^a Hakan Bahadır Haberal^a Emrullah Söğütülen^a
Ali Cansu Bozaci^a Dilek Ertoy Baydar^b Hasan Serkan Doğan^b Serdar Tekgül^a

^aDepartment of Urology; and ^bDepartment of Pathology, Hacettepe University, Ankara, Turkey

Key Words

Bladder exstrophy • Squamous cell carcinoma • Adenocarcinoma • Unreconstructed exstrophic bladder • HPV infection

Abstract

Bladder exstrophy is a complex abnormality and is traditionally treated within the early years of life. It is associated with an increased risk of bladder cancer, with 95% of the arising tumors being adenocarcinomas and 3 to 5% being squamous cell carcinomas. HPV infections are also associated with an increased risk of bladder cancer. This case represents a patient with bladder exstrophy that gave rise to coinciding squamous cell carcinoma and adenocarcinoma. Final pathology results showed an infection with HPV. We presented the management of the case and discussed the diagnosis and treatment methods for this patient.

Copyright © 2015 S. Karger AG, Basel

Introduction

Bladder exstrophy is a complex congenital abnormality and is traditionally recommended to be treated within the early years of life. It occurs in approximately 1 in 35,000 live births and is associated with an increased incidence of bladder cancer [1]. Treatment of bladder exstrophy in patients who present in adulthood is rarely reported in the literature [2–6]. The malignant potential of the exstrophied bladder mucosa is well known, with 95% of the arising tumors being adenocarcinomas and 3–5% being squamous cell carcinomas [7, 8]. We report a rare case of concomitant squamous cell carcinoma (SCC) and adenocarcinoma in the bladder of a 37-year-old man with unreconstructed bladder exstrophy. The presented case is the first recently reported patient with bladder exstrophy giving rise to coinciding squamous cell carcinoma and adenocarcinoma.

Case Report

A 37-year-old man applied to our clinic mainly suffering from persistent incontinence. He had a history of exstrophia vesicae closure attempt twice in 1981 and iliac osteotomy in the same year that resulted in complete failure. Our physical examination revealed operation scars, one of which was vertical at the suprapu-

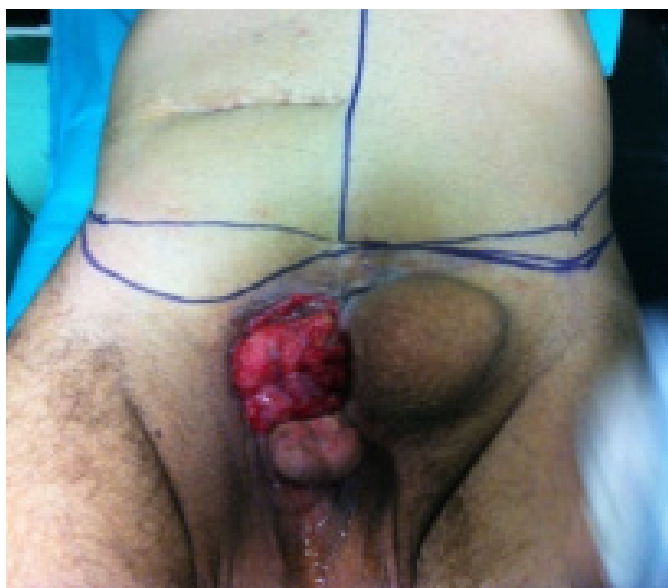

Fig. 1. Preoperative image. Bladder mucosa is easily seen by inspection.

bic skin and the other was transverse to the right of the umbilicus (fig. 1). Bladder mucosa and bilateral ureter orifices were easily seen. No mass lesion could be noted. There was a very large hernia immediately left of the bladder and bilateral huge hydroceles. The serum biochemistry and complete blood count were normal. Simple cystectomy with ileal loop diversion, bilateral hydrocelectomy, penile reconstruction, hernia repair with prolene mesh, and abdominoplasty were done in December, 2013.

Pathology

Macroscopic examination of the specimen revealed an ulcerated polypoid mass measuring $5 \times 4.5 \times 1$ cm in size, mainly occupying the left part of the bladder, but also extending to the right half over the midline (fig. 2). The cut surface showed a vague solid white lesion with indistinct borders. Ureters and their orifices were patent. Microscopically, hematoxylin and eosin-stained tissue sections from the lesion indicated a collision tumor composed of 2 different types. One was a moderately differentiated intestinal type adenocarcinoma and the other was an intermediate grade SCC (fig. 3). They were closely intermixed and both infiltrated the muscularis propria in the bladder wall. Surgical margins were free of the tumor. There were wide-spread squamous and intestinal metaplasia in the non-neoplastic mucosa of the organ. Koilocytotic atypia reflecting the HPV effect was

noted in the metaplastic squamous epithelium. The presence of HPV was confirmed by PCR amplification after the extraction of the bladder and tumor DNA from paraffin embedded tissue sections. HPV genotyping was performed using the HBGA-21 GenoArray Diagnostic Kit (Hybridio Biotechnology LTD Corp, Chaozhou, Guangdong Province, China). Results showed mixed infection with high risk HPV types of 16, 18, 35, and 56.

Follow-up

The patient was referred to the medical oncology department. No adjuvant treatment was started. He is under regular follow-up visits and alive with no evidence of disease one year after surgery.

Discussion

Exstrophy increases the risk of neoplasia in the bladder by 694 times as compared to the general population [9]. SCC arising in an exstrophic bladder is a very rare situation although squamous metaplasia has been found in 80% of such cases [10]. In the literature, there are only 10 reported cases of SCC arising from an exstrophic bladder. These patients had no surgical history for exstrophic bladder repair. Only two of them were primary closed and one of them also had an augmentation cystoplasty procedure, but the other's surgery resulted in failure.

The exact pathogenesis of tumor development in an exstrophic bladder is not clear. It was proposed that genitourinary secretions might exert a carcinogenic effect on the boundary skin [11], but this has yet not been proved. Chronic irritation and infection that lead to metaplastic transformation of the urothelium which may end up with malignant transformation seem to be the most logical possibility. In addition to this, the intrinsic predisposition to malignancy should be considered [9].

Adenocarcinomas in the bladder are most commonly metastatic. Primarily gastrointestinal adenocarcinomas, that also metastase from endometrial, pulmonary, and prostatic cancers should be kept mind. Chronic infections and nitrosamines produced by bacteria in the urine and feces are suspected in the development of adenocarcinomas in ureterosigmoidostomy patients [12, 13]. In the case of an exstrophic bladder, the environmental irritation and chronic infection may induce urothelial cells to undergo glandular metaplasia [14]. For enteric aug-

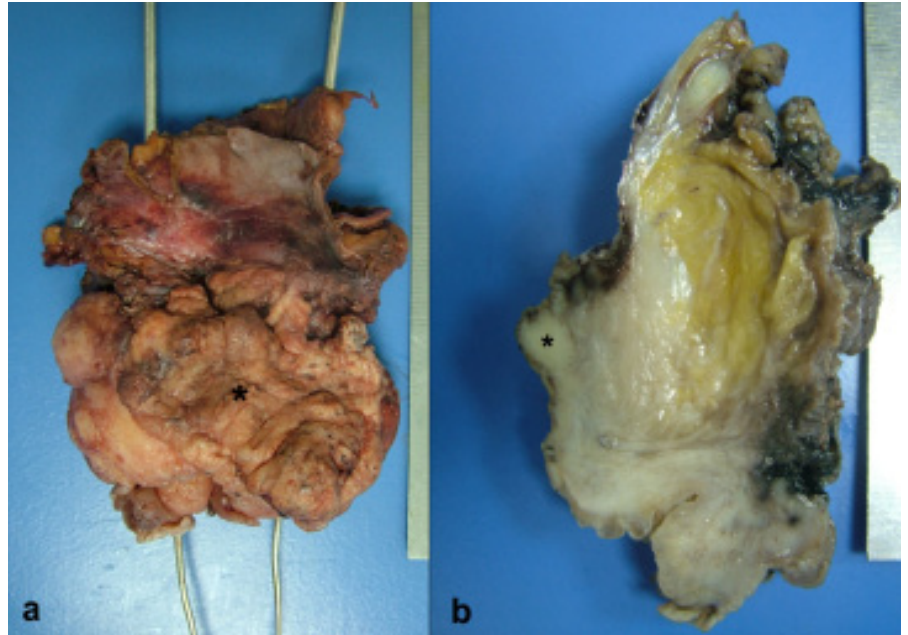


Fig. 2. Macroscopical appearance of the specimen after operation. Asterisk shows tumor, metal sticks point out the ureters. **a)** Front view. **b)** Cut surface.

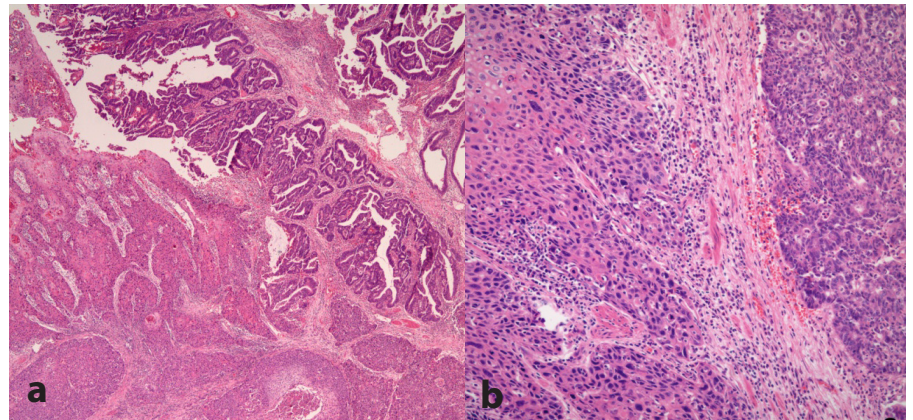


Fig. 3. Micrographs from the tumor having 2 different components. Squamous cell carcinoma is seen on the left whereas adenocarcinoma is on the right in both pictures **a)** H & E $\times 40$, **b)** H & E $\times 200$).

mentation bladders, exstrophy is a risk factor for cancer development [15]. These facts may be hints of the intrinsic predisposing factor.

There appears to be an increased risk of bladder cancer associated with HPV infection, which has been documented by the results of previous meta-analyses [16,17]. These meta-analyses have failed to show a connection

between HPV types and bladder cancer histology. In a recent meta-analysis, high risk HPV types, especially type 16, were found to be responsible for bladder tumor carcinogenesis [18]. The presence of high risk HPV types in our patient strongly implicates a viral carcinogenesis at least in the SCC component of the tumor.

Since unreconstructed exstrophic bladder patients have a higher risk of bladder cancer development, we suggest biopsy from uncorrected exstrophic bladders especially in adult patients. If a malignancy is detected, we advocate radical surgical management after exclusion of a metastasis from other primary sites, especially from the gastrointestinal tract in the case of adenocarcinoma. The role of chemotherapy or radiotherapy in patient management cannot be specified due to the small number of patients.

Conclusion

Exstrophia vesica is a rare congenital disorder. In today's practice, reconstruction surgeries are required very early in the life. Even if the appropriate surgical corrections are done on time, exstrophia vesica patients still have a significantly higher risk for bladder cancer than the population. Early diagnose, early surgery, intensive care, and multidisciplinary approaches are the key parts of the treatment on these patients.

References

- 1 Grossfeld GD, Carroll PR: Evaluation of asymptomatic microscopic hematuria. *Urol Clin North Am* 1998;25:661–676.
- 2 Matsuda T, Okada Y, Takeuchi H, Yoshida O: Adult female exstrophy of bladder treated with a Koch continent reservoir: report of a case. *Urol Int* 1987;42:74–76.
- 3 Gulati P, Yadav SP, Sharma U: Management of bladder exstrophy in adulthood: report of 2 cases. *J Urol* 1997;157:947–948.
- 4 Ozdiler E, Sarica K, Baltaci S, Isikay L, Kossar A, Yaman O: A 49-year-old woman with non-complicated exstrophy of bladder. *Int Urol Nephrol* 1996;28:747–750.
- 5 Quattara K, Daffe S, Timbely A: Exstrophy of the bladder in adults. *J Urol (Pars)* 1992; 98:64–65.
- 6 Pathak HR, Mahajan R, Ali NI, Kaul S, Andankar MG: Bladder preservation in adult classic exstrophy: early results of four patients. *Urology* 2001;57:906–910.
- 7 de Riese WD, Warmbold H: Adenocarcinoma in extrophy of the bladder, a case report and review of the literature. *Int Urol Nephrol* 1986;18:159–162.
- 8 Gupta S, Gupta IM: Ectopia vesica complicated by squamous cell carcinoma. *Br J Urol* 1976;48:224.
- 9 Smeulders N, Woodhouse CR: Neoplasia in adult exstrophy patients. *BJU Int* 2001;87: 623–628.
- 10 Witters S, Baert-Van Damme L: Bladder exstrophy complicated by adenocarcinoma. *Eur Urol* 1987;13:415–416.
- 11 Rieder JM, Parsons JK, Gearhart JP, Schoenberg M: Primary squamous cell carcinoma in unreconstructed exstrophic bladder. *Urology* 2006;67:199.
- 12 Husmann D, Spence H: Current status of tumor of the bowel following ureterosigmoidostomy: a review. *J Urol* 1990;144:607–610.
- 13 Filmer R, Spencer J: Malignancies in bladder augmentations and intestinal conduits. *J Urol* 1990;143:671–678.
- 14 McIntosh JF, Worley G Jr: Adenocarcinoma arising in exstrophy of the bladder: report of two cases and review of the literature. *J Urol* 1955;73:820–829.
- 15 Husmann DA, Rathbun SR: Long-term follow up of enteric bladder augmentations: the risk for malignancy. *J Pediatr Urol* 2008;4: 381–385.
- 16 Gutierrez J, Jimenez A, de Dios Luna J, Soto MJ, Sorlozano A: Meta-analysis of studies analyzing the relationship between bladder cancer and infection by human papillomavirus. *J Urol* 2006;176:2474–2481.
- 17 Wiwanitkit V: Urinary bladder carcinoma and human papilloma virus infection, an appraisal of risk. *Asian Pac J Cancer Prev* 2005; 6:217–218.
- 18 Li N, Yang L, Zhang Y, Zhao P, Zheng T, Dai M: Human papillomavirus infection and bladder cancer risk: a meta-analysis. *J Infect Dis* 2011;204:217–223.